



# Percutaneous Hallux Valgus: An Algorithm for the Surgical Treatment\*

## *Hálux valgo percutâneo: Um algoritmo para o tratamento cirúrgico*

Igor Marijuschkin<sup>1</sup> Matheus Levy Souza<sup>2</sup> José Luiz Garcia Diaz<sup>1</sup> Paulo Carvalho<sup>3</sup>

<sup>1</sup>Hospital São Lucas, Santos, SP, Brazil

<sup>2</sup>Hospital Mater Dei, Belo Horizonte, MG, Brazil

<sup>3</sup>Hospital Ortopédico de Santana, Parede, Portugal

Address for correspondence Igor Marijuschkin, MD, Clínica do Pé, Av. Washington Luis 316, Santos, SP, 11055-001, Brazil (e-mail: igormarijus@hotmail.com).

Rev Bras Ortop 2021;56(4):504–512.

### Abstract

**Objective** To present the clinical and radiographic results of hallux valgus surgical correction using four percutaneous techniques, chosen according to a predefined radiographic classification.

**Methods** We prospectively evaluated 112 feet in 72 patients with hallux valgus operated over the course of 1 year. Percutaneous distal soft tissue release (DSTR) and the Akin procedure (DSTR-Akin) were performed in mild cases. In mild to moderate hallux valgus with distal metatarsal joint angle  $> 10^\circ$ , we added the Reverdin-Isham (RI) osteotomy. In moderate cases with joint incongruity, we performed the percutaneous chevron (PCH). Finally, a Ludloff-like percutaneous proximal osteotomy fixed (PPOF) with a screw was proposed in severe cases with an intermetatarsal angle (IMA)  $> 17^\circ$ . According to these criteria, 26 DSTRs-Akin, 36 PCHs, 35 RIs, and 15 PPOFs were performed. The mean follow-up was of 17.2 months (range: 12 to 36 months). The mean age at operation was 58.8 years (range: 17 to 83 years), and 89% of the patients were female.

**Results** The mean preoperative hallux valgus angle (HVA) and the IMA decreased from  $21^\circ$  to  $10.2^\circ$  and from  $11.2^\circ$  to  $10.3^\circ$  respectively in the DSTR-Akin. In the RI, the mean HVA decreased from  $26.6^\circ$  to  $13.7^\circ$ , and the IMA, from  $11.2^\circ$  to  $10.3^\circ$ ; in the PCH, the mean HVA decreased from  $31^\circ$  to  $14.5^\circ$ , and the IMA decreased  $14.9^\circ$  to  $10.7^\circ$ ; as for the PPOF, the mean HVA decreased from  $39.2^\circ$  to  $17.7^\circ$ , and the IMA, from  $11.8^\circ$  to  $6.8^\circ$ . The average ankle and hindfoot score of the American Orthopaedic Foot and Ankle Society (AOFAS) increased from 49.2 to 88.6. The rate of complications was of 11%.

**Conclusion** Our treatment protocol does not differ much from the classic ones, with similar results as well. We have as advantages less aggression to soft tissues and better cosmetic results. Level of Evidence: level IV, prospective case series.

### Keywords

- ▶ hallux valgus
- ▶ metatarsal bones
- ▶ minimally invasive surgical procedures

\* Work developed at Hospital São Lucas, Santos, SP, Brazil.

received  
April 28, 2020  
accepted  
September 16, 2020

DOI <https://doi.org/10.1055/s-0040-1721367>.  
ISSN 0102-3616.

© 2021. Sociedade Brasileira de Ortopedia e Traumatologia. All rights reserved.

This is an open access article published by Thieme under the terms of the Creative Commons Attribution-NonDerivative-NonCommercial-License, permitting copying and reproduction so long as the original work is given appropriate credit. Contents may not be used for commercial purposes, or adapted, remixed, transformed or built upon. (<https://creativecommons.org/licenses/by-nc-nd/4.0/>)

Thieme Revinter Publicações Ltda., Rua do Matoso 170, Rio de Janeiro, RJ, CEP 20270-135, Brazil

## Resumo

**Objetivo** Apresentar os resultados clínicos e radiográficos da correção cirúrgica de hálux valgo utilizando quatro técnicas percutâneas escolhidas de acordo com uma classificação radiográfica predefinida.

**Métodos** Avaliamos prospectivamente 112 pés em 72 pacientes com hálux valgo operado em um período de um ano. A liberação de tecido mole distal (LTMD) percutâneo e o procedimento de Akin (LTMD-Akin) foram realizados em casos leves. Em hálux valgo de leve a moderado com ângulo distal da articulação do metatarso acima de 10°, adicionamos a osteotomia de Reverdin-Isham (RI). Em casos moderados com incongruência articular, realizamos o *chevron* percutâneo (CHP). Finalmente, uma osteotomia proximal percutânea fixada (OPPF) com um parafuso, semelhante à de Ludloff, foi proposta em casos graves com ângulo intermetatarsal (AIM) acima de 17°. De acordo com esses critérios, foram realizados 26 LTMDs-Akin, 36 CHPs, 35 RIs e 15 OPPFs. O seguimento médio foi de 17,2 meses (12 a 36 meses). A média de idade em operação foi de 58,8 anos (17 a 83 anos), e 89% dos pacientes eram do sexo feminino.

**Resultados** A média do ângulo de hálux valgo (AHV) pré-operatório e o AIM diminuíram de 21° para 10,2°, e de 11,2° para 10,3°, respectivamente, em casos de LTMD-Akin. Em casos de RI, a média do AHV diminuiu de 26,6° para 13,7°, e o AIM, de 11,2° para 10,3°; em casos de CHP, o AHV médio diminuiu de 31° para 14,5°, o AIM diminuiu de 14,9° para 10,7°, e a OPPF, de 39,2° para 17,7°, e o AIM 11,8° para 6,8°. A média do escore de tornozelo e retopé da American Orthopaedic Foot and Ankle Society (AOFAS) aumentou de 49,2 para 88,6. A taxa de complicação foi de 11%.

**Conclusão** Nosso protocolo de tratamento não difere muito dos clássicos, com resultados semelhantes. Temos como vantagem menos agressividade aos tecidos moles e melhores resultados cosméticos. Nível de evidência: nível IV, série de casos prospectivos.

## Palavras-chave

- ▶ hálux valgo
- ▶ ossos do metatarso
- ▶ procedimentos cirúrgicos minimamente invasivos

## Introduction

Percutaneous surgery is a set of techniques performed with punctiform incisions in order to enable the performance of osteotomies, exostectomies and capsulotomies, while minimizing aggression to the soft tissues. This surgical approach was developed 65 years ago, but only gained notoriety after 1985 in the United States,<sup>1</sup> in the 1990s in Europe with Mariano Prado and Pau Golano,<sup>2</sup> and in 2002 in France with the Groupe de Recherche et d'Etude en Chirurgie Mini-Invasive du Pied (Group of Research and Study in Minimally-Invasive Surgery of the Foot, GRECMIP).<sup>3</sup>

Following a worldwide trend in several areas of orthopedics to reduce incisions and surgical aggression in order to decrease complications and comorbidities, we developed a protocol for hallux valgus (HV) surgery. We used already-defined radiographic criteria, which do not differ much from those used by other authors.<sup>4,5</sup> We used four percutaneous techniques to perform the procedures in an individualized manner, respecting angular changes, particular characteristics and all aspects that may alter the surgical indication, similar to those found in algorithms regarding open procedures.

The objective of the present study is to describe the clinical, functional and radiographic results of the surgical treatment of HV by percutaneous techniques.

## Material and Methods

The project was submitted and approved by the institution's Ethics in Research Committee, under number 0001/2020.

We prospectively evaluated 112 feet in 72 patients with HV operated over the course of 1 year by the same surgeon. The surgical indications were based on the severity of the angular radiographic findings, as well as the presence of a congruent metatarsophalangeal (MTP) joint and increased distal metatarsal articular angle (DMAA). Deformity was considered mild when the hallux valgus angle (HVA) was between 12° and 30°, the intermetatarsal angle (IMA) was between 8° and 14°, and the distal metatarsal articular angle (DMAA) was lower than 10°. Moderate HV was considered when the HVA was  $\leq 40^\circ$ , and the IMA was between 14° and 17°; mild to moderate HV with an increased DMAA was considered if the DMAA was greater than 10°, with the HVA  $\leq 40^\circ$  and the IMA  $\leq 17^\circ$ . Severe HV was defined as HVA greater than 40° or IMA greater than 17° (► **Table 1**).

The HVA is the angle formed by the middle axis of the diaphysis of the proximal hallux phalanx and the mechanical axis of the first metatarsus. The IMA is the angle formed between the mechanical axis of the first and second metatarsi, and the DMAA is the angle formed between the line perpendicular to the articular surface of the head of the first metatarsus and the long axis of the first metatarsus. All angular

**Table 1** Radiographic features and proposed procedure

	Mild hallux valgus	Mild to moderate hallux valgus with high distal metatarsal articular angle	Moderate hallux valgus	Severe hallux valgus
Angle	Intermetatarsal angle < 14°	Intermetatarsal angle: 8° to 17°	Intermetatarsal angle: 12° to 17°	Intermetatarsal angle > 17°
	Hallux valgus angle < 30°	Hallux valgus angle: 12° to 40°	Hallux valgus angle: 20° to 40°	Hallux valgus angle > 30°
		distal metatarsal articular angle > 10°	Joint incongruence	
Technique	Percutaneous distal soft tissue release and Akin procedure	Reverdin-Isham	Percutaneous Chevron	Proximal Percutaneous Osteotomy

measurements were performed digitally on anteroposterior weight-bearing x-rays using a commercially-available software (Directview, Carestream, NY, US) (→Fig. 1A, B and C). The patients were evaluated using the ankle and hindfoot score of the American Orthopaedic Foot and Ankle Society (AOFAS),<sup>6</sup> followed by clinical and radiographic analyses, as well as an analysis of the degree of subjective satisfaction of Johnson,<sup>7</sup> each performed before and after surgery.

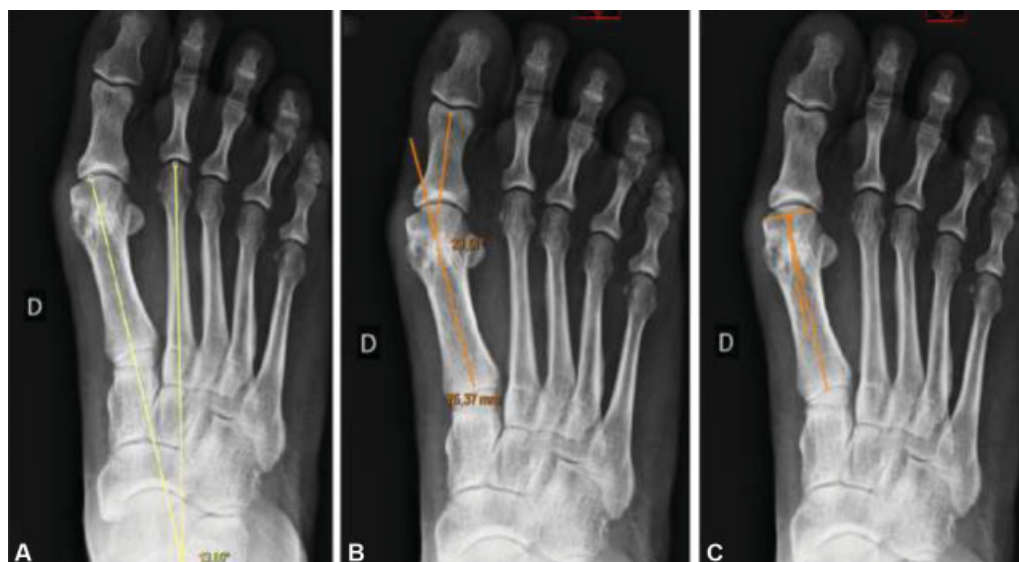The statistical analysis was performed with the EvIEWS 11 (IHS Markit, London, UK) software for Windows, and the paired Student *t*-test was used to evaluate the results with a significance level < 0.05.

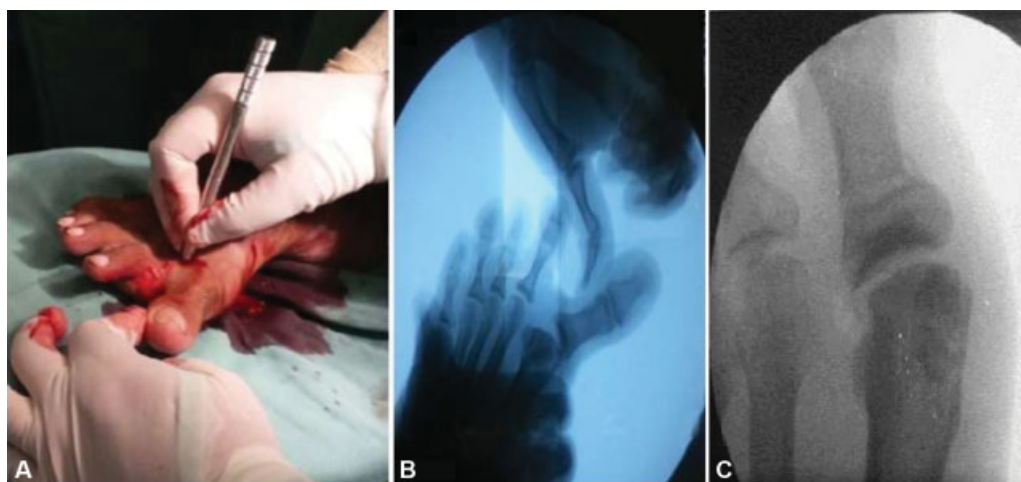
In mild HV, we percutaneously performed exostectomy, distal soft tissue release (DSTR) and Akin osteotomy<sup>8</sup> (DSTR-Akin). The surgery was performed under locoregional or spinal anesthesia, with the patient in supine position and the feet overhanging the end of the table, with the operated foot supported on the image intensifier. Tourniquet was not necessary.

An incision was made in the plantar base of the exostosis of the first metatarsus with the Beaver 64 (BVI, Waltham, MA,

US) scalpel. Afterwards, we removed the periosteum, with the scraper or scalpel, and performed an exostectomy using a 3.1-mm wedge burr. The bone was removed from the joint by manual compression or with a scraper, and, sometimes, with saline solution. Next, we made a dorsolateral incision in the metatarsophalangeal joint of the hallux to perform the tenotomy of the adductor tendon of the hallux and lateral capsulotomy (→Fig. 2A and B). To do so, we moved the finger medially; promoting a varus of the hallux, introducing the Beaver scalpel with the cutting face aimed laterally and deeply, and performed lateral capsulotomy and tenotomy. Finally, we performed a medial incision at the base of the proximal phalanx and, with the wedge 3.1-mm burr, an incomplete osteotomy was performed to obtain a closing wedge after a manual compression. The osteotomy was stable, and no fixation was necessary (→Fig. 1C).

In mild to moderate deformities with altered DMAA, we performed the Reverdin-Isham<sup>1,3</sup> (RI) technique. We performed exostectomy as previously described, followed by osteotomy using the same approach. We introduced a Shannon burr from dorsal to plantar at 45 degrees of lateral

**Fig. 1** Angular measurements. (A) Hallux valgus angle (HVA); (B) intermetatarsal angle (IMA); (C) distal metatarsal articular angle (DMAA).



**Fig. 2** (A) Dorsolateral incision in the metatarsophalangeal joint of the hallux; (B) fluoroscopy after adductor tendon tenotomy and capsulotomy; (C) Akin procedure on the image intensifier.

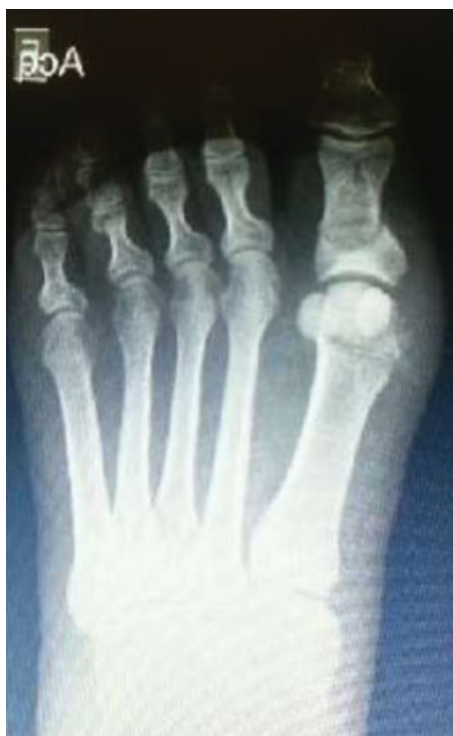inclination on the metatarsal head and cut the bone, taking care to preserve the lateral cortical. This enables the performance of a varus osteoclasia, closing the osteotomy and correcting the DMAA, while maintaining stability (► Fig. 3). Next, we performed the release of lateral soft tissues and Akin osteotomy, as previously described.

In cases of moderate HV with joint incongruity, we performed the percutaneous chevron (PCH) technique as described by Vernois.<sup>9</sup> We incised the base of the medial exostosis with the Beaver scalpel. With a 20-mm long Shannon burr, a v-shaped osteotomy was performed with the apex slightly dorsal in relation to the center of the shaft. The first

dorsal cut was perpendicular to the ground, and the second, at 90°, parallel to the floor. (► Fig. 4A, B and C). The burr should be parallel to the distal joint in the horizontal plane. With a Kirschner (K) wire or lever, the first metatarsal head was moved laterally and fixed with 1 or 2 screws with 3 mm in diameter. An exostectomy was performed if necessary, followed by the release of lateral soft tissues and the Akin procedure.

In cases of severe HV, percutaneous proximal osteotomy fixed (PPOF) with a screw, similar to the Ludloff osteotomy,<sup>10</sup> was performed. The Beaver 64 scalpel was used to create a proximal and lateral incision, 1 cm distal from the metatarsocuneiform joint. We detached the periosteum, and, with the Shannon 2 × 20-mm burr, performed an oblique distal plantar to dorsal proximal osteotomy (► Fig. 5A). With a K wire attached below the metatarsal head, the first metatarsus was moved laterally and secured with a 3.0-mm screw (► Fig. 5B). After this, we performed the percutaneous exostectomy, the lateral release of soft tissues, and the Akin procedure, as described.

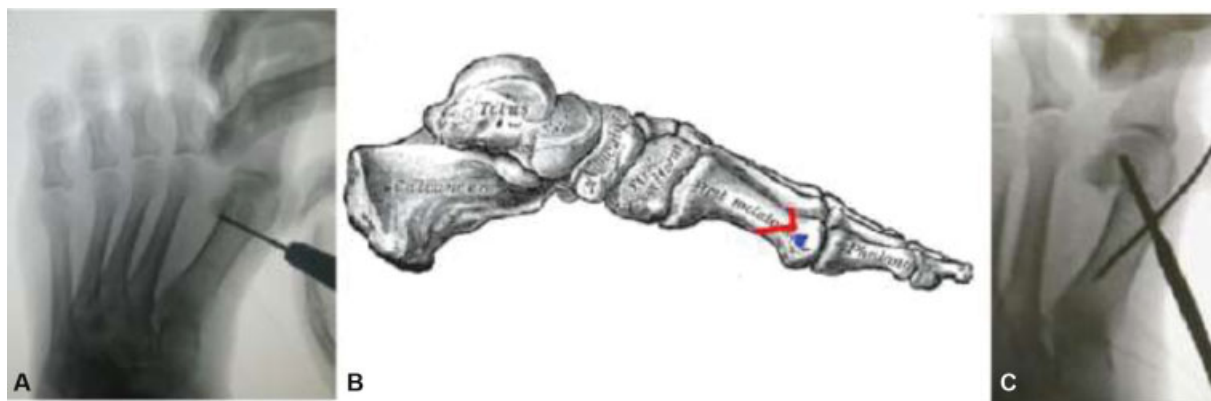
The bandage is made with gauze and adhesive tape, keeping the toe in a neutral position with 10° of flexion. The tapings were changed weekly, for 4 weeks, and immediate loading with rigid shoes was allowed as tolerated. When the pathology was bilateral, the patients were operated on both feet. Angular measurements were taken and questionnaires were applied at six weeks, six months and one year.



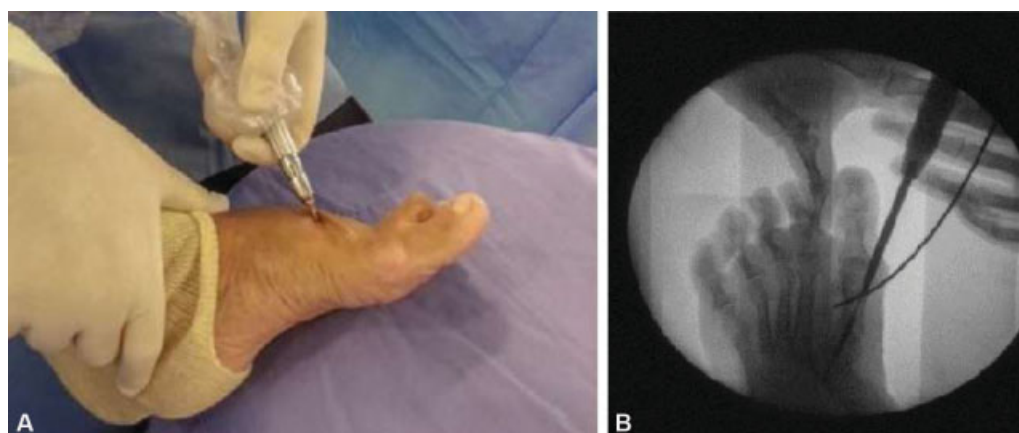**Fig. 3** Reverdin-Isham (RI) technique associated with exostectomy, tenotomy and Akin osteotomy.

## Results

In total, 72 (112 feet) patients, with an average age of 58.8 years (range: 17 to 83) were submitted to surgery, and 89% were female. They were divided in the 4 aforementioned categories, and 26 DSTRs-Akin (23.2%), 36 PCHs (32.1%), 35 IRs (31.25%), and 15 PPOFs (13.4%) were performed. A total of 54 (48%) feet required additional procedures to correct other associated deformities. We performed distal minimally-invasive metatarsal osteotomies in 26 feet, corrective fifth-bunion osteotomies in 14 feet, corrective osteotomies of toe deformities in 34 feet, neurolysis in 1 foot, and calcaneal osteotomies for flat feet on 2 patients.



**Fig. 4** (A) Fluoroscopy control showing the position of the burr, parallel to the articular surface of the first metatarsus during the first cut for the chevron osteotomy; (B) the red line shows the directions for the chevron cut; (C) fixation of the percutaneous chevron with one screw. A Kirschner wire is used to assist on the reduction.



**Fig. 5** (A) Position of the burr to perform the Ludloff osteotomy; (B) fixation of the osteotomy with one screw. A Kirschner wire is used to help translate the metatarsal head.

The average follow-up was of 17.2 months (range: 12 to 36 months). The mean preoperative HVA was of  $35.1^\circ$  (range:  $13^\circ$  to  $51^\circ$ ); postoperatively, it was of  $12.3^\circ$  (range:  $0^\circ$  to  $28^\circ$ ). Therefore, a mean correction of  $22.8^\circ$  was obtained, with the difference being statistically significant ( $p < 0.05$ ). The mean preoperative IMA was of  $13.7^\circ$  ( $6^\circ$  -  $23^\circ$ ) and of  $9.3^\circ$  ( $5^\circ$  to  $19^\circ$ ) postoperatively, with a mean correction of  $4.4^\circ$  ( $p < 0.05$ ). The mean preoperative AOFAS was of 49.2 (34 to 60), and, at the last follow-up, it was of 88.6 (45 to 100), with a mean increase of 39.4 points ( $p < 0.05$ ).

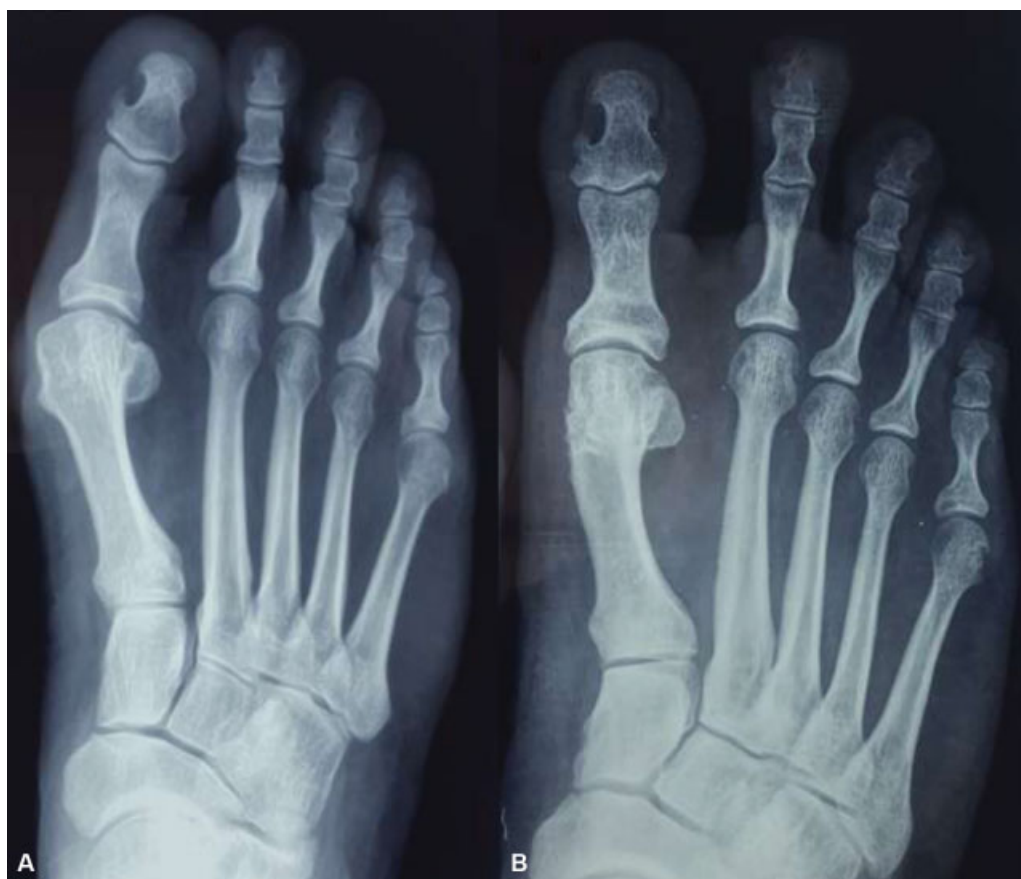When the groups were analyzed separately, in the cases of mild HV (**Fig. 6A and B**), the mean preoperative HVA was of  $21^\circ$  (range:  $15^\circ$  to  $27^\circ$ ), and, at the last follow-up, it was of  $10.2^\circ$  (range:  $4^\circ$  to  $21^\circ$ ). The mean angular correction was of  $10.8^\circ$  (range:  $7^\circ$  to  $20^\circ$ ). The mean preoperative IMA was of  $11.2^\circ$  (range:  $6^\circ$  to  $15^\circ$ ), and, at the last follow-up, it was of  $10.3^\circ$  ( $8^\circ$  to  $13^\circ$ ), with an average correction of  $0.9^\circ$  (range:  $0^\circ$  to  $2^\circ$ ). The mean preoperative AOFAS was of 55.6 (range: 34 to 65), and, postoperatively, it was of 94.2 (range: 77 to 100).

In the cases submitted to RI (**Fig. 7A and B**), the mean preoperative HVA was of  $26.5^\circ$  (range:  $18^\circ$  to  $36^\circ$ ), and, in the postoperative period, it was of  $13.7^\circ$  (range:  $6^\circ$  to  $21^\circ$ ), with  $12.8^\circ$  of average correction. The mean IMA was of  $13.4^\circ$  (range:  $11^\circ$  to  $17^\circ$ ) preoperatively, and  $12.6^\circ$  (range:  $7^\circ$  to

$17^\circ$ ) postoperatively, with a mean correction of  $0.8^\circ$ . The average AOFAS score increased from 52.4 (range: 44 to 60) to 85.3 (range: 70 to 100) points. In the moderate cases with articular incongruity in which PCH was indicated (**Fig. 8A and B**), the HVA decreased from  $31^\circ$  (range:  $26^\circ$  to  $40^\circ$ ) to  $14.5^\circ$  (range:  $3^\circ$  to  $26^\circ$ ), with a mean correction of  $16.5^\circ$ . The IMA decreased from  $14.9^\circ$  (range:  $9^\circ$  to  $17^\circ$ ) to  $10.7^\circ$  (range:  $8^\circ$  to  $16^\circ$ ), with a mean correction of  $4.2^\circ$ . The average AOFAS score increased from 42 to 87.1 points.

In severe cases, submitted to PPOF (**Fig. 9A and B**), the mean preoperative HVA decreased from  $39.2^\circ$  (range:  $30^\circ$  to  $51^\circ$ ) to  $17.7^\circ$  (range:  $8^\circ$  to  $28^\circ$ ), with a mean correction of  $21.5^\circ$ . The mean preoperative IMA decreased from  $18.4^\circ$  (range:  $15^\circ$  to  $23^\circ$ ) to  $11.8^\circ$  (range:  $7^\circ$  to  $17^\circ$ ), with a mean correction of  $6.8^\circ$ . The mean preoperative AOFAS was of 41.8 (range: 34 to 50) and increased to 88 (range: 70 to 100) points at the last follow-up. One patient was dissatisfied with the outcome due to recurrence.

Regarding the complications, there were 6 cases in which removal of the screw was needed (3 PCHs and 3 PPOFs), 1 case of fistula (PCH), 3 cases of joint stiffness (2 RIs and 1 PCH), 2 cases of residual edema after 1 year of the surgery (PPOF), 2 cases of transfer metatarsalgia (1 PCH and 1 PPOF), 2 asymptomatic non-unions of metatarsal osteotomy after



**Fig. 6** (A) Pre-operative mild case; (B) pos-operative (exostectomy + distal soft tissue release + Akin) mild case.

1 year, and 1 broken burr that could not be removed. Two patients presented a symptomatic callus, caused by dorsal dislocation of first metatarsal head (1 RI and 1 PPOF), there was 1 recurrence in less than 1 year (PPOF), and 1 non-transient neuropathy (DSTR-AKIN). These represent 18% of all cases. The percentage of complications was proportionally higher in the severe cases (33%; PPOF) followed by the moderate cases (18%; PCH), intermediate cases (17.6%; RI), and mild cases (12%; DSTR-Akin).

## Discussion

Several techniques for the surgical treatment of HV have been described. We do not believe that a single technique can solve all cases. The present study is based on modern treatment concepts, which have originated protocols based on clinical and radiographic changes.<sup>11,12</sup> Our protocol is based on the criteria and techniques already established regarding open procedures. The main difference is the application of this protocol with percutaneous techniques and stable fixation, preserving the local biology.<sup>13</sup>

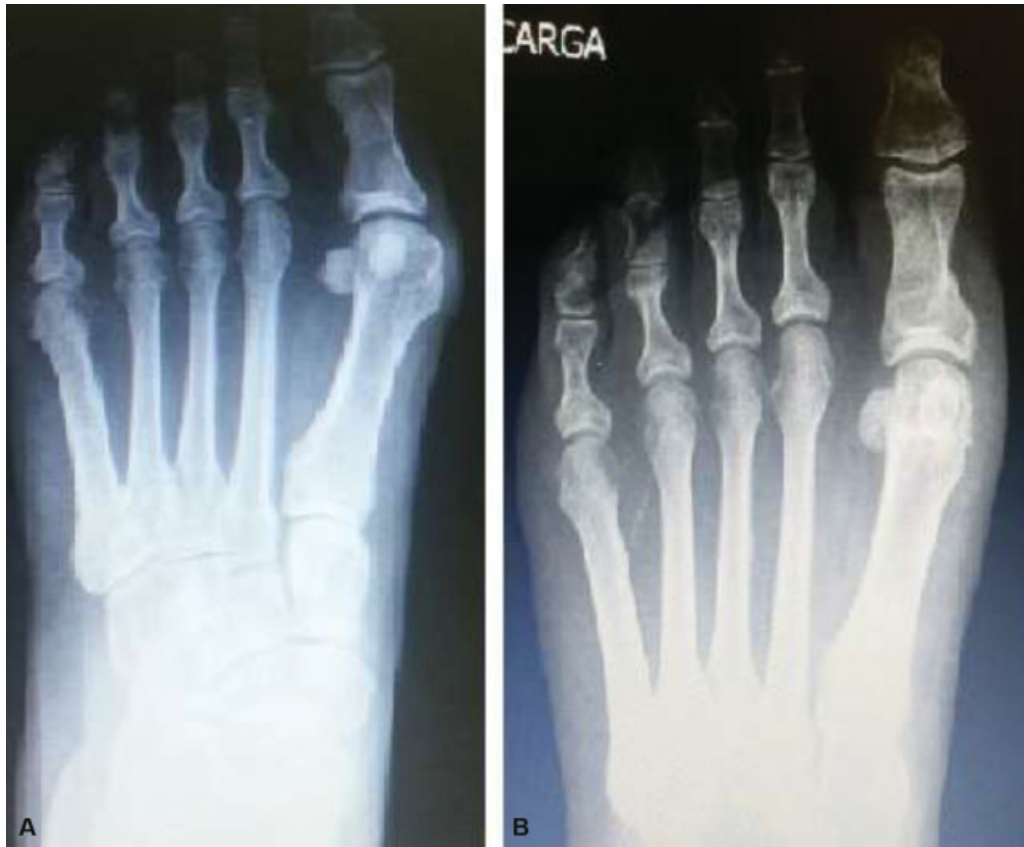In mild cases, we chose to perform the DSTR-Akin, according to Kayali et al.,<sup>14</sup> as the release of soft tissues rebalances the deforming forces and enables the achievement of good corrections. This procedure is performed only when the AIM is lower than 15°. In the present study, there was no recur-

rence after up to 28.6 months of follow-up. Colloff and Weitz<sup>15</sup> and Martinez-Nova et al.<sup>16</sup> also performed DSTR-Akin percutaneously in the treatment of mild to moderate HV, with similar results in the short term. Pansini et al.<sup>17</sup> used the Akin osteotomy in 89.1% of HV surgeries, highlighting the importance of this procedure for the correction of the deformity in combination with other techniques.

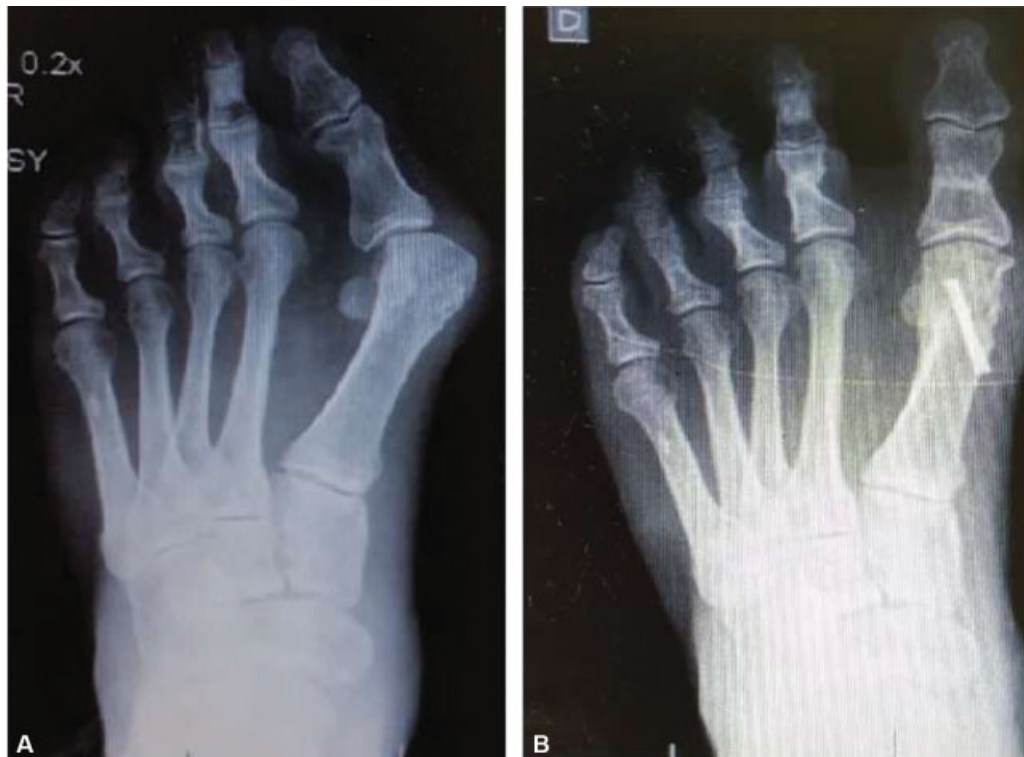We obtained similar results compared to those already published in the literature, in which the Austin technique is the most popular.<sup>18,19</sup> Basile et al.<sup>20</sup> compared the Akin procedure associated with chevron with DSTR-Akin and described similar results, with a mild radiographic advantage for the chevron with the Akin procedure.

In mild to moderate cases, which require DMAA correction, we considered the biplane chevron<sup>21</sup> the most appropriate open technique. We performed the RI<sup>4</sup> technique with good results, as already described in the literature in a multicenter study.<sup>5</sup>

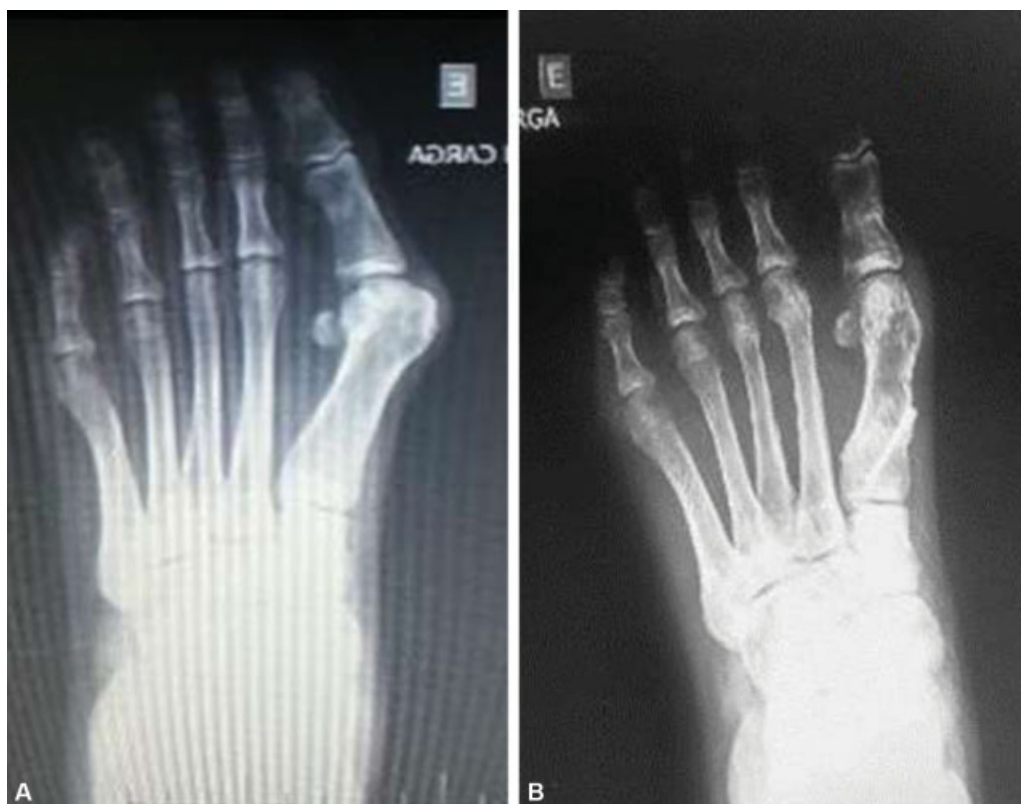In cases of moderate to severe HV with joint incongruity, we chose the percutaneous chevron procedure, as described by Vernois and Redfern.<sup>22</sup> Marijuschkin et al.<sup>23</sup> demonstrated the advantage of this technique with a low rate of complications and a high rate of patient satisfaction compared to conventional techniques. Lam et al.,<sup>24</sup> in a comparative study with the scarf osteotomy, highlighted an advantage in surgical time and postoperative pain. Brogan et al.<sup>25</sup> compared the conventional



**Fig. 7** (A) Pre-operative moderate case with altered DMAA; (B) post-operative RI procedure with exostectomy + tenotomy + Akin.



**Fig. 8** (A) Pre-operative moderate case with articular incongruence; (B) post-operative percutaneous chevron.



**Fig. 9** (A) Pre-operative severe halux valgus; (B) post-operative Ludloff-like osteotomy.

**Table 2** Pre and post-operative HVA and IMA values with average correction and AOFAS score

	Results							
Procedure	Initial HVA	Final HVA	(AC) HVA	Initial IMA	Final IMA	(AC) IMA	Initial AOFAS	Final AOFAS
DSTR-Akin	21°	10,2°	10,8°	11,2°	10,3°	0,9°	55.6	94.2
Reverdin-Isham	26,5°	13,7°	12,8°	13,4°	12,6°	0,8°	52.4	85.3
Percutaneous Chevron	31°	14,5°	16,5°	14,9°	10,7°	4,2°	42	87.1
PPOF	39,2°	17,7°	21,5°	18,4°	11,8°	6,8°	41.8	88
Total	35,1°	17,2°	22,8°	13,7°	9,3°	4,4°	49.2	88.6

Abbreviations: AC, average correction; AOFAS, ankle and hindfoot score of the American Orthopaedic Foot and Ankle Society; IMA, intermetatarsal angle; DSTR-Akin, distal soft tissue release and the Akin procedure; HVA, hallux valgus angle; PPOF, percutaneous proximal osteotomy fixed with a screw.

chevron and PCH, and stated there were no differences in complications and results, suggesting a short-term advantage for the PCH.

In severe cases, we chose the PPOF with screws, similar to the Ludloff osteotomy, enabling IMA correction. According to Saxena and McCammon,<sup>26</sup> who performed the conventional Ludloff osteotomy, this technique offers the advantage of better stability than the proximal chevron and crescent osteotomy. Lavigne et al.<sup>27</sup> described a triple percutaneous osteotomy for the correction of severe deformities, making 3 fixed shortening wedges, which was not our choice due to great technical difficulty. Vernois and Redfern<sup>13</sup> performed PCH and oblique incomplete first metatarsal base osteotomies for the treatment of severe HV, both with good results; these might also be good options. Regarding the open

techniques, Mann et al.<sup>28</sup> performed proximal osteotomy and lateral release with similar results and with 28% elevation of the metatarsal head, high complications typical of severe cases. Considering the Ludloff osteotomy, Myerson<sup>29</sup> described complications in 22 of 75 feet, and considered these good results, with good radiographic corrections and good patient satisfaction.

Percutaneous surgery has many advantages, especially considering its minimally-invasive characteristics. As presented by Lara et al.<sup>30</sup> it is less painful than open surgery, and has better cosmetic results and very similar overall results. These could be confirmed in our results by the elevated patient satisfaction and high AOFAS scores.

The present study has a few limitations regarding its case series design. On one hand, we did not have an open surgery



control group, and the follow-up was limited. On the other hand, it is a prospective work with a significant number of patients operated in a one-year period by the same surgeon. We believe that further research is necessary to establish this protocol, but the present study is a start, and it shows that the percutaneous techniques, with all of their benefits, could be performed in place of open procedures, with very similar results. In future studies, we suggest a longer follow-up in order to evaluate potential recurrence and a larger sample to confirm the protocol.

## Conclusion

The surgical techniques herein described were effective in the treatment of HV with an improvement in the AOFAS score, high patient satisfaction, and good radiographic correction.

With the percutaneous and conventional surgeries, physicians are able to treat HV regarding the peculiar characteristics of each case, considering the radiographic and clinical knowledge already acquired with the classic studies. The percutaneous approach has as the advantage of being less aggressive to the soft tissues, providing better cosmetic results and less painful recovery.

### Financial Support

There was no financial support from public, commercial, or non-profit sources.

### Conflict of Interests

The authors have no conflict of interests to declare.

## References

- Isham SA. The Reverdin-Isham procedure for the correction of hallux abducto valgus. A distal metatarsal osteotomy procedure. *Clin Podiatr Med Surg* 1991;8(01):81-94
- De Prado M, Ripoll PL, Golano P. Hallux valgus. In: *Percutaneous foot surgery*. Barcelona: Masson; 2003:57-94
- Bauer T, Biau D, Lortat-Jacob A, Hardy P. Percutaneous hallux valgus correction using the Reverdin-Isham osteotomy. *Orthop Traumatol Surg Res* 2010;96(04):407-416
- Coughlin MJ. Hallux valgus. *J Bone Joint Surg Am* 1996;78(06):932-966
- Coughlin MJ, Saltzman CL, Anderson RB. *Mann's Surgery of the Foot and Ankle*. 9th ed. Philadelphia: Elsevier/Saunders; 2014
- Rodrigues RC, Masiero C, Mizusaki JM, et al. Translation, cultural adaptation and validation of American Orthopedic Foot and Ankle Society (AOFAS) Ankle-Hindfoot scale. *Acta Ortop Bras* 2008;16(02):107-111
- Johnson KA, Cofield RH, Morrey BF. Chevron osteotomy for hallux valgus. *Clin Orthop Relat Res* 1979;(142):44-47
- Akin O. The treatment of hallux valgus - a new operative procedure and its results. *Med Sentinel* 1925;33:678-683
- Vernois J. L'ostéotomie et chevron percutané du premier métatarsien. In: Cazeau C, ed. *Chirurgie mini-invasive et percutanée du pied*. Paris: Sauramps Médical; 2009:97-104
- Ludloff K. Die beseitigung des hallux valgus Dirch die schrage plantodorsale osteotomei des metatarsalus I. *Arch Klin Chir* 1918;110:364-387
- Robinson AH, Limbers JP. Modern concepts in the treatment of hallux valgus. *J Bone Joint Surg Br* 2005;87(08):1038-1045
- Trnka HJ. Osteotomies for hallux valgus correction. *Foot Ankle Clin* 2005;10(01):15-33
- Vernois J, Redfern DJ. Percutaneous chevron: The union of classic stable Fixed approach and percutaneous technique. *Fuss & Sprunggelenk* 2013;11(02):70-75
- Kayali C, Ozturk H, Agus H, Altay T, Hancerli O. The effectiveness of distal soft tissue procedures in hallux valgus. *J Orthop Traumatol* 2008;9(03):117-121
- Colloff B, Weitz EM. Proximal phalangeal osteotomy in hallux valgus. *Clin Orthop Relat Res* 1967;54(54):105-113
- Martínez-Nova A, Sánchez-Rodríguez R, Leal-Muro A, Sánchez-Barrado E, Pedrera-Zamorano JD. Percutaneous distal soft tissue release-akin procedure, clinical and podobarometric assessment with the BioFoot in-shoe system: a preliminary report. *Foot Ankle Spec* 2008;1(04):222-230
- Pansini JV, Matunaga RY, Aguiar A, Buchen EC. Clinical and radiographic analysis of hallux valgus treatment by distal Chevron osteotomy. *Rev ABTPe* 2008;2(01):17-22
- Coull R, Stephens M. Operative decision making in hallux valgus. *Curr Orthop* 2002;16(03):180-186
- Trnka HJ, Zembsch A, Wiesauer H, Hungerford M, Salzer M, Ritschl P. Modified Austin procedure for correction of hallux valgus. *Foot Ankle Int* 1997;18(03):119-127
- Basile A, Battaglia A, Campi A. Comparison of chevron-Akin osteotomy and distal soft tissue reconstruction-Akin osteotomy for correction of mild hallux valgus. *Foot Ankle Surg* 2000;6(03):155-163
- Nery C, Barroco R, Réssio C. Biplanar chevron osteotomy. *Foot Ankle Int* 2002;23(09):792-798
- Vernois J, Redfern DJ. Percutaneous Surgery for Severe Hallux Valgus. *Foot Ankle Clin* 2016;21(03):479-493
- Marijuschkin I, Camargo AA, Diaz JL, Magalhães SL. Surgical treatment of mild and moderate hallux valgus by percutaneous Chevron technique. *Tobillo Pie* 2015;7(01):21-28
- Lam P, Lee M, Xing J, Di Nallo M. Percutaneous Surgery for Mild to Moderate Hallux Valgus. *Foot Ankle Clin* 2016;21(03):459-477
- Brogan K, Lindsfarne E, Akehurst H, Farook U, Shrier W, Palmer S. Minimally Invasive and Open Distal Chevron Osteotomy for Mild to Moderate Hallux Valgus. *Foot Ankle Int* 2016;37(11):1197-1204
- Saxena A, McCammon D. The Ludloff osteotomy: a critical analysis. *J Foot Ankle Surg* 1997;36(02):100-105
- Lavigne C, Rasmont Q, Hoang B. Percutaneous double metatarsal osteotomy for hallux valgus correction of severe deformity. *Acta Orthop Belg* 2011;77(04):516-521
- Mann RA, Rudicel S, Graves SC. Repair of hallux valgus with a distal soft-tissue procedure and proximal metatarsal osteotomy. A long-term follow-up. *J Bone Joint Surg Am* 1992;74(01):124-129
- Myerson MS. The Ludloff osteotomy. In: *Joint Meeting of the American Orthopaedic Foot & Ankle Society and the Japanese Society for Surgery of the Foot*. Hawaii, November 13-15, 1997
- Lara LC, Montesi Neto DJ, Guerra RR, Marques RF, Bicudo LR. Postoperative pain behavior of the hallux valgus using conventional, minimally invasive and percutaneous techniques. *Rev ABTPe* 2011;5(02):81-86