



# Treatment of Hip Wave Lesion Using Reverse Microfracture: A Retrospective Clinical Study

## *Tratamento da lesão em onda do quadril através da microfratura reversa: Estudo clínico retrospectivo*

Leandro Calil De Lazari<sup>1</sup> Celso Herminio Ferraz Picado<sup>2</sup> Flavio Luis Garcia<sup>2</sup>   
Fernando Jorge Garcia<sup>3</sup>

<sup>1</sup> Orthopedics Residence Service, Grupo São Lucas, Hospital Care, Ribeirão Preto, SP, Brazil

<sup>2</sup> Hip Group, Hospital das Clínicas, Faculdade de Medicina de Ribeirão Preto, Universidade de São Paulo (FMRP – USP), Ribeirão Preto, SP, Brazil

<sup>3</sup> Hospital Estadual de Sumaré, Universidade de Campinas (Unicamp), Campinas, SP, Brazil,

Address for correspondence Leandro Calil De Lazari, PhD, Av Itatiaia 1049, Higienópolis, Ribeirão Preto, SP, 14025-070, Brazil  
(e-mail: calil.delazari@gmail.com; contato@leandrocalil.com.br).

Rev Bras Ortop 2022;57(1):144–149.

### Abstract

#### Keywords

- ▶ arthroplasty, replacement, hip
- ▶ arthroscopy
- ▶ microfracture
- ▶ femoroacetabular impingement

### Resumo

#### Palavras-chave

- ▶ artroplastia de quadril
- ▶ artroscopia
- ▶ microfratura
- ▶ impacto femoroacetabular

**Objective** The present study aims to evaluate the treatment of hip wave lesion using reverse microfracture, which is a simple and cheap surgical procedure.

**Methods** We retrospectively analyzed 19 patients with acetabular wave lesion treated with reverse microfracture. The patients were assessed by magnetic nuclear resonance imaging (MRI) at the time of diagnosis and 6 months after the surgery and functionally evaluated using the Harris Hip Score (HHS) and the visual analogue scale (VAS) for pain in the preoperative period, and 3 and 6 months after the surgery.

**Results** The statistical data showed a significant improvement in HHS and VAS 6 months after the surgery. Six months after the surgery, the MRI revealed that the area subjected to reverse microfracture presented cartilage with the same visual characteristics observed in areas with no chondral injury.

**Conclusion** We conclude that the reverse microfracture proved to be an effective, reproducible method for the treatment of wave lesion.

**Objetivo** Avaliar o tratamento desta lesão, através da microfratura reversa, que é um procedimento simples e sem aumento de insumos na cirurgia.

**Métodos** Foram analisados retrospectivamente 19 pacientes submetidos a tratamento da lesão em onda no acetábulo, através da microfratura reversa. Utilizamos a ressonância nuclear magnética (RNM) no momento do diagnóstico e 6 meses após a cirurgia, avaliação funcional pelo *Harris Hip Score* (HHS) e escala visual e analógica (EVA) da dor no pré-operatório, e 3 e 6 meses após a cirurgia.

Study developed at Grupo São Lucas, Hospital Care, Ribeirão Preto, São Paulo, Brazil.

received  
April 9, 2020  
accepted  
October 2, 2020  
published online  
April 19, 2021

DOI <https://doi.org/10.1055/s-0040-1722259>  
ISSN 0102-3616.

© 2021. Sociedade Brasileira de Ortopedia e Traumatologia. All rights reserved.

This is an open access article published by Thieme under the terms of the Creative Commons Attribution-NonDerivative-NonCommercial-License, permitting copying and reproduction so long as the original work is given appropriate credit. Contents may not be used for commercial purposes, or adapted, remixed, transformed or built upon. (<https://creativecommons.org/licenses/by-nc-nd/4.0/>)

Thieme Revinter Publicações Ltda., Rua do Matoso 170, Rio de Janeiro, RJ, CEP 20270-135, Brazil

**Resultado** Os dados estatísticos mostraram melhora significativa do HHS e EVA da dor após 6 meses da cirurgia. A RNM após 6 meses da cirurgia mostrou que na área que foi submetida à microfratura reversa, a cartilagem se apresentou com as mesmas características visuais que nas áreas sem lesão condral.

**Conclusão** Concluímos que a microfratura reversa se mostrou eficaz e reprodutível no tratamento da lesão em onda.

## Introduction

The wave lesion is a predeformation or deep delamination of the articular cartilage or chondrolabral complex with no intra-articular extension.<sup>1</sup> This type of injury is difficult to diagnose preoperatively, and it is often recognized during surgery.<sup>1</sup> As an articular cartilage injury, it can cause serious hip joint problems, including arthralgia, synovitis, and free bodies formation and/or result in osteoarthritis.<sup>2</sup> For surgeons, the challenge is the correct surgical indication associated with a clinical treatment for injury resolution.

A therapeutic option for wave lesions is the arthroscopic technique described as reverse microfracture.<sup>3</sup> This technique is performed with a proximal accessory anterolateral portal, which allows the adequate angulation and positioning to microfracture the acetabular bone sparing the chondrolabral cartilage, thus reducing the pressure of the bubbles formed by the wave lesion and inducing a clot that, associated with the bone healing reaction, can act as a natural adhesive to join the cartilage to the bone.<sup>3</sup>

The present study aimed to evaluate the clinical and radiological results in 19 patients with wave lesions treated using the reverse microfracture technique.

## Materials and Methods

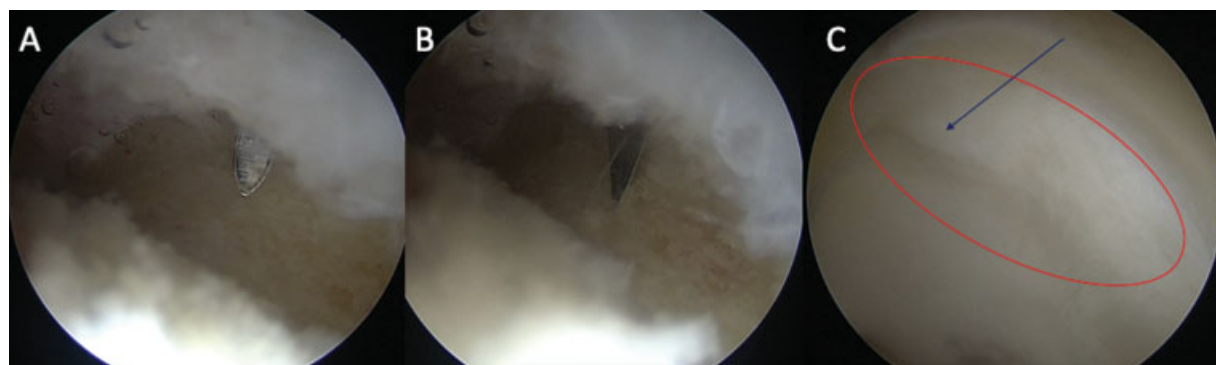
The current study was carried out after approval by the Ethics and Research Council of Hospitals São Lucas and Ribeirânia, Ribeirão Preto, São Paulo, Brazil. This research was developed as recommended by the Brazilian National Health Council (*Conselho Nacional de Saúde*), Resolution #466/12.

This was a retrospective, descriptive, quantitative study using data collected after analysis and review of medical records from patients with a wave lesion who were treated using the reverse microfracture technique from May 2016 to October 2017.

The arthroscopic technique described as reverse microfracture, which was used in this study, was performed with the patient in supine position on a traction table.<sup>3</sup> Aided by radioscscopy, the affected lower limb was pulled until a joint space of 2 centimeters was obtained. After surgical fields placement, the anterolateral and anterior portals were used to visualize the intra-articular compartment and diagnose the wave lesion at the acetabular cartilage. For lesion treatment, a proximal accessory anterolateral portal (ACP) was created with an angle of 30° to 45° proximal and anterior to the anterolateral portal and halfway between the anterosuperior iliac spine and a perpendicular line to the top of the greater trochanter.<sup>3</sup>

Using the ACP portal, the reverse microfracture technique was performed under direct visualization with a low rotation drill, making as many microfractures as required for treatment, at 3 to 4-mm intervals<sup>4</sup> (→ **Figure 1**).

Nineteen medical records from a total of 28 operated patients were selected and included in the study. The following data were evaluated: gender, age, laterality, date of surgery, type of femoroacetabular impingement (FAI), magnetic resonance imaging (MRI) findings at the time of diagnosis and 6 months after surgery, and functional assessment using the Harris Hip Score (HHS) and visual analog scale (VAS) for pain preoperatively, and 3 and 6 months after surgery. For the VAS, scores from 0 to 2 indicated mild pain, from 3 to 7, moderate pain, and from 8 to 9, severe pain (→ **Table 1**).



**Fig. 1** (A) Image showing the cannulated introducer and the desired position to place the 2.3-mm drill. (B) Image showing the drill, and the beginning of the drilling process. (C) Image of the wave lesion (red ellipse) and subchondral bone drilling sparing the cartilage (arrow).

**Table 1** Patient data.

	SURGERY DATE	GENDER	SIDE	FAI TYPE	PREOP HHS	PREOP VAS	HHS AT 3M	VAS AT 3M	HHS AT 6M	VAS AT 6M	MRI AT 6M
1	January 27, 2017	FEMALE	LEFT	MIXED	76	7	86	3	100	0	Cartilage similar to non-injured area and with signs of viability
2	September 02, 2016	MALE	RIGHT	CAM	56	8	70	5	81	3	Cartilage similar to non-injured area and with signs of viability
3	March 10, 2017	MALE	LEFT	CAM	74	7	85	3	95	0	Cartilage similar to non-injured area and with signs of viability
4	September 28, 2016	FEMALE	RIGHT	MIXED	70	7	85	4	91	1	Cartilage similar to non-injured area and with signs of viability
5	May 9, 2016	FEMALE	LEFT	MIXED	70	6	75	4	85	2	Cartilage similar to non-injured area and with signs of viability
6	April 8, 2017	MALE	RIGHT	MIXED	74	6	88	2	91	1	Cartilage similar to non-injured area and with signs of viability
7	June 23, 2017	FEMALE	RIGHT	CAM	81	4	90	1	100	0	Cartilage similar to non-injured area and with signs of viability
8	September 30, 2016	FEMALE	LEFT	CAM	56	9	70	4	79	1	Cartilage similar to non-injured area and with signs of viability
9	January 26, 2017	FEMALE	RIGHT	CAM	68	8	75	5	90	2	Cartilage similar to non-injured area and with signs of viability
10	October 05, 2016	FEMALE	RIGHT	MIXED	81	6	91	2	100	0	Cartilage similar to non-injured area and with signs of viability
11	October 05, 2017	FEMALE	RIGHT	MIXED	70	7	91	5	95	1	Cartilage similar to non-injured area and with signs of viability
12	April 19, 2017	FEMALE	RIGHT	MIXED	61	7	79	3	100	1	Cartilage similar to non-injured area and with signs of viability
13	September 10, 2016	FEMALE	LEFT	CAM	56	8	79	3	91	1	Cartilage similar to non-injured area and with signs of viability
14	September 29, 2017	FEMALE	LEFT	CAM	56	8	75	4	91	2	Cartilage similar to non-injured area and with signs of viability
15	August 02, 2017	MALE	RIGHT	CAM	86	7	91	1	100	0	Cartilage similar to non-injured area and with signs of viability
16	August 19, 2016	FEMALE	RIGHT	MIXED	70	7	85	3	91	1	Cartilage similar to non-injured area and with signs of viability
17	October 25, 2016	FEMALE	RIGHT	CAM	41	8	75	3	91	2	Cartilage similar to non-injured area and with signs of viability
18	November 14, 2016	FEMALE	LEFT	MIXED	56	8	75	4	79	3	Cyst at surgical site
19	July 25, 2016	FEMALE	LEFT	MIXED	81	5	91	1	100	0	Cartilage similar to non-injured area and with signs of viability

Abbreviations: FAI, femoroacetabular impingement; HHS, Harris hip score; M, months; MRI, magnetic resonance imaging; PREOP, preoperative; POSTOP, postoperative; VAS, visual analog scale.

Nine patients were excluded from the study due to lack of necessary documentation or loss at follow-up.

The inclusion criteria were mixed or cam-type FAI, wave lesion alone or associated with labral injury, assisted physical therapy,<sup>5</sup> and patients operated on by the same surgeon. The exclusion criteria were lack of HHS or MRI at the pre or postoperative period, cleavage-type chondral injury, subchondral bone delamination or exposure associated with wave lesion, acetabular dysplasia, incarcerated hip or excessive hip overcoverage, deep or protruding thigh, arthroscopy revision, hip instability, and joint hypermobility per the Beighton criteria.<sup>6</sup>

### Statistical Analysis

The data were evaluated using descriptive statistics for sample characterization.

A Fisher exact test verified any association between qualitative variables.<sup>7</sup>

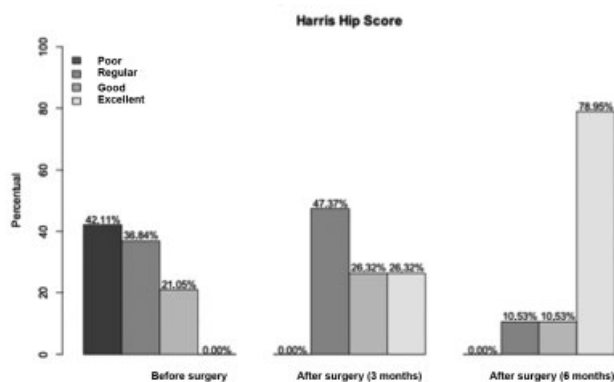
Student t-tests were used to compare two mean values from unpaired samples. This test aims to verify whether variances from both groups are statistically equal, and if the data follow a normal distribution.

All statistical analyses were performed using the SAS statistical software (SAS Institute Inc., Cary, NC, USA). P-values were considered significant when lower than 0.05.

For the statistical analysis, HHSs were considered poor if lower than 70 points, regular when ranging from 70 to 80 points, good when ranging from 80 to 90 points, and excellent if greater than 90 points.<sup>8</sup>

### Results

Nineteen patients were evaluated, including 15 (78.95%) females and four (21.05%) males. Eleven (57.89%) patients were operated on the right side, while 8 (42.11%) were operated on the left side.



**Fig. 2** Graph showing the improvement of preoperative and postoperative Harris Hip Scores.

Nine (47.37%) patients presented cam-type FAI, whereas the remaining 10 (52.63%) had mixed-type FAI. Three (75%) men and 6 (40%) women had cam-type FAI. No patient presented exclusive pincer-type FAI.

Only one patient (5.26%) had a postoperative complication, a cyst formed in the region of the microfracture.

At the temporal statistical evaluation, preoperatively, HHS was poor in 42.11% of the patients, regular in 36.84%, and good in 21.05% of the patients. Three months after surgery, 47.37% of the patients had regular scores, 26.32% had good scores, and 26.32%, excellent scores. Six months after surgery, 10.53% of the patients had regular scores, 10.53%, good, and 78.95%, excellent scores ( $p < 0.05$ ) (► **Tables 2** and **3** and ► **Figure 2**).

Regarding the temporal evaluation of VAS score for pain, 63.16% of the patients had moderate pain and 36.84% presented severe pain during the preoperative period. Three months after surgery, 26.32% had mild pain and 73.68% presented moderate pain, and 6 months after surgery, 89.47% had mild pain and 10.53%, moderate pain ( $p < 0.05$ ). Data showed a significant improvement in pain according to VAS 3 and 6 months after surgery (► **Table 4** and ► **Figure 3**).

**Table 2** Mean Harris hip score before surgery (T0), and at 3 months (T3) and 6 months (T6) after surgery

HHS X Time						
Time	N	Mean value	Standard deviation	Minimum value	Median	Maximum value
T0	19	67.53	11.73	41.00	70.00	86.00
T3	19	81.89	7.52	70.00	85.00	91.00
T6	19	92.11	7.15	79.00	91.00	100.00

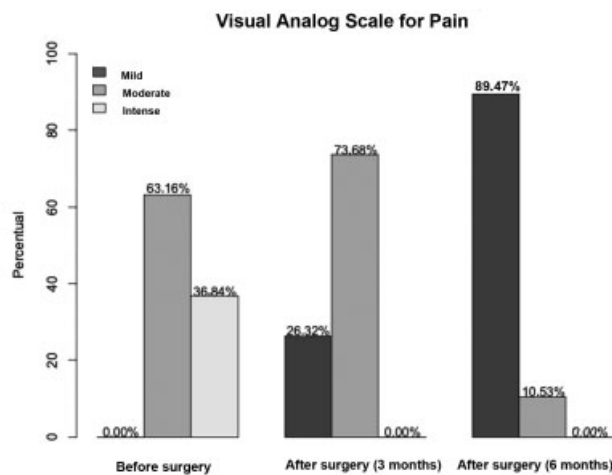
**Table 3** Significant difference in Harris hip scores before surgery (T0), and at 3 months (T3) and 6 months (T6) after surgery, using a p-value of 5%

Mean HHS X Time				
Comparison	Estimated value	p-value*	95% confidence interval	
(T0–T3)	–14.3684211	< 0.0001	–20.2495574	–8.4872847
(T0–T6)	–24.5789474	< 0.0001	–30.4600837	–18.6978111
(T3–T6)	–10.2105263	0.0010	–16.0916626	–4.3293900

**Table 4** Visual analog scale (VAS) for pain scores analyzed using the Fisher method and with a *p*-value of 5%.

Time X VAS				
Time	VAS*			Total
	1	2	3	
T0	0 0.00	12 61.16	7 36.84	19 100.00
T3	5 26.32	14 73.68	0 0.00	19 100.00
T6	17 89.47	2 10.53	0 0.00	19 10.00
<b>Total</b>	22	28	7	57

\*VAS 1 represents mild pain, whereas VAS 2 indicates moderate, and VAS 3, severe pain.



**Fig. 3** Graph illustrating the staggered decrease in pain according to the visual analog scale (VAS) before surgery and 3 and 6 months after the procedure.

Magnetic resonance imaging scans were performed 6 months after surgery in all patients, revealing that the treated cartilage had signal intensity similar to the adjacent normal cartilage in 18 subjects (► **Figure 4**). One patient developed a cyst in the area of the microfracture (► **Table 1**).

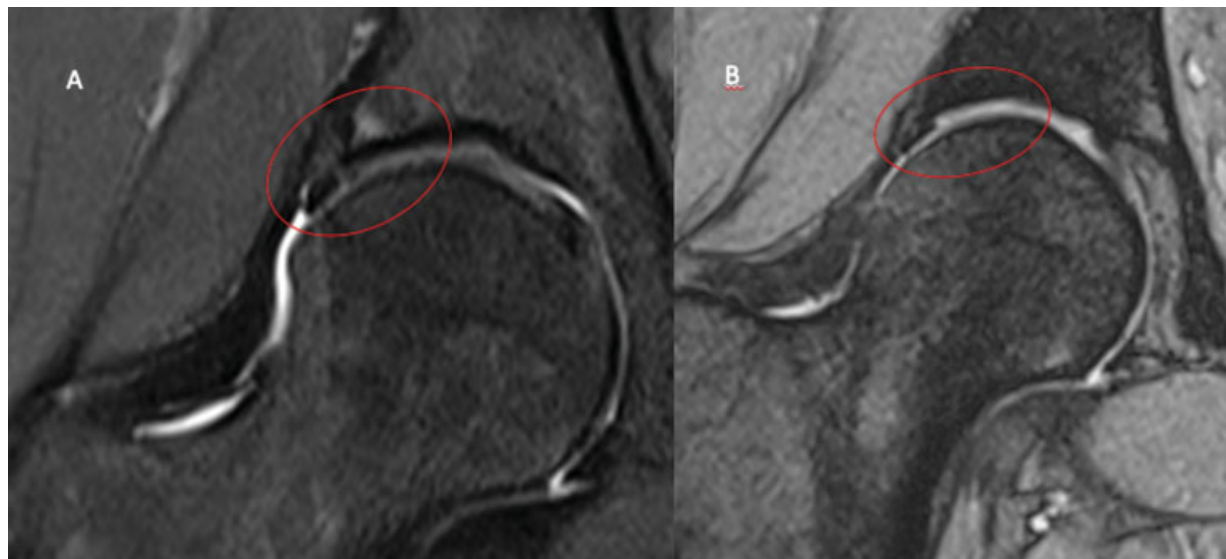
## Discussion

Microfracture,<sup>4,9</sup> direct repair,<sup>4,10</sup> repair with fibrin adhesives,<sup>11,12</sup> autologous chondrocyte transplantation (ACT),<sup>13</sup> autologous membrane induced chondrogenesis (AMIC),<sup>14</sup> mosaicplasty,<sup>15</sup> osteochondral allograft transplantation,<sup>2</sup> and matrix stem-cells implantation<sup>2</sup> are successful techniques in some specific injuries but not in others.

The present study reports outcomes from an arthroscopic procedure indicated for acetabular cartilage wave lesions. As this is a new procedure, the literature has scarce data for comparisons.<sup>12</sup>

Most (52.63%) patients had mixed-type injuries, and, among male subjects, three (75%) patients had cam-type lesions. These findings are consistent with the current literature,<sup>1</sup> which demonstrates the mixed type as the most common FAI and reports that isolated cam injuries are the most frequent in men.<sup>1</sup>

The improvement in the HHS and VAS for pain is consistent with the literature, showing a progressive symptom reduction when comparing scores from the preoperative period to 3 and 6 months after surgery. Preoperative MRI revealed a darkest injured chondral region, with reduced signal in the DP FAT SAT- and GRET2 echo gradient-weighted sequences compared to the healthy acetabular cartilage. Six months after the reverse microfracture, the MRI showed that the treated cartilage had the same signal as the adjacent, uninjured cartilage in 18 patients, potentially suggesting that the cartilage is healthy and adhered to the subchondral bone, corroborating the clinical and functional improvement.



**Fig. 4** (A) Highlighted preoperative image corresponding to wave lesion showing the altered cartilage at the chondrolabral junction. (B) Six months after surgery, a highlighted image shows that the cartilage submitted to microfracture presents the same signal and features from non-injured areas.

The only complication observed in this study was a cystic formation at the microfracture region in one subject. We have not found other studies in the current literature demonstrating the occurrence of this same complication. We believe that this cyst resulted from synovial fluid entering the microfracture's orifices.

The ideal method for confirming procedural success would be a new arthroscopy for lesion site biopsy. However, since this is an additional invasive procedure, ethical aspects prevented its performance.

## Conclusion

The treatment of a wave lesion using reverse microfracture proved to be effective and safe during a 6-month follow-up, with significant improvement in the HHS and VAS for pain, and imaging findings similar to the adjacent healthy cartilage in MRI scans. Additional studies with a larger sample and longer follow-up periods are required to define the clinical impact of this new technique.

### Financial Support

There was no financial support from public, commercial, or not-for-profit sources.

### Conflict of Interests

The authors declare that they have no conflict of interests.

## References

- 1 Wulf CA, Larson CM. Chondral Lesion. In: Byrd JW, Guanche C. AANA Advanced Arthroscopy: The Hip. Philadelphia: Elsevier; 2010:33–50
- 2 Chahla J, LaPrade RF, Mardones R, et al. Biological Therapies for Cartilage Lesions in the Hip: A New Horizon. *Orthopedics* 2016;39(04):e715–e723
- 3 De Lazari LC, Laguna CB, Picado CHF, Garcia FL. Reverse Microfracture of the Hip Acetabulum: A Technique for the Wave Lesion. *Arthrosc Tech* 2018;7(06):e607–e610
- 4 Haughom BD, Erickson BJ, Rybalko D, Hellman M, Nho SJ. Arthroscopic Acetabular Microfracture With the Use of Flexible Drills: A Technique Guide. *Arthrosc Tech* 2014;3(04):e459–e463
- 5 Byrd JW. *Operative Hip Arthroscopy*. 3rd ed. New York: Springer; 2013
- 6 Stone AV, Mehta N, Beck EC, et al. Comparable patient-reported outcomes in females with or without joint hypermobility after hip arthroscopy and capsular plication for femoroacetabular impingement syndrome. *J Hip Preserv Surg* 2019;6(01):33–40
- 7 Fisher RA. The logic of inductive inference. *J R Stat Soc* 1935;98(01):39–82
- 8 Guimarães RP, Alves DP, Azuaga TL, et al. Tradução e adaptação transcultural do “Harris Hip Score modificado por Byrd”. *Acta Ortop Bras* 2010;18(06):339–342
- 9 Philippon MJ, Schenker ML, Briggs KK, Maxwell RB. Can microfracture produce repair tissue in acetabular chondral defects? *Arthroscopy* 2008;24(01):46–50
- 10 Trask DJ, Keene JS. Analysis of the Current Indications for Microfracture of Chondral Lesions in the Hip Joint. *Am J Sports Med* 2016;44(12):3070–3076
- 11 MacDonald AE, Bedi A, Horner NS, et al. Indications and Outcomes for Microfracture as an Adjunct to Hip Arthroscopy for Treatment of Chondral Defects in Patients With Femoroacetabular Impingement: A Systematic Review. *Arthroscopy* 2016;32(01):190–200.e2
- 12 Tzaveas AP, Villar RN. Arthroscopic repair of acetabular chondral delamination with fibrin adhesive. *Hip Int* 2010;20(01):115–119
- 13 Marquez-Lara A, Mannava S, Howse EA, Stone AV, Stubbs AJ. Arthroscopic Management of Hip Chondral Defects: A Systematic Review of the Literature. *Arthroscopy* 2016;32(07):1435–1443
- 14 Fontana A. Autologous Membrane Induced Chondrogenesis (AMIC) for the treatment of acetabular chondral defect. *Muscles Ligaments Tendons J* 2016;6(03):367–371
- 15 Kılıçoğlu Öİ, Polat G, Erşen A, Birişik F. Long-term result of mosaicplasty for femoral head osteochondral lesion: a case report with 8 years follow-up. *Hip Int* 2015;25(06):589–592