



Isolated distal pisiform dislocation: Case Report*

Luxação distal isolada do pisiforme: Relato de caso

Rafael Dias¹ Teresa Alves-da-Silva¹ Carlos Martinho¹ Francisco Guerra-Pinto¹

¹ Surgical Specialties Department, Orthopedics Functional Unit, Hospital de Cascais – Dr. José de Almeida, Alcabideche, Portugal

Address for correspondence Rafael Dias, MD, Avenida Brigadeiro Novais, 2755-099, Alcabideche, Portugal (e-mail: rafaelrmdias@gmail.com).

Rev Bras Ortop 2022;57(2):341–344.

Abstract

Isolated pisiform dislocation is a rare lesion with few cases described in the literature. This type of lesion is typically observed in young males and can be easily overlooked at first assessment. Isolated proximal dislocation is more common due to the action of the flexor carpi ulnaris (FCU) muscle.

We present the case of a 19-year-old male patient with isolated distal pisiform dislocation after wrist trauma. He underwent open reduction and internal fixation with Kirschner wires with excellent functional outcomes.

Although there is no consensual therapeutic method, closed reduction is a first-line treatment for acute presentations. Pisiform open reduction or excision may be performed alternatively or after a failed closed reduction.

Keywords

- ▶ wrist injuries
- ▶ carpal bones
- ▶ joint dislocations
- ▶ pisiform

Resumo

A luxação isolada do pisiforme é uma lesão rara com poucos casos descritos na literatura. Esse tipo de lesão é observado tipicamente em adultos jovens do sexo masculino e pode ser facilmente negligenciada numa primeira avaliação. A luxação proximal isolada é mais comum devido à ação do flexor ulnar do carpo (FUC).

Apresentamos o caso de um paciente do sexo masculino, com 19 anos de idade, com luxação distal isolada do pisiforme após traumatismo do punho. O paciente foi submetido a uma redução aberta e fixação interna com fios de Kirschner com excelente resultado funcional.

Apesar de não existir um método de tratamento consensual, a redução fechada perfila-se como tratamento de primeira linha na apresentação aguda. Em caso de insucesso ou como método alternativo pode-se optar pela redução aberta ou a excisão do pisiforme.

Palavras-chave

- ▶ traumatismos do punho
- ▶ ossos do carpo
- ▶ luxações articulares
- ▶ pisiforme

* Study developed at Surgical Specialties Department, Orthopedics Functional Unit, Hospital de Cascais – Dr. José de Almeida, Alcabideche, Portugal.

received
June 6, 2020
accepted
September 17, 2020
published online
March 31, 2021

DOI <https://doi.org/10.1055/s-0040-1722589>.
ISSN 0102-3616.

© 2021. Sociedade Brasileira de Ortopedia e Traumatologia. All rights reserved.
This is an open access article published by Thieme under the terms of the Creative Commons Attribution-NonDerivative-NonCommercial-License, permitting copying and reproduction so long as the original work is given appropriate credit. Contents may not be used for commercial purposes, or adapted, remixed, transformed or built upon. (<https://creativecommons.org/licenses/by-nc-nd/4.0/>)
Thieme Revinter Publicações Ltda., Rua do Matoso 170, Rio de Janeiro, RJ, CEP 20270-135, Brazil

Introduction

Pisiform dislocation is a rare condition with less than 30 documented cases.¹⁻⁷ Its location within the tendon of the flexor carpi ulnaris (FCU) muscle accounts for its intrinsic stability, making dislocation unlikely, especially with no other associated injuries. With few cases described in the literature, the ideal therapeutic approach is still unclear.

Clinical Case

We present the case of a 19-year-old male patient with trauma to the volar face of the left wrist after lifting a heavy object (furniture). The continuous compression inflicted by the weight of the object on the extended wrist resulted in sudden onset of pain and slight functional wrist disability. Upon admission to the emergency department, the patient presented pain and swelling on the left ulnar edge of the wrist and hand. He reported slight limitation of wrist flexion and showed no signs of neurological impairment.

The radiography revealed a distal pisiform dislocation at the level of the hook of hamate (► **Figure 1**). A computed tomography scan did not show any other concomitant injuries (► **Figure 2**). A closed reduction attempt was unsuccessful. Thus, the patient had his wrist immobilized with a posterior plaster cast from the forearm to the palm of the hand and was referred to surgical intervention.

An open reduction of the pisiform was performed, followed by fixation to the triquetral bone with two Kirschner wires under radioscopic control (► **Figure 3**). The joint capsule was disrupted but the FCU remained intact. The patient's

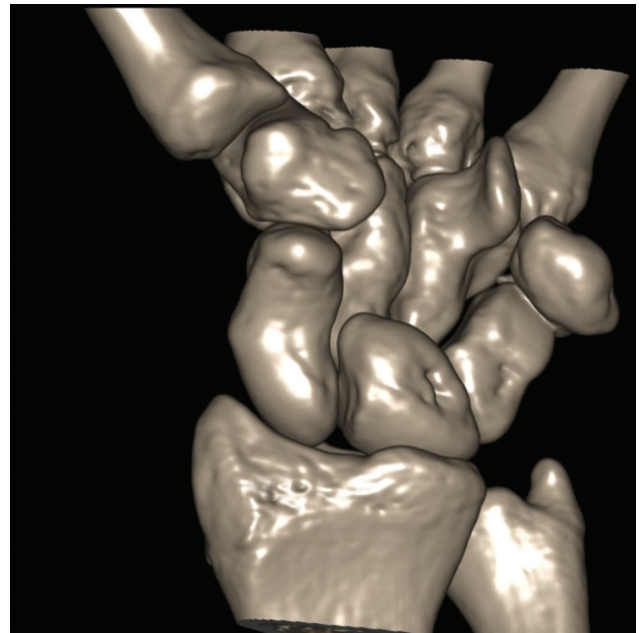


Fig. 2 Computed tomography scan (with three-dimensional reconstruction) showing pisiform dislocation and no other concomitant lesions.

wrist was immobilized with a posterior plaster cast from the forearm to the palm of the hand in flexion and ulnar deviation.

Five weeks after the surgery, the Kirschner wires and the plaster cast were removed, and motor rehabilitation

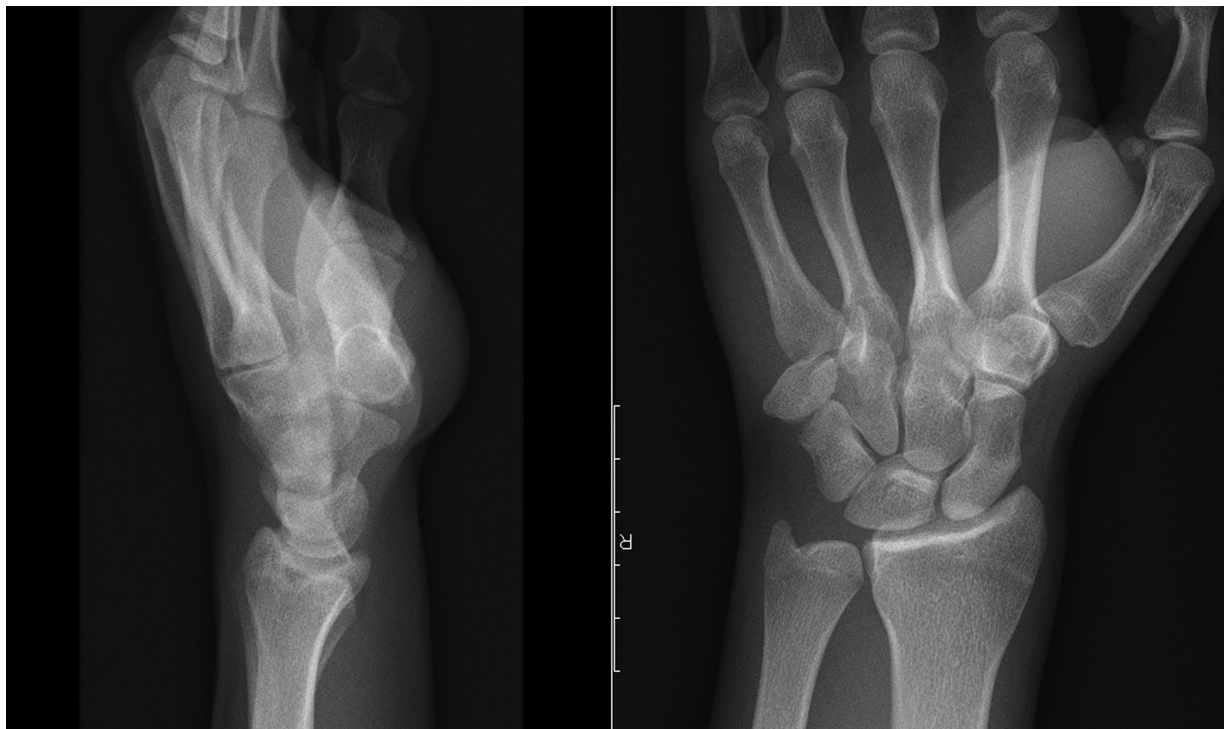


Fig. 1 Initial radiograph demonstrating a distal pisiform dislocation.

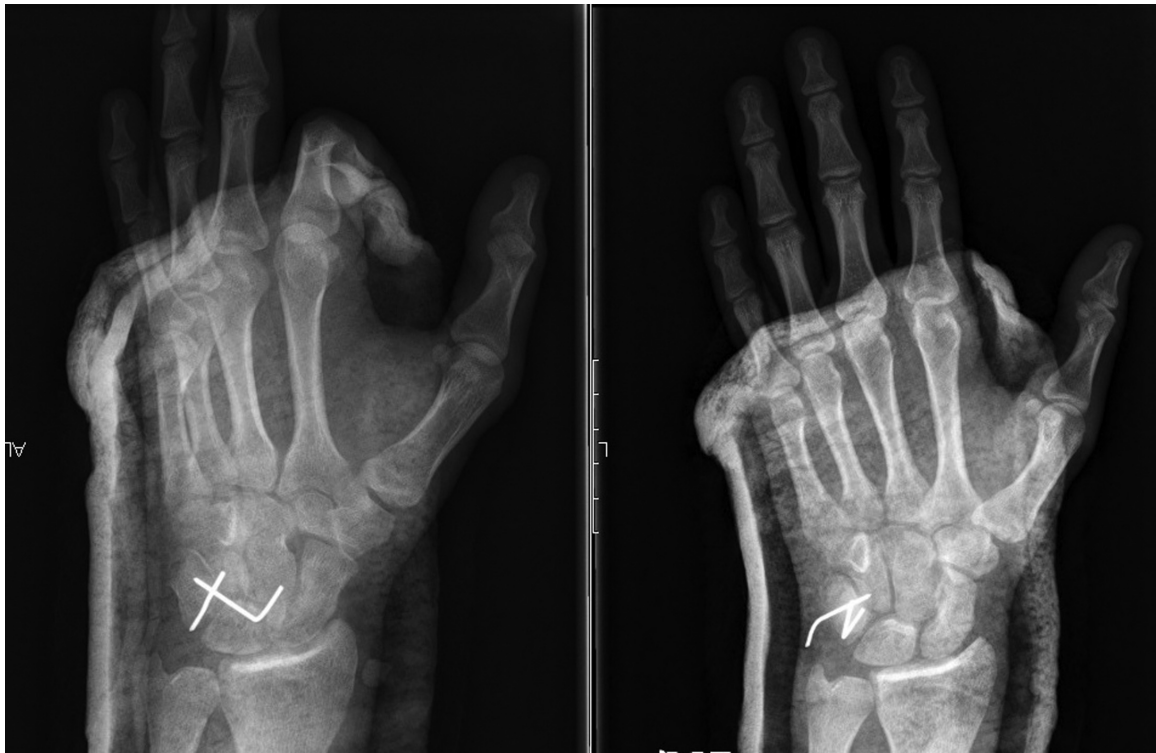

Fig. 3 Immediate postoperative radiograph demonstrating the anatomical reduction of the pisiform and its fixation to the triquetrum bone with Kirschner wires.

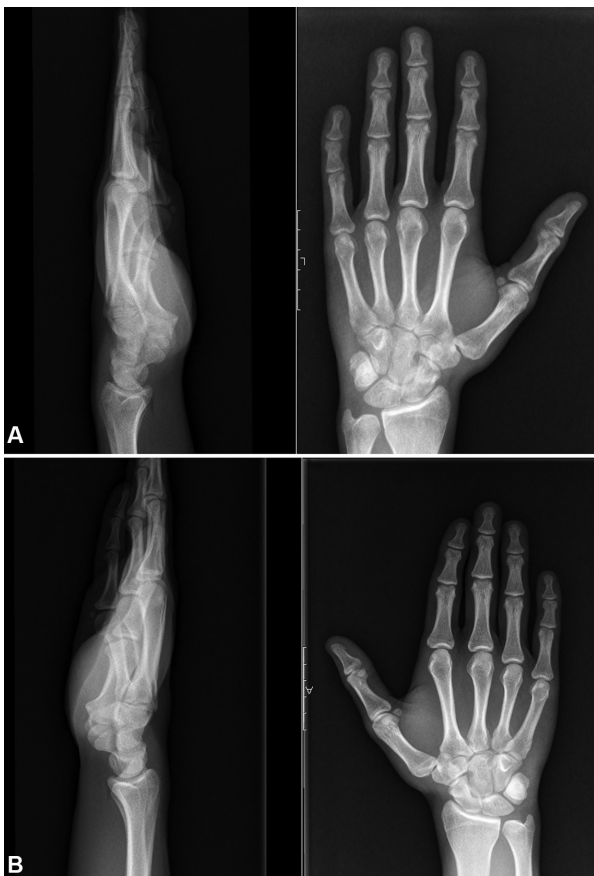

Fig. 4 (A) Radiograph of the left wrist at 12 weeks postoperatively, revealing the sustained pisiform reduction; (B) Radiograph of the right wrist.

was started. At 12 weeks postoperatively, a follow-up radiography showed the pisiform in its native position (→ **Figure 4**). At 12 months postoperatively, the patient recovered the wrist's complete range of motion, presenting symmetrical muscle strength and no residual pain (→ **Figure 5**). In addition, the Disability of Arm Shoulder and Hand (DASH) and the Patient-Rated Wrist Evaluation (PRWE) scores were equal to 0.

Discussion

Isolated pisiform dislocation is an extremely rare lesion, with a small number of cases described in the literature. This type of injury is easily overlooked, especially when concomitant lesions are present. Thus, a high degree of suspicion is required to identify it in patients with upper limb trauma.

Located on the ulnar edge of the proximal carpal row, the pisiform bone articulates with the triquetrum bone through its dorsal face. Due to its flat joint facet, the pisiform depends on the surrounding soft tissues to sustain its stability, such as the pisohamate and pisometacarpal ligaments, FCU tendons, and abductor digiti minimi muscle. The pisiform acts as a sesamoid bone, working as a lever to increase the flexion force of the wrist produced by the FCU.^{1,8,9}

Two mechanisms are proposed to explain pisiform dislocation: direct external trauma or excessive traction force exerted by the FCU.²⁻⁴ This last mechanism seems to be the most frequent, either due to a fall with trauma of the wrist in extension, or a sudden, violent FCU muscle contraction.

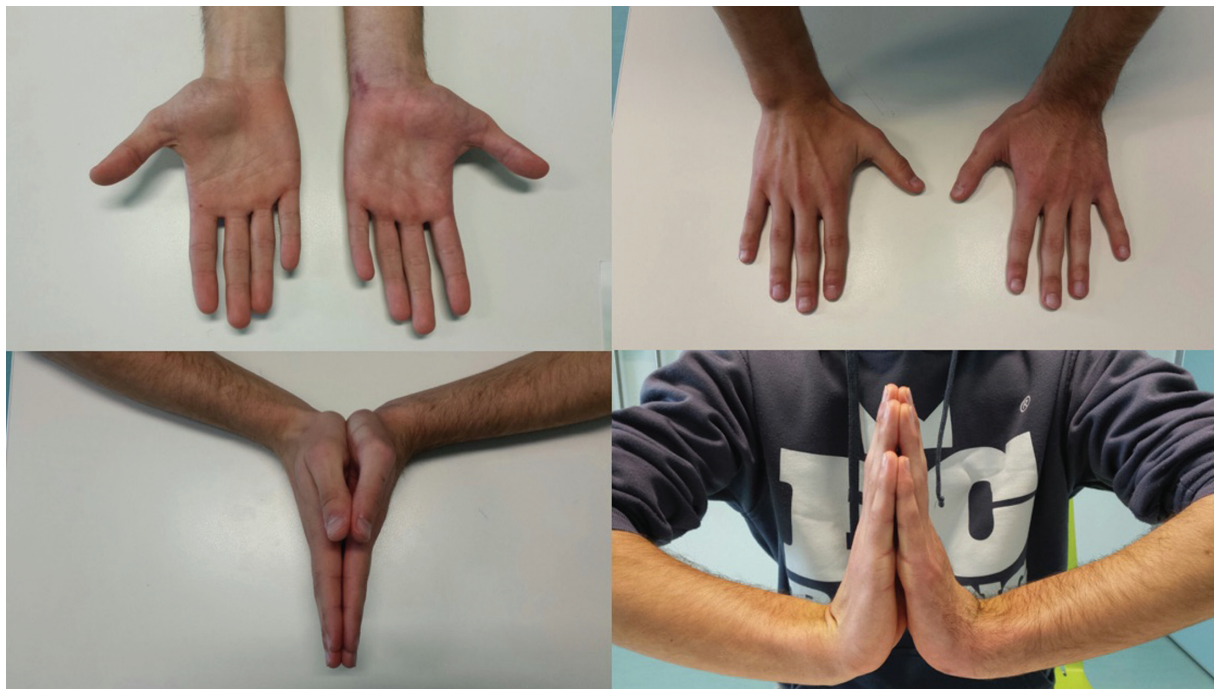

Fig. 5 Photograph of the patient demonstrating a symmetrical range of motion.

The FCU, as the main wrist flexor muscle, tends to displace the pisiform proximally. Thus, pisiform proximal dislocation is the most frequent type observed, due to the overlap of forces from the FCU and other stabilizing structures.⁵

In our case, the specific traumatic mechanism may explain the pathophysiology of the pisiform dislocation in a distal direction. We hypothesized that the progressive tangential force exerted by the heavy object on the wrist resulted in the distal migration of the pisiform due to capsular disruption and FCU tendon stretching. The hook of the hamate can act as a blocking factor to reduce the pisiform to its anatomical position. The force exerted by the abductor digiti minimi muscle may represent another factor for pisiform migration to the distal carpal row.

The preferred treatment is still unclear, but an attempted closed reduction in acute trauma may be the first therapeutic option. If the closed reduction is unsuccessful, open reduction and internal fixation or excision of the pisiform must be performed. In cases of non-immediate treatment or diagnostic delay, anatomical reduction may become difficult, and pisiform excision results in more predictable outcomes.^{3,6}

In our case, we opted for open reduction and pisiform fixation in its anatomical position due to the potential full recovery of FCU function. The immobilization in flexion and ulnar deviation reduces tension over the FCU, enhancing the healing of this and the remaining juxta-articular structures.⁸ We believe that this technique is a reliable method with good functional outcomes in isolated pisiform dislocation.

Conflict of Interests

The authors declare that there is no conflict of interest. The study was performed in compliance with the World Medical Association Declaration of Helsinki on Ethical Principles for Medical Research Involving Human Subjects.

References

- 1 Kwon OS, Choi SP, Won HY. Acute isolated pisiform dislocation: A case report. *J Korean Orthop Assoc* 2007;42(05):688–691
- 2 Minami M, Yamazaki J, Ishii S. Isolated dislocation of the pisiform: a case report and review of the literature. *J Hand Surg Am* 1984;9A(01):125–127
- 3 Schädel-Höpfner M, Junge A, Böhringer G. [Dislocation of the pisiform bone. A review of the literature]. *Handchir Mikrochir Plast Chir* 2002;34(03):168–172
- 4 Sharara KH, Farrar M. Isolated dislocation of the pisiform bone. *J Hand Surg Br* 1993;18(02):195–196
- 5 Campbell E, Magi E. A dislocated pisiform: Case report. *Can J Plast Surg* 1999;7(02):57–58
- 6 Goriainov V, Bayne G, Warwick DJ. Traumatic dislocation of the pisiform: a case report. *J Orthop Surg (Hong Kong)* 2010;18(03):389–390
- 7 Kubiak R, Slongo T, Tschäppeler H. Isolated dislocation of the pisiform: an unusual injury during a cartwheel maneuver. *J Trauma* 2001;51(04):788–789
- 8 Pevny T, Rayan GM, Egle D. Ligamentous and tendinous support of the pisiform, anatomic and biomechanical study. *J Hand Surg Am* 1995;20(02):299–304
- 9 Moojen TM, Snel JG, Ritt MJ, Venema HW, den Heeten GJ, Bos KE. Pisiform kinematics in vivo. *J Hand Surg Am* 2001;26(05):901–907