



Spontaneous Perinephric Urinoma Secondary to Drug Induced Acute Interstitial Nephritis: A Case Report

Rajesh Kumar Varatharajaperumal¹ Rupa Renganathan¹ Mangalakumar V² Sriman Rajasekaran¹
Venkatesh Kasi Arunachalam¹

¹Department of Radiology, Kovai Medical Center and Hospital, Coimbatore, India

²Department of Nephrology, Kovai Medical Center and Hospital, Coimbatore, India

Address for correspondence Venkatesh Kasi Arunachalam, DMRD, DNB, FRCR, Senior Consultant Radiologist, Department of Radiology, Kovai Medical Center and Hospital, Coimbatore, India (e-mail: drkasivenkatesh@yahoo.co.in).

J Gastrointestinal Abdominal Radiol ISGAR 2021;4:240–242.

Abstract

Keywords

- ▶ spontaneous urinoma
- ▶ NSAID-induced Nephritis
- ▶ acute kidney injury
- ▶ acute interstitial nephritis

Urinoma is defined as the extravasation of urine from any part of the urinary collecting system, which causes lipolysis of the surrounding fat, resulting in an encapsulated collection. The most common cause of urinoma is the direct obstruction of the urinary system. The other etiologies include trauma and postinstrumentation/surgery. Parenchymal cause for spontaneous urinoma is exceedingly rare. We present a case of a 30-year-old gentleman who presented with lower abdominal pain and was treated with a Diclofenac injection. The pain got better temporarily, but he presented again with right loin pain after 3 days. His computed tomography scan images revealed bilateral perinephric urinoma. As there was significant deterioration of renal function, he underwent a renal biopsy. The histopathology was reported as acute interstitial nephritis (AIN). Drug-induced AIN is very rarely presented with acute loin or abdominal pain due to spontaneous perinephric urinoma, as it was seen in our case.

Introduction

Urine leaked from the urinary tract into the retroperitoneum causes lipolysis of the surrounding fat and results in the encapsulated collection which is known as urinoma.¹ Although direct obstruction and injury to the urinary tract (trauma/postinstrumentation) are the main causes of urinoma formation, it can also occur very rarely secondary to renal parenchymal pathologies. Few cases of spontaneous perinephric urinoma secondary to nephrotic syndrome were reported in the literature.^{2–4} Only one case of spontaneous perirenal urinoma secondary to nonsteroidal anti-inflammatory drug (NSAID)-induced acute interstitial nephritis (AIN) was reported in the previous literature.¹

Case History

A 30-year-old gentleman presented with lower abdominal pain to a general practitioner and was treated with a Diclofenac injection after which the pain subsided. After 3 days, he presented to our hospital with right iliac fossa and loin pain. The patient underwent a noncontrast computed tomography (CT) scan of the abdomen, which showed bilaterally enlarged kidneys with a thin rim of perinephric fluid on both sides (▶ **Fig. 1**). Contrast-enhanced CT was advised to rule out underlying pyelonephritis. On the day of admission, his blood investigation revealed elevated serum creatinine (1.7 mg/dl) and decreased estimated glomerular filtration rate (eGFR) (47 mL/min / 1.73 m²). Complete blood

published online
March 25, 2021

DOI <https://doi.org/10.1055/s-0041-1723924>
ISSN 2581-9933.

© 2021. Indian Society of Gastrointestinal and Abdominal Radiology. This is an open access article published by Thieme under the terms of the Creative Commons Attribution-NonDerivative-NonCommercial-License, permitting copying and reproduction so long as the original work is given appropriate credit. Contents may not be used for commercial purposes, or adapted, remixed, transformed or built upon. (<https://creativecommons.org/licenses/by-nc-nd/4.0/>). Thieme Medical and Scientific Publishers Pvt. Ltd. A-12, 2nd Floor, Sector 2, Noida-201301 UP, India

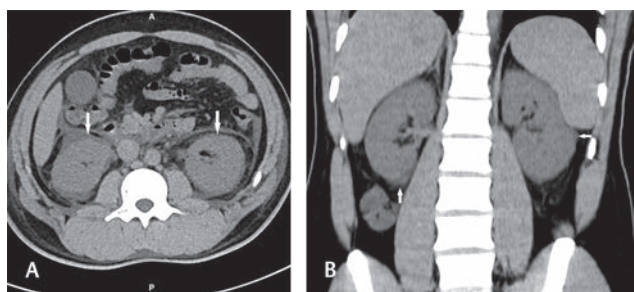


Fig. 1 Axial (A) and coronal (B) noncontrast computed tomography abdomen images show bilateral enlarged kidneys with thin rim of perinephric fluid (white arrows) on both sides.

count (CBC) was within normal limits. Urine microscopic and macroscopic analysis was within normal limits. The repeat blood investigation on the night of admission showed further deterioration of renal function (serum creatinine–2.0 mg/dl, eGFR–41 mL/min / 1.73 m²). Considering the results of urine and blood analysis, the possibility of drug-induced renal parenchymal injury was considered as one of the diagnosis. However, since the patient presented with repeated episodes of abdominal pain, contrast-enhanced CT was performed to rule out other causes of pain including bowel ischemia. The contrast-enhanced CT was performed using 50 mL of iodixanol (nonionic dimer) contrast agent. CT images showed diffuse poor enhancement of the kidneys in both arterial and venous phases consistent with acute kidney injury (AKI) (► **Fig. 2**). CT scan done after 2 hours showed the presence of contrast within the collection (► **Fig. 3**). There was no definite breach in the urinary tract seen on both sides on 2 hours of delayed images. The patient also went through renal biopsy on the same day. The renal biopsy samples were evaluated with both light and immunofluorescence microscopy. The histopathology report revealed acute tubular injury with focal and occasional neutrophil and eosinophil in the cortical interstitium, consistent with AIN. The cortical glomeruli, basement membrane, and arterioles were unremarkable. No organism was grown in blood and urine culture. The AKI was ultimately diagnosed secondary to diclofenac-induced AIN. The patient was managed with methyl prednisolone and underwent bilateral double J (DJ) stenting. The patient's renal function was stabilized and discharged.

Discussion

Urinoma in the perinephric location is most often due to rupture of the pelvicalyceal system/ureter, secondary to distal obstruction or a direct injury. The collection of urine secondary to renal parenchymal disease in the perirenal region is very rarely reported. Among the parenchymal disease, most of the reported cases were secondary to nephrotic syndrome. To date, only a few cases of spontaneous perinephric urinoma secondary to drug-induced acute interstitial nephritis were reported in the literature.¹ In our case of perinephric urinoma, AIN was secondary to Diclofenac injection.

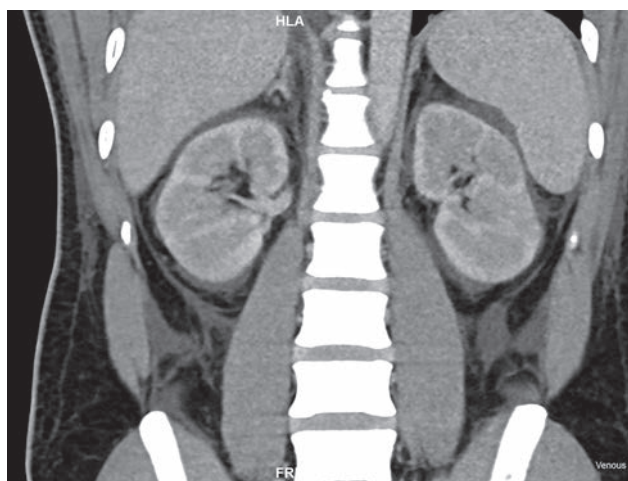

Fig. 2 Coronal postcontrast abdomen image in venous phase shows areas of poor enhancement in both kidneys.

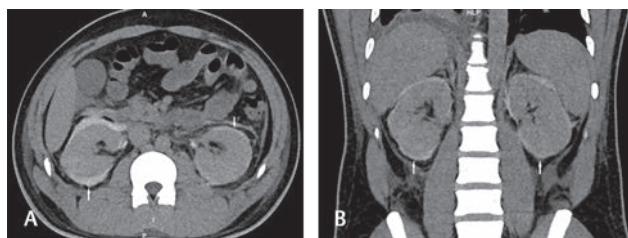


Fig. 3 Axial (A) and coronal (B) images of computed tomography abdomen in excretory phase show the presence of contrast within the perinephric fluid (white arrows) on both sides.

The NSAIDs cause injury to kidneys in two mechanisms. The first mechanism is by a decrease in prostaglandins, which results in reduced renal plasma flow and acute deterioration of renal function. The other mechanism of AKI is by an immunological reaction to NSAID and inflammatory cell infiltration of the interstitium of the kidney, which results in AIN.⁵ The second mechanism explained above is a nondose-dependent unpredictable idiosyncratic reaction.⁶

The perinephric spaces include subcapsular, perirenal, anterior, and posterior pararenal spaces. In patients with nephropathy, spontaneous subcapsular transudate occurs and results in fluid accumulation.⁷ The accumulated fluid causes distension of the renal capsule and Gerota's fascia and may present with loin pain. The perirenal fluid can be unilateral/bilateral and is diagnosed with USG/CT. They are graded on ultrasound as follows: grade 1, a thin layer of perirenal fluid; grade 2, a moderate amount of collected perirenal fluid with indentations of the renal parenchyma and strands in the fluid; and grade 3, a large fluid collection surrounding the kidney.⁷

The exact cause for spontaneous urinoma associated with AIN is not clearly discussed anywhere. The possible hypothesis is poor lymphatic drainage associated with analgesic use, which may lead to a decrease in clearance

of interstitial edema and results in the perirenal fluid.⁸ Similarly case studies in previous literature also demonstrated the coexisting lymphangiectasis in patients with nephrotic syndrome and perirenal fluid.² Urinoma secondary to renal parenchymal disease is mostly bilateral. In all reported cases as well as in our case too, urinoma was appreciated on both sides.

Small perinephric urinoma will be reabsorbed spontaneously, and these patients are managed conservatively most of the time. Urinoma is also managed with percutaneous nephrostomy, ureteric stenting, or percutaneous drainage, depending upon size and cause of urinoma.⁹ In our case, CT images show a thin rim of perirenal fluid with the extension of fluid into the paracolic gutter. The patient was managed with methyl prednisolone and bilateral DJ stent. The renal functions were stabilized, and he was discharged.

In conclusion, if a patient presents with flank or abdominal pain following NSAID intake, spontaneous perinephric urinoma secondary to drug-induced AIN should also be considered as one of the differential diagnoses.

Conflict of Interest

None declared.

References

- 1 Chang HW, Kuei CH, Tseng CF, Hou YC, Tseng YL. Spontaneous perirenal urinoma induced by NSAID-associated acute interstitial nephritis. *Ther Clin Risk Manag* 2018;14:595–599
- 2 Wani NA, Mir F, Gojwari T, Qureshi UA, Ahmad R. Subcapsular fluid collection: an unusual manifestation of nephrotic syndrome. *Am J Kidney Dis* 2010;56(1):181–184
- 3 Yalcin AU, Akcar N, Can C, Kasapoglu E, Sahin G. An unusual presentation for nephrotic syndrome. Bilateral perirenal subcapsular fluid collection. *Nephron* 2002;92(1):244–245
- 4 Yilmaz S, Zor M, Ersan M, Hamcan S. Bilateral massive perirenal subcapsular effusion: A case report. *J Clin Ultrasound* 2017;45(9):597–599
- 5 Dixit M, Doan T, Kirschner R, Dixit N. Significant acute kidney injury due to non-steroidal anti-inflammatory drugs: inpatient setting. *Pharmaceuticals (Basel)* 2010;3(4):1279–1285
- 6 Naughton CA. Drug-induced nephrotoxicity. *Am Fam Physician* 2008;78(6):743–750
- 7 Haddad MC, Medawar WA, Hawary MM, Khoury NJ, Ammouri NF, Shabb NS. Perirenal fluid in renal parenchymal medical disease ('floating kidney'): clinical significance and sonographic grading. *Clin Radiol* 2001;56(12):979–983
- 8 Seeger H, Bonani M, Segerer S. The role of lymphatics in renal inflammation. *Nephrol Dial Transplant* 2012;27(7):2634–2641
- 9 Lang EK, Glorioso L, III. Management of urinomas by percutaneous drainage procedures. *Radiol Clin North Am* 1986;24(4):551–559