



# Use of a Customized Three-dimensional Guide in Preparing the Pilot Pedicle Hole in Spinal Deformities

## *Uso de guia tridimensional personalizado no preparo do orifício do pedículo piloto em deformidades da coluna vertebral*

Kelsen de Oliveira Teixeira<sup>1</sup> Thiago Dantas Matos<sup>1</sup> Rodrigo Barra Caiado Fleury<sup>1</sup>   
Herton Rodrigo Tavares Costa<sup>2</sup> Helton Luiz Aparecido Defino<sup>3</sup>

<sup>1</sup> Postgraduate Program, Faculdade de Medicina de Ribeirão Preto, Universidade de São Paulo, Ribeirão Preto, SP, Brazil

<sup>2</sup> Hospital das Clínicas, Faculdade de Medicina de Ribeirão Preto, Universidade de São Paulo, Ribeirão Preto, SP, Brazil

<sup>3</sup> Department of Orthopedics and Traumatology, Faculdade de Medicina de Ribeirão Preto, Universidade de São Paulo, Ribeirão Preto, SP, Brazil

Address for correspondence Kelsen de Oliveira Teixeira, Master, Rua Dr. Amâncio de Carvalho, 86. Ed. Tita Salzano, Ap. 406, P.O, São Paulo, SP, 04012-080, Brazil (e-mail: kelsenteixeira@gmail.com).

Rev Bras Ortop 2022;57(3):375–383.

### Abstract

**Objective** The present study aimed to develop and evaluate the use of customized guides in patients undergoing surgery to correct vertebral deformity with a pedicular fixation system.

**Methods** Four patients with spinal deformity (three with idiopathic scoliosis and one with congenital kyphoscoliosis) underwent surgical treatment to correct the deformity with a pedicular fixation system. Prototypes of 3D cost guides were developed and evaluated using technical feasibility, accuracy, and radiation exposure.

**Results** The present study included 85 vertebral pedicles in which pedicle screws were inserted into the thoracic spine (65.8%) and into the lumbar spine (34.2%). Technical viability was positive in 46 vertebral pedicles (54.1%), with 25 thoracic (54%) and 21 lumbar (46%). Technical viability was negative in 39 pedicles (45.9%), 31 of which were thoracic (79.5%), and 8 were lumbar (20.5%). In assessing accuracy, 36 screws were centralized (78.2%), of which 17 were in the thoracic (36.9%) and 19 in the lumbar spine (41.3%). Malposition was observed in 10 screws (21.7%), of which 8 were in the thoracic (17.4%) and 2 in the lumbar spine (4.3%). The average radiation record used in the surgical procedures was of  $5.17 \pm 0.72$  mSv, and the total time of use of fluoroscopy in each surgery ranged from 180.3 to 207.2 seconds.

### Keywords

- ▶ fractures, bone
- ▶ congenital abnormalities
- ▶ spine
- ▶ thoracic vertebrae

*Work developed at the Orthopedics and Traumatology Department, Hospital das Clínicas, Faculdade de Medicina de Ribeirão Preto, Universidade de São Paulo, Ribeirão Preto, SP, Brazil.*

received  
July 31, 2020  
accepted  
October 2, 2020  
published online  
August 13, 2021

DOI <https://doi.org/10.1055/s-0041-1724074>.  
ISSN 0102-3616.

© 2021. Sociedade Brasileira de Ortopedia e Traumatologia. All rights reserved.

This is an open access article published by Thieme under the terms of the Creative Commons Attribution-NonDerivative-NonCommercial-License, permitting copying and reproduction so long as the original work is given appropriate credit. Contents may not be used for commercial purposes, or adapted, remixed, transformed or built upon. (<https://creativecommons.org/licenses/by-nc-nd/4.0/>)

Thieme Revinter Publicações Ltda., Rua do Matoso 170, Rio de Janeiro, RJ, CEP 20270-135, Brazil

## Resumo

### Palavras-chave

- ▶ fraturas ósseas
- ▶ anormalidades congênitas
- ▶ coluna vertebral
- ▶ vértebras torácicas

**Conclusion** The customized guide prototypes allowed the safe preparation of the pilot orifice of the vertebral pedicles in patients with deformities with improved accuracy and reduced intraoperative radiation.

**Objetivo** O presente estudo teve como objetivo desenvolver e avaliar a utilização de guias personalizadas em pacientes submetidos a cirurgia para correção de deformidades vertebrais com sistema de fixação pedicular.

**Métodos** Quatro pacientes com deformidade espinhal (três casos de escoliose idiopática e um caso de cifoescoliose congênita) foram submetidos a tratamento cirúrgico corretivo com sistema de fixação pedicular. Protótipos de guias tridimensionais foram desenvolvidos e avaliados quanto à viabilidade técnica, precisão e exposição à radiação.

**Resultados** O presente estudo incluiu 85 pedículos vertebrais submetidos à inserção de parafusos pediculares na coluna torácica (65,8%) e na coluna lombar (34,2%). A viabilidade técnica foi positiva em 46 pedículos vertebrais (54,1%), sendo 25 torácicos (54%) e 21 lombares (46%). A viabilidade técnica foi negativa em 39 pedículos (45,9%), sendo 31 torácicos (79,5%) e 8 lombares (20,5%). Quanto à precisão, 36 parafusos foram centralizados (78,2%), sendo 17 na coluna torácica (36,9%) e 19 na coluna lombar (41,3%). O mau posicionamento foi observado em 10 parafusos (21,7%), sendo 8 na coluna torácica (17,4%) e 2 na coluna lombar (4,3%). A radiação média registrada nos procedimentos cirúrgicos foi de  $5,17 \pm 0,72$  mSv, e o tempo total de uso da fluoroscopia em cada cirurgia variou de 180,3 a 207,2 segundos.

**Conclusão** Os protótipos de guias personalizadas permitiram o preparo seguro do orifício piloto nos pedículos vertebrais em casos de deformidade, com maior precisão e menor exposição intraoperatória à radiação.

## Introduction

Systems for correcting spinal deformities mainly use pedicle screws for posterior anchoring.<sup>1</sup> These systems allow the three-dimensional (3D) correction of deformities, providing sufficient stability to avoid the use of postoperative immobilization.<sup>2,3</sup> Besides, this system allows for even more significant correction of deformities, especially when compared with hook or hybrid systems.<sup>4-7</sup> However, pedicle fixation systems have some disadvantages, especially concerning complications caused by incorrect positioning of the screw inside the pedicle and exposure of the surgeon to radiation.<sup>8</sup> The incorrect positioning of pedicle screws occurs more frequently in deformities, whose vertebrae present anatomical changes and due to their 3D positioning.<sup>9,10</sup>

The average accuracy of placing pedicle screws freehand, or with fluoroscopy, and with the aid of navigation is 85.1% and 95.5%, respectively.<sup>11-14</sup> Frequently, fluoroscopy is used to assist in the insertion of pedicle screws.<sup>14</sup> However, during fluoroscopy, the exposure of the surgeon to radiation is 10 to 12 times greater than in other procedures that use fluoroscopy in segments outside the spine.<sup>15,16</sup>

New alternatives have been developed to improve accuracy and reduce exposure to radiation, with emphasis on customized guides.<sup>17-19</sup> The advantages of using a customized

guide (low-cost) motivated us to carry out a project for the development of a prototype.

Therefore, the present study aimed to develop and evaluate the use of customized guides in patients undergoing surgery to correct vertebral deformity with a pedicular fixation system. These guides are made using 3D printing from spinal models and are developed to assist in the preparation of the pilot hole in the spinal pedicle.

## Methods

The Research Ethics Committee approved the present study (protocol number 3,365,105).

The present study was performed in four patients with spinal deformities who underwent surgical treatment using a pedicular fixation system.

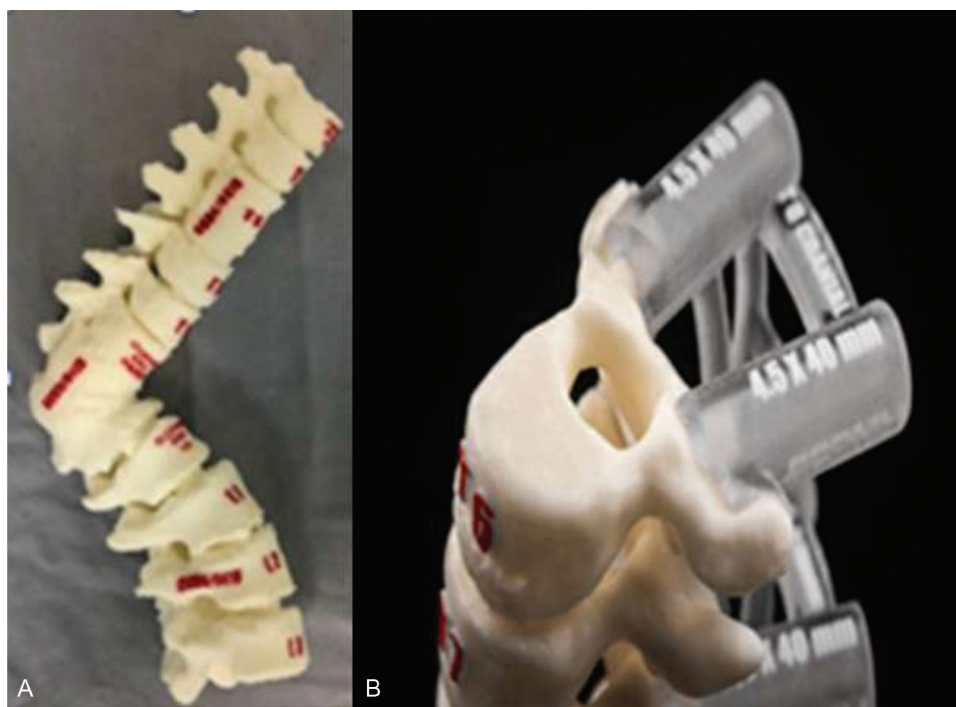
The demographic data of the patients are shown in **Table 1**. Three patients had idiopathic scoliosis and one patient had kyphoscoliosis. All patients were female, ranging in age from 11 to 17 years old (mean = 15 years old).

A set of 3D guides was made for each patient. An individual guide was created for each vertebra programmed to receive pedicle fixation. Along with the guides, a model of the spine was also made, which helped the 3D orientation of the vertebral structures (**Fig. 1**).

**Table 1** Demographic data of the patients evaluated in the study.

	Age (years)	Sex	Deformity	Levels	Cobb Angle
Patient 1	16	Female	AIS	T10-L4	65,8°
Patient 2	17	Female	JIS	T3-L3	68,1°
Patient 3	11	Female	Congenital kyphoscoliosis	T8-L2	57,5° (scoliosis) / 87,3° (kyphosis)
Patient 4	15	Female	JIS	T6-L2	64,1°

Abbreviations: AIS, adolescent idiopathic scoliosis; JIS, juvenile idiopathic scoliosis; Levels, extension of the scoliotic curve.



**Fig. 1** Illustrative images. (A) photograph of the model of the spine of a patient with congenital deformity; (B) a photo of the surgical guide attached to the model in the position to prepare the pilot hole.

The 3D guides were made based on preoperative computed tomography (TC) covering the extension of the vertebral segment programmed to receive the pedicle screws. Computed tomography was standardized in sections  $\leq 1$  millimeter to allow greater accuracy in the anatomical reconstruction of the bone surface.

The preoperative programming to determine bilaterally, in each vertebra, the positioning of the screw inside the vertebral pedicle, its angulation and length was performed employing 3D anatomical analysis (ATA) using software (Materialize Brazil, São Paulo, SP, Brazil). The surgeon guided the position, angulation, and length of the pedicle screw to be used (– Fig. 2).

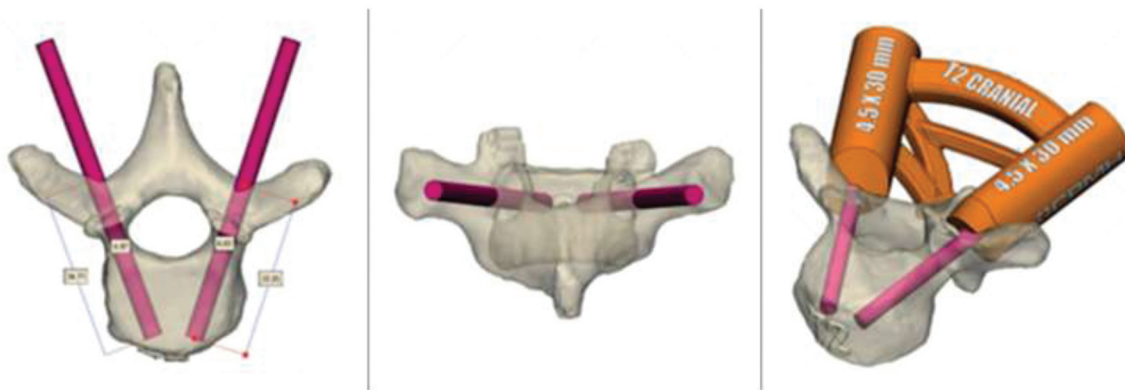The guides were made with synthetic material of biocompatible, nonbiodegradable resin, and were subjected to sterilization at a temperature of 50°C in a Sterrad (Medsteril, Água Branca, São Paulo, SP, Brazil) device. A specific guide was created for each vertebra using a 3D printer. Each guide, made for one particular vertebra separately, consisted of two cylindrical parts that guided the entry point and the preparation of the pilot hole of the vertebral pedicle by placing the instruments inside it (– Fig. 3).

During the surgical procedure, the guides were coupled to each vertebra, through their fit in the spinous process and the opposition of the surface of the guides at the point corresponding to the projection of the vertebral pedicle on the back of the vertebra (– Fig. 4)

With the guide positioned and stabilized, the entry point into the vertebral pedicle was determined by the introduction of the appropriate instrument within the guide. Then, the pilot hole was made with probes placed inside, followed by taps and checks on the vertebral pedicle walls before the insertion of the screws.

To assess the use of the guides, we used the following parameters: technical viability, precision, and exposure to radiation.

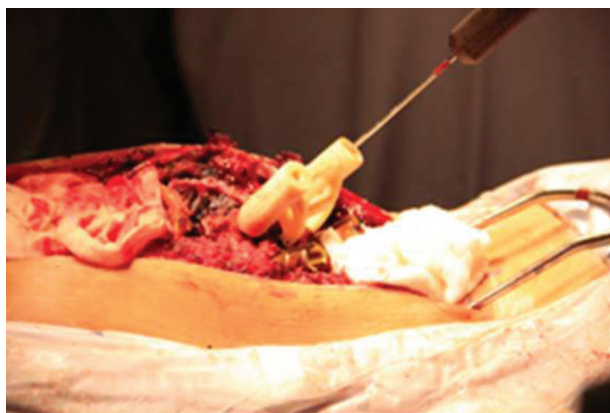The technical performance of the guide and its use for the desired purpose was considered, being classified as positive or negative. Therefore, we considered of positive technical viability the guide that allowed its use according to the desired objectives. On the other hand, negative technical viability was considered when the guide could not be used or did not reach the desired goals (inadequate adjustment of the guide in the posterior vertebral elements, entry point of the



**Fig. 2** Photograph of the preoperative 3D anatomical analysis in different angles with the simulation of the position of the pedicle screws and the fitting of the surgical guide in the posterior region of the corresponding vertebra.



**Fig. 3** Photograph of the surgical guide for a lumbar vertebra.



**Fig. 4** Intraoperative image of a surgical guide positioned in the posterior vertebral region, with an instrument attached to prepare a pilot hole.

perforation without correlation with the anatomical references, breakage of the guide during its use, failure to couple the surgical instruments with the guide, inadequacy of the pilot hole observed by checking the pedicle walls or fluoroscopy).

Accuracy was assessed in the postoperative period using CT. We consider the pedicle screw to be well-positioned when centralized in the vertebral pedicle, keeping the lateral

and medial walls of the vertebral pedicle integral. If there is a violation of the lateral or medial wall of the vertebral pedicle, we consider the screw to be malpositioned.

The exposure to intraoperative radiation was performed by measuring the total time of use of fluoroscopy and its dose.

The Mann-Whitney nonparametric test was used to analyze the results, and the level of significance was set at  $p \leq 0.05$ .

## Results

We evaluated the total set of 85 vertebral pedicles (56 thoracic and 29 lumbar) in which the pedicle screws were inserted.

Technical viability was positive in 46 vertebral pedicles (54.1%), of which 25 were thoracic (54%) and 21 lumbar pedicles (46%). Technical viability was negative in 39 pedicles (45.9%), of which 31 were thoracic (79.5%), and 8 were lumbar (20.5%). Technical viability was negative due to several factors, such as inadequate fitting of the guide to the posterior vertebral elements (10 pedicles [11.7%]), the entry point of perforation without correlation with anatomical references (23 pedicles [27%]), breakage of the guide during use, failure in the coupling of surgical instruments with the guide (2 pedicles [2.5%]), and inadequacy of the pilot hole observed by checking the pedicle walls or fluoroscopy (4 pedicles [4.7%]). The negative technical viability was directly related to the development stages of the customized guide prototype. It was reduced as a result of surgeries performed with the improvement of the guide prototype.

The evaluation of the accuracy of pedicle screws in which the pilot hole was prepared with the help of the guide showed that 36 screws were centralized (78.2%), with 17 in the thoracic (36.9%) and 19 in the lumbar spine (41.3%).

In 10 pedicles (21.7%), the screws were not centralized according to what was established in the preoperative schedule, with violation of the lateral wall in 6 pedicles (13%) and 4 in the medial (4.3%). The accuracy of the screws in the thoracic spine and concavity was lower concerning the other vertebral segments.

Here, the positioning of the screws predominated in the thoracic spine and was superior to the group of vertebral pedicles in which the guide cannot be used. The pilot hole

**Table 2** Analysis of the position of pedicle screws with and without guides

	With guide			Without guide		
	Violation		Central	Violation		Central
	Medial cortical	Lateral cortical		Medial cortical	Lateral cortical	
T2				1	1	
T3						1
T4		1		2	1	
T5			2		2	2
T6			2	2	1	1
T7				2	1	1
T8	2		2	1		1
T9	1	1	2	1	1	2
T10	1		1		1	3
T11		1	3	1	1	1
T12		1	5			

was prepared with the help of the model, showing its assistance in improving the accuracy.

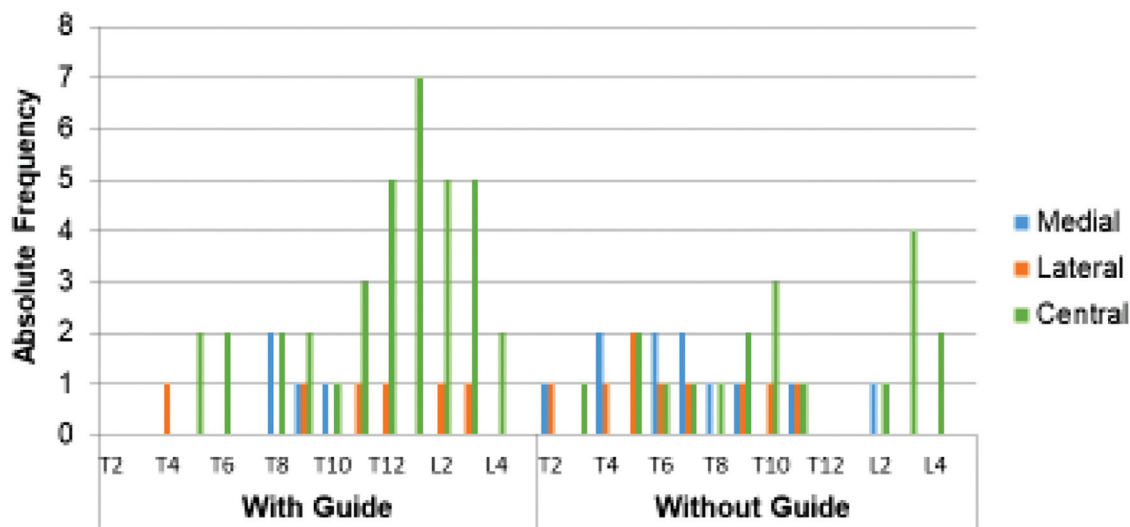
A noncentralized positioning of the screw was observed in 10 pedicles (21.7%), 8 in the thoracic (17.4%), and 2 in the lumbar spine (4.3%). The rupture of the lateral wall was observed in 6 pedicles (13%), 4 of which were thoracic (8.7%), and 2 were lumbar (4.3%). The rupture of the medial wall was observed in 4 pedicles (8.7%), all of them in the thoracic spine.

In the 39 pedicles whose pilot holes were prepared without the aid of the guide, the screws were centralized in 19 pedicles (48.7%), 12 in the thoracic spine (30.8%), and 7 in the lumbar spine (17.9%). Malposition was observed in 20 screws (51.3%), 18 in the thoracic (46.2%), and 2 in the lumbar spine (5.1%). The rupture of the lateral wall was observed in 9 pedicles (23%), all of them being thoracic. The separation of

the medial wall was observed in 11 pedicles (28.2%), 10 of which were thoracic (25.7%), and 1 lumbar (2.5%).

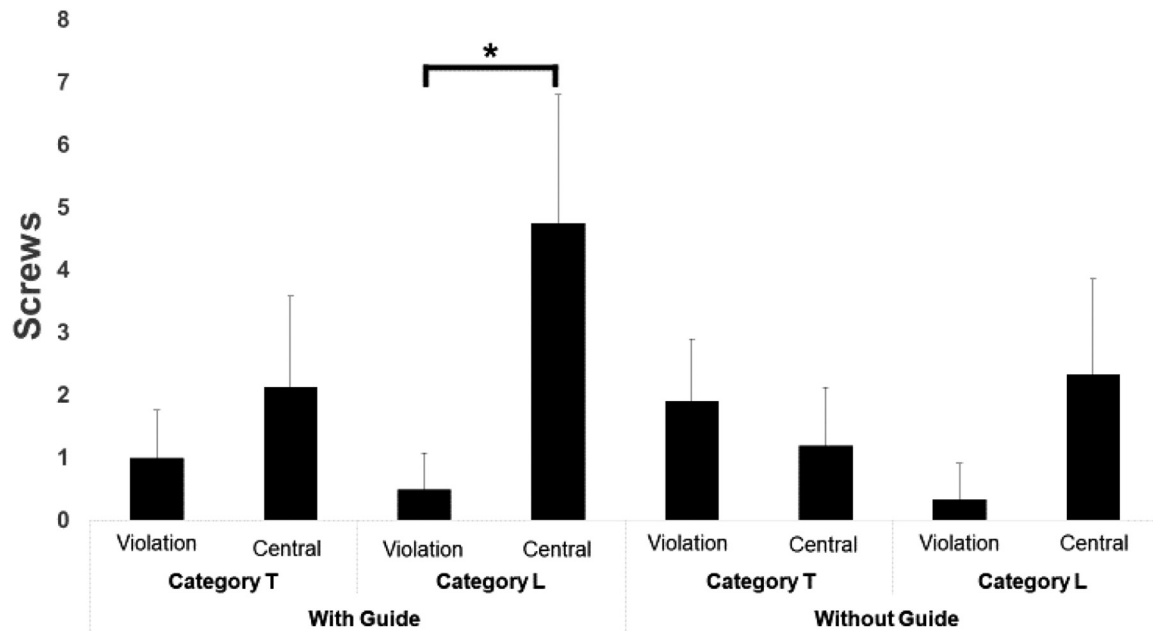
The comparison of the accuracy of the set of pedicles in which the pilot hole was prepared with and without the guide is shown in ►Table 2 and ►Fig. 5. Higher efficiency was observed with the use of guides in the pedicles of the lumbar vertebrae ( $p < 0.05$ ). In contrast, in the pedicles of the thoracic spine and in the set of all pedicles, the accuracy did not show the statistical difference (►Fig. 6). It must be considered that the nonuse of the drilling guides was related to the negative technical viability, and that the intraoperative visualization of the model helped in the preparation of the pilot hole.

The general technical feasibility showed statistical significance ( $p = 0.0089$ ) (►Fig. 7), and a gradual increase was observed following surgical procedures. Improvement of

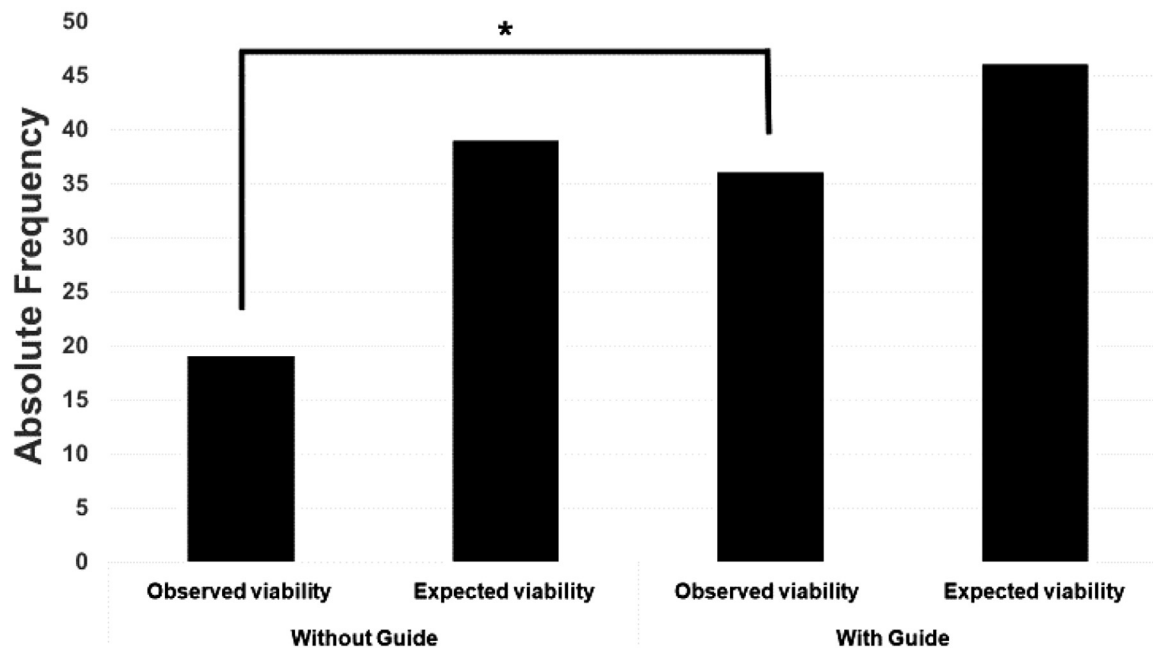


**Fig. 5** Comparison of the accuracy of pedicle screws in the thoracic and lumbar levels in absolute frequency (number of pedicles), positioned with and without the aid of surgical guides.





**Fig. 6** Accuracy of positioning pedicle screws with and without the use of guides in the thoracic (category T) and lumbar (category L) spine, by the average number of screws by number of levels addressed in each vertebral segment (lumbar and thoracic). \* $p \leq 0.05$ .



**Fig. 7** Technical viability considering all pedicles instrumented with and without the use of guides. Absolute Frequency: frequency in the absolute number of pedicles addressed. \* $p = 0.0089$ .

prototypes (► Fig. 8) has been of great help in the correction of complex and severe deformities (► Fig. 9).

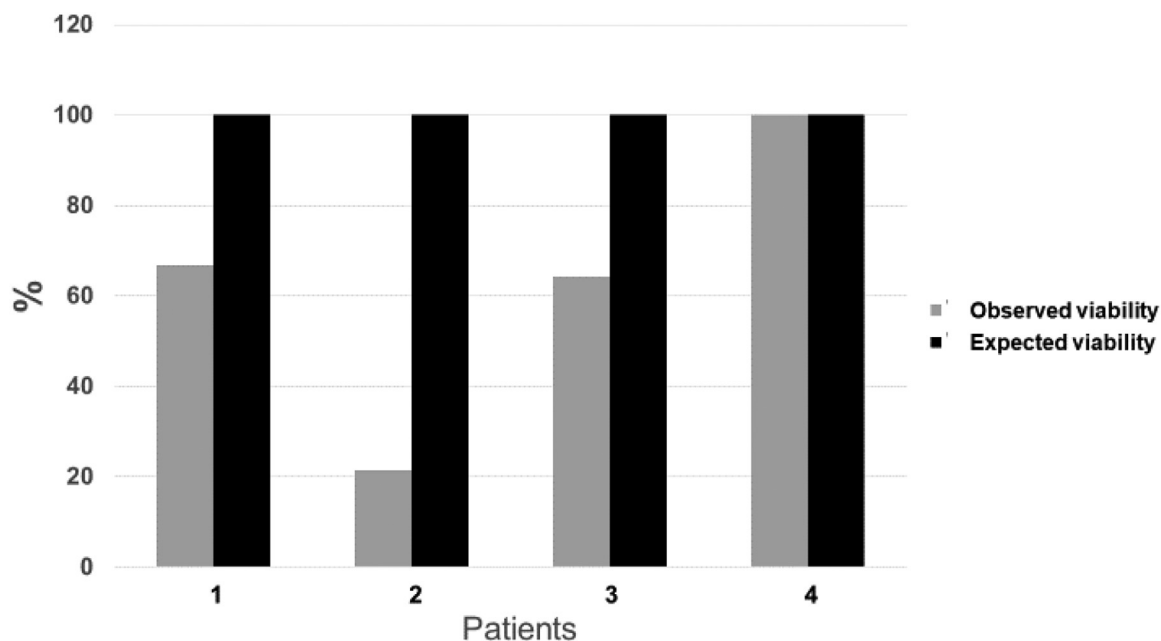
Intraoperative radiation exposure ranged from 4.35 millisievert (mSv) to 6.32 mSv (mean =  $5.17 \pm 0.72$ ), with radioscopy use time from 180.3 to 207.2 seconds (mean =  $190 \pm 16.23$ ).

There were no operative and postoperative complications, such as increased bleeding, neurological injuries, or changes in motor or sensory potential during intraoperative neurophysiological monitoring.

## Discussion

Initially, 3D printing was idealized by Hall<sup>20</sup> in 1986. After that, the technique was improved and introduced as an auxiliary tool in surgeries, especially in the spine.<sup>19</sup> In the context of spine surgery, it has been used to produce anatomical models, surgical guides, and implants.<sup>20</sup>

In the present study, we aimed to develop a customized guide prototype and evaluate its results for the preparation



**Fig. 8** Technical viability with the use of guides for each patient operated at a relative frequency (percentage).

of the pilot hole in the pedicles of the thoracic and lumbar vertebrae of patients with spinal deformity.

Through the interpretation of our results, it was possible to observe the improvement of the surgery with the use of the prototype, adjusting and correcting the problems found, and increasing its technical viability after the performed operations. Changes in the synthetic composition of the guide, its mechanism of fixation to the posterior elements of the vertebra, and the best adaptation of the instruments for the preparation of the pedicle within the guide were the main changes made. Also, problems related to the technical feasibility of using the guide were more frequent in the pedicles of the thoracic vertebrae.

The problems related to the fitting of the guides in the vertebrae of patients with rigid scoliosis and high angular value were also reported by Liu et al.<sup>21</sup> A more significant contact of the guide with the posterior surface of the vertebra increases the stability of the guide for the preparation of the pilot hole so that the guides must be made for private use in each vertebra. This observation corroborates the reports of Berry et al.,<sup>22</sup> showing the inaccuracy of the guides for multiple levels.

The fitting of the guide on the posterior face of the vertebra required extensive dissection and detachment of the soft parts inserted in the vertebrae. This factor was also pointed out as being essential for the fitting of the guide in the vertebrae,<sup>21</sup> and could be pointed out as a disadvantage for the use of this type of guide in procedures of smaller extension. However, in deformities, it is necessary to have a broad exposure of the vertebra with the disinsertion of the soft parts, so that the full exposure and detachment does not present a disadvantage for the use of the guide.

The use of guides increased the precision of screw placement compared with the group in which the guide was not used, due to the technical unfeasibility and the model used to help guide the preparation of the pilot hole. In patients with

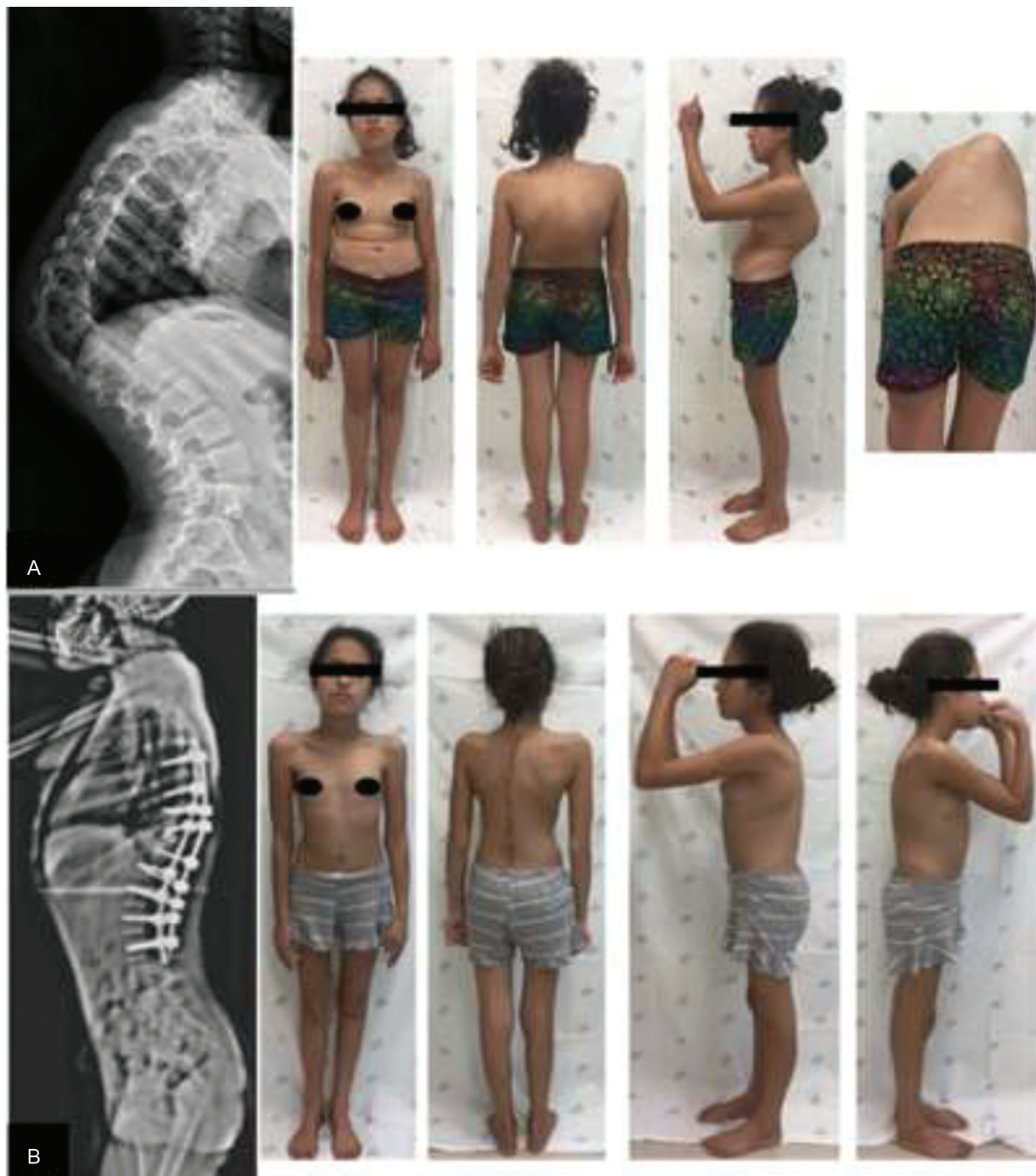
spinal deformity, the rate of screw malposition varies from 3 to 44.2%, and neurological complications from 0 to 0.9%.<sup>3,13,16,23–28</sup> The pedicles of the thoracic spine and of the concavity of the curve have the highest percentage of malposition.<sup>3,13,16,23–28</sup> The results observed in the present study corroborate the reports in the literature, with the pedicles of the thoracic region having the highest index of malpositioning. However, despite the noncentralized positioning in 10 pedicles (8 thoracic and 2 lumbar), there was no damage to the structures adjacent to the pedicle or the need to reposition or remove implants in any patient.

The accuracy of the use of guides in the thoracic pedicles was 68%, being higher than the results of the group in which the guide was not used, evidencing the benefit of its use in the preparation of the pilot orifice.

Indeed, the learning curve and the development of the guide prototype must be considered when analyzing our results. The results of the accuracy of the last operated patient showed high technical feasibility and accuracy close to the 3D anatomical analysis performed in the preoperative period.

The use of the customized guide prototype allowed the reduction of the time of use of fluoroscopy and, consequently, reduction of exposure to intraoperative radiation. The exposure of the surgeon during the placement of pedicle screws is between 10 and 12 times greater than that of other procedures outside the spine.<sup>29,30</sup> The intraoperative radiation dose in surgeries for vertebral deformities has been reported to be  $\sim 7.05$  mSv. Here, we observed lower values that ranged from 4.35 mSv to 6.32 mSv ( $5.17 \pm 0.72$  mSv), indicating less exposure to intraoperative radiation. However, the ideal comparison would imply the analysis of similar groups, which was not possible due to the similarity of heterogeneous samples, so that the comparative value can only be used as a reference.

Although the technique of preparing the pilot hole and inserting the pedicle screws without the aid of images or



**Fig. 9** Pre (A) and postoperative (B) radiographic and clinical images of a patient with congenital kyphoscoliosis (patient 3), in which the customized guide was used.

devices has been reported to be safe and with acceptable accuracy, the use of the pilot hole preparation guides can increase the efficiency and reduce the amount of intraoperative radiation. The use of guides associated with the knowledge and experience of the surgeon can make the procedure safer, more accurate, and reduce the amount of intraoperative radiation. The results presented here are only related to the development of the guide prototype, indicating that its development can assist in performing spine surgeries that use the vertebral pedicle as the implant anchorage site.

## Conclusion

The use of guides to prepare the pilot orifice in the vertebral pedicles of patients with spinal deformity allowed for safe preparation, improving the accuracy of pedicle screws, and reducing the intensity of intraoperative radiation. This technology has great potential for clinical use, allowing the placement of pedicle screws in a safer, more accurate manner, and with less use of intraoperative radiation.



### Contribution of the Authors

(I) Conception and design: Teixeira K.O., Defino H.L.A.; (II) Administrative support: none; (III) Supply of study materials or of patients: all authors; (IV) Collection and assembly of data: Teixeira K.O., Matos T.D., Fleury R.B. C.; (V) Data analysis and interpretation : Teixeira K.O., Bergamaschi J.P.M., Defino H.L.A.; (VI) Writing of the manuscript: all authors; (VII) Final approval of the manuscript: all authors.

### Financial Support

This work was supported by the Instituto de Pesquisa e Ensino Home, Brasília, DF, Brazil.

### Conflicts of Interest

The authors have no conflicts of interest to declare.

### Acknowledgments

We thank the company CPMH Produtos Médicos Hospitalares for providing the material used in the surgeries and scientific support.

We would also like to thank Camila Cardador for the scientific support, and Professor Walter Krause Neto for his help in the final preparation of this manuscript.

### References

- Dobbs MB, Lenke LG, Kim YJ, Kamath G, Peelle MW, Bridwell KH. Selective posterior thoracic fusions for adolescent idiopathic scoliosis: comparison of hooks versus pedicle screws. *Spine* 2006;31(20):2400–2404
- Webb JK, Burwell RG, Cole AA, Lieberman I. Posterior instrumentation in scoliosis. *Eur Spine J* 1995;4(01):2–5
- Boos N, Webb JK. Pedicle screw fixation in spinal disorders: a European view. *Eur Spine J* 1997;6(01):2–18
- Maruyama T, Takeshita K. Surgical treatment of scoliosis: a review of techniques currently applied. *Scoliosis* 2008;3:6
- Takeshita K, Maruyama T, Murakami M, et al. Correction of scoliosis using segmental pedicle screw instrumentation versus hybrid constructs with hooks and screws. *Stud Health Technol Inform* 2006;123:571–576
- Kim YJ, Lenke LG, Kim J, et al. Comparative analysis of pedicle screw versus hybrid instrumentation in posterior spinal fusion of adolescent idiopathic scoliosis. *Spine* 2006;31(03):291–298
- Bullmann V, Liljenqvist UR, Schmidt C, Schulte TL. [Posterior operative correction of idiopathic scoliosis. Value of pedicle screws versus hooks]. *Orthopade* 2009;38(02):198–200, 202–204
- Merc M, Recnik G, Krajnc Z. Lumbar and sacral pedicle screw placement using a template does not improve the midterm pain and disability outcome in comparison with free-hand method. *Eur J Orthop Surg Traumatol* 2017;27(05):583–589
- Abul-Kasim K, Ohlin A. The rate of screw misplacement in segmental pedicle screw fixation in adolescent idiopathic scoliosis. *Acta Orthop* 2011;82(01):50–55
- Pan Y, Lü GH, Kuang L, Wang B. Accuracy of thoracic pedicle screw placement in adolescent patients with severe spinal deformities: a retrospective study comparing drill guide template with free-hand technique. *Eur Spine J* 2018;27(02):319–326
- Esses SI, Sachs BL, Dreyzin V. Complications associated with the technique of pedicle screw fixation. A selected survey of ABS members. *Spine* 1993;18(15):2231–2238, discussion 2238–2239
- Halm H, Niemeyer T, Link T, Liljenqvist U. Segmental pedicle screw instrumentation in idiopathic thoracolumbar and lumbar scoliosis. *Eur Spine J* 2000;9(03):191–197
- Hamill CL, Lenke LG, Bridwell KH, Chapman MP, Blanke K, Baldus C. The use of pedicle screw fixation to improve correction in the lumbar spine of patients with idiopathic scoliosis. Is it warranted? *Spine* 1996;21(10):1241–1249
- Panjabi MM, O'Holleran JD, Crisco JJ 3rd, Kothe R. Complexity of the thoracic spine pedicle anatomy. *Eur Spine J* 1997;6(01):19–24
- Liljenqvist UR, Halm HF, Link TM. Pedicle screw instrumentation of the thoracic spine in idiopathic scoliosis. *Spine* 1997;22(19):2239–2245
- Lonstein JE, Denis F, Perra JH, Pinto MR, Smith MD, Winter RB. Complications associated with pedicle screws. *J Bone Joint Surg Am* 1999;81(11):1519–1528
- Cordemans V, Kaminski L, Banse X, Francq BG, Detrembleur C, Cartiaux O. Pedicle screw insertion accuracy in terms of breach and reposition using a new intraoperative cone beam computed tomography imaging technique and evaluation of the factors associated with these parameters of accuracy: a series of 695 screws. *Eur Spine J* 2017;26(11):2917–2926
- Upendra B, Meena D, Kandwal P, Ahmed A, Chowdhury B, Jayaswal A. Pedicle morphometry in patients with adolescent idiopathic scoliosis. *Indian J Orthop* 2010;44(02):169–176
- Kong X, Tang L, Ye Q, Huang W, Li J. Are computer numerical control (CNC)-manufactured patient-specific metal templates available for posterior thoracic pedicle screw insertion? Feasibility and accuracy evaluation. *Eur Spine J* 2017;26(11):2927–2933
- Cecchinato R, Berjano P, Zerbi A, Damilano M, Redaelli A, Lmartina C. Pedicle screw insertion with patient-specific 3D-printed guides based on low-dose CT scan is more accurate than free-hand technique in spine deformity patients: a prospective, randomized clinical trial. *Eur Spine J* 2019;28(07):1712–1723
- Liu K, Zhang Q, Li X, et al. Preliminary application of a multi-level 3D printing drill guide template for pedicle screw placement in severe and rigid scoliosis. *Eur Spine J* 2017;26(06):1684–1689
- Berry E, Cuppone M, Porada S, et al. Personalised image-based templates for intra-operative guidance. *Proc Inst Mech Eng H* 2005;219(02):111–118
- Kosmopoulos V, Schizas C. Pedicle screw placement accuracy: a meta-analysis. *Spine* 2007;32(03):E111–E120
- Cotrel Y, Dubousset J, Guillaumat M. New universal instrumentation in spinal surgery. *Clin Orthop Relat Res* 1988;227(227):10–23
- West JL III, Ogilvie JW, Bradford DS. Complications of the variable screw plate pedicle screw fixation. *Spine* 1991;16(05):576–579
- Suk SI, Kim WJ, Lee SM, Kim JH, Chung ER. Thoracic pedicle screw fixation in spinal deformities: are they really safe? *Spine* 2001;26(18):2049–2057
- Youkilis AS, Quint DJ, McGillicuddy JE, Papadopoulos SM. Stereotactic navigation for placement of pedicle screws in the thoracic spine. *Neurosurgery* 2001;48(04):771–778, discussion 778–779
- Gertzbein SD, Robbins SE. Accuracy of pedicular screw placement in vivo. *Spine* 1990;15(01):11–14
- Rampersaud YR, Foley KT, Shen AC, Williams S, Solomito M. Radiation exposure to the spine surgeon during fluoroscopically assisted pedicle screw insertion. *Spine* 2000;25(20):2637–2645
- Villard J, Ryang YM, Demetriades AK, et al. Radiation exposure to the surgeon and the patient during posterior lumbar spinal instrumentation: a prospective randomized comparison of navigated versus non-navigated freehand techniques. *Spine* 2014;39(13):1004–1009