



# Idiopathic Hypertrophic Spinal Pachymeningitis: A Case Report

## *Paquimeningite hipertrófica idiopática espinhal: Relato de caso*

Lucas Lodomiro Araújo Melo<sup>1,2</sup> Murilo Tavares Daher<sup>1,2</sup> Marcus Vinícius Magno Gonçalves<sup>3</sup>  
Marianne Borges Freitas<sup>4</sup>

<sup>1</sup> Faculty of Medicine, Department of Orthopedics, Universidade Federal de Goiás, Goiânia, GO, Brazil

<sup>2</sup> Centro Estadual de Reabilitação e Readaptação Dr. Henrique Santillo (CRER), Goiânia, GO, Brazil

<sup>3</sup> Department of Medicine, Universidade Regional de Joinville (UNIVILLE), Joinville, SC, Brazil

<sup>4</sup> Universidade Federal de Uberlândia, Uberlândia, MG, Brazil

**Address for correspondence** Lucas Lodomiro Araújo Melo, MD, Ortopedista, Brazil (e-mail: lucaslodomiro@yahoo.com.br).

Rev Bras Ortop 2022;57:521–523.

### Abstract

#### Keywords

- ▶ spinal cord
- ▶ meningitis/pathology
- ▶ meningitis/physiopathology
- ▶ hypertrophy

Idiopathic hypertrophic pachymeningitis is rare cause of neurological symptoms with myelopathy due to spinal cord compression. We report a case of pachymeningitis, which was manifested primarily by tetraparesis after low-energy trauma and recurrence the myelopathy symptoms after 5 years of surgery. The patient, a 19-year-old woman, was subjected to extensive investigation without evidence of any underlying disease. A meningeal biopsy was performed and showed an unspecific inflammatory process with extensive fibrosis of the dura mater. These findings, associated with the exclusion of other causes, suggest idiopathic hypertrophic pachymeningitis.

### Resumo

#### Palavras-chave

- ▶ medula espinal
- ▶ meningite/patologia
- ▶ meningite/fisiopatologia
- ▶ hipertrofia

A paquimeningite hipertrófica idiopática é uma causa rara de sintomas neurológicos com mielopatia por compressão da medula espinhal. Relatamos um caso de paquimeningite com manifestação primária de tetraparesia após trauma de baixa energia e recorrência dos sintomas de mielopatia 5 anos após a cirurgia. A paciente, uma mulher de 19 anos, foi submetida a extensa investigação sem evidências de qualquer doença de base. Uma biópsia da meninge revelou processo inflamatório inespecífico com extensa fibrose da dura-máter. Esses achados, associados à exclusão de outras causas, sugerem paquimeningite hipertrófica idiopática.

## Introduction

Idiopathic hypertrophic spinal pachymeningitis (IHSP) is a rare inflammatory autoimmune disorder that leads to spinal

cord compression. This disease, which may be related to IgG4 is an immune-mediated condition characterized by lesions with inflammatory reaction associated with fibrosis and lymphoplasmocyte infiltration, composing a spectrum of

received  
October 12, 2020  
accepted  
December 1, 2020  
published online  
August 13, 2021

DOI <https://doi.org/10.1055/s-0041-1724087>.  
ISSN 0102-3616.

© 2021. Sociedade Brasileira de Ortopedia e Traumatologia. All rights reserved.

This is an open access article published by Thieme under the terms of the Creative Commons Attribution-NonDerivative-NonCommercial-License, permitting copying and reproduction so long as the original work is given appropriate credit. Contents may not be used for commercial purposes, or adapted, remixed, transformed or built upon. (<https://creativecommons.org/licenses/by-nc-nd/4.0/>)

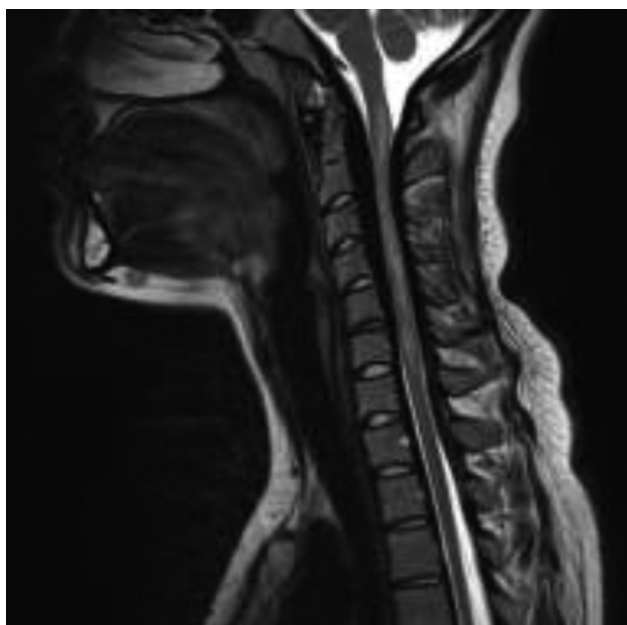
Thieme Revinter Publicações Ltda., Rua do Matoso 170, Rio de Janeiro, RJ, CEP 20270-135, Brazil

lymphoproliferative diseases. We present a case with this pathology and the magnetic resonance imaging (MRI) and meningeal biopsy findings.

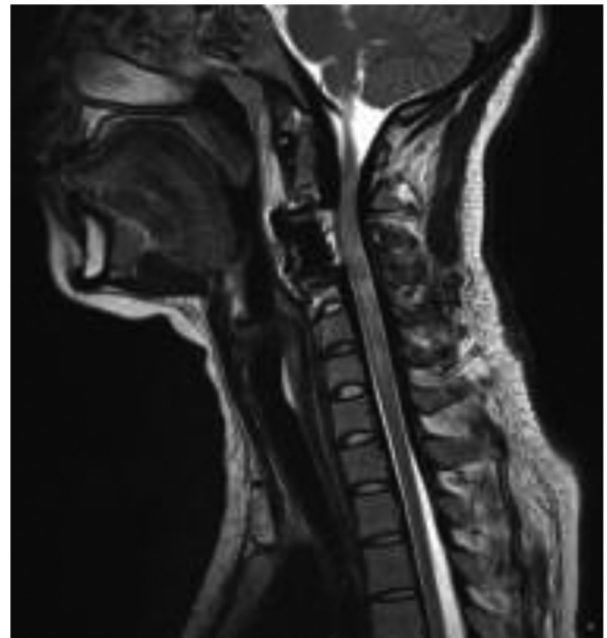### Case Report

A 19-year-old woman presented with acute tetraparesis after cervical whiplash injury. The image of the arrival examination (►Figure 1) showed signs of cervical stenosis at the C3 to C6 level, suggestive of epidural hematoma in the differential diagnosis. Initially, a C3 to C6 laminoplasty was performed. After the surgery, there was no improvement in the neurological status, and postoperative imaging still showed cervical stenosis. It was decided to perform a corpectomy of the C3 level with anterior arthrodesis of the C2 to C4 levels (►Figure 2).

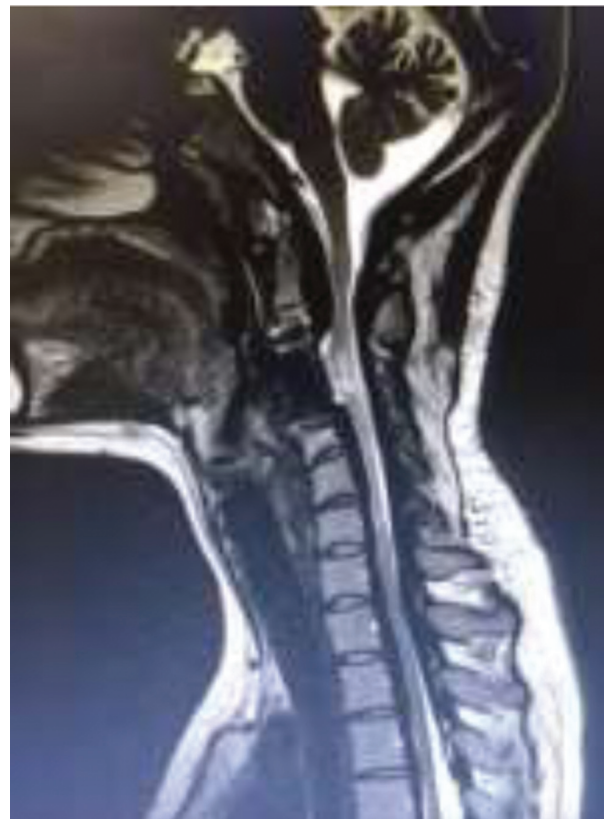The patient showed a progressive motor and sensitive improvement after surgery and physiotherapy. Five years later, the patient displayed abrupt worsening of gait without trauma and motor worsening in the upper and lower limbs (asymmetrical, worse on the right side). Magnetic resonance imaging noted cervicothoracic stenosis at the C7 to T4 levels (►Figure 3). A C7 to T4 laminoplasty was performed. During the surgery, we observed a posterior thickening of the meninge (►Figure 4), which led to the decision of performing a duraplasty with dura mater substitute and posterior arthrodesis of C7 to T5 (►Figure 5). In the biopsy, it was noted a nonspecific chronic inflammatory process of the meninges, with lymphoplasmocyte infiltrate, suggestive of hypertrophic pachymeningitis (►Figure 6). The patient evolved with improvement of the gait and motor symptoms after surgery. Secondary causes were excluded during clinical investigation and the histological clinical diagnosis was IHSP.



**Fig. 1** Magnetic resonance imaging at admission with multilevel cervical stenosis associated with signs of myelopathy.



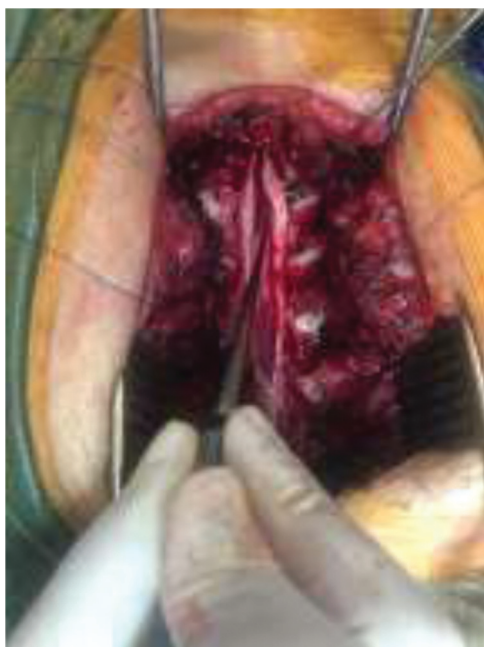**Fig. 2** Magnetic resonance imaging after corpectomy of C3 with anterior arthrodesis of C2–C4 and laminoplasty of C3–C6 levels.



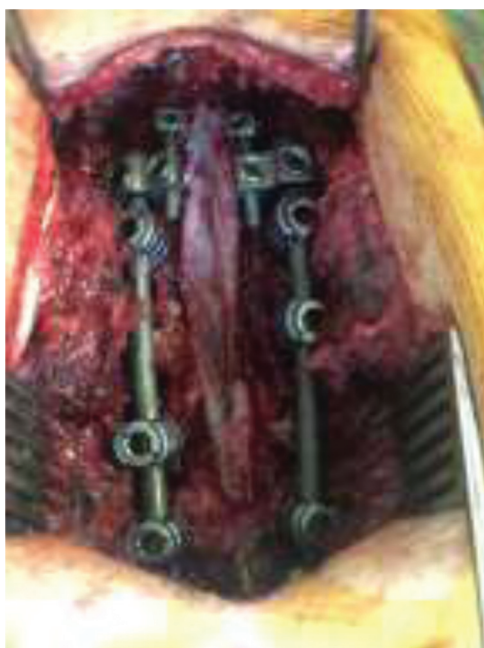**Fig. 3** Cervicothoracic stenosis.

### Discussion

Hypertrophic pachymeningitis is a rare disease arising from a chronic inflammatory course evolving with fibrosis of the dura



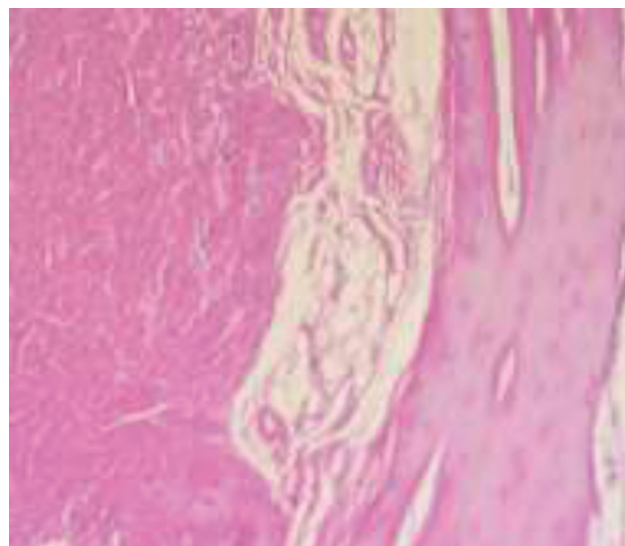
**Fig. 4** Hypertrophy of the meninge after durotomy.



**Fig. 5** Final aspect after duraplasty + posterior arthrodesis of C7–T5.

mater.<sup>1,2</sup> It may be idiopathic or secondary to systemic diseases, such as sarcoidosis, tuberculosis, fungal meningitis, rheumatoid arthritis, carcinomatosis, among other inflammatory diseases.

This disease may have intracranial and spinal involvement. A spinal form, IHSP, is extremely rare, and it might be associated with myelopathy, radiculopathy, or both. This disease is included in the spectrum of diseases related to IgG4, which present with diffuse fibrosis combined with lymphoplasmacytic infiltration rich in IgG4-positive tissue plasma cells.<sup>3</sup> The spinal canal stenosis occurs in this case, and the patient may present abrupt neurological worsening after the trauma. In MRI, it is common to find thickening of the dura mater with hypointensity in T2 and T1, affecting multiple levels with strong contrast enhance-



**Fig. 6** Nonspecific chronic inflammatory process of the meninges with lymphoplasmacyte infiltrate.

ment.<sup>4,5</sup> The clinical treatment includes use of long-term immunosuppressants, such as corticosteroids. Surgical treatment is performed in patients with myelopathy or radiculopathy associated with neurological changes for decompression of the spinal cord. In some cases, it is necessary to perform duraplasty for adequate decompression.

## Conclusion

Hypertrophic pachymeningitis is a rare disease that can develop with spinal canal stenosis with signs of myelopathy. In these cases, surgical decompression may be one of the first therapeutic options implemented, combined with the use of immunosuppressants, which can reduce neurological sequelae in these patients.

### Financial Support

There was no financial support from public, commercial, or non-profit sources.

### Conflict of Interests

The authors have no conflict of interests to declare.

## References

- 1 de Deus-Silva L, Queiroz LS, Zanardi Vd VA, et al. Hypertrophic pachymeningitis: case report. *Arq Neuropsiquiatr* 2003;61(01):107–111
- 2 Rossi S, Giannini F, Cerase A, et al. Uncommon findings in idiopathic hypertrophic cranial pachymeningitis. *J Neurol* 2004;251(05):548–555
- 3 Albuquerque GCM, Guimarães BDA, Ribeiro MAS, Vaz RT, Silva JJX. Apresentação periorbitária de doença relacionada ao IgG4. *Rev Bras Oftalmol* 2018;77(05):286–288
- 4 Mikawa Y, Watanabe R, Hino Y, Hirano K. Hypertrophic spinal pachymeningitis. *Spine* 1994;19(05):620–625
- 5 Jimenez-Caballero PE, Diamantopoulos-Fernandez J, Camacho-Castaneda I. [Hypertrophic cranial and spinal pachymeningitis. A description of four new cases and a review of the literature]. *Rev Neurol* 2006;43(08):470–475