



# Psychomotor Delay in a Child with *FGFR3* G380R Pathogenic Mutation Causing Achondroplasia

Mahmut C. Ergoren<sup>1</sup> Erdal Eren<sup>2</sup> Elena Manara<sup>3</sup> Stefano Paolacci<sup>3</sup> Pinar Tulay<sup>1</sup> Sebnem O. Sag<sup>4</sup>  
Matteo Bertelli<sup>3</sup> Gamze Mocan<sup>1</sup> Sehime Gulsun Temel<sup>4,5</sup>

<sup>1</sup>Department of Medical Genetics, Faculty of Medicine, Near East University, Nicosia, Cyprus

<sup>2</sup>Department of Pediatric Endocrinology, Faculty of Medicine, Bursa Uludağ University, Bursa, Turkey

<sup>3</sup>MAGI's LAB S.r.l., Rovereto, Italy

<sup>4</sup>Department of Medical Genetics, Faculty of Medicine, Bursa Uludağ University, Bursa, Turkey

<sup>5</sup>Department of Histology and Embryology, Faculty of Medicine, Bursa Uludağ University, Bursa, Turkey

Address for correspondence Sehime Gulsun Temel, Department of Medical Genetics, Faculty of Medicine, Near East University, Nicosia, Cyprus (e-mail: pinar.tulay@neu.edu.tr).

Global Med Genet 2021;8:100–103.

## Abstract

Achondroplasia (ACH) is a hereditary disorder of dwarfism that is caused by the aberrant proliferation and differentiation of chondrocyte growth plates. The common findings of macrocephaly and facial anomalies accompany dwarfism in these patients. *Fibroblast growth factor receptor 3 (FGFR3)* gene mutations are common causes of achondroplasia. The current study presents a case of 2-year-old male child patient presenting with phenotypic characteristics of ACH. The interesting finding of the case is the presence of psychomotor delay that is not very common in these patients. Clinical exome sequencing analyzing 4.813 disease causing genes revealed a de novo c.1138G > A mutation within the *FGFR3* gene. In conclusion, the mutation confirms the clinical diagnosis of ACH, and it seems to be causing the psychomotor delay in this patient.

## Keywords

- ▶ achondroplasia
- ▶ *FGFR3* mutations
- ▶ psychomotor delay

## Introduction

Achondroplasia (ACH) is characterized by abnormal proliferation and differentiation of the chondrocyte growth plates and endochondral bone growth. It is presented by macrocephaly with distinct facial anomalies, including frontal bossing, depressed nasal bridge, and rhizomelic dwarfism. Further clinical phenotypes include protruding abdomen and bottoms with short hands. Multiple joints, except the elbows, are hyperextensible.<sup>1</sup> Psychomotor delay anomalies can be caused by hydrocephalus, narrow foramen magnum, and spinal canal stenosis. Although it is a rare disorder with a prevalence of 15000 to 40000 live births, ACH is a very common bone dysplasia.<sup>2</sup> Majority of the ACH cases are sporadic.<sup>3</sup> The autosomal dominant inheritance is mainly

caused by mutations of *fibroblast growth factor receptor 3 (FGFR3)* gene, which encodes a transmembrane (TM) receptor. *FGFR3* is important in development; therefore, the expression of *FGFR3* has been reported in many tissues, including cartilage, brain, kidneys, and intestines. The mutations within the *FGFR3* gene mainly disturb the chondrocyte proliferation and cartilage development. Thus, it has a direct effect on the phenotype of ACH.<sup>4</sup> The most common mutation was shown to be c.1138G > A (p.G380R).<sup>5,6</sup> Pathogenic mutations, including this one, leads to gain-of-function properties. In this study, we report the genetic diagnosis in a 2-year-old male with clinical indications suggestive of ACH, with the exception of cervicomedullary compression and hydrocephaly.

published online  
May 21, 2021

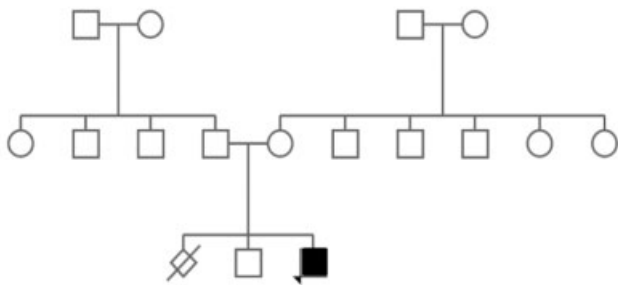
DOI <https://doi.org/10.1055/s-0041-1725070>.  
ISSN 2699-9404.

© 2021. The Author(s).

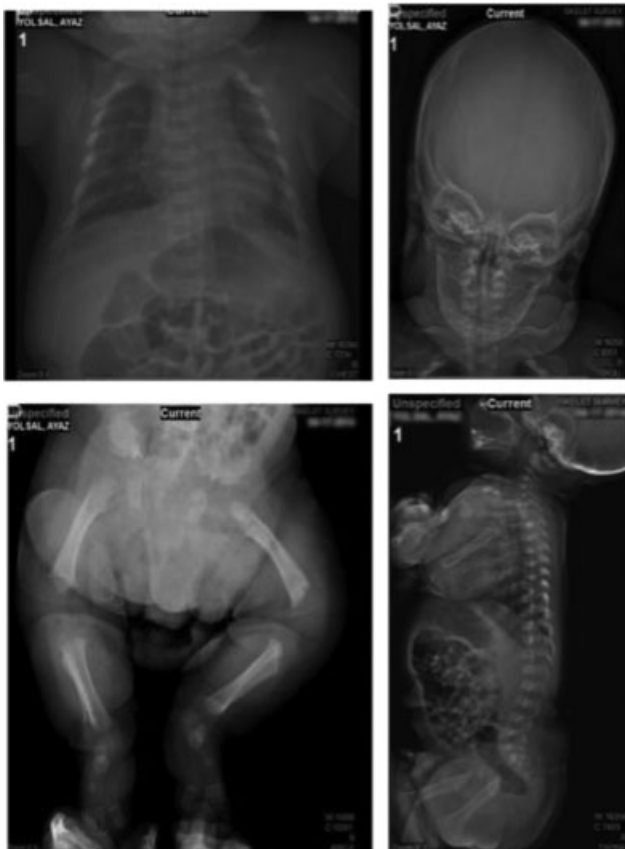This is an open access article published by Thieme under the terms of the Creative Commons Attribution License, permitting unrestricted use, distribution, and reproduction so long as the original work is properly cited. (<https://creativecommons.org/licenses/by/4.0/>)  
Georg Thieme Verlag KG, Rüdigerstraße 14, 70469 Stuttgart, Germany

## Case Report

A 2-year-old male child patient was presented to pediatric endocrinology clinic at the Bursa Uludag University Hospital. He was born via caesarean delivery at 39 weeks of gestation as the second birth of the third pregnancy of a 33-year-old female (→Fig. 1). His weight, height, and head circumference were 3340 g, 49 cm, and 35 cm, respectively. The femur shortness of the patient was reported at the 28th week of the gestational period. In the following weeks of the gestation, he was reported to have an increased head circumference. After the delivery, he was admitted to intensive care for 10 days due to respiratory distress. At the 17-month checkup, he weighed 6.5 kg (< 3p), 65 cm (< 3p), and head circumference of 49 cm (50–75p). Physical examination revealed macrocephaly, mild narrow thorax,



**Fig. 1** The pedigree of a child with achondroplasia (ACH).



**Fig. 2** Radiology scan results of a patients' spinal cord, skull, pelvis and lower extremities, respectively.

long body, flatted nose, simian line on the left hand, shortness on the tips of the fingers, and shortness of rhizome in the limbs (→Fig. 2). Furthermore, hypotonicity was also reported. Even though, he could control his head, pick up and hold the objects with his thumb and index fingers, turn sideways and crawl backwards; he could not sit without support. His speech was impaired, in such he could only communicate via single words, rather than sentences. Radiologic investigation showed a compression of the interpedicular distance toward the distal end, expansion of the discs and pelvis penetration and short extremities. Cranial MRI showed frontal bossing of the cranium. In the follow-up checkups, he was reported to have delayed neurologic development. At the age of 3.5 years, he weighed 9.8 kg with 74 cm in height, hypotonicity, impairment of walking, distinct hypersensitivity, and gibbus deformity. Although these findings were in accordance with ACH phenotype, due to the absence of cervicomedullary compression and hydrocephaly, these findings could also be associated with another skeletal dysplasia. Therefore, genetic testing was offered to the parents of the patient.

## Genetic Diagnosis

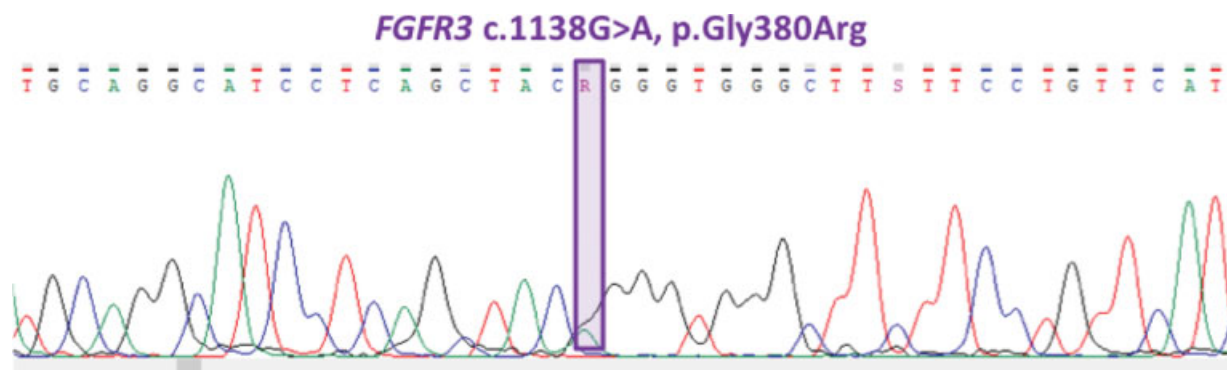
Informed consent was obtained from the patient's parents, and whole blood was withdrawn from the patient as well as the parents for genetic analysis. DNA extraction was performed (DNeasy Blood and Tissue Kit, Qiagen, UK) and clinical exome sequencing of 4,813 genes was performed using TruSight One Sequencing Panel (Illumina, UK) on MiSeq platform.

## Results

Clinical exome sequencing analysis revealed c.1138G>A mutation within the *FGFR3* gene (→Fig. 3). This missense mutation led to substitution of glycine with arginine at position 380 (p.G380R) within the FGFR3 protein. The mutation was heterozygous, and it was confirmed by Sanger Sequencing on CEQ. 8800 system (Beckman Coulter). The parents' genetic testing showed no mutation within exon 10 of *FGFR3* gene, and therefore it was concluded that this mutation was de novo.

## Discussion

ACH is the most common form of skeletal dysplasia that leads to short-limb dwarfism in humans.<sup>7</sup> The main clinical manifestation is macrocephaly with prominent forehead, flat nasal bridge, and short upper arms and legs. More than 90% of the ACH patients were shown to have a mutation at nucleotide position 1138 on *FGFR3* gene, located on 4p16.3.<sup>5</sup> This gene has shown to have crucial roles in the development of the skeleton. The gene is approximately 15kb and comprises 10 introns and 19 exons. All of these exons encode the TM domain of the gene. Receptor tyrosine kinase FGFR3 has 806 amino acid residues and three domains, including an intracellular region, a TM domain, and an extracellular



**Fig. 3** Sequencing result presented a typical achondroplasia (ACH) causing heterozygous *fibroblast growth factor receptor 3* (*FGFR3*) gene G1138A mutation.

region. FGF has the ability to bind to acetylated proteins on cells. This attachment stimulates the receptor dimerization and tyrosine kinase transautophosphorylation.<sup>8</sup>

In the current study, the genetic diagnosis of a male patient with the clinical manifestation suggestive of ACH, with the exception of cervicomedullary compression and hydrocephaly, is presented. The interesting side of this case is the presence of psychomotor delay, which is not very common in ACH patients. The clinical exome sequencing results revealed *FGFR3* c.1138G>A pathogenic variation, which is a widespread deleterious variation detected in ACH patients. Mutations within the *FGFR3* gene lead to dimerization of cell membrane proteins. Thus, the downregulatory effects may suppress the proliferation and differentiation of cartilage through activating intracellular signaling pathways.<sup>9</sup> This mutation within the *FGFR3* gene is the only finding that could lead to the psychomotor delay in this child with achondroplasia. A scarce number of ACH cases have been reported with neurologic and/or psychomotor delays.<sup>10–13</sup> However, to our knowledge, none of these have associated the *FGFR3* gene c.1138G>A (p.G380R) pathogenic variation in the ACH patients with psychomotor delay. Thus, this is the first report to associate the detected mutation with the psychomotor deficits. It has been shown previously via computer modeling of this mutation that G380R mutation causes a rotation within the only TM domain dimer of the *FGFR3*.<sup>14</sup> The contact between two helices was mediated by different amino acids in the mutant dimer compared with the wild type. Previously investigated models using the program CHI revealed the cation- $\pi$  interactions between Arg-380 and three aromatic residues (Phe-384 on the same helix; and Tyr-379, Phe-383 on the neighboring helix).<sup>14</sup> The rotation of the TM dimer interface was associated with variations of the kinase activity. The positions of the catalytic domain positions were suggested to be determined by the RTK TM dimer structure. The phosphorylation capacity was also proposed to be directed by the RTK TM dimer structure. Thus, there can be an increase in the phosphorylation, due to the mutation that is caused by the change in the RTK TM dimer structure. Therefore, it has been suggested that the G380R mutation leading to TM dimer rotation causes the catalytic domains to rotate with respect to each other. This rotation of the catalytic domains was

proposed to cause higher phosphorylation capacity of the unliganded G380R dimer.<sup>14</sup> Thus, it is a possibility that these structural changes lead to the clinical manifestation of this patient with psychomotor delay, which is not widely observed in the ACH patients.

In conclusion, the detected *FGFR3* c.1138G>A pathogenic variation is the most common cause of ACH. Thus, this mutation detected by sequencing the exons and exon-flanking regions of genes involved in clinical phenotypes is the most likely cause of the neurological manifestation, including the psychomotor delay of the patient with ACH phenotype.

#### Conflict of Interest

None declared.

#### References

- Horton WA, Hall JG, Hecht JT. Achondroplasia. *Lancet* 2007;370(9582):162–172
- Placone J, Hristova K. Direct assessment of the effect of the Gly380Arg achondroplasia mutation on *FGFR3* dimerization using quantitative imaging FRET. *PLoS One* 2012;7(10):e46678
- Orioli IM, Castilla EE, Barbosa-Neto JG. The birth prevalence rates for the skeletal dysplasias. *J Med Genet* 1986;23(04):328–332
- Su N, Xu X, Li C, et al. Generation of *Fgfr3* conditional knockout mice. *Int J Biol Sci* 2010;6(04):327–332
- Rousseau F, Bonaventure J, Legeai-Mallet L, et al. Mutations in the gene encoding fibroblast growth factor receptor-3 in achondroplasia. *Nature* 1994;371(6494):252–254
- Shiang R, Thompson LM, Zhu YZ, et al. Mutations in the transmembrane domain of *FGFR3* cause the most common genetic form of dwarfism, achondroplasia. *Cell* 1994;78(02):335–342
- Kaushal A, Halder R, Ambesh P. Anesthesia for an achondroplastic individual with coexisting atlantoaxial dislocation. *Anesth Essays Res* 2015;9(03):443–446
- Mohammadi M, Dikic I, Sorokin A, Burgess WH, Jaye M, Schlesinger J. Identification of six novel autophosphorylation sites on fibroblast growth factor receptor 1 and elucidation of their importance in receptor activation and signal transduction. *Mol Cell Biol* 1996;16(03):977–989
- Webster MK, Donoghue DJ. Constitutive activation of fibroblast growth factor receptor 3 by the transmembrane domain point mutation found in achondroplasia. *EMBO J* 1996;15(03):520–527
- Fowler ES, Glinski LP, Reiser CA, Horton VK, Pauli RM. Biophysical bases for delayed and aberrant motor development in young

- children with achondroplasia. *J Dev Behav Pediatr* 1997;18(03):143–150
- 11 Brinkmann G, Schlitt H, Zorowka P, Spranger J. Cognitive skills in achondroplasia. *Am J Med Genet* 1993;47(05):800–804
- 12 Ruiz-García M, Tovar-Baudin A, Del Castillo-Ruiz V, et al. Early detection of neurological manifestations in achondroplasia. *Childs Nerv Syst* 1997;13(04):208–213
- 13 Hecht JT, Thompson NM, Weir T, Patchell L, Horton WA. Cognitive and motor skills in achondroplastic infants: neurologic and respiratory correlates. *Am J Med Genet* 1991;41(02):208–211
- 14 He L, Horton W, Hristova K. Physical basis behind achondroplasia, the most common form of human dwarfism. *J Biol Chem* 2010;285(39):30103–30114