



Evaluation of Role of Arterialization of Venous Flaps in Abdomen in Rats

Krittika Aggarwal¹ Arun K. Singh¹ Sameer M. Halageri¹ Vijay Kumar¹ Brijesh Mishra¹ D. N. Upadhyay¹

¹Department of Plastic Surgery, King George Medical College, Lucknow, Uttar Pradesh, India

Address for correspondence Krittika Aggarwal, MS, Department of Plastic Surgery, King George Medical College, Lucknow 226003, Uttar Pradesh, India (e-mail: krittika.agga@gmail.com).

Indian J Plast Surg:2021;54:69–74.

Abstract

Introduction Reconstruction forms the primary tenet in plastic surgery. Venous flaps are a known option but the survival is limited. Arterialization of venous flap can enhance its survival. While various techniques of arterialization of venous flaps are described, there are very few studies comparing them.

Material and methods The current study was conducted among 34 rats weighing 160 to 200 grams. The rats were divided into four groups. Group I—isolated epigastric flap was raised with superficial caudal epigastric vessels as pedicle. Group II—arterialized flow through venous flap was raised with superficial caudal epigastric vein (SCEV) as afferent and lateral thoracic vein as drainage vein. Side-to-side anastomosis was done between femoral artery and vein, lateral to the origin of superficial caudal epigastric artery. Group III—after raising the flap, as in group II, femoral vein was ligated proximal to superficial caudal epigastric vessels. Group IV—an arterialized flow through venous flap was raised with superficial caudal epigastric vein as afferent and lateral thoracic vein as drainage vein. End-to-side anastomosis was done between femoral artery and superficial caudal epigastric vein. Animals that died before completion of the study were excluded. The color changes of flaps were noted. Flap survival was expressed as a percentage of the total flap surface area. The patency of anastomosis was seen on postoperative day 5.

Results There was no total flap failure. On statistical analysis, the flap survival area on day 5 between Group I and Group IV was not significant (p value 0.431). The survival area in Group I ($78.85 \pm 10.54\%$) was comparable to Group IV ($65.71 \pm 20.70\%$). Group II and III had poor results as compared with Group I. In four rats, thrombosis of arteriovenous anastomosis was noted with flap survival area of 30 to 33%.

Conclusion It was noted that epigastric venous flaps with end-to-side anastomosis between femoral artery and superficial caudal epigastric vein (group IV) have survival area comparable to isolated flaps.

Keywords

- ▶ venous flap
- ▶ reconstruction
- ▶ experimental

Introduction

Venous flaps are composite flaps which contain skin and subcutaneous veins and rely on venous system alone for flap

perfusion. The primary blood supply enters and exits the flap through the venous system. Venous flaps do not involve sacrifice of an artery at the donor site and do not require deep dissection. Hence, the operative technique is easier and

published online
March 10, 2021

DOI <https://doi.org/10.1055/s-0041-1725227>
ISSN 0970-0358.

©2021. Association of Plastic Surgeons of India.

This is an open access article published by Thieme under the terms of the Creative Commons Attribution-NonDerivative-NonCommercial-License, permitting copying and reproduction so long as the original work is given appropriate credit. Contents may not be used for commercial purposes, or adapted, remixed, transformed or built upon. (<https://creativecommons.org/licenses/by-nc-nd/4.0/>).

Thieme Medical and Scientific Publishers Pvt. Ltd. A-12, 2nd Floor, Sector 2, Noida-201301 UP, India

results in less donor site morbidity. Also, venous flaps are more pliable and thinner than conventional flaps.¹ Venous flaps do not form a commonly used tool in the armamentarium of plastic surgeons. Many successful modifications have been done to increase the chances of survival. Arterialization of venous flaps is one such modification done to increase the chances of its survival. On review of literature, a single similar study has been conducted to study arterialized venous flaps created by various techniques.² This study was conducted to further elaborate on the same.

Relevant Anatomy

Anatomy of the rat groin is analogous to that of the humans. Hind limb when fully extended lies at the angle of 135 degrees to long axis of the body. Inguinal crease, which is analogous to inguinal ligament, makes an angle of 45 degrees with long axis of the body.

The skin of rat is very lax and mobile. It is attached by loose connections to underlying musculature and panniculus carnosus. The femoral triangle is covered with inguinal fat pad. Femoral vessels and nerve contained in femoral sheath lie underneath inguinal fat pad.

The common femoral artery is approximately 1.5 cm long and starts at inguinal crease. The diameter of femoral artery ranges from 0.4 mm to 1 mm and that of femoral vein between 1 to 2 mm. Femoral artery ends by dividing into superficial and deep branches. Just before its division, femoral artery gives off a large branch, superficial caudal epigastric artery, which ascends superomedially through the inguinal fat pad to supply overlying skin. Superficial caudal epigastric artery is accompanied by corresponding veins. The diameter of superficial caudal epigastric artery and vein are 0.3 to 0.5 mm and 0.6 to 0.8 mm, respectively.

Materials and Methods

Aim and Objectives

1. To compare the area of survival between conventional flap and arterialized venous flaps.
2. To evaluate the survival area of flaps created with arterialized venous flaps with different microvascular construct techniques in the abdomen of the rat.

The current experimental study was conducted in the Postgraduate Department of Plastic Surgery in a tertiary care hospital in India from October 2017 to October 2018 after approval from the Institutional Animal Ethical Committee. The sample size was 34 (4 died during the study and were excluded). Sprague–Dawley rats weighing 150 to 200 g were taken. Rats were anaesthetized with ketamine (50 mg/kg) given intraperitoneally. The adequacy of anesthesia was determined by checking loss of limb withdrawal reflex in hind limbs. Supplementary doses of the anesthetic were provided if needed (one-third of the initial dose). Anaesthetized animals were prepared for surgery by placing them supine on a board with lower limbs extended.

A 4-cm long and 3-cm wide fasciocutaneous flap was raised on the right side of abdomen with the help of surgical microscope. The inferior border was the inguinal crease, lateral border was the midlateral line, medial border was parallel to midline of the body, and superior border was parallel to inguinal crease. Incision was first made over the medial border and then over the inguinal crease. The flap was then raised just deep to the panniculus carnosus layer. The flap raised was islanded on the superficial caudal vessels. The rest of the veins were ligated.

The rats were divided into four groups. The flaps were raised in four groups as follows:

In group I, conventional islanded flap, as described above, was elevated. In group II, lateral thoracic vein was preserved cranially. After raising the flap, superficial caudal epigastric artery was ligated with nylon 10–0 suture. A 1-mm long side-to-side anastomosis was created after making a 1-mm long ostium in adjacent flanks of the femoral artery and vein. The anastomosis was done between the femoral artery and vein, in a side-to-side manner, lateral to the ending of superficial caudal epigastric vein (SCEV). A monofilament nylon 10–0–interrupted suture was used for the vascular anastomosis.

In group III, after following the procedure described for group II, the femoral vein was ligated immediately medial to the ending of the SCEV. In group IV, the SCEV was cut from the femoral vein, keeping a 1-mm long ellipse of femoral vein tissue around the ostium. The ostium in the femoral vein was closed with a nylon 10–0 continuous suture. A side-to-end arteriovenous anastomosis between the SCEV and the femoral artery, through a 1-mm-long ostium previously created, was done using nylon 10–0 interrupted suture. Superficial caudal epigastric artery was ligated with nylon 10–0 suture. The patency of anastomosis was confirmed by Flicker test and Milking test.

►Fig. 1 shows the schematic diagram for the study.

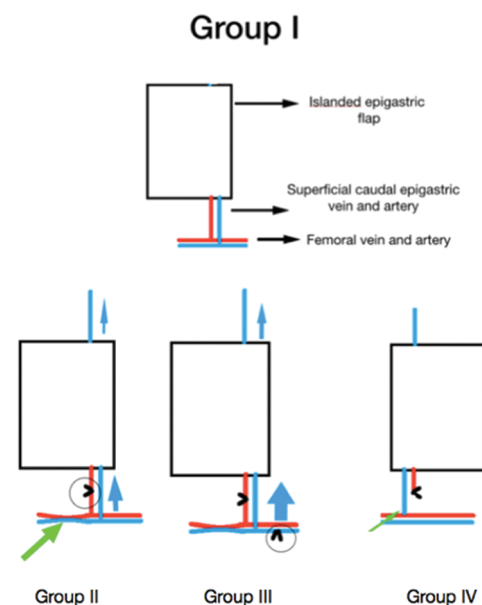


Fig. 1 Showing schematic diagram for the study.

No anticoagulants were administered postoperatively. After surgery, rats were kept in solitary rat cages and offered animal chow and water ad libitum. Flap viability was assessed by noting the color of the flap.

Five days after the surgery, rats were reanaesthetized by the same method and patency of anastomosis was noted. The operative time was noted in for all cases by a blinded observer. Parameters noted were: animal well-being, flap viability, area of ischemia, and presence of complications. Measurement of flap survival was done on the fifth day postoperatively based on digital photographs. Flap survival was expressed as a percentage of the total flap surface area, as shown in ►Fig. 2.

Statistical Analysis

Qualitative variables were expressed as percentages and quantitative variables as means \pm standard deviation (SD).

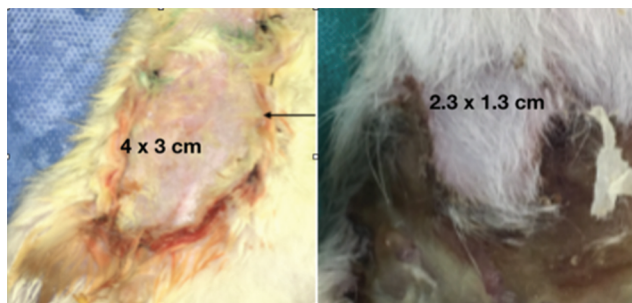


Fig. 2 Showing assessment of flap survival area.

Analysis of variance and *t*-test were used to compare averages in normally distributed data. To compare the data in the groups to each other, analysis of variance and posthoc test were used. A value of $p < 0.05$ was considered to be statistically significant.

Results

Out of 34 rats, four died during the first 48 hours and could not be assessed. Of the remaining 30 rats assessed, 20 were male and 10 female. The weight of the rats ranged from 150 to 200 g. Average weight was 163.87 ± 13.82 g. All procedures were performed by a single operator. The time taken for group I was (24.78 ± 7.95) minutes and (200 ± 14.14) minutes for group IV, which was statistically significant (p value < 0.0005). On comparing the operating time between the groups by using posthoc test, the difference was statistically significant between all groups. The standard deviation and range of data for all four groups has been shown in ►Table 1.

Flap Survival Area

Flap survival was noted on postoperative days one, three, and five. The area of flap that was healthy was taken as flap survival area. The mean and the range have been depicted in ►Table 2. It can be inferred from ►Table 2 that the area of flap survival was almost 100% for all groups on day 1. The flap survival area on day 5 was more in group IV ($65.71 \pm 20.70\%$) as compared with groups II and III. The survival area on day 1 was significantly more than the survival area on day 3

Table 1 Time taken for arterIALIZED venous flap

	n	Mean	Standard deviation	95% confidence interval for mean		Minimum	Maximum
				Lower bound	Upper bound		
Group I	9	27.7778	7.94949	21.6673	33.8883	20.00	45.00
Group II	7	154.29	26.36737	1029.9000	178.6715	120.00	190.00
Group III	7	110.00	12.90994	98.0603	121.9397	90.00	120.00
Group IV	7	200.00	14.14214	186.9207	213.0793	180.00	210.00
Total	30	116.67	68.68636	91.0188	142.3146	20.00	210.00

Table 2 Area of flap survival in postoperative period

		n	Mean	Standard deviation
Area of survival, d1	Group I	9	100	0.00000
	Group II	7	97.1429	7.55929
	Group III	7	97.1429	4.87950
	Group IV	7	100	0.00000
Area of survival, d3	Group I	9	80.0000	11.18034
	Group II	7	59.7143	19.67837
	Group III	7	52.8571	14.96026
	Group IV	7	72.8571	24.97618
Area of survival, d5	Group I	9	78.8889	10.54093
	Group II	7	49.0000	19.92486
	Group III	7	48.5714	16.76163
	Group IV	7	65.7143	20.70197

Table 3 Comparison of area of flap survival among the groups

Dependent variable	(a) Group	(b) Group	Mean difference (a-b)	p value
Area of survival, d1	Group I	Group II	2.85714	0.564
		Group III	2.85714	0.564
		Group IV	0.00000	1.000
	Group II	Group III	0.00000	1.000
		Group IV	-2.85714	0.610
Area of survival, d3	Group I	Group II	20.28571	0.139
		Group III	27.14286 ^a	0.029
		Group IV	7.14286	0.859
	Group II	Group III	6.85714	0.891
		Group IV	-13.14286	0.530
Area of survival, d5	Group I	Group II	29.88889 ^a	0.009
		Group III	30.31746 ^a	0.008
		Group IV	13.17460	0.431
	Group II	Group III	0.42857	1.000
		Group IV	-16.71429	0.279
Group III	Group IV	-17.14286	0.259	

^aThe mean difference is significant at the 0.05 level.

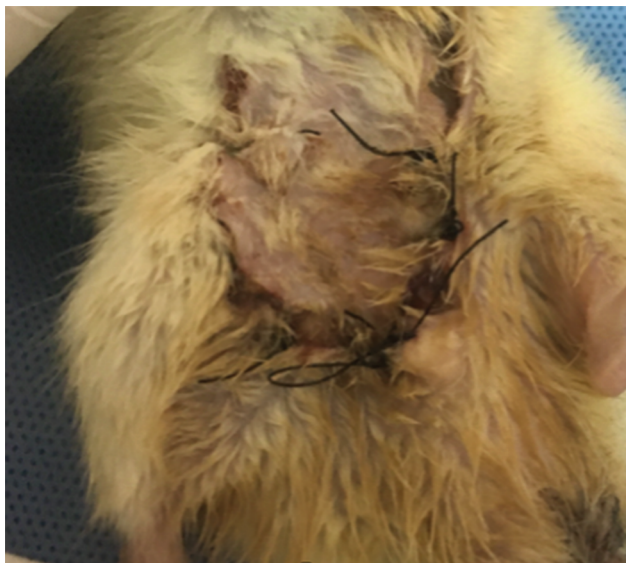


Fig. 3 Showing flap survival area in group I at day 5.

for all groups. Similar difference was also noted between day 1 and day 5 for all groups. The flap survival area on day 1, day 3, and day 5 was compared between the groups, as shown in ► **Table 3**. As seen in the table, the flap survival was not significantly different between groups I and IV on day 5.

► **Figs. 3-6** show postoperative results in various groups on day 5.

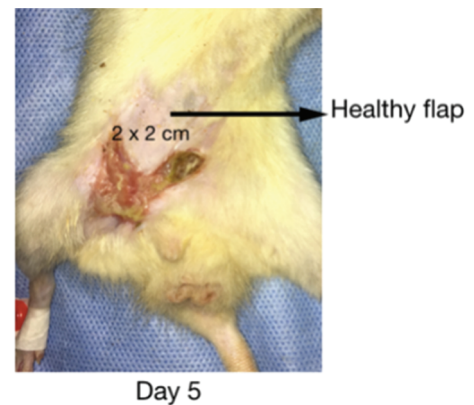


Fig. 4 Showing flap survival area of 30% on day 5.

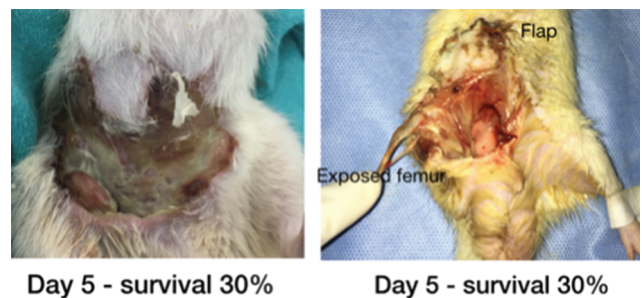


Fig. 5 Showing postoperative result in Group III.

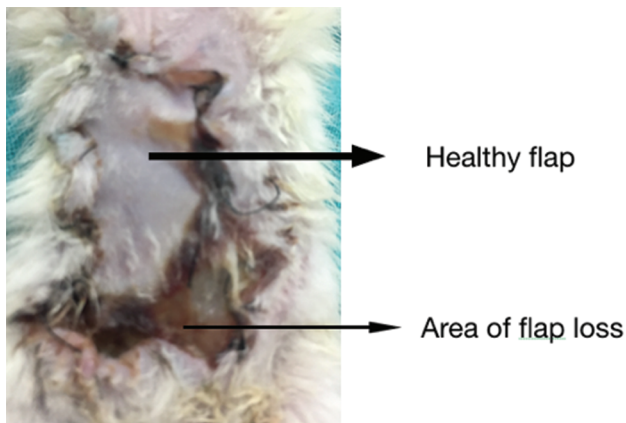


Fig. 6 Showing postoperative result in Group IV.

Patency

On postoperative day 5, patency of the anastomosis was checked by re-elevating the flap. Among the animals that survived till day 5, the patency rates were 100% in group I and group III. Three out of seven rats in group II and one in group IV had partial flap survival despite nonpatent anastomosis. Fibrosis between the flap and underlying muscle was noted but all the vessels were visualized.

Complications in Postoperative Period

In group III, one rat had right lower limb loss following venous congestion of the leg. The leg got autoamputated. No aneurysm was noted in any of the groups. Hematoma was noted on subsequent exploration in three rats, one from group III and two from Group IV, but the anastomoses were patent on removal of hematoma.

Discussion

In the present study, arterialized venous flaps were constructed in two groups, using side-to-side anastomosis (group II, III), and in one using end-to-side anastomosis (group IV). Previously, it has been demonstrated that the results of flaps with end-to-side and side-to-side anastomosis with similar sized arteries are comparable.^{3,4}

Lorenzi et al performed a study on arterialized venous flaps for soft-tissue reconstruction in digits and hands in 40 patients. It was noted that in most of the cases, postoperative flap congestion was present and resolved conservatively by 2 weeks. They reported that partial necrosis rate was 42.5% and total flap necrosis rate of 7.5%. Superficial epidermolysis occurred in 17.5% of flaps.⁵ Inoue et al noted failure rates as high as 50% in their 15 patients.⁶ However, in a systematic review of arterialized venous flaps, the survival rate was 97% with 5.5% having complete flap necrosis. The study also reported that the survival area in clinical contexts ranged from 87% to 91%.⁷ However, this estimation may be affected by several biases associated with any meta-analysis, such as publication bias, which tends to overestimate positive outcomes. In the present study, flap survival was maximum in group I with conventional islanded flap. Among

the venous flaps, flap survival area was maximum in Group IV (65.71%). There were no cases of total flap failure. In a similar study conducted by Casal et al, the flap survival area were 98.89 ± 1.69 , 68.84 ± 7.36 , 63.84 ± 10.38 , $76.86 \pm 13.67\%$ in Group I, II, III and IV, respectively.² This is inferior in comparison to previous studies. In the study conducted, lateral thoracic vein was preserved in group I. The area of flap survival was studied on day one, three, and five. The difference in flap survival area was not statistically significant between day 3 and day 5. It can be inferred that the area of necrosis was demarcated on day 3. This finding was supported by other studies.⁸

Due to high technical difficulty in group IV and smaller size of superficial caudal epigastric vessels as compared with femoral vessels, the operating time was maximum in group IV. Similar results were observed in a similar study conducted in 52 rats by Casal et al.²

A previous study noted the effect of vein size on flap inflow and outflow. It was reported that the arteriovenous flap survival was more in the group with smaller vein used for inflow as compared with when a larger vein was used.⁸ In the present study, in agreement, the flap survival area was more in group IV as compared with groups II and III. This group had rats with SCEV as inflow as compared with group II and III with femoral vein as inflow. The size of vessel may also affect the flap survival.

On postoperative day 5, flaps were lifted again, and patency of anastomosis was checked using Flicker and milking tests. Out of 30, 26 (86%) anastomoses were patent. In four cases, the anastomoses were not patent. However, the flap survival area ranged from 30 to 33% in these animals. The flap necrosis was noted more in the distal part in all cases. In a previous study with similar model, one animal in Group IV had arteriovenous thrombosis. The authors did not comment on the area of survival of flap.² It has been well proven by various studies that retrograde flow plays a role in survival of venous flaps.⁹ The presence of flap survival along the proximal part of flap may be due to retrograde flow from lateral thoracic vein.

Various techniques have been used to construct arterialized venous flaps. The retrograde flow and arteriovenous fistulas have also been studied. Voukidis et al conducted an experimental study and created arteriovenous fistula of femoral artery and vein using end-to-side anastomosis technique. Patency of fistula was checked. A total of 20 to 25 days later, the superficial caudal epigastric artery was ligated. When a thoracoabdominal flap of 9×4 cm was then raised, it was noted that all flaps survived.¹⁰ This study signifies that early creation of arteriovenous fistula helps in venous flap survival.

Limitations

As this was an animal study, it is difficult to implement the results in humans. The difference in size of vessels and flap anatomy may affect the flap survival area. The epigastric flap in rats is raised just above the panniculus carnosus. In the deep aspect of integument, panniculus carnosus has been

noted to cause wound contraction in loose-skinned animals.¹¹ This might also affect the size of flap in the postoperative period. Since this contraction is not seen in humans, the results might vary. Additionally, the sample size of the study was small.

Clinical Implications

Arterialized venous flaps spare the main artery of the limb and provide a durable and pliable cover. In case of digits and ischemic lower limbs with single functioning vessel, arterialized venous flaps add to the options of reconstruction. The donor site morbidity is also minimal.

Conclusion

It was noted that epigastric venous flaps with end-to-side anastomosis between femoral artery and SCEV (group IV) have survival area comparable to islanded flaps. Initially, venous congestion was present in most of the cases but no case of total flap necrosis was noted.

Conflicts of Interest

None declared.

References

- 1 Yan H, Fan C, Zhang F, Gao W. Arterialized Venous Flaps in Reconstructive and Plastic Surgery. Available at: <https://www.intechopen.com/books/arteriovenous-fistulas-diagnosis-and-management/arterialized-venous-flaps-in-reconstructive-and-plastic-surgery>. Accessed January 19, 2021
- 2 Casal D, Mota-Silva E, Pais D, et al. Optimization of an arterialized venous fasciocutaneous flap in the abdomen of the rat. *Plast Reconstr Surg Glob Open* 2017;5(8):e1436
- 3 Nakano A, Komai Y, Seki J, Quintos R, Niimi H. Microvascular hemodynamic responses to arteriovenous shunting in rat limb. *Clin Hemorheol Microcirc* 2005;33(1):29–39
- 4 Miyamoto S, Takushima A, Okazaki M, Ohura N, Minabe T, Harii K. Relationship between microvascular arterial anastomotic type and area of free flap survival: comparison of end-to-end, end-to-side, and retrograde arterial anastomosis. *Plast Reconstr Surg* 2008;121(6):1901–1908
- 5 De Lorenzi F, van der Hulst RR, den Dunnen WF, et al. Arterialized venous free flaps for soft-tissue reconstruction of digits: a 40-case series. *J Reconstr Microsurg* 2002;18(7):569–574, discussion 575–577
- 6 Inoue G, Tamura Y, Suzuki K. One-stage repair of skin and tendon digital defects using the arterialized venous flap with palmaris longus tendon: an additional four cases. *J Reconstr Microsurg* 1996;12(2):93–97
- 7 Casal D, Cunha T, Pais D, et al. Systematic review and meta-analysis of unconventional perfusion flaps in clinical practice. *Plast Reconstr Surg* 2016;138(2):459–479
- 8 Pittet B, Quinodoz P, Alizadeh N, Schlaudraff KU, Mahajan AL. Optimizing the arterialized venous flap. *Plast Reconstr Surg* 2008;122(6):1681–1689
- 9 Iglesias M, Fonseca-Lazcano JA, Moran MA, Butron P, Díaz-Morales M. Revascularization of arterialized venous flaps through a total retrograde reverse blood flow: randomized experimental trial of viability. *Plast Reconstr Surg Glob Open* 2013;1(5):e34
- 10 Voukidis T. An axial-pattern flap based on the arterIALIZED venous network: an experimental study in rats. *Br J Plast Surg* 1982;35(4):524–529
- 11 Dunn RM, Mancoll J. Flap models in the rat: a review and reappraisal. *Plast Reconstr Surg* 1992;90(2):319–328