



Quadriceps Tendon: Option in Knee Ligament Reconstruction

Tendão quadriceps: Opção na reconstrução ligamentar do joelho

Edmar Stieven Filho¹ Maisa Sayuri Namba² Isabela do Prado Nascimento³
Fernando Martins Rosa⁴ Mario Massatomo Namba⁵

¹ Department of Orthopedics and Traumatology, Universidade Federal do Paraná, Curitiba, PR, Brazil

² Department of Orthopedics and Traumatology, Complexo Hospitalar do Trabalhador, Curitiba, PR, Brazil

³ Department of Medicine, Universidade Federal do Paraná, Curitiba, PR, Brazil

⁴ Department of Surgery, Universidade Federal do Paraná, Curitiba, PR, Brazil

⁵ Hospital de Clínicas, Universidade Federal do Paraná, Curitiba, PR, Brazil

Address for correspondence Edmar Stieven, PhD Professor of Orthopedics and Traumatology - Universidade Federal do Paraná, Department of Surgery - Orthopedics and Traumatology, Rua General Carneiro, 181. Alto da Glória, Curitiba, Paraná, 80060-900, Brazil (e-mail: filho2000@gmail.com).

Rev Bras Ortop 2022;57(1):180–184.

Abstract

Although it is a versatile tendon, only 1% of surgeons choose to use the quadriceps tendon as a graft in anterior cruciate ligament (ACL) reconstruction. The present article aims to describe a quadriceps graft removal technique in which its deepest part is maintained. The technique consists of an approach in which the first incision is made in the medial part of the quadriceps tendon to prevent it from getting too short. This is due to its triangular design. The technique also addresses the depth and identification of the three layers of the quadriceps tendon so that it is possible to preserve its deepest part. This approach aims to preserve the extensor apparatus and to not communicate it with the joint environment, avoiding fluid extravasation both in the trans and postoperative periods.

Keywords

- ▶ grafts
- ▶ orthopedics
- ▶ anterior cruciate ligament

Resumo

Ainda que seja um tendão versátil, apenas 1% dos cirurgiões optam por utilizar o tendão quadriceps como enxerto na reconstrução do ligamento cruzado anterior (LCA). O presente artigo tem o objetivo de descrever uma técnica de retirada do enxerto quadriceps na qual a sua porção mais profunda é mantida. A técnica consiste em uma abordagem na qual a primeira incisão é feita na porção medial do tendão quadriceps para evitar que ele fique muito curto. Isso acontece devido ao seu desenho triangular. A técnica também aborda a profundidade e a identificação das três camadas do tendão quadriceps para que seja possível preservar sua porção mais profunda. Esta conduta tem o objetivo de uma maior preservação do aparelho extensor e de não haver comunicação com o meio articular, evitando extravasamento de líquido tanto no trans- quanto no pós-operatório.

Palavras-chave

- ▶ enxertos
- ▶ ortopedia
- ▶ ligamento cruzado anterior

Work developed in the Department of Surgery - Orthopedics and Traumatology, Universidade Federal do Paraná, Curitiba, PR, Brazil.

received
August 17, 2020
accepted
December 1, 2020
published online
August 13, 2021

DOI <https://doi.org/10.1055/s-0041-1726069>.
ISSN 0102-3616.

© 2021. Sociedade Brasileira de Ortopedia e Traumatologia. All rights reserved.

This is an open access article published by Thieme under the terms of the Creative Commons Attribution-NonDerivative-NonCommercial-License, permitting copying and reproduction so long as the original work is given appropriate credit. Contents may not be used for commercial purposes, or adapted, remixed, transformed or built upon. (<https://creativecommons.org/licenses/by-nc-nd/4.0/>)

Thieme Revinter Publicações Ltda., Rua do Matoso 170, Rio de Janeiro, RJ, CEP 20270-135, Brazil

Introduction

Due to its high incidence in the economically active population, there is great interest in the advances of surgical techniques of anterior cruciate ligament (ACL) reconstruction, including the grafts used.¹ Despite the advances, it is estimated that ~25% of patients progress with failure in the 10 years following primary surgery, either due to graft rupture or clinical failure; therefore, many of them undergo new surgery, requiring a second graft.^{2,3}

Considered by some authors as the "forgotten graft", the quadriceps muscle tendon is versatile and can be used with or without a bone plug in ligament reconstruction.⁴ Its advantages include favorable clinical response and low morbidity of the donor site, especially when it is removed without the bone plug. Complications such as fluid extravasation during arthroscopy, muscle gap, retraction of the femoral rectum, aesthetic deformity, and hematoma at the graft site may occur.⁵

Although it is a versatile tendon, only 1% of surgeons choose to use the quadriceps tendon as a graft in ACL reconstruction due to nonfamiliarity with graft removal techniques and lack of specific instrumentation.^{4,5}

The present article aims to describe a quadriceps graft removal technique in which the deepest layer, composed of the vastus intermediae, is maintained.

Technical Description

The present study was approved by the Research Ethics Committee through opinion 35471420.2.0000.5225.

Surgical Technique

Step 1: Patient Preparation and Positioning

The patient is put in the supine position, usually under spinal anesthesia. The knee is positioned at 90°. After emptying the

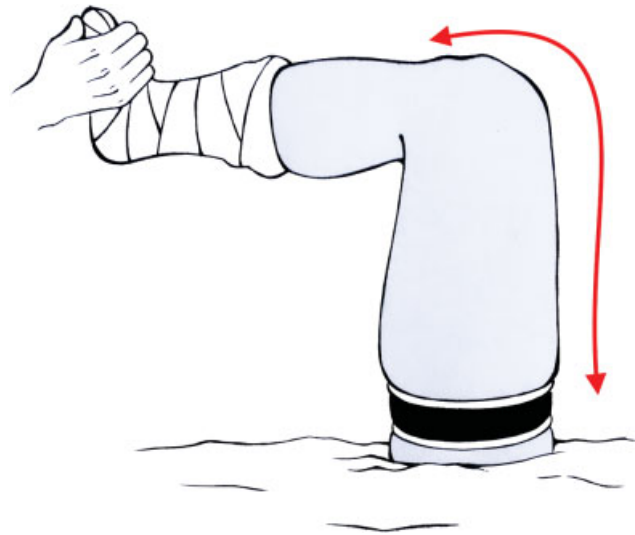


Fig. 1 Knee 90° position.

limb with Esmarch bandage, the garrote is inflated (→ **Figure 1**).

Step 2: Subcutaneous Access and Dissection

The center of the patella is used as a reference in the access of the skin, which starts from the center in the proximal direction, of approximately between 4 and 5 cm. Dissection of soft tissues and subcutaneous tissue is performed with the aid of a scalpel and a rugine.

Step 3: Graft Removal

After access, the incision in the graft is started by the medial portion, at between 3 and 5 mm lateral to the myotendinous transition from the proximal vastus medial of the oblique vastus to the proximal pole of the patella (→ **Figure 2**).

The second incision in the tendon is made at 10 mm lateral to the first incision, determining the width of the graft.

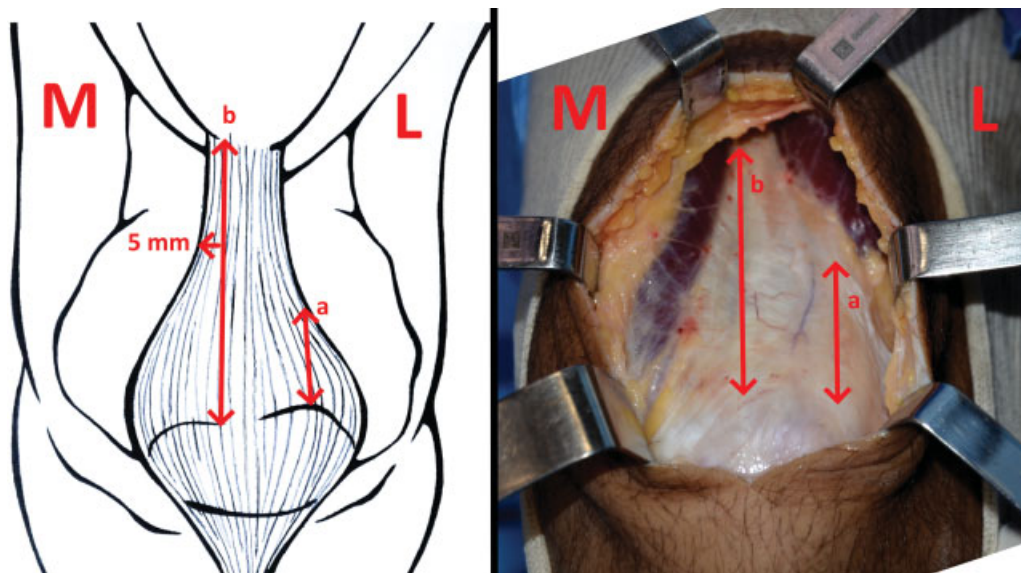


Fig. 2 First incision in the quadriceps tendon, 3 to 5 mm of the medial myotendine (a. short graft; b. ideal graft). M - medial, L- lateral.

The tendon is dissected carefully, observing its layers. The first layer is that of the femoral rectum. When dissecting it, it is possible to observe a lamina of adipose tissue by separating it from the confluence of the vastus medial and lateral. Then, the scalpel is deepened below the fat and the medial and lateral vastus sections. Below that, as the third layer, is the vast intermediate and, in this technique, we intend to preserve it. To aid the measurement of the depth of the first two layers, the highest cutting of the blade of a scalpel number 23 can be a parameter, as it measures ~ 5 mm. This is the approximate depth of the surface of the quadricipital tendon to the beginning of the third layer, the vast intermediate (\rightarrow Figure 3).

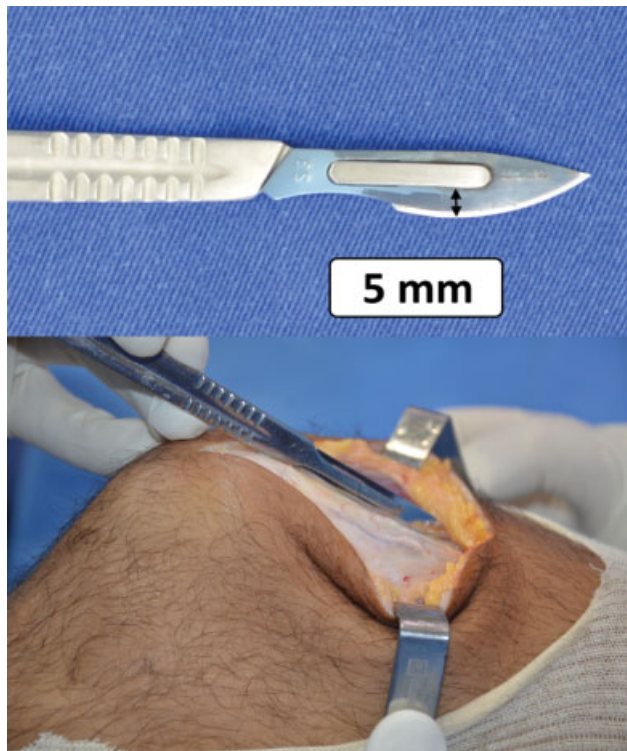


Fig. 3 Number 23 scalpel, inserted in the quadricipital tendon, with a depth of 5 mm.

After the depth is defined, a Kelly-type hemostatic forceps is positioned transversely 3 cm above the proximal pole of the patella, separating the intact vastus intermediate from the rest of the quadriceps. The tweezers can be forced proximally and distally to assist in dissection (\rightarrow Figure 4).

Once the cutting layer is defined, the dissection to the proximal and distal can be done bluntly, forcing the Kelly forceps itself or with a cutting tool. Usually, we prefer to perform proximal dissection with metzenbaum scissors and dissection to the bone plug with scalpel.

We usually use electric cautery for marking the bone plug, and we prefer a small baguette (15 mm long and 10 mm wide). Before performing the side cuts, the middle of the plug is drilled with a 3.5 mm drill for passage of the anchor suture.

The cuts are made with an oscillatory saw with an angle of 45° , in order to remove a trapezoidal plug. Distally, the cut is straight, at 90° . After the use of the saw, with a narrow osteotome, the bed plug is highlighted. Since the quadricipital tendon involves the entire thickness of the patella, after loosening the bone block, it is common for it to remain attached by the tendon (\rightarrow Figure 5).

To loosen the graft, this transition is carefully dissected so as not to pierce the vastus intermediate and expose the joint, in addition to preventing the graft from falling.

Step 4: Graft Preparation

The tendinous part of the graft is prepared with Krackov-like stitches, with polyester thread number two. The bone plug is prepared by seaming edges to create a bone tunnel of smaller diameter. A polyester number five thread is passed through the hole in the bone plug for traction.

Step 5: Closing

Bed inspection is performed to verify that there was no violation of the suprapatellar bursa; if it occurred, a simple suture with polyglycolic acid number one thread is performed.

The arthroscopic procedure is performed before skin closure, because if there is liquid extravasation, it is possible to locate the drainage site by direct visualization and close the hole.

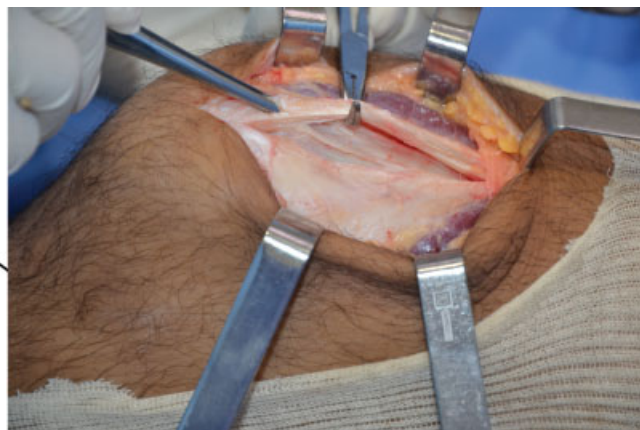



Fig. 4 Quadricipital tendon – vastus intermediate preserved, while the rectum and vastus medial and lateral are repaired by surgical forceps.

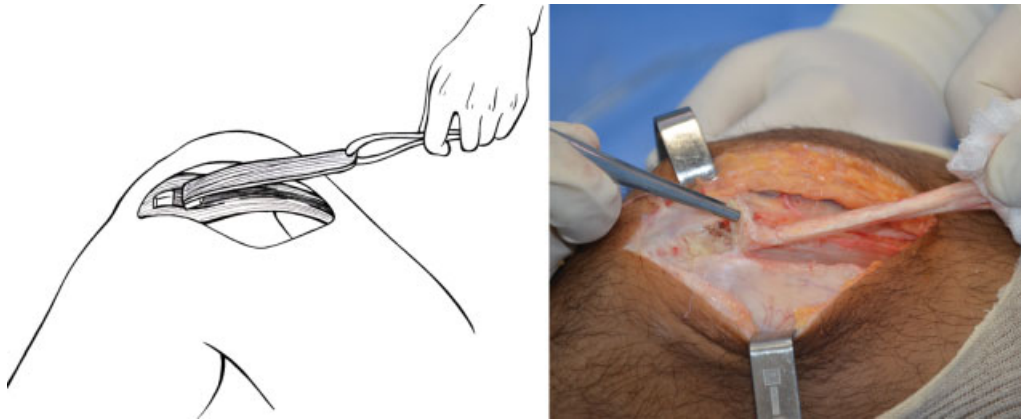


Fig. 5 Quadriceps graft and bone plug. In the photo, it is possible to observe the patella still attached to the quadricipital tendon.

The garrote is turned off and inspection and hemostasis are carried out.

Patella defect correction is not performed, neither is the approach of the edges of the quadricipital tendon, since the deepest part of the vastus intermediae has been preserved.

Discussion

When preparing and positioning the patient, it is important that, when inflating the garrote, the knee is frailled at 90° in order to keep the quadriceps muscle in its greatest distension, which will keep the quadriceps tendon under lower tension for graft removal.⁶ For the removal of grafts from the flexor tendons, the opposite is performed: the garrote is inflated with the knee extended (→ **Figure 1**).

Differently from the descriptions that initiate the removal of the quadricipital graft by the bone block,⁷ we consider essential that the first incision is in the quadricipital tendon. We started with a linear incision, parallel to the tendon, 3 to 5 millimeters lateral to the myotendinous region of the vastus medial. The reason we insist on this point is that the quadricipital graft is triangular and its medial portion is more parallel to the femur than the lateral one. Thus, we are careful not to place the incision too lateral, as this would result in a very short graft (→ **Figure 2**).

There is a thin layer of adipose tissue that separates the femoral rectum from the vastus intermediae, and it is easier to separate the femoral rectum from the second layer than the second from the third. Since we are proposing a technique in which there is a preservation of the last layer of the quadricipital tendon, it is necessary to deepen the incision beyond the division of the femoral rectum with the second layer. Thus, the thickness of the tendon is increased and the vastness of the intermediae is preserved. This step is not always simple, as there is a tendency to stop after the femoral rectum.

After the removal of the tendon and the garrote, we consider important to inspect for communication with joint media and to evaluate hemostasis. This is especially important in cases of intra-articular surgeries, as this

communication can cause a large hematoma in the quadriceps postoperatively.⁵ This type of hematoma is painful and hinders rehabilitation. Therefore, close the skin and subcutaneous at the end of the procedure, because if there are signs of fluid outflow during surgery, it can be closed.

Ferrer et al.⁸ performed a computed tomography (CT) study to verify the pattern of the patellae that suffered fracture after the removal of the quadricipital tendon graft. Fractures are more common in cases in which the block was removed more laterally and when it exceeds more than 30% of the thickness of the patella. This reinforces our thinking of keeping the first incision close to the vast medial. We also believe that a small baguette is enough to perform most procedures that require this type of graft.

Final Considerations

The onset of the incision 5 mm lateral to the medial myotendinea region can prevent the removal of a short graft.

It is possible to remove two of the three layers of the quadricipital graft preserving part of the extensor apparatus and obtain an adequate graft.

Financial Support

There was no financial support from public, commercial, or non-profit sources.

Conflict of Interests

The authors have no conflict of interests to declare.

References

- 1 Barié A, Köpf M, Jaber A, et al. Long-term follow-up after anterior cruciate ligament reconstruction using a press-fit quadriceps tendon-patellar bone autograft. *BMC Musculoskelet Disord* 2018;19(01):368
- 2 Condello V, Zdanowicz U, Di Matteo B, et al. Allograft tendons are a safe and effective option for revision ACL reconstruction: a clinical review. *Knee Surg Sports Traumatol Arthrosc* 2019;27(06):1771–1781

- 3 Crawford SN, Waterman BR, Lubowitz JH. Long-term failure of anterior cruciate ligament reconstruction. *Arthroscopy* 2013;29(09):1566–1571
- 4 van Eck CF, Illingworth KD, Fu FH. Quadriceps tendon: the forgotten graft. *Arthroscopy* 2010;26(04):441–442, author reply 442–443
- 5 Slone HS, Romine SE, Premkumar A, Xerogeanes JW. Quadriceps tendon autograft for anterior cruciate ligament reconstruction: a comprehensive review of current literature and systematic review of clinical results. *Arthroscopy* 2015;31(03):541–554
- 6 DeAngelis JP, Fulkerson JP. Quadriceps tendon—a reliable alternative for reconstruction of the anterior cruciate ligament. *Clin Sports Med* 2007;26(04):587–596
- 7 Fulkerson JP, Langeland R. An alternative cruciate reconstruction graft: the central quadriceps tendon. *Arthroscopy* 1995;11(02):252–254
- 8 Ferrer GA, Miller RM, Murawski CD, et al. Quantitative analysis of the patella following the harvest of a quadriceps tendon autograft with a bone block. *Knee Surg Sports Traumatol Arthrosc* 2016;24(09):2899–2905