



Childhood Varicose Veins—An Unusual Visceral “May–Thurner” Like Compression

Sreenivasa Narayana Raju¹ Rengarajan Rajagopal¹ Niraj Nirmal Pandey¹ Amarinder Singh¹
Sanjeev Kumar¹

¹Department of Cardiovascular Radiology and Endovascular Interventions, All India Institute of Medical Sciences, New Delhi, India

Address for correspondence Sanjeev Kumar, MD, Department of Cardiovascular Radiology and Endovascular Interventions, All India Institute of Medical Sciences, New Delhi 110029, India (e-mail: sanjeevradio@gmail.com).

J Clin Interv Radiol ISVIR 2021;5:190–192.

Abstract

Keywords

- ▶ May–Thurner syndrome
- ▶ congenital ectopic kidney
- ▶ common iliac vein compression

We report the case of 8-year-old girl with left lower limb edema due to superficial venous incompetence and varicosities. Color Doppler demonstrated compression of the left common iliac vein by an ectopic left kidney, which was partly relieved in right lateral decubitus position. CT demonstrated ectopic malrotated pelvic kidney, compressing the left common iliac vein against the L5 vertebra. A “May–Thurner” like syndrome due to visceral compression needs to be suspected in children with unilateral left lower limb varicosities.

Introduction

Incidence of superficial venous disease in children has been estimated to be very low (0.2% to 2.9%), with physiologic venous reflux seen in up to 13% of adolescents.¹ Deep vein thrombosis (DVT) and Klippel–Trenaunay syndrome are common causes of childhood lower extremity superficial venous insufficiency.² Causes of venous compression due to enlarged lymph nodes, mass lesions, and by abnormal location of normal visceral organs like ectopic kidneys, which are uncommon in adults, are more common in children and may cause lower limb edema with a “May–Thurner” like presentation. We describe the case of an 8-year-old girl with such a “May–Thurner” like syndrome caused by compression due to ectopic left kidney, leading to left lower limb varicosities along with review of relevant literature.

Case Report

An 8-year-old girl presented with insidious onset of painless left lower limb edema, which was prominent during early morning for 2 years. Clinical examination showed a thin built child with nontender edematous left leg. No other superficial swellings or cutaneous vascular malformations were seen.

Color Doppler evaluation showed reflux in the common femoral vein, with incompetence of saphenofemoral junction, leading to dilatation of great saphenous vein and multiple subcutaneous varicosities. No findings of thrombosis or vascular malformations were seen in both legs.

Further evaluation of this child with abdominal ultrasound revealed an ectopic left pelvic kidney, causing compression of the proximal left common iliac vein (CIV) in supine position. (▶ **Fig. 1A**) The compression on the CIV was relieved when the child was positioned in right lateral decubitus position. However, incompetence at the saphenofemoral junction persisted. CT examination confirmed significant extrinsic compression of the left CIV (▶ **Fig. 1B, C**) by the ectopic malrotated left pelvic kidney against the L5 vertebra close to its confluence with the right CIV, with multiple varicosities in the medial aspect of the left leg (▶ **Fig. 1D**).

Extrinsic compression of the left CIV secondary to ectopic kidney is exceedingly rare, and has been reported more commonly in older patients with transplanted kidneys in the iliac fossa.³ Vascular compression leading to superficial venous disease is less common as compared with iliac vein thrombosis, which is more commonly seen in these patients with transplanted kidneys.⁴

published online
August 3, 2021

DOI <https://doi.org/10.1055/s-0041-1728993>
ISSN 2457-0214

© 2021. Indian Society of Vascular and Interventional Radiology.
This is an open access article published by Thieme under the terms of the Creative Commons Attribution-NonDerivative-NonCommercial-License, permitting copying and reproduction so long as the original work is given appropriate credit. Contents may not be used for commercial purposes, or adapted, remixed, transformed or built upon. (<https://creativecommons.org/licenses/by-nc-nd/4.0/>).
Thieme Medical and Scientific Publishers Pvt. Ltd. A-12, 2nd Floor, Sector 2, Noida-201301 UP, India

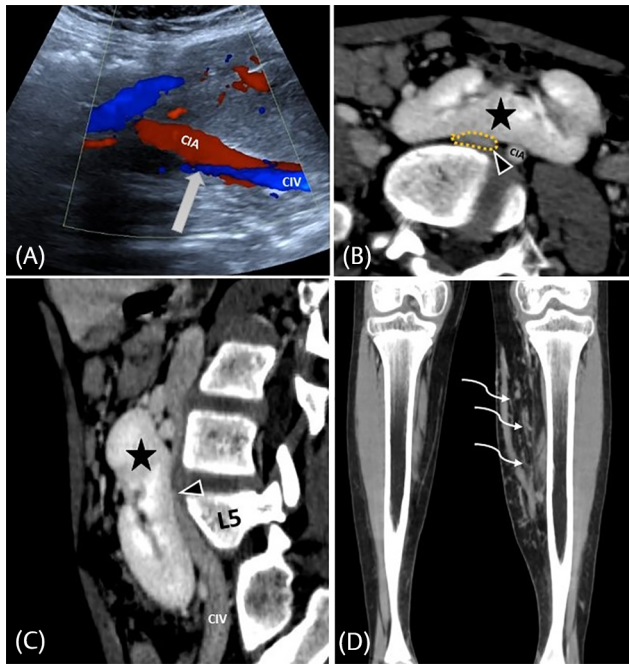


Fig. 1 (A) Abdominal ultrasound with color Doppler revealed an ectopic left pelvic kidney, causing compression of the proximal left common iliac vein (CIV) (white solid arrow) in supine position. (B, C) Computed tomography axial and sagittal sections confirmed significant extrinsic compression of the left CIV (yellow dotted line) (B, C) by the ectopic malrotated left pelvic kidney (black star) against the L5 vertebra. (D) Coronal computed tomography sections showing varicose veins in the medial aspect of the left leg (curved white arrows).

Discussion

Ectopic pelvic kidneys are rare variants seen in approximately 1 in 3000 individuals, more commonly involving the left side. Although patients with pelvic kidneys are mostly

asymptomatic, reflux uropathy and ureteropelvic junction obstruction are commonly associated complications.⁵ May–Thurner syndrome is typically caused by extrinsic compression of the left CIV by the right common iliac artery, leading to obstruction of venous flow, venous insufficiency and, later, deep vein thrombosis secondary to formation of mural spur and other intimal abnormalities at the site of the venous compression.⁶ Venous compression by pelvic kidneys has been reported previously in patients presenting with left lower limb deep vein thrombosis (DVT) (– **Table 1**). An ectopic pelvic kidney can also cause dynamic venous compression, with partial relief of compression in lateral decubitus position. Patients with May–Thurner syndrome are usually managed by medical anticoagulant therapy for DVT, thrombolysis or thrombectomy, followed by left iliac vein stenting.⁹ Endovenous laser ablation followed by postprocedural compression stockings for 6 weeks has been successfully used in treatment of varicose veins in children aged 13 to 16 years¹⁰. There is little clarity on the management of children with symptoms of iliac vein compression due to ectopic kidney, as it is rare and only isolated case reports can be found in literature. Our patient has been advised conservative management with class II compression stockings and yearly surveillance; the patient is doing well on 18 months follow-up.

Conclusion

In conclusion, children with superficial venous disease should be evaluated to rule out extrinsic compression by enlarged lymph nodes, mass lesions, and malpositioned solid organs. Doppler ultrasound and cross-sectional imaging may be necessary to demonstrate the venous compression. Management of these children is decided on a case-to-case basis due to the absence of large cohort studies.

Table 1 Reported cases of May–Thurner-like syndrome due to compression by ectopic kidney in literature

Author	Age and Sex	History	Imaging	Treatment
Eng et al ⁷	17 y, M	Pain, swelling and discoloration of the left lower limb	Doppler–DVT of the left iliofemoral vein MRV–Ectopic left kidney compressing the left common iliac vein	Medical treatment for DVT with no surgical intervention
Sahnan et al ⁸	87 y, F	Decreased mobility, lower respiratory tract infection and acute kidney injury	Doppler–DVT of the left common iliac, external iliac vein and common femoral vein. CT venogram–compression of the left common iliac vein by calcified left common iliac artery and osteophyte and ectopic pelvic left kidney, contributing to the compression	Medical treatment for DVT with no surgical intervention
Vittore et al ⁴	43 y, F	Recurrent episodes of DVT after gastric bypass surgery for obesity	Transverse mobility of the left pelvic kidney as revealed by interval imaging between prior CT, followed by MR venography, with ectopic left kidney compressing the left common iliac vein	Medical treatment with anticoagulation and considering stenting of left CIV

Abbreviations: CIV, common iliac vein; DVT, deep vein thrombosis; MRV, magnetic resonance venography.

Conflict of Interest

None declared.

References

- 1 Schultz-Ehrenburg U, Reich-Schupke S, Robak-Pawelczyk B, et al. Prospective epidemiological study on the beginning of varicose veins. *Phlebologie* 2009;38(1):17–25
- 2 Andraska EA, Horne DC, Campbell DN, Eliason JL, Wakefield TW, Coleman DM. Patterns of pediatric venous disease. *J Vasc Surg Venous Lymphat Disord* 2016;4(4):422–425
- 3 Koster-Kamphuis L, Die CE, der Vliet JA, Monnens L. Early transient leg swelling at the side of renal transplant in two children. *Pediatr Transplant* 2006;10(1):112–113
- 4 Vittore CP, Murray RA. Transverse mobility of pelvic kidney causing left lower extremity deep venous thrombosis. *Radiol Case Rep* 2017;12(2):285–286
- 5 Stevens AR. Pelvic single kidneys. *J Urol* 1937;37(5):610–618
- 6 Gleason PE, Kelalis PP, Husmann DA, Kramer SA. Hydronephrosis in renal ectopia: incidence, etiology and significance. *J Urol* 1994;151(6):1660–1661
- 7 Eng JM, Walor DM, Michaels LA, Weiss AR. An unusual presentation of May-Thurner syndrome in a pediatric patient with a pelvic kidney. *J Pediatr Urol* 2013;9(1):e72–e75
- 8 Sahnun K, Yee CPY, Thomas RH, Sritharan K. A rare case of May-Thurner-like syndrome in an elderly lady. *Case Rep Intern Med* 2014;1(2):19–24
- 9 Patel NH, Stookey KR, Ketcham DB, Cragg AH. Endovascular management of acute extensive iliofemoral deep venous thrombosis caused by May-Thurner syndrome. *J Vasc Interv Radiol* 2000;11(10):1297–1302
- 10 Patel PA, Barnacle AM, Stuart S, Amaral JG, John PR. Endovenous laser ablation therapy in children: applications and outcomes. *Pediatr Radiol* 2017;47(10):1353–1363