



# Correlation between Intensity of Pain and Disability Due to Intra-articular Lesions in Patients with Femoroacetabular Impingement Syndrome

## *Correlação entre intensidade da dor e incapacidade com as lesões intra-articulares em pacientes com síndrome do impacto femoroacetabular*

Giancarlo Cavalli Polesello<sup>1</sup> Nayra Deise Anjos Rabelo<sup>2</sup> João Tomás Fernandes Castilho Garcia<sup>3</sup>   
Walter Ricioli Junior<sup>1</sup> Marco Rudelli<sup>1</sup> Marcelo Cavalheiro de Queiroz<sup>1</sup>

<sup>1</sup>Hip Group, Department of Orthopedics and Traumatology, Faculdade de Ciências Médicas, Santa Casa de Misericórdia de São Paulo (FCMSCSP), São Paulo, SP, Brazil

<sup>2</sup>Núcleo de Apoio à Pesquisa em Análise do Movimento (NAPAM), Universidade Nove de Julho, São Paulo, SP, Brazil

<sup>3</sup>Medical Residency, Department of Orthopedics and Traumatology, Santa Casa, São Paulo, SP, Brazil

Address for correspondence Giancarlo Cavalli Polesello, M.D, Ph.D., Adjunct professor and head of the hip group, Departamento de Ortopedia e Traumatologia da Santa Casa de São Paulo, "Pavilhão Fernandinho Simonsen", Sala do Grupo do Quadril (2° andar), Rua Dr. Cesário Motta Junior, 112, Bairro Vila Buarque, São Paulo, SP, 01221-020, Brazil (e-mail: giancarlopolesello@hotmail.com).

Rev Bras Ortop 2022;57(5):836–842.

### Abstract

**Objective** To correlate radiographic alterations and lesions in intra-articular structures of the acetabulum with the intensity of pain and disability of patients diagnosed with femoroacetabular impingement syndrome.

**Methods** A retrospective analysis of the preoperative data of 182 patients (190 hips) was performed. Clinical variables such as age, gender, the practice of physical activity, and radiographic variables, such as the Wiberg and alpha angles, were evaluated. Through an intraoperative video, the extent of the chondral and labial lesions was evaluated considering the clock-face method, the degree of joint involvement by the Outerbridge classification, and the presence of wave lesions. The variables were analyzed by linear regression, with the intensity of the pain assessed by the Visual Analog Scale (VAS), and functional disability measured by the Modified Harris Hip Score (mHHS).

**Results** The mean age of the patients was of  $38.5 \pm 9.6$  years, the mean intensity of the pain was of  $7.8 \pm 1.6$ , and the mean mHHS score was of  $56.3 \pm 12.7$ . In total, 61% of the sample were classified as Outerbridge III or IV, and 12.6% had wave lesions. There was a correlation between the male gender ( $r = 0.497$ ) and lower intensity of the pain,

### Keywords

- ▶ femoroacetabular impingement
- ▶ arthroscopy
- ▶ pain
- ▶ hip

\* Study developed in the Hip Group of the Department of Orthopedics and Traumatology, Faculty of Medical Sciences Santa Casa de Misericórdia de São Paulo (FCMSCSP), São Paulo, SP, Brazil.

received  
July 22, 2020  
accepted  
November 3, 2020  
published online  
January 21, 2022

DOI <https://doi.org/10.1055/s-0041-1729573>  
ISSN 0102-3616.

© 2022. Sociedade Brasileira de Ortopedia e Traumatologia. All rights reserved.

This is an open access article published by Thieme under the terms of the Creative Commons Attribution-NonDerivative-NonCommercial-License, permitting copying and reproduction so long as the original work is given appropriate credit. Contents may not be used for commercial purposes, or adapted, remixed, transformed or built upon. (<https://creativecommons.org/licenses/by-nc-nd/4.0/>)

Thieme Revinter Publicações Ltda., Rua do Matoso 170, Rio de Janeiro, RJ, CEP 20270-135, Brazil

and a correlation of age ( $r = -0.27$ ), the male gender ( $r = 8.419$ ) and physical activity with higher functional scores on the mHHS ( $r = 4.729$ ).

**Conclusion** There was no correlation of the radiographic and arthroscopic parameters of the present study and the intensity of pain and the disability of the patients. The male gender is related to lower intensity of pain, and higher functional ability is related to the male gender, lower age, and the practice of physical activity.

**Level of Evidence IV.**

## Resumo

**Objetivo** Correlacionar alterações radiográficas e lesões de estruturas intra-articulares do acetábulo com a intensidade da dor e a incapacidade de pacientes com diagnóstico de síndrome do impacto femoroacetabular.

**Métodos** Realizou-se uma análise retrospectiva de dados pré-operatórios de 182 pacientes (190 quadris). Foram avaliadas variáveis clínicas como idade, sexo e prática de atividade física, e variáveis radiográficas, como ângulo de Wiberg e o ângulo alfa. Por meio do vídeo intraoperatório, foi avaliada a extensão das lesões condrais e labiais considerando-se o método *clock-face*, o grau de comprometimento articular pela classificação de Outerbridge, e a presença de lesão em onda. As variáveis foram analisadas por meio de regressão linear, tendo como variáveis dependentes a intensidade da dor, avaliada pela Escala Visual Analógica (EVA), e a incapacidade funcional, mensurada pelo Harris Hip Score modificado (HHSm).

**Resultados** A média de idade dos pacientes foi de  $38,5 \pm 9,6$  anos, a da intensidade da dor,  $7,8 \pm 1,6$ , e a do HHSm,  $56,3 \pm 12,7$ . No total, 61% da amostra apresentava Outerbridge III ou IV, e 12,6% apresentava lesão em onda. Observou-se correlação do sexo masculino ( $r = 0,497$ ) com menor intensidade da dor, e correlação da idade ( $r = -0,27$ ), do sexo masculino ( $r = 8,419$ ) e da realização de atividade física com maior escore funcional no HHSm ( $r = 4,729$ ).

**Conclusão** Não houve correlação dos parâmetros radiográficos e artroscópicos deste estudo com a intensidade da dor e a incapacidade dos pacientes. O sexo masculino está relacionado com menor intensidade da dor, e maior capacidade funcional está relacionada com o sexo masculino, menor idade, e a prática de atividade física.

**Nível de Evidência IV.**

## Palavras-chave

- ▶ impacto femoroacetabular
- ▶ artroscopia
- ▶ dor
- ▶ quadril

## Introduction

Femoroacetabular impingement syndrome (FAIS) is a clinical condition characterized by the early impact between the proximal femur and the acetabule,<sup>1</sup> and it is a common cause of hip pain and physical disability in young adult individuals.<sup>2,3</sup> It is described as a clinical disorder of the hip related to movement, in which the individual presents a triad of clinical signs and symptoms involving pain, limitation of the range of motion of the hip, and functional disability, linked to imaging findings characteristic of morphological changes in the neck-head junction of the femur, or cam-like impact, on the acetabular edge, or pincer-type impact or both, known as mixed impact.<sup>4</sup>

It is known that one of the most common complaints related to FAIS is hip pain, especially in the inguinal region, but these individuals also have functional deficit, difficulty in performing daily activities and sports, limitation of the range of motion and worsening of the quality of life.<sup>3,4</sup> In addition, according to the pathogenesis of this condition, early contact

between the aforementioned bone structures during movements such as flexion, adduction and internal rotation can lead to impaction and consequent injury to joint structures, such as the lip and cartilage. This results in progressive joint damage<sup>5</sup> that is related to degenerative diseases such as hip arthrosis and pain.<sup>6</sup> Thus, it is believed that early diagnosis and accurate treatment indication play a decisive role in the improvement of the condition.

Although plausible, the association between altered morphology or damage to the soft tissue of the joint<sup>1</sup> and the manifestation of symptoms and functional disability of the individuals with FAIS remains uncertain. The prevalence of pathologies of the intra-articular soft tissue believed to be associated with FAIS has been reported in a recent review,<sup>7</sup> and data indicate that labral lesions have been observed in 62% of symptomatic individuals and in 54% of asymptomatic individuals. On the other hand, cartilage defects were reported in 64% of symptomatic cases, compared with 12% in asymptomatic patients. Subchondral bone edema and injuries to the round ligament were more prevalent in people

with symptoms, and paralabral cysts and impingement cysts were equally prevalent in both symptomatic and asymptomatic patients.

The higher prevalence of these findings in individuals with FAIS may reinforce the idea that the pain and disability evidenced in these cases are directly related to imaging findings. However, the few studies<sup>8,9</sup> that tested the relationship of bone morphology and joint-tissue damage with the intensity of the pain in subjects with FAIS did not show an important correlation.

This shows that the interaction of pain and functional impairment with the structural lesions found in this disease is not yet clear, and that, despite the clinical improvement evidenced after arthroscopic surgery,<sup>10</sup> the understanding of the factors associated with the pain and disability of these patients remains uncertain. Thus, the aims of the present study were: to analyze the correlation of the morphological alterations studied and the degree of injury to intra-articular structures with the pain and function of patients who were waiting for a surgical procedure for FAIS; and to identify the factors associated with the pain and function of these individuals.

## Methods

The present study consists of a retrospective analysis of preoperative data of patients diagnosed with FAIS with an indication for arthroscopic hip surgery. These are preoperative data extracted from a consecutive series of patients pertaining to the database of arthroscopic procedures performed by a single surgeon specialized in hip surgery, with extensive experience in hip arthroscopy, over a period of eight years, whose postoperative data were used in another study by the same group of authors of the present study, registered in the institutional ethics committee (under CAEE: 49250215.4.0000.5479).

### Inclusion and Exclusion Criteria

A second surgeon, with about five years of experience in orthopedic surgery and specializing in hip surgery, retrospectively analyzed the medical records and reviewed the videos of the arthroscopies of the patients with a diagnosis of FAIS and labral lesion who were submitted to an arthroscopic hip procedure. Patients with congenital dysplastic alterations of the hip were excluded, due to the already-defined relationship of poor prognosis,<sup>11</sup> patients with hip osteoarthritis leading to a decrease in joint space < 2 mm, patients with traumatic lesion of the lip who have already undergone other surgical procedures of the hip, and patients with incomplete medical records.

### Measured Variables

The intensity of the preoperative pain, analyzed using the Visual Analog Pain Scale (VAS),<sup>12</sup> and the preoperative functional ability, analyzed by the Harris Hip Score modified (mHHS) by Byrd, translated and adapted into Portuguese, were considered dependent variables.<sup>13</sup>

The independent variables analyzed were: age, gender, laterality, practice of physical activity, alpha angle, Wiberg

angle, extension of the labral and chondral injuries based on the clock-face method, wave injury, and the degree of chondral injury by the Outerbridge classification.

The individuals who performed at least 150 minutes of moderate activity per week were considered practitioners of physical activity, according to the recommendations of the American College of Sports Medicine.<sup>14</sup>

### Radiographic Analysis

The radiographic analysis of the hips of patients included was performed to measure the Wiberg (center-edge, CE, angle)<sup>15</sup> and alpha angles on anteroposterior (AP) radiographs.<sup>6</sup> The measurements were performed through digital radiographs using the IMPAX Orthopaedic Tools (AGFA HealthCare, Mortsel, Belgium) software, version 1.0.323.

The Wiberg or CE angle is used to evaluate the head cover provided by the acetabular bone roof. It was obtained by drawing a line that crosses the centers of the femoral heads, one perpendicular to that line also passing through the center of the femoral head, and another line at the lateral edge of the acetabulum.<sup>12</sup>

The alpha angle is a measure proposed by Nötzli et al.<sup>16</sup> that evaluates the concavity of the femur-head joint. It was obtained through the intersection of two lines, drawn throughout the axis of the femoral neck, and a line drawn from the center of the femoral head to the point of greatest loss of the sphericity of the head.

### Analysis of the Chondral and Labral Damage

Through the analysis of the arthroscopic intraoperative video, the same orthopedic surgeon (with five years of experience) who performed the inclusion of the patients in the study evaluated the extent of the labral and chondral lesions, which were measured and located using the clock-face method, considering the upper region of the acetabulum as 12 o'clock, and calculating their extent based on the distance in "hours" between the lesional extremities.<sup>17</sup>

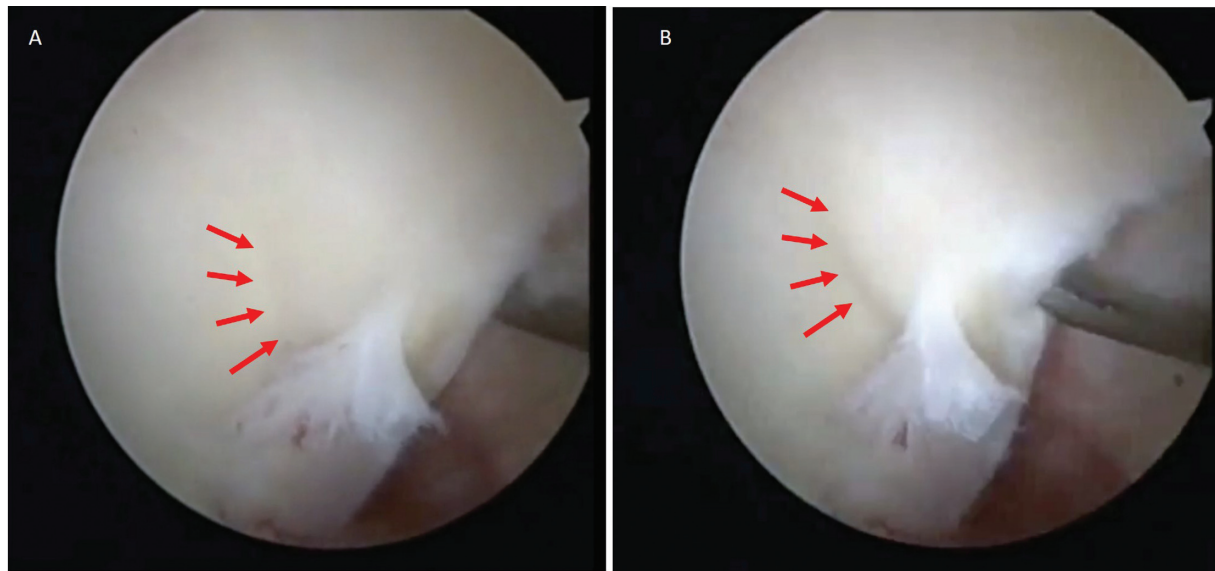
The Outerbridge classification of the chondral lesions was also determined through an analysis of the video of the arthroscopic procedure,<sup>18</sup> and they were classified as grades 1 to 4, with a spectrum of lesions ranging from cartilage edema to subchondral cartilage erosion.<sup>19</sup>

Regarding the chondral damage, during the procedure, "palpation" of the joint cartilage was performed with an arthroscopic probe in order to locate alterations suggestive of delamination of the articular cartilage with loss of fixation of cartilage to the subchondral bone, characterizing the wave lesion (► **Figure 1**).<sup>20,21</sup>

### Statistical Analysis

The normality of the quantitative variables of the main outcome was tested using the Kolmogorov-Smirnov (KS) test. The test of equality of two proportions was applied to characterize the distribution of the relative frequency (percentages) of the qualitative variables.

Spearman correlation analysis was performed to evaluate the association of the scores on the mHHS and VAS with the quantitative covariates, and, to analyze qualitative covariates



**Fig. 1** (A) Red arrows: aspect of the delamination of the articular cartilage of the subchondral bone, characteristic of the wave lesion. (B) Red arrows: “palpation” of the delamination with an arthroscopic probe, confirming the presence of wave lesion.

in relation to the mHHS and VAS scores, the Mann-Whitney test was performed. Finally, a multivariate linear regression analysis was performed following the stepwise model to verify which variables influence the mHHS and VAS scores. All statistical analyses were performed using the Statistical Package for the Social Sciences (SPSS, IBM Corp., Armonk, NY, US) software, version 20.0, with significance defined as values of  $p < 0.05$ , and intervals with 95% of statistical confidence.

**Results**

A total of 182 patients (190 hips) were analyzed, with a mean age of 38.5 (standard deviation [SD]: 9.8) years, 58.4% of whom were men, and a mean pain of 7.8 (SD: 1.6) points in the VAS and an mHHS score of 56.3 (SD: 12.7). In total, 61% of the sample presented grade-III and IV chondral lesions according to the Outerbridge classification, and 12.6% presented wave lesion. Other clinical and demographic data and the frequency distribution are described in ►Tables 1 and 2 respectively.

**Table 1** Mean and standard deviation of sample characterization data

	Mean (standard deviation)
Age	38.5 (9.8)
Modified Harris Hip Score	56.3 (12.7)
Visual Analog Scale	7.8 (1.6)
Wiberg angle	39.1 (6.7)
Alpha angle	57.4 (9.3)
Sum of the labral clock-face	2.53 (0.79)
Sum of the chondral clock-face	2.7 (0.87)

In the analysis of the correlation with quantitative variables, a weak and negative correlation between the mHHS and age was identified, with  $r = -0.237$ . No significant correlation was observed between the intensity of the pain and any quantitative variable in the present study.

According to the Mann-Whitney test, a statistical effect of gender and physical activity was evidenced in the mHHS and VAS scores, and male patients and those who practiced physical activity had higher functional scores and lower intensity of pain than female patients and sedentary individuals ( $p = 0.011$ ). There was a tendency of individuals with wave lesions to have lower functional scores ( $p = 0.058$ ); nonetheless, no statistical difference was observed for this variable (►Table 3). When analyzing the Outerbridge classification in relation to the mHHS and VAS through the

**Table 2** Distribution of the absolute and relative frequencies of the qualitative data

Qualitative data		N (%)
Practice of physical activity	No	60 (31.6)
	Yes	130 (68.4)
Side	Right	112 (58.9)
	Left	78 (41.1)
Gender	Female	79(41.6)
	Male	111(58.4)
Wave lesion	No	166 (87.4)
	Yes	24 (12.6)
Degree on the Outebrigde classification	I	40 (21.1)
	II	34 (17.9)
	III	55 (28.9)
	IV	61 (32.1)

**Table 3** Multivariate linear regression analysis for dependent variables: pain and modified Harris Hip Score

Visual Analog Scale	Stepwise	
	Beta coefficient	p-value
Constant	8.051	< 0.001
Age	0.017	0.196
Wiberg angle	0.021	0.265
Alpha angle	0.023	0.12
Labral clock-face	-0.104	0.594
Chondral clock-face	0.139	0.435
Male gender*	-0.537	0.03
Right side	-0.012	0.961
Practice of physical activity	-0.372	0.178
Wave lesion	0.362	0.367
Outebrigde classification	-0.083	0.542
Analysis of variance	0.03	
Coefficient of determination (R <sup>2</sup> )	2.00%	
Modified Harris Hip Score	Stepwise	
	Beta coefficient	p-value
Constant	58.074	< 0.001
Age*	-0.241	0.006
Wiberg angle	-0.224	0.081
Alpha angle	-0.07	0.492
Labral clock-face	2.209	0.105
Chondral clock-face	-0.424	0.731
Male gender*	7.569	< 0.001
Right side	-1.553	0.373
Practice of physical activity*	4.471	0.019
Wave lesion	-2.396	0.389
Outebrigde classification	-1.188	0.208
Analysis of variance	< 0.001	
Coefficient of determination (R <sup>2</sup> )	17.30%	

Note: \*Variable with statistical significance.

Kruskal-Wallis test, no statistical interaction was identified regarding these variables.

Finally, in the multivariate linear regression analysis, evaluating the models by the stepwise method for the VAS, only the variable gender ( $r = -0.497$ ) was significant, that is, being a man is a factor related to lower intensity of pain. In the analysis for the mHHS, 3 variables emerged in the model as significant: age ( $r = -0.270$ ), that is, the older the age, the lower the functional score; gender ( $r = 8.419$ ), that is, being a man is related to higher functional scores; and physical activity ( $r = 4.729$ ), which was an indicator of higher functional scores.

## Discussion

The morphological alterations found in FAIS, especially cam-type deformity, seem to be related to the involvement of the intra-articular tissues of the hip during the impact that occurred between the structures during the execution of the movements.<sup>6</sup> It is plausible that these lesions are suggestive of pain and functional disability evidenced in individuals with FAIS. However, the findings of the present study did not enable us to establish a correlation of the parameters evaluated, whether anatomical or intra-articular lesions, with the disability of patients, and no correlation was identified of the radiographic findings or the magnitude of the labral and chondral acetabular lesions observed intraoperatively with the intensity of the pain or functional disability measured by the mHHS.

For some years now, the relationship between the structural alterations observed in individuals with FAIS and the clinical manifestations of this syndrome has intrigued clinicians and researchers. Frank et al.<sup>22</sup> evaluated the presence of structural alterations compatible with femoroacetabular impingement (FAI) and labral lesion on imaging exams of asymptomatic patients and identified that 37% of them presented cam-type morphological alterations, and 67% had pincer-type alterations. Heerey et al.,<sup>7</sup> in a systematic review with meta-analysis, found by moderate evidence the prevalence of 54% of labral lesions and 12% of chondral injuries in asymptomatic individuals.

Yamauchi et al.<sup>8</sup> correlated the symptomatology and disability of the patients with radiographic findings suggestive of FAIS, but showed no association between the changes in imaging exams and the intensity of the pain or provocative clinical tests. And, in a study conducted by Grace et al.,<sup>9</sup> there was only a weak association between chondral alterations in the head of the femur and the intensity of the pain of individuals with FAIS, while the extent of the labral lesions and the damage to the acetabular articular cartilage did not correlate with the symptomatology of the patients.

It is known that the surgical approach widely indicated for the treatment of FAIS is arthroscopy, a procedure that aims to minimize the changes in bone morphology and the damage to soft structures, assuming that these changes are directly related to the pain and functional impairment of the patients.<sup>23,24</sup> However, although this procedure demonstrates good results, with good patient satisfaction in the postoperative period,<sup>25,26</sup> doubts remain as to the pain mechanisms involved in FAIS, and a great diagnostic difficulty remains, given that FAIS is a multifactorial dynamic condition, and many of its contributing factors are not evaluated by static tests.

We believe that our findings reflect the multidimensional nature of pain, especially in individuals with chronic hip pain, in whom, in addition to the physical aspects, psychological factors, such as anxiety, depression, dysfunctional beliefs about their pain and mental health, may contribute to the magnitude and chronicity of the symptoms and of the disability.<sup>27,28</sup>



Moreover, the absence of correlation between the evaluated structural lesions and pain challenges the linear and traditional view of the models to comprehend pain based only on tissue damage, a fact highlighted by Jacobs et al.,<sup>28</sup> who, when evaluating variables related to the preoperative symptoms of individuals with FAIS, identified that mental health scores are more associated with symptoms than the severity of the labral damage or the magnitude of the morphological changes.

From the perspective of a more complex analysis, the data of the present study also indicate that, in addition to non-modifiable variables such as age and gender, the practice of physical activity emerged as an important factor correlated both with lower pain levels and higher levels of functionality in the preoperative analysis. Assuming that higher scores on functional questionnaires are predictors of good postoperative prognosis,<sup>29</sup> and that the regular practice of physical activity is a protective factor against recurrent pain after arthroscopy for FAIS,<sup>30</sup> it seems plausible that the engagement in more active life habits is an important recommendation on the part of the professionals who treat individuals with this clinical condition.

The present study has limitations, one of which is the ceiling effect presented by the chosen disability questionnaire (the mHHS), although there are similar results in the literature<sup>9</sup> with other scores, such as the Hip Disability and Osteoarthritis Outcome Score (HOOS). In any case, we suggest that the results of the present study be carefully extrapolated in cases of other methods of quantification of functional disability. In addition, the data in question were extracted retrospectively, which also suggests that it be interpreted with due caution. The structural factors evaluated are not all existing factors related to FAIS, and there are also limitations in their evaluations, especially the alpha angle measured only through AP radiographs, so the conclusion that there is no structural correlation with the degree of disability should be interpreted based only on the methods used by the present study.

The lack of evaluation of bone edema by magnetic resonance imaging is a limitation, since the literature describes that there is a higher prevalence of this finding in individuals with pain. More studies are needed to evaluate the correlation of other possible morphological, functional and multi-dimensional variables with the functional status and pain of the patients. Femoroacetabular impingement syndrome encompasses a very wide range of causative factors and it would probably be necessary to divide them into subgroups for a more accurate analysis.

## Conclusion

There was no correlation of the Wiberg angle, alpha angle and chondrolabral damage with the intensity of the pain and level of functional impairment in the present cohort of patients. Male patients presented lower intensity of pain and higher functional scores are associated with the male gender, lower age, and the practice of physical activity.

## Financial Support

There was no financial support from public, commercial, or non-profit sources.

## Conflict of Interests

The authors have no conflict of interests to declare.

## References

- Ganz R, Parvizi J, Beck M, Leunig M, Nötzli H, Siebenrock KA. Femoroacetabular impingement: a cause for osteoarthritis of the hip. *Clin Orthop Relat Res* 2003;(417):112-120
- Freke MD, Kemp J, Svege I, Risberg MA, Semciw A, Crossley KM. Physical impairments in symptomatic femoroacetabular impingement: a systematic review of the evidence [published correction appears in *Br J Sports Med* 2019;53(20):e7. *Br J Sports Med* 2016;50(19):1180
- Kemp J, Grimaldi A, Heerey J, et al. Current trends in sport and exercise hip conditions: Intra-articular and extra-articular hip pain, with detailed focus on femoroacetabular impingement (FAI) syndrome. *Best Pract Res Clin Rheumatol* 2019;33(01):66-87
- Griffin DR, Dickenson EJ, O'Donnell J, et al. The Warwick Agreement on femoroacetabular impingement syndrome (FAI syndrome): an international consensus statement. *Br J Sports Med* 2016;50(19):1169-1176
- Beck M, Kalthor M, Leunig M, Ganz R. Hip morphology influences the pattern of damage to the acetabular cartilage: femoroacetabular impingement as a cause of early osteoarthritis of the hip. *J Bone Joint Surg Br* 2005;87(07):1012-1018
- Agricola R, Heijboer MP, Bierma-Zeinstra SM, Verhaar JA, Weinans H, Waarsing JH. Cam impingement causes osteoarthritis of the hip: a nationwide prospective cohort study (CHECK). *Ann Rheum Dis* 2013;72(06):918-923
- Heerey JJ, Kemp JL, Mosler AB, et al. What is the prevalence of imaging-defined intra-articular hip pathologies in people with and without pain? A systematic review and meta-analysis. *Br J Sports Med* 2018;52(09):581-593
- Yamauchi R, Inoue R, Chiba D, et al. Association of clinical and radiographic signs of femoroacetabular impingement in the general population. *J Orthop Sci* 2017;22(01):94-98
- Grace T, Samaan MA, Souza RB, Link TM, Majumdar S, Zhang AL. Correlation of Patient Symptoms With Labral and Articular Cartilage Damage in Femoroacetabular Impingement. *Orthop J Sports Med* 2018;6(06):2325967118778785
- Clohisey JC, St John LC, Schutz AL. Surgical treatment of femoroacetabular impingement: a systematic review of the literature. *Clin Orthop Relat Res* 2010;468(02):555-564
- Yeung M, Kowalczyk M, Simunovic N, Ayeni OR. Hip arthroscopy in the setting of hip dysplasia: A systematic review. *Bone Joint Res* 2016;5(06):225-231
- Pimenta CAM, Teixeira MJ. Avaliação da dor. *Rev Med (São Paulo)* 1997;76:27-35
- Guimarães R, Alves D, Azuaga T, et al. Translation and transcultural adaptation of the modified Harris Hip Score. *Acta Ortop Bras* 2009;18(06):339-342
- Thompson PD. American College of Sports Medicine. Physical Activity and Fitness Terminology. In: *Guidelines for exercise testing and prescription*. Baltimore: Wolters Kluwer; 2014:1-18
- Wiberg G. Studies on dysplastic acetabula and congenital subluxation of the hip joint: with special reference to the complication of osteoarthritis. *Acta Chir Scand* 1939;83(Suppl):5-135
- Nötzli HP, Wyss TF, Stoecklin CH, Schmid MR, Treiber K, Hodler J. The contour of the femoral head-neck junction as a predictor for the risk of anterior impingement. *J Bone Joint Surg Br* 2002;84(04):556-560
- Philippon MJ, Stubbs AJ, Schenker ML, Maxwell RB, Ganz R, Leunig M. Arthroscopic management of femoroacetabular impingement:

- osteoplasty technique and literature review. *Am J Sports Med* 2007;35(09):1571–1580
- 18 Barros AAG, Vassalo CC, Costa LP, Gómez-Hoyos J, Paganini VO, Andrade MAP. Reliability of the Arthroscopic Classifications of Hip Chondral Lesions. *Rev Bras Ortop (Sao Paulo)* 2019;54(04):440–446
  - 19 Outerbridge RE. The etiology of chondromalacia patellae. *J Bone Joint Surg Br* 1961;43-B:752–757
  - 20 Konan S, Rayan F, Meermans G, Witt J, Haddad FS. Validation of the classification system for acetabular chondral lesions identified at arthroscopy in patients with femoroacetabular impingement. *J Bone Joint Surg Br* 2011;93(03):332–336
  - 21 El-Radi MA, Marin-Peña OR, Said HG, Tey-Pons M. Basics in hip chondrolabral lesions and state of the art. *SICOT J* 2017;3:73
  - 22 Frank JM, Harris JD, Erickson BJ, et al. Prevalence of Femoroacetabular Impingement Imaging Findings in Asymptomatic Volunteers: A Systematic Review. *Arthroscopy* 2015;31(06):1199–1204
  - 23 Kemp JL, Collins NJ, Makdissi M, Schache AG, Machotka Z, Crossley K. Hip arthroscopy for intra-articular pathology: a systematic review of outcomes with and without femoral osteoplasty. *Br J Sports Med* 2012;46(09):632–643
  - 24 Minkara AA, Westermann RW, Rosneck J, Lynch TS. Systematic Review and Meta-analysis of Outcomes After Hip Arthroscopy in Femoroacetabular Impingement. *Am J Sports Med* 2019;47(02):488–500
  - 25 O'Connor M, Minkara AA, Westermann RW, Rosneck J, Lynch TS. Return to Play After Hip Arthroscopy: A Systematic Review and Meta-analysis. *Am J Sports Med* 2018;46(11):2780–2788
  - 26 Polesello GC, Honda EK, Ono NK, et al. Artroscopia do quadril: experiência após seguimento médio de 33 meses. *Rev Bras Ortop* 2006;41(05):145–150
  - 27 Potter MQ, Wylie JD, Sun GS, Beckmann JT, Aoki SK. Psychologic distress reduces preoperative self-assessment scores in femoroacetabular impingement patients. *Clin Orthop Relat Res* 2014;472(06):1886–1892
  - 28 Jacobs CA, Burnham JM, Jochimsen KN, Molina D IV, Hamilton DA, Duncan ST. Preoperative Symptoms in Femoroacetabular Impingement Patients Are More Related to Mental Health Scores Than the Severity of Labral Tear or Magnitude of Bony Deformity. *J Arthroplasty* 2017;32(12):3603–3606
  - 29 Nabavi A, Olwill CM, Harris IA. Preoperative predictors of outcome in the arthroscopic treatment of femoroacetabular impingement. *Hip Int* 2015;25(05):402–405
  - 30 Stone AV, Malloy P, Beck EC, et al. Predictors of Persistent Postoperative Pain at Minimum 2 Years After Arthroscopic Treatment of Femoroacetabular Impingement. *Am J Sports Med* 2019;47(03):552–559