



Evaluations of Repaired Artery Patency in Forearm Wounds Using the Allen Test, Handheld Doppler and Doppler Ultrasonography*

Avaliações do lúmen da artéria reparada em lesões do antebraço usando o teste de Allen, doppler portátil e ultrassonografia com doppler

Amanda Favaro Cagnolati¹ Fernanda Ruiz Andrade¹ Sara Dadona Correia Serrano²
Claudio Henrique Barbieri³ Nilton Mazzer³ Marcello Henrique Nogueira-Barbosa⁴

¹ Hand Surgery Medical Residence, Department of Orthopedics and Anesthesiology, Faculdade de Medicina de Ribeirão Preto da Universidade de São Paulo, Ribeirão Preto, SP, Brazil

² Hand Surgery Program, Department of Orthopedics and Anesthesiology, Faculdade de Medicina de Ribeirão Preto da Universidade de São Paulo, Ribeirão Preto, SP, Brazil

³ Hand Surgery Program, Department of Orthopedics and Anesthesiology, Faculdade de Medicina de Ribeirão Preto da Universidade de São Paulo, Ribeirão Preto, SP, Brazil

⁴ Division of Radiology, Department of Medical Imaging, Hematology and Clinical Oncology, Faculdade de Medicina de Ribeirão Preto da Universidade de São Paulo, Ribeirão Preto, SP, Brazil

Address for correspondence Amanda Favaro Cagnolati, Department of Orthopedics and Anesthesiology, Faculdade de Medicina de Ribeirão Preto da Universidade de São Paulo, Campus Universitário., Ribeirão Preto, SP, Brazil
(e-mail: amandafavaro@terra.com.br).

Rev Bras Ortop 2022;57(3):455–461.

Abstract

Objective The purpose of the present study was to evaluate the rate of patency in the postoperative period of arterial injuries of the forearm secondary to penetrating trauma. The injuries were subjected to primary repair and examined with the Allen test and a handheld Doppler device, and the results were later confirmed with Doppler ultrasonography.

Methods Eighteen patients were included, with a total of 19 arterial lesions, 14 ulnar lesions, and 5 radial lesions; one patient had lesions on both forearms. All patients underwent surgery and three clinical evaluations: the Allen test and assessment of arterial blood flow by a handheld Doppler device at 4 and 16 weeks after surgery and Doppler ultrasonography performed at 12 weeks after surgery.

Results At the first clinical evaluation, 77% of the patients had patency based on the Allen test, and 72% had a pulsatile sound identified by the handheld Doppler device. In

Keywords

- ▶ ulnar artery
- ▶ arterial injury
- ▶ Doppler
- ▶ arterial patency
- ▶ arterial repair

* Study developed at the Department of Orthopedics and Anesthesiology, Faculdade de Medicina de Ribeirão Preto da Universidade de São Paulo, Ribeirão Preto, SP, Brazil.

received
July 10, 2020
accepted
November 3, 2020
published online
August 13, 2021

DOI <https://doi.org/10.1055/s-0041-1729574>.
ISSN 0102-3616.

© 2021. Sociedade Brasileira de Ortopedia e Traumatologia. All rights reserved.
This is an open access article published by Thieme under the terms of the Creative Commons Attribution-NonDerivative-NonCommercial-License, permitting copying and reproduction so long as the original work is given appropriate credit. Contents may not be used for commercial purposes, or adapted, remixed, transformed or built upon. (<https://creativecommons.org/licenses/by-nc-nd/4.0/>)
Thieme Revinter Publicações Ltda., Rua do Matoso 170, Rio de Janeiro, RJ, CEP 20270-135, Brazil

the second evaluation, 61% of the patients had patency based on the Allen test, and the rate of pulsatile sound by the handheld Doppler device was 72%, similar to that observed 2 months earlier. Based on the Doppler ultrasonography evaluation (~12 weeks after surgery), the success rate for arteriorrhaphy was 88%. Regarding the final patency (Doppler ultrasonography evaluation) and trauma mechanism, all patients with penetrating trauma had patent arteries.

Conclusion We cde that clinical evaluation using a handheld Doppler device and the Allen test is reliable when a patent artery can be palpated. However, if a patent artery cannot be located during a clinical examination, ultrasonography may be required.

Resumo

Objetivo O objetivo deste estudo foi avaliar a taxa de perviedade pós-operatória de lesões arteriais do antebraço secundárias a traumatismo penetrante. As lesões foram submetidas a reparo primário e examinadas com o teste de Allen e um dispositivo Doppler portátil; posteriormente, os resultados foram confirmados à ultrassonografia com Doppler.

Métodos Dezoito pacientes foram incluídos, com um total de 19 lesões arteriais, 14 lesões ulnares e 5 lesões radiais; um paciente tinha lesões em ambos os antebraços. Todos os pacientes foram submetidos à cirurgia e três avaliações clínicas: o teste de Allen e a avaliação do fluxo sanguíneo arterial com um dispositivo portátil de Doppler na 4ª e 16ª semanas após a cirurgia e ultrassonografia com Doppler 12 semanas após o procedimento.

Resultados Na primeira avaliação clínica, 77% dos pacientes apresentavam perviedade segundo o teste de Allen e 72% apresentavam som pulsátil identificado pelo Doppler portátil. Na segunda avaliação, 61% dos pacientes apresentaram perviedade com base no teste de Allen e a taxa de som pulsátil ao Doppler portátil foi de 72%, semelhante à observada 2 meses antes. À ultrassonografia com Doppler (cerca de 12 semanas após a cirurgia), a taxa de sucesso da arteriorrafia foi de 88%. Em relação à perviedade final (avaliação por ultrassonografia com Doppler) e mecanismo de trauma, todos os pacientes com traumatismo penetrante apresentavam artérias pérvias.

Conclusão Concluímos que a avaliação clínica com um dispositivo Doppler portátil e o teste de Allen é confiável caso a artéria pérvia possa ser palpada. No entanto, a ultrassonografia pode ser necessária em caso de impossibilidade de localização de uma artéria pérvia durante o exame clínico.

Palavras-chave

- ▶ artéria ulnar
- ▶ lesão arterial
- ▶ Doppler
- ▶ lúmen arterial
- ▶ reparo arterial

Introduction

Arterial injury of the forearm accounts for 50% of peripheral vascular lesions.^{1,2} These injuries commonly involve penetrating or blunt/penetrating trauma, with the highest incidence occurring in the young male population due to penetrating glass injury.^{3,4}

Generally, associated lesions are present in musculotendinous structures. Orthopedic and neurological injuries occur more frequently as a result of blunt trauma.^{5,6}

The diagnosis of arterial injury can be made through a clinical evaluation; the symptoms include hemorrhage, ischemia, and accompanying neurological deficits due to the proximity of the nerves to arteries. Complementary imaging examinations are indicated when the clinical signs cannot confirm the existence or location of an arterial injury.^{5,6}

Clinical evaluation tests, such as palpation of the arterial pulse, the Allen test, and handheld Doppler examination, can

be used to assess arterial patency. Doppler ultrasonography can be used for the evaluation as an imaging test.⁵

In the Allen test, the examiner occludes the radial and ulnar arteries by digital compression and then asks the patient to open and close his or her hand to drain the blood from the palmar arch. The patient then relaxes his or her hand, and the examiner stops compressing the artery to be evaluated, observing the time required for the color of the palm to return to normal. The test is considered positive when the artery is patent, showing a return to normal color in less than 6 seconds.¹

Doppler ultrasonography has an accuracy of ~ 98% in diagnosing arterial obstruction and is considered a low-cost and noninvasive test. This test is more specific than sensitive, and it is time consuming and examiner dependent.⁴

One complication associated with repair is vessel thrombosis, which leads to treatment failure. The rate of patency after individual repair of the radial or ulnar artery using

microsurgical techniques ranges from ~ 46 to 84% .⁴ The highest success rates are observed in injuries repaired within 36 hours, injuries caused by sharp objects (not by avulsion or laceration), and injuries to the radial artery.⁴

Due to the potential for thrombosis, as previously reported for arterial repairs, we decided to perform clinical evaluations and use diagnostic tests (Doppler ultrasound) to evaluate patients who underwent emergency surgery to check arterial patency and propose clinical evaluation as an alternative to Doppler ultrasonography.

Materials and Methods

Patients with injuries of the volar zone V of the forearm with an associated arterial injury underwent primary repair of the injury and were followed up with clinical and ultrasonography evaluations at the Clinics Hospital of the Faculdade de Medicina de Ribeirão Preto da Universidade de São Paulo from May 2018 to September 2019.

Patients who underwent ligation of the injured artery or with the need for graft interposition to repair the artery were excluded.

Of the 33 patients selected, 15 did not complete follow-up at the clinic, that is, did not return for the visits and did not undergo the appropriate evaluations. Eighteen patients had all of the information necessary for the study, and most men (72%) were young, with an average age of 30 years (range, 16–60 years), without diseases.

The patients returned for a follow-up visit at 1 week to evaluate the dressing and at 4 weeks to assess the range of motion, when they presented with an associated tendon lesion, and for evaluation of arterial flow using the Allen test and a handheld Doppler device (**►Figs. 1 and 2**). At ~ 12 weeks after the injury, the patients were evaluated using Doppler ultrasonography, and at ~ 14 to 16 weeks after the injury, they were reevaluated using the Allen test and handheld Doppler device.

The most frequent trauma mechanism was penetrating trauma, accounting for $\sim 78\%$ of cases, whereas in 22% of cases, the mechanism was blunt/penetrating trauma, such as work accidents.

The most commonly used suture was polypropylene (88%), and nylon was used in 12% of cases, based on the surgeon's choice.

All repairs were performed using loupes, with loupes with up to $3.5\times$ magnification used in 9 cases and loupes with 4 to $6\times$ magnification used in 9 cases. All surgeries were performed in an identical manner by two surgeons who were at the end of their hand surgery training and under the tutelage of the senior author.

Seventy-seven percent of the patients underwent arteriorrhaphy within 120 hours (5 days) of the injury, with an average duration of 82 hours (~ 3 days after injury).

A descriptive statistical analysis of the data was performed. The Student *t*-test, Fisher⁷ exact test, and McNemar test were used, and all statistical analyses were performed using the statistical software SAS 9.4 (SAS Institute Inc., Cary, NC, USA).⁷⁻⁹



Fig. 1 Handheld Doppler device used to evaluate the patients.

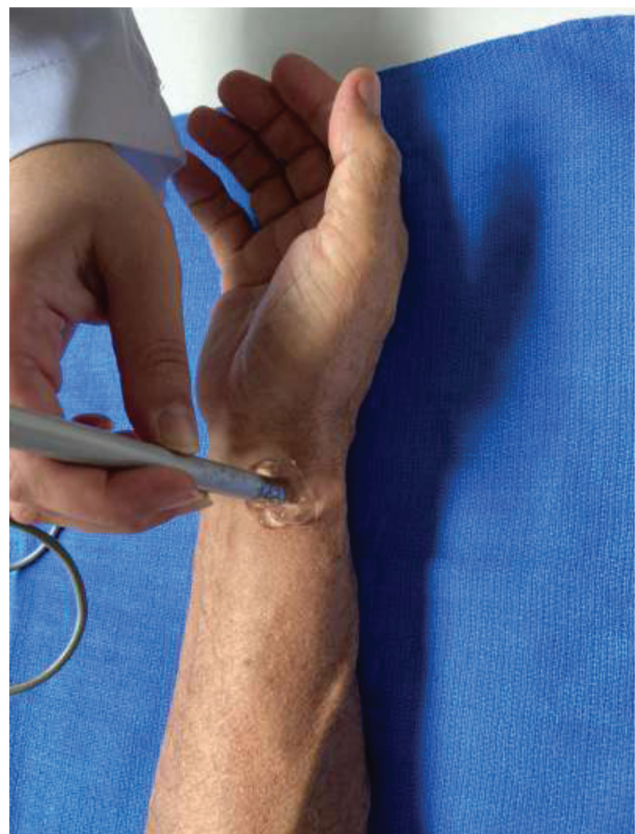

Fig. 2 Assessment of a patient using a handheld Doppler device.

Table 1 Comparison of arterial patency determined using Doppler ultrasound in patients undergoing early and late arteriorrhaphy

INTERVAL	DOPPLER		Total
	Non- patent	Patent	
up to 120 hours	0 0.00	14 77.78	14 77.78
> 120 hours	2 11.11	2 11.11	4 22.22
Total	2 11.11	16 88.89	18 100.00

Fisher exact test: p -value = 0.0392.

The current study was approved by the Ethics in Human Research Committee, and all participants provided written informed consent.

Results

At the first clinical evaluation (~ 4 weeks after the injury), 77% of the patients showed patency based on the Allen test, and the pulse was identified in 72% of patients using a handheld Doppler device (►Figs. 1 and 2).

At the second clinical evaluation (~ 14–16 weeks after the injury), 61% of the patients had patency based on the Allen test, and the rate of pulse identification by the handheld Doppler device remained at 72%, as observed 2 months earlier.

The Doppler ultrasonography evaluation (~ 12 weeks after the injury) indicated an arteriorrhaphy success rate of 88%. Regarding the final patency (evaluation using Doppler ultrasonography) and the trauma mechanism, all patients

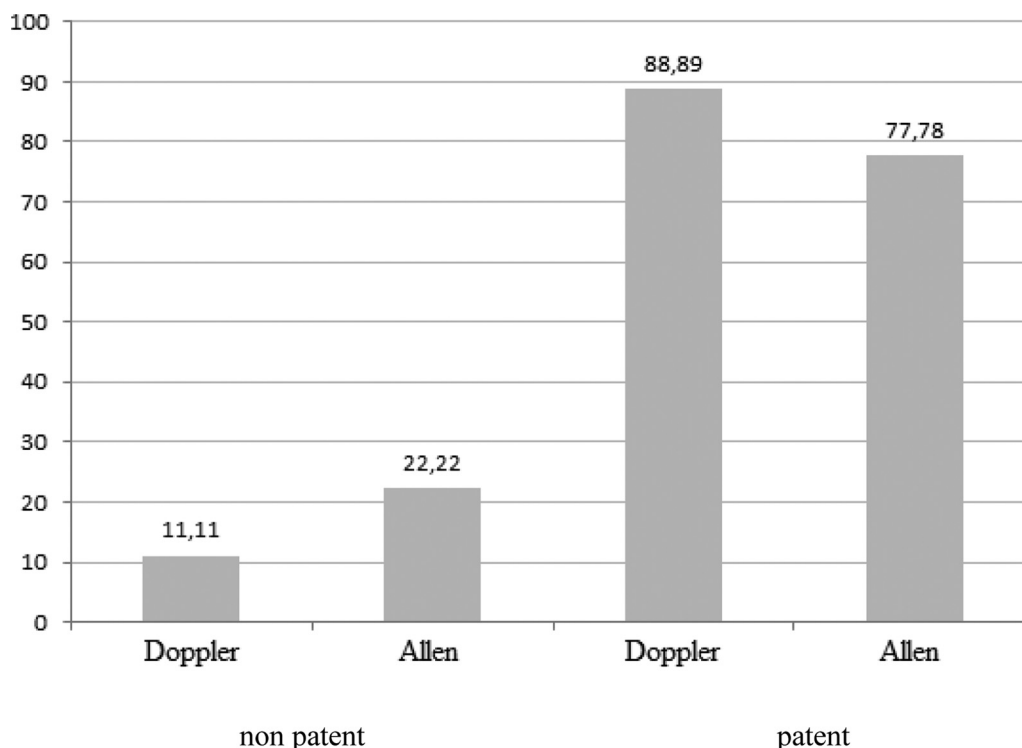
with penetrating trauma had patent arteries, and in patients with blunt/penetrating trauma, the success rate was 85% (p -value: 1.0).

All patients who underwent arteriorrhaphy using nylon sutures showed patent arteries in the final evaluation, and among patients who underwent arteriorrhaphy using polypropylene, 87% showed patency via Doppler ultrasonography (p -value: 1.0).

All surgeries were performed by magnification using loupes during the repair, that is, 3.5× or 4×, and there was no difference between the groups (p -value: 1.0) and between the surgeons.

All patients who underwent repair within 5 days had patent arteries in the final evaluation, and the patency rate for patients with late arteriorrhaphy was 50% (p -value: 0.03) (►Table 1). All patients for whom the Allen test at the first clinical evaluation (4 weeks) showed patent arteries had patent arteries at the final ultrasound evaluation. Of the patients with negative Allen test results (occluded artery) at the first clinical evaluation, only 50% had patent arteries at the final Doppler ultrasonography evaluation (p -value: 0.03) (►Fig. 3). In the second clinical evaluation (14–16 weeks), agreement of the Allen test with the ultrasonography evaluation remained at 100% for patients with patent arteries based on the Allen test, but the agreement rate decreased to 28% for patients with a negative Allen test (p -value: 0.13) (►Fig. 4).

Handheld Doppler examination performed during the first clinical evaluation also showed 100% agreement with the ultrasonography evaluation in patients with patent arteries and 40% agreement when the pulse was not located (p -value: 0.06). These parameters were maintained in the second clinical evaluation (►Fig. 5).

**Fig. 3** Comparison of the initial Allen test with the final ultrasonography evaluation.

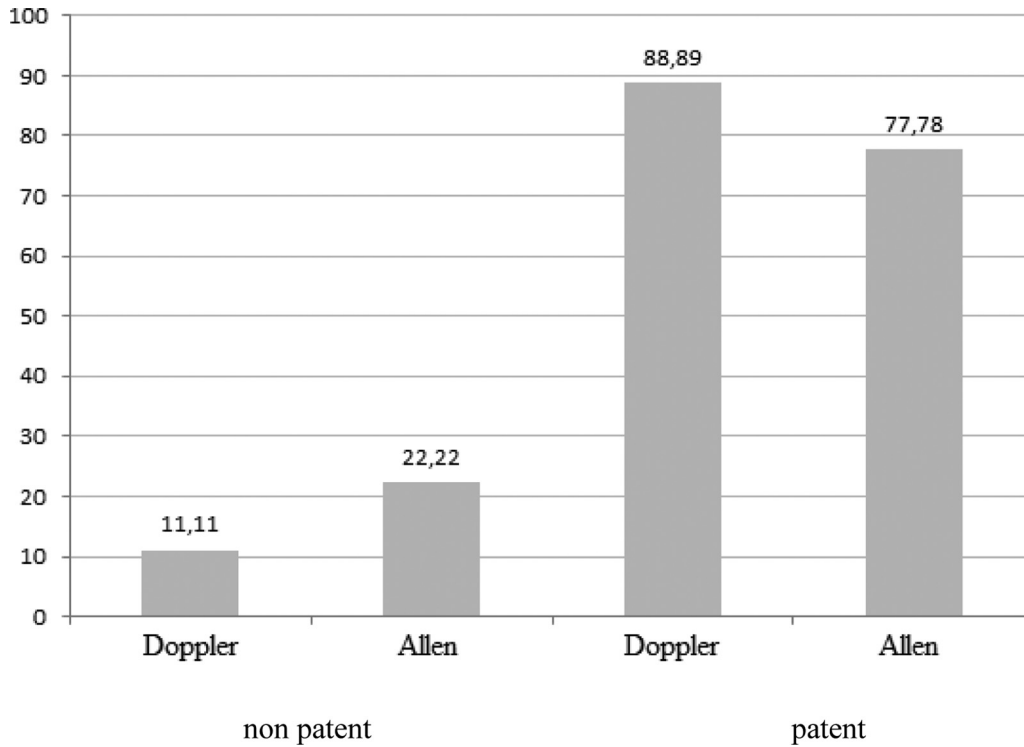


Fig. 4 Comparison of the Allen test in the second evaluation with the final ultrasonography evaluation.

Discussion

Treatment of arterial injuries can be performed through ligation of the artery, primary repair (in lesions with gaps smaller than 2 cm and good mobility of the stumps for

nontension sutures) or repair with graft interposition (in lesions with gaps greater than 2 cm).^{10,11}

When both arteries (radial and ulnar) are injured, even in cases with a well-perfused hand, arterial repair should be performed to decrease ischemic symptoms.^{1,4} Some studies

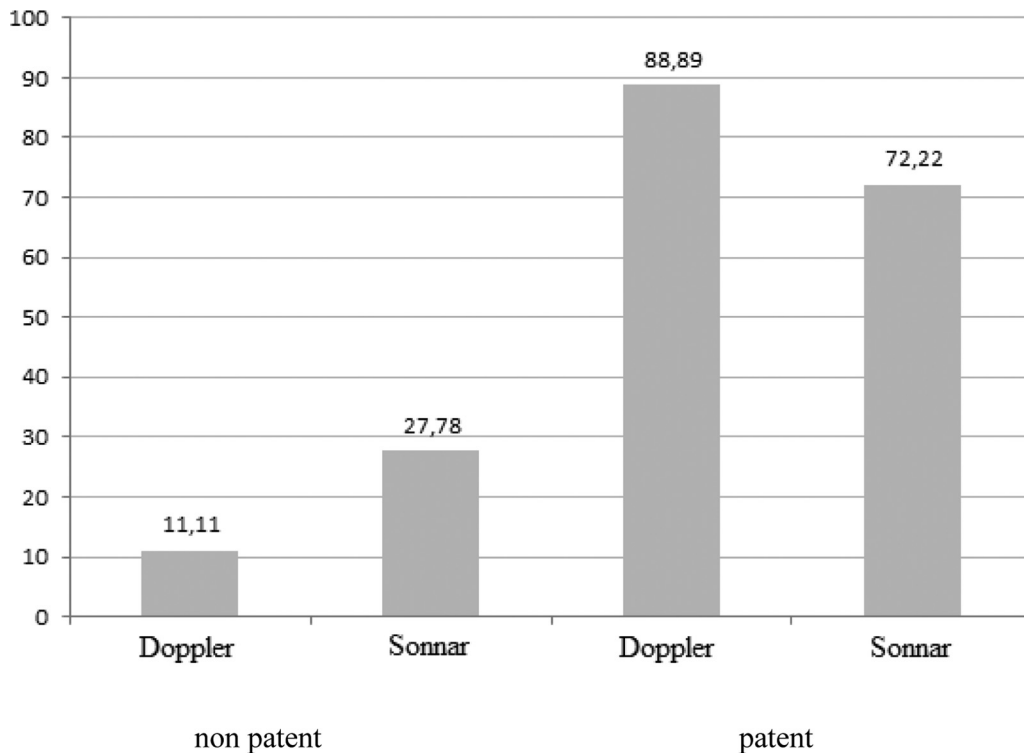


Fig. 5 Comparison of the initial handheld Doppler evaluation and final ultrasonography evaluation.

have shown that the loss of perfusion through the radial or ulnar artery to the hand can lead to cold intolerance, muscle and bone atrophy, and loss of strength,¹² which confirms the importance of performing arterial repair and ensuring patency even in single-artery injuries with a well-perfused hand.

When an associated neurological lesion is present, an important gain in recovery is observed when artery patency is achieved after arterial repair. According to the literature, 87% of patients with ulnar nerve injuries achieved adequate and excellent neurological recovery when the ulnar artery was patent; the rate of good results decreased to 33% in patients with an obliterated ulnar artery.^{5,12}

The reasons for vessel thrombosis are still not well understood, but it is hypothesized that retrograde pressure in the palmar arch causes turbulence in the vessel and decreases flow in the repaired artery, leading to its obstruction.^{13,14}

Similar to the epidemiology observed in other studies, in our sample, the highest prevalence of arterial injuries in the forearm was observed in young male patients.

Doppler ultrasonography is a noninvasive, rapid, and accurate technique to evaluate the results of vascular repair, flow rate, and flow characteristics; the success rate of achieving patent arteries demonstrated by Doppler ultrasonography in our study was 88%, a rate higher than that reported in the literature, in which we found values of up to 84%.^{2,4} The highest success rate occurred in patients with penetrating trauma (100%) and reached 85% in cases of penetrating/blunt trauma.

When analyzing the final patency relative to the type of sutures used, we found a higher success rate with the use of nylon (100%) than with polypropylene (87%) sutures; however, only two arteries were repaired with nylon (two repairs), thus resulting in little statistical significance of the finding (p -value: 1.0). The literature shows a similar patency rate between the types of sutures, with better biocompatibility with the use of polypropylene.¹⁵

All repairs were performed using surgical loupes, and the literature demonstrates that the use of microsurgical techniques increases the arteriorrhaphy success rate.

Regarding the interval between injury and repair, we obtained a patency rate of 100% for arteries repaired within 5 days (→Fig. 6), with a significant decrease to 50% when the interval was greater than 5 days, with good statistical significance for these data (p -value: 0.03). We had a high success rate even if the procedure was performed after 36 hours, unlike that reported in the literature.⁴

Regarding clinical and ultrasound evaluations, we found that both the Allen test and the handheld Doppler evaluation were reliable for determining arterial patency when they indicated positive results (patent artery), resulting in a high positive predictive value. However, the Doppler ultrasonography results were not well correlated with clinical test results showing a nonpatent artery (→Fig. 7), resulting in a large number of false negatives. Our sample size was small, but we propose that the clinical evaluations are sufficient to assess vascular repair.⁴

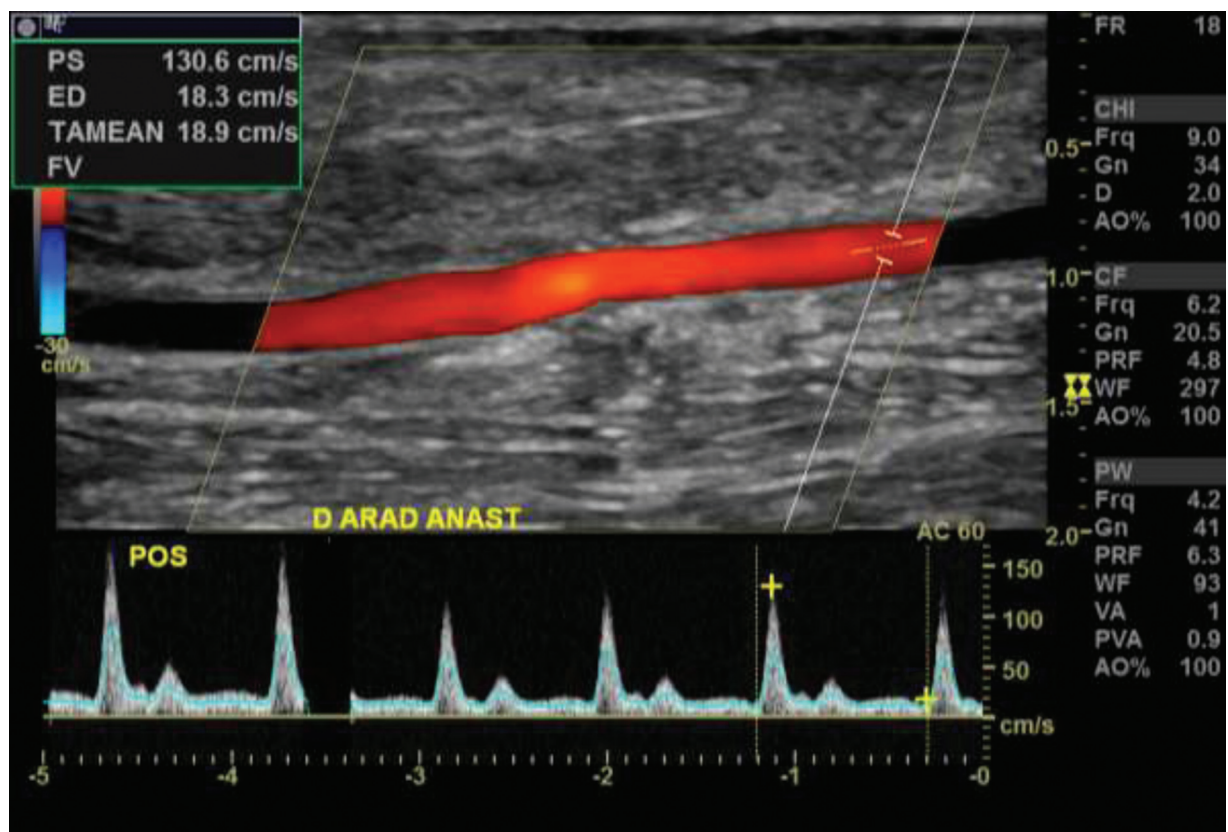


Fig. 6 Doppler ultrasonography examination showing a patent artery after arteriorrhaphy.

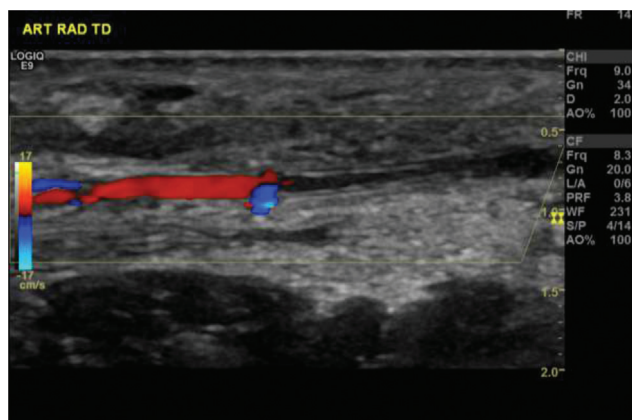


Fig. 7 Doppler ultrasonography examination showing an obstructed artery.

We conclude that clinical evaluation using a handheld Doppler device and the Allen test is reliable when a patent artery is observed on clinical evaluation. However, if the clinical evaluation reveals nonpatent arteries, the result must be confirmed using ultrasonography.

Financial Support

This work was supported by the Instituto de Pesquisa e Ensino Home, Brasilia, DF, Brazil.

Conflict of Interests

The authors have no conflict of interests to declare.

References

- 1 Thai JN, Pacheco JA, Margolis DS, et al. Evidence-based comprehensive approach to forearm arterial laceration. *West J Emerg Med* 2015;16(07):1127–1134
- 2 Lannau B, Bliley J, James IB, et al. Long-term patency of primary arterial repair and the modified cold intolerance symptom severity questionnaire. *Plast Reconstr Surg Glob Open* 2015;3(11):e551
- 3 Andreev A, Kavrakov T, Karakolev J, Penkov P. Management of acute arterial trauma of the upper extremity. *Eur J Vasc Surg* 1992;6(06):593–598
- 4 Lebowitz C, Matzon JL. Arterial injury in the upper extremity: evaluation, strategies, and anticoagulation management. *Hand Clin* 2018;34(01):85–95
- 5 Keleş MK, Şimşek T, Polat V, Yosma E, Demir A. Evaluation of forearm arterial repairs: Functional outcomes related to arterial repair. *Ulus Travma Acil Cerrahi Derg* 2017;23(02):117–121
- 6 Franz RW, Goodwin RB, Hartman JF, Wright ML. Management of upper extremity arterial injuries at an urban level I trauma center. *Ann Vasc Surg* 2009;23(01):8–16
- 7 Fisher RA. The logic of inductive inference. *J R Stat Soc* 1935; 98:39–82
- 8 Pagano M, Gauvreau K. *Princípios de bioestatística. Tradução de Luiz Sérgio de Castro Paiva. Revisão técnica de Lúcia Pereira Barroso* São Paulo: Pioneira Thomson Learning; 2004
- 9 SAS Institute Inc. *SAS/STAT® user's guide, version 9.4*. Cary, NC: SAS Institute Inc; 2019
- 10 Gelberman RH, Blasingame JP, Fronck A, Dimick MP. Forearm arterial injuries. *J Hand Surg Am* 1979;4(05):401–408
- 11 Bornmyr S, Arner M, Svensson H. Laser Doppler imaging of finger skin blood flow in patients after microvascular repair of the ulnar artery at the wrist. *J Hand Surg Br* 1994;19(03):295–300
- 12 Rothkopf DM, Chu B, Gonzalez F, Borah G, Ashmead D 4th, Dunn R. Radial and ulnar artery repairs: assessing patency rates with color Doppler ultrasonographic imaging. *J Hand Surg Am* 1993;18(04): 626–628
- 13 Rasulic L, Cinara I, Samardzic M, et al. Nerve injuries of the upper extremity associated with vascular trauma-surgical treatment and outcome. *Neurosurg Rev* 2017;40(02):241–249
- 14 Nunley JA, Goldner RD, Koman LA, Gelberman R, Urbaniak JR. Arterial stump pressure: a determinant of arterial patency? *J Hand Surg Am* 1987;12(02):245–249
- 15 Chen LE, Seaber AV, Urbaniak JR. Comparison of 10-0 polypropylene and 10-0 nylon sutures in rat arterial anastomosis. *Microsurgery* 1993;14(05):328–333