

Grafts in Endonasal Rhinoplasty

Daniel D. Lee, MD¹ Ziad Katrib, MD¹ Edwin F. Williams, MD, FACS¹

¹Department of Otolaryngology, Albany Medical Center, Albany, New York

Address for correspondence Edwin F. Williams, MD, FACS, Department of Otolaryngology, Albany Medical Center, 50 New Scotland Avenue, Albany, NY 12206-1043 (e-mail: ewilliams@williamssurgery.com; lee.dan46@gmail.com).

Facial Plast Surg 2022;38:2–6.

Abstract

Keywords

- ▶ endonasal rhinoplasty
- ▶ cosmetic rhinoplasty
- ▶ endonasal grafting
- ▶ surgical technique

Rhinoplasty is arguably one of the most challenging but rewarding procedures for the facial plastic surgeon. To adequately improve facial aesthetic parameters and preserve nasal function, the appropriate utilization of grafts is of utmost importance. While there is no best method, I found that in my hands, the endonasal approach allowed me to achieve greater control over my results by limiting dissection, utilizing less cartilage, and minimizing variables. In this manuscript, I outline the surgical pearls I have developed throughout my career that have helped me execute these grafts efficiently and effectively.

Rhinoplasty is arguably one of the most challenging but rewarding procedures for the facial plastic surgeon. To adequately improve facial aesthetic parameters and preserve nasal function, the appropriate utilization of grafts is of utmost importance. Early in my career, I subscribed to the open structure concept.¹ However, in 2002, after critically reviewing my results, my paradigm shifted toward endonasal rhinoplasty. While there is no best method, I found that in my hands, the endonasal approach allowed me to achieve greater control over my results by limiting dissection, utilizing less cartilage, and minimizing variables.^{2,3}

At first, the transition to a closed approach can certainly be daunting as the surgeon's anatomic exposure is substantially limited. However, after understanding the pocket principle and philosophy of endonasal rhinoplasty, grafts can be confidently and consistently deployed with little risk of graft mobilization. In this manuscript, I outline the surgical pearls I have developed throughout my career that have helped me execute these grafts efficiently and effectively.

Surgical Technique

Access to the Nasal Dorsum

1. Use a 15 blade to make an intercartilaginous incision in the left nasal cavity and to expose both sides of the nasal dorsum. Dissect in a supracartilaginous plane bilaterally. Ensure that you maintain a thick, soft tissue envelope to prevent telangiectasia formation and prevent an inadvertent puncture wound through the overlying skin.

2. If the profile needs to be taken down, lift the periosteum off the nasal bones with a Joseph periosteal elevator and release any remaining fibrous attachments with Metzenbaum scissors. Remember to be precise and only lift the periosteum off the bony dorsum that you plan to reduce. Maintaining an intact periosteum on the lateral nasal wall and maxillary process will prevent nasal wall collapse following osteotomies if indicated.⁴
3. Use a converse retractor to allow for full visualization of the cartilaginous and bony dorsum. At this point, the profile can either be taken down and or dorsal grafts can be implemented.

Radix Graft

1. Use septal cartilage for the radix graft. Taper the caudal end of the graft so that it is thinner and narrower compared with the cephalic portion. Bevel the edges of the graft to avoid external visualization of the graft margins.
2. At ~1 mm (mm) cephalic to the midline of the graft, place an anchoring stitch with a 5.0 chromic suture by taking a 2 mm bite starting and ending at the ventral surface of the graft. The stitch is oriented in this fashion so that the knot remains below the graft when employed.
3. Use the same needle to impale the graft 2 mm caudal to the cephalic edge of the graft from the ventral to dorsal surface. The stitch will now act as a reference point for the leading edge of the graft (▶**Fig. 1**).
4. Gently morselize the graft with a handheld morselizing forceps (▶**Fig. 2**). I prefer this instrument compared with

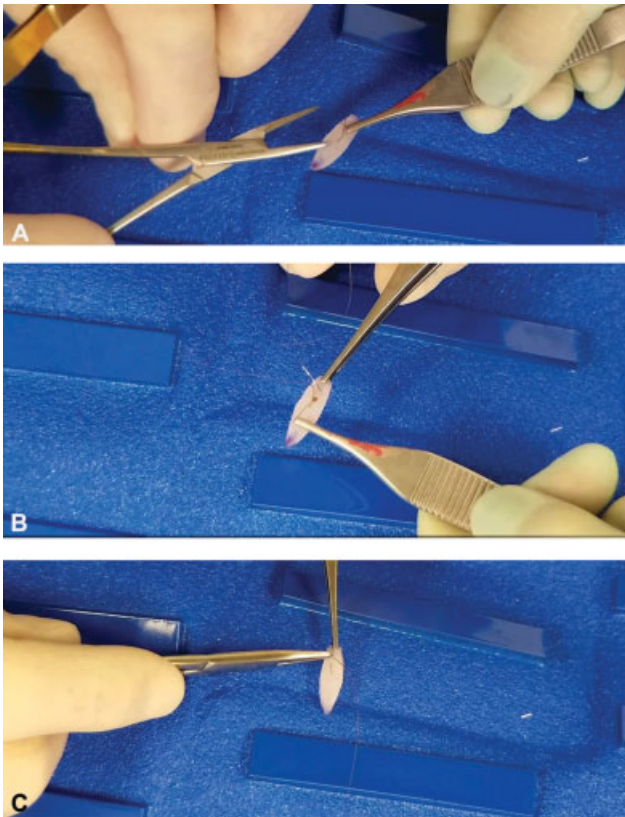


Fig. 1 (A) Anchoring stitch is secured so that the knot is facing the ventral surface of the graft. (B) The same needle is used to impale the graft 2 mm caudal to the cephalic edge from the ventral to dorsal surface. (C) Dorsal surface of the graft. Needle driver pointing to the stitch that serves as a reference point for the leading edge of the graft.

- the cartilage crusher as it allows the surgeon to weaken the cartilage with much greater control. Do not be overly aggressive as you can easily compromise the graft and stitch.
5. Identify the appropriate starting point on the radix (typically parallel to the level of the supratarsal crease) and mark this with a pen.
 6. Use a converse retractor and headlight to transilluminate the soft tissue envelope and place the stitch 2 mm caudal to the external point. This will accurately match the leading edge of the graft to the intended starting point.
 7. Advance the needle through the skin and anchor the stitch to the glabella. Remember you cannot use the pocket principle when placing a radix graft as the approach to the dorsum creates a large void. Thus, every radix graft must

be sutured and anchored in place to prevent graft mobilization (► **Fig. 3**).

8. Following graft placement, minor dorsal refinements can be addressed with diced cartilage that I have found to be reliable and forgiving. If utilized, perform this as the last surgical step to prevent unintended graft mobilization.

Spreader Graft

1. Pack the contralateral nasal cavity with a moist Raytec sponge to create a buttress to push against.
2. Inject 1 mL (mL) of 1% lidocaine with 1:50,000 epinephrine ~2 mm caudal to the nasal valve to hydrodissect the mucoperichondrial flap.
3. Use a 15 blade and make a vertical incision that is the precisely the size of the harvested spreader graft.
4. Establish a mucoperichondrial pocket using a sharp Freer elevator. Maintain a 1 to 2 mm bridge of intact mucoperichondrium superiorly and inferiorly so that a tight pocket is established. If the pocket is unintentionally violated superiorly, reapproximate the upper lateral cartilage to the septum with a 6.0 polydioxanone suture. Go deep to superficial on the septum and superficial to deep on the upper lateral cartilage so that the knot is kept down and away from the dorsum.
5. Once the pocket is established, advance the spreader graft with cartilage forceps. Prior to advancing the graft, have the assistant retract the mucosal incision laterally with a tiny double skin hook to provide counter-traction. If significant resistance is met, do not push too hard as the graft can easily violate the pocket superiorly through the dorsum or to the contralateral nasal cavity.
6. As an insurance policy, if there is any concern about the viability of the pocket, use a 5.0 chromic suture to impale the spreader graft and place multiple mattress sutures on the septum to immobilize the graft and re-establish a tight pocket (► **Video 1**).⁵

Video 1

Endonasal spreader graft: our surgical technique. Online content including video sequences viewable at: <https://www.thieme-connect.com/products/ejournals/html/10.1055/s-0041-1729633>.

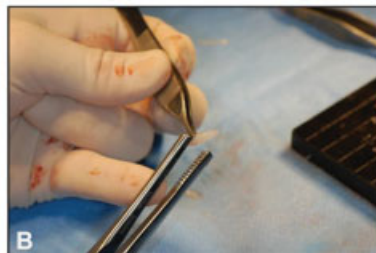
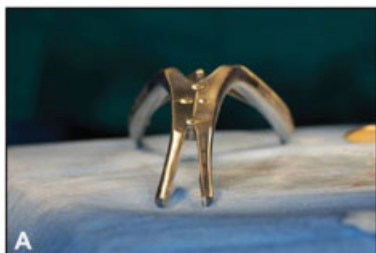


Fig. 2 (A) Handheld morselizing forceps. (B, C) Compared with using a mallet and handheld cartilage crusher, notice how the morselizing forceps allows the surgeon to have greater precision and control when handling the radix graft.

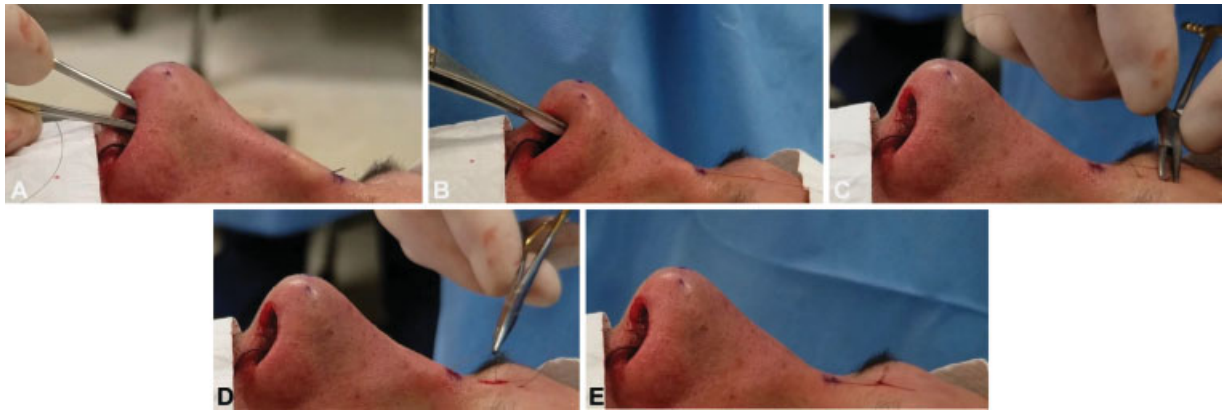


Fig. 3 (A) Needle inserted 2 mm caudal to the externally marked starting point so that the leading edge of the radix graft is aligned appropriately. (B) Gently pull the anchoring stitch while advancing the graft to help facilitate placement. (C, D) Stitch anchored to the glabella. (E) Anchoring stitch removed 1 week following surgery.

Alar Batten Graft

- 1) Use a wide double skin hook and your ring finger to evert the alar rim and identify the caudal border of the lower lateral cartilage.
- 2) Using your ring finger as a buttress, make a marginal incision with a 15 blade ~4 to 5 mm in length.
- 3) Dissect a tunnel in a supracartilaginous plane ~1 cm superiorly and then laterally toward the piriform aperture. Use the ring finger to palpate the tip of the Stevens scissors to confirm that the pocket rests over the ascending process of the maxilla. Avoid the common mistake of making the pocket too medial. If this is done, nasal obstruction can paradoxically worsen, and the graft can also be felt or visualized by the patient externally.
- 4) After the pocket is established, have the assistant evert and retract both ends of the incision with skin hooks to provide adequate counter-traction when advancing the graft.
- 5) Use cartilage forceps to first advance the graft superiorly, and then angle the graft laterally so that it is resting on the ascending maxillary process (► **Video 2**).

Video 2

Endonasal alar batten graft: our surgical technique. Online content including video sequences viewable at: <https://www.thieme-connect.com/products/ejournals/html/10.1055/s-0041-1729633>.

Alar Rim Graft

1. This graft is highly effective in both addressing alar-tip junction concavities and/or 1 to 2 mm of cephalic malposition (► **Fig. 4**). Identify where the concavity is greatest on the alar margin and mark this spot with a pen.
2. Use a wide double skin hook and your ring finger to evert the alar rim to distinguish the caudal border of the lower lateral cartilages.
3. Use a 15 blade to make a 3 to 4 mm incision on the mucosal surface of the nasal rim at the predetermined

marked position. The length of the incision is deliberately small to prevent the risk of graft extrusion.

4. Use a Stevens scissors to make a lateral and medial pocket in a supracartilaginous plane. Make the lateral pocket larger than the medial pocket. The smaller medial pocket is essential so that the edge of the graft does not line up with the initial incision. Remember the pocket should be no larger than the graft that is typically 6 to 7 mm long and 2 to 3 mm wide.
5. When harvesting the graft, avoid the temptation of making the graft too large as the risk of graft extrusion and visibility increases.
6. Create the appropriate counter-traction with skin hooks and advance the graft with cartilage forceps. Advance the graft laterally first to allow the medial edge of the graft to enter the incision. Then push the graft medially to lock the graft in a tight pocket.

Alar Composite Graft

1. For patients with cephalic malposition greater than 1 to 2 mm or patients with excess columellar show, consider an alar composite graft.
2. Identify the point on the lower lateral cartilage where there is the highest notch or where the columella is most exposed. Mark this with a pen.
3. Use a wide double skin hook and ring finger to evert the lower lateral cartilage and make a marginal incision at the predetermined point. Make sure the incision is not too caudal because the incision will move caudally when you set in the composite graft.
4. Use a Stevens scissors to unfurl the alar margin caudally (not cephalically). This will mobilize the alar margin caudally and bring the nostril down.
5. Harvest a composite graft. I prefer using the concha cymba as a donor site.
6. Place a Raytec gauze in between the fingers of your non-dominant hand and hold the ear. This will prevent your hand from slipping and provide a buttress to cut against.
7. Create a fusiform incision only through the skin with a 15 blade. During the second pass, go through the cartilage without violating the postauricular skin.

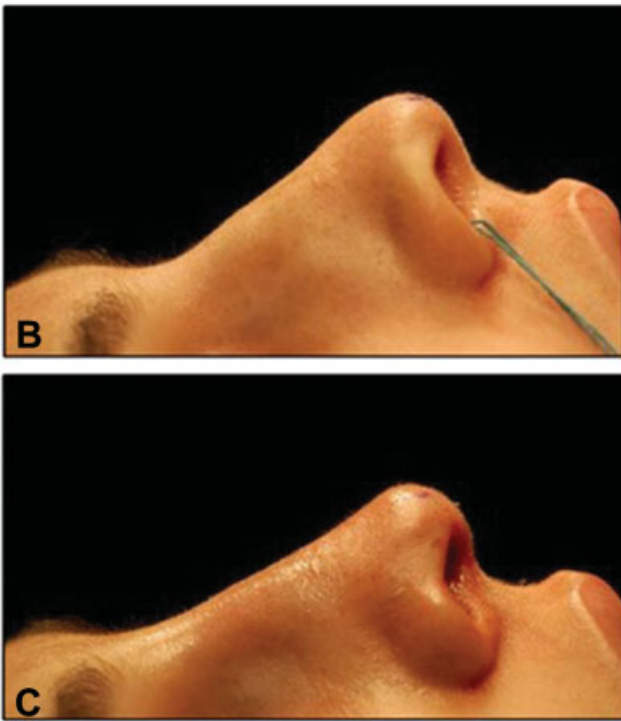
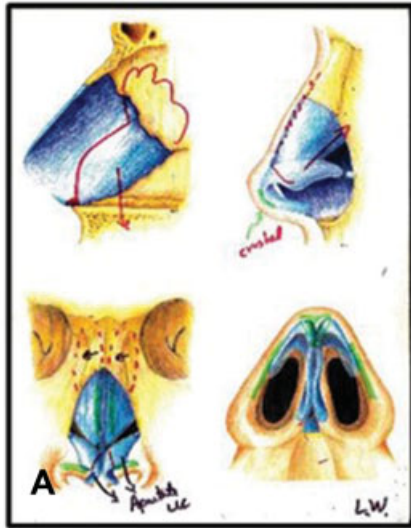


Fig. 4 (A) Surgical schematic. Green markings indicate the grafts that were utilized intraoperatively. In summary, this endonasal rhinoplasty consisted of a septoplasty with cartilage harvest, dorsal hump removal, osteotomies, and amputation of the lower lateral cartilages. A rim graft, spreader graft, and flakes of cartilage were used as a tip graft. (B, C) Intraoperative result immediately after surgical intervention. Notice how the rim graft and transected lower lateral cartilage can work synergistically to lower the alar margin and address the patient's cephalic malposition. By utilizing flakes of cartilage on the tip, a subtle supratip break is established creating an appropriate tip to supratip relationship.

8. Use an Adson-Brown forceps and Stevens scissors to dissect the graft off the postauricular skin. Care is taken to avoid separating the superficial skin from the conchal cartilage so that the composite graft remains intact.
9. After harvesting the graft, impale the graft with a 5.0 chromic needle on the caudal edge of the graft. Then go deep to superficial on the caudal end of the vestibular

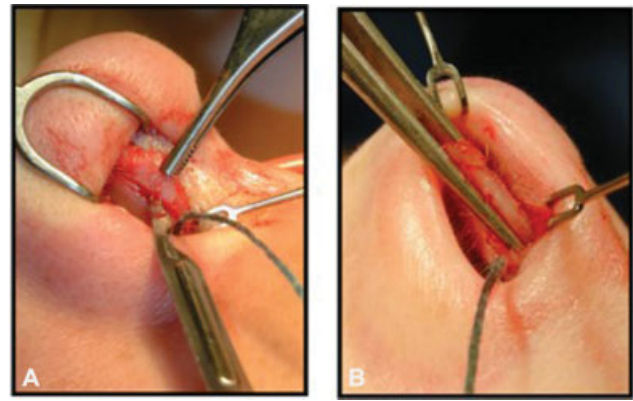


Fig. 5 Columellar strut placement. (A) Incision is placed through both the vestibular mucosa and medial crus. (B) Note the position of the skin hooks. This will provide the appropriate amount of counter-traction and help facilitate graft placement.

mucosa and tie a knot. This is often the hardest stitch to accomplish.

10. Gently use a Q-tip to push the graft into the potential space to approximate the remainder of the graft edges to the mucosa. Place a second stitch on the opposite side cephalic to the initial stitch with the initial bite going into the graft and then to the vestibular skin.
11. Once both opposing stitches are in place, place the remainder of the interrupted sutures circumferentially around the graft to secure it in place (– **Video 3**).

Video 3

Endonasal alar composite graft: our surgical technique. Online content including video sequences viewable at: <https://www.thieme-connect.com/products/ejournals/html/10.1055/s-0041-1729633>.

Columellar Strut

1. Use a 15 blade to make an incision through the right vestibular skin and medial crura.
2. Use a Stevens scissors to dissect a pocket between the medial crus and inferiorly to the nasal spine and superiorly to the dome.
3. Have the assistant retract the caudal end of the incision anteriorly and use a tiny forceps to retract the nasal ala superiorly to create the proper counter-traction and advance the columellar strut into the pocket (– **Fig. 5**).
4. Initially advance the graft past the nasal spine so that the superior edge of the graft can pass through the incision.
5. After the strut is adequately in between the medial crura, advance the graft superiorly toward the dome so that the graft is resting just above the nasal spine. If the graft buckles, remove the graft and make it smaller. The biggest mistake with a columellar strut is making the graft too large

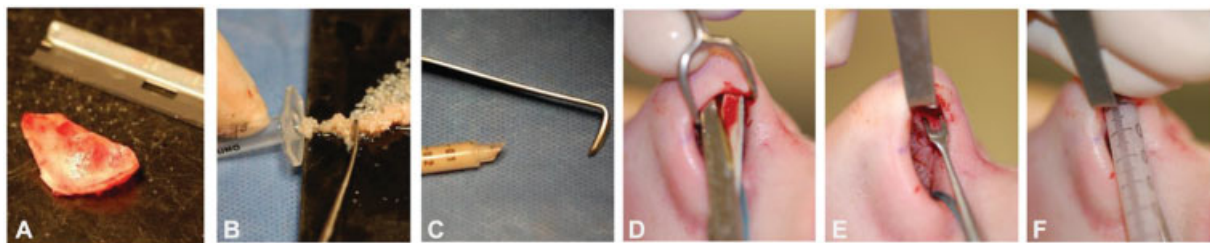


Fig. 6 Tip graft with diced cartilage. (A) Dice the harvested cartilage with a Weck blade and mix this with 1 mL of saline (B) Place the mixture into a 1 mL tuberculin syringe. (C) Note how the tip of syringe is beveled by cutting a portion of the leading edge with heavy Mayo scissors. This design will make it easier for the syringe to enter the small marginal incision during graft placement. (D) After the marginal incision, dissect a precise pocket on the tip. Palpate the tip of the Stevens scissors to delineate the lateral extent of the pocket. (E) Use a baby converse retractor and a tiny double skin hook to allow visualization into the pocket. (F) The beveled syringe should advance through the marginal incision with ease. Avoid the temptation of injecting too quickly. Inject slowly so that the cartilage can evenly distribute throughout the pocket.

leading to a widened or deviated columella. Additionally, patients often complain about a clicking sensation that is a result of the inferior aspect of the graft sliding back and forth along the nasal spine. If the columellar strut appears too bulky despite graft reduction, consider using suture techniques (such as a tongue and groove) in conjunction with small flakes of cartilaginous plumping grafts at the nasal base as an alternative option to establish tip support.⁶

Tip Graft

1. Harvest the tip graft from alar cartilage as it is more pliable than septal cartilage. If septal cartilage is utilized, gently morselize the graft to make it softer. Use a handheld cartilage crusher for greater control. Shave flakes of cartilage from the harvested graft with a 10 blade. I prefer placing flakes of cartilage as opposed to solid grafts as it is incredibly soft and pliable. Remember the tip is the most unforgiving area for contour deformities.
2. Use a wide double skin hook and identify the caudal border of the lower lateral cartilage just under the dome.
3. Make a marginal incision with a 15 blade and dissect in a supracartilaginous plane over the dome using Stevens scissors.
4. Palpate the tip of the Stevens scissors with your ring finger of the nondominant hand to distinguish the lateral most extent of the pocket.
5. Use a baby converse to visualize the pocket and gently place the shaved pieces of cartilage in the pocket with cartilage forceps.
6. If further tip refinements are needed, use a Weck blade and dice some cartilage. Mix this with saline in a 1 mL tuberculin syringe and gently inject the diced cartilage into the pocket (→ Fig. 6).

Conclusion

These grafts have been the workhorses of my rhinoplasty career. At first, endonasal rhinoplasty can be intimidating as it is an entirely different operation and philosophy. In 2002, my paradigm shifted where I found in my hands, a closed approach required less dissection, utilized less cartilage, and provided greater control over my results. Rhinoplasty is certainly far from a perfect operation. However, I have found over the years that the key to rhinoplasty is simplicity. By adhering to the pocket principle and subscribing to the surgical pearls stated above, I hope that the rhinoplasty surgeon can add another skillset to their armamentarium of options.

Conflict of Interest

None declared.

References

- 1 Johnson CM, Toriumi DM. Open structure rhinoplasty. Philadelphia: Saunders; 1989
- 2 Constantian MB. Differing characteristics in 100 consecutive secondary rhinoplasty patients following closed versus open surgical approaches. *Plast Reconstr Surg* 2002;109(06):2097–2111
- 3 Williams EF III, Lam SM. A systematic, graduated approach to rhinoplasty. *Facial Plast Surg* 2002;18(04):215–222
- 4 Tardy ME. Rhinoplasty: the art and science. California: Saunders; 1997
- 5 Pontius AT, Williams EF III. Endonasal placement of spreader grafts in rhinoplasty. *Ear Nose Throat J* 2005;84(03):135–136
- 6 Williams EF. Alar-columellar disharmony using the tongue-in-groove maneuver in primary endonasal rhinoplasty. *Arch Facial Plast Surg* 2012;14(04):283–288