









Microinvasive Meniscal Suture with Disposable Needle*

Sutura meniscal microinvasiva com agulha descartável

Edmar Stieven Filho¹  Carolline Popovicz Nunes²  Fernando Martins Rosa³ 
Paul André Alain Milcent⁴  Mário Namba⁴  Mauro Batista Albano⁵ 

¹Department of Surgery, Universidade Federal do Paraná, Curitiba, PR, Brazil

²Department of Orthopedics and Traumatology, Hospital das Clínicas, Universidade Federal do Paraná, Curitiba, Paraná, Brazil

³Department of Surgery, Universidade Federal do Paraná, Curitiba, PR, Brazil

⁴Department of Surgery, Universidade Federal do Paraná, Curitiba, PR, Brazil

⁵Hospital de Clínicas, Universidade Federal do Paraná, Curitiba, PR, Brazil

Address for correspondence Edmar Stieven Filho, PhD, Rua Gen. Carneiro, 181, Department of Surgery, Curitiba, Paraná, Brazil, Brazil (e-mail: filho2000@gmail.com).

Rev Bras Ortop 2022;57(3):524–528.

Abstract

The first meniscal suture was performed in 1885 and took about a century to become popular. Currently, all-inside meniscal repair devices are widely used. However, this technique presents the disadvantage of being a method dependent on specific devices, presenting a higher cost than other techniques. This high cost limits the use of such a technique in many locations. The objective of the present technical note is to describe a microinvasive meniscal suture technique as a modification of the all-inside technique, using a disposable 40 × 12 mm procedure needle. The authors believe that the proposed modification to the technique can make it more popular, enabling the use of the microinvasive technique in places with limited resources.

Keywords

- tibial meniscus injuries
- suture techniques
- arthroscopy

Resumo

A primeira sutura meniscal foi realizada em 1885 e levou cerca de um século para tornar-se popular. Atualmente, os dispositivos de reparo meniscal all-inside são amplamente utilizados. Contudo, esta técnica apresenta a desvantagem de ser um método dependente de dispositivos específicos, apresentando um custo superior aos de outras técnicas. Este valor elevado limita o uso de tal técnica em muitos locais. O objetivo da presente nota técnica é descrever uma técnica de sutura meniscal microinvasiva, como uma modificação da técnica all-inside, utilizando uma agulha descartável de procedimento de 40 × 12 mm. Os autores acreditam que a modificação proposta para a técnica pode torná-la mais popular, possibilitando o uso da técnica microinvasiva em locais com recursos limitados.

Palavras-chave

- lesões do menisco tibial
- técnicas de sutura
- artroscopia

* Study carried out at the Hospital de Clínicas of the Universidade Federal do Paraná, Curitiba, PR, Brazil.

received
April 7, 2020
accepted
December 1, 2020
published online
October 14, 2021

DOI <https://doi.org/10.1055/s-0041-1729938>.
ISSN 0102-3616.

© 2021. Sociedade Brasileira de Ortopedia e Traumatologia. All rights reserved.

This is an open access article published by Thieme under the terms of the Creative Commons Attribution-NonDerivative-NonCommercial-License, permitting copying and reproduction so long as the original work is given appropriate credit. Contents may not be used for commercial purposes, or adapted, remixed, transformed or built upon. (<https://creativecommons.org/licenses/by-nc-nd/4.0/>)

Thieme Revinter Publicações Ltda., Rua do Matoso 170, Rio de Janeiro, RJ, CEP 20270-135, Brazil

Introduction

For a long time the meniscus was considered a structure without function that should be removed in any sign of abnormality.¹ Thus, until the 1970s, meniscus removal occurred as standard treatment.¹ However, meniscal sutures demonstrate a chondroprotective effect in relation to long-term meniscectomies.² In addition, several studies have shown that menisci play a fundamental role in the distribution of knee load and stability, thus, they are currently considered vital structures in the healthy knee that should be preserved whenever possible.²

The first meniscal suture was performed in 1885 by Annandale and took about a century to become popular.³ It was only in the 1970s that Ikeuchi apud Zhang et al.³ described meniscal repair by arthroscopy, using a disposable needle. Over the years, arthroscopic and instrumental techniques were developed, and the procedure was then popularized, with a peak growth in the number of meniscal repairs between 2005 and 2011.³

Meniscal repair techniques can be divided into three forms. They can be performed by addressing the intra-articular meniscus and passing the suture material to extra-articular (inside-out). Another way is to start by the skin, introducing the suture material to intra-articular (outside-in). There is still the all-inside technique, in which all steps are made inside the joint.

The all-inside arthroscopic suture technique has the advantage of not needing incisions in the skin, having a low rate of complications and results similar to those of other suture techniques. One disadvantage of the all-inside system is that it has a higher cost. Usually, disposable devices are used, and their use significantly increases the final cost of the procedure. This can be a limiting factor of its use in many locations.⁴

In this context, the objective of the present work is to describe a microinvasive meniscal suture technique, as a modification of the all-inside technique, using a disposable 40 × 12 mm procedure needle.

Description of the Surgical Technique

The procedure begins with incisions for the anterolateral and anteromedial portals of arthroscopy, adjacent to the lateral

and medial edges of the patellar ligament, respectively. Arthroscopic inspection of the knee is carried out. The meniscal lesion is identified and evaluated to determine its location, size and degree of instability. The meniscal lesion is then prepared with debridement of the edges of the lesion to increase the healing potential. The injury is then reduced, and the stitches are started.

The procedure starts with the insertion of a 1-0 polyglycolic acid thread into the 40 × 12 mm needle. The needle is then inserted into the interarticular line of the knee, with percutaneous transfixation, from the outside in, monitored by the articular side under arthroscopy, transfixing the meniscus in the injured region (► **Figure 1**).

The needle leads a suture thread, which will remain in the path, and with the help of a grasper inserted by the anteromedial portal, the intra-articular thread is pulled by the portal, keeping the rest of the thread inside the needle. The needle is then removed from the meniscus, without removing it from the skin (► **Figure 2**).

Then, the needle is reintroduced into the meniscus near the first insertion (► **Figure 3**).

The second end of the wire is then pulled with the aid of the grasper (► **Figure 4**). With both ends of the wire in hand, the surgeon can hold the knot out of the joint. After the knot is made, it is driven to the desired region with the aid of a knot pusher (► **Figure 5**).

Final Comments

Meniscal surgeries are among the most commonly performed procedures in orthopedics.⁴ The current primary options for arthroscopic meniscal surgery are partial meniscectomy or meniscal repair. However, the findings about the vital functions of the meniscus and the development of osteoarthritis reported after its resection forced surgeons to protect as much of this structure as possible by repairing or reconstructing the meniscus whenever possible.² Currently, there are three main techniques for meniscus repair: inside-out, outside-in, and all-inside. All-inside meniscal repair devices, first reported in 1993, are widely used today.⁴ However, this technique has the disadvantage of being a method dependent on specific devices developed by only a

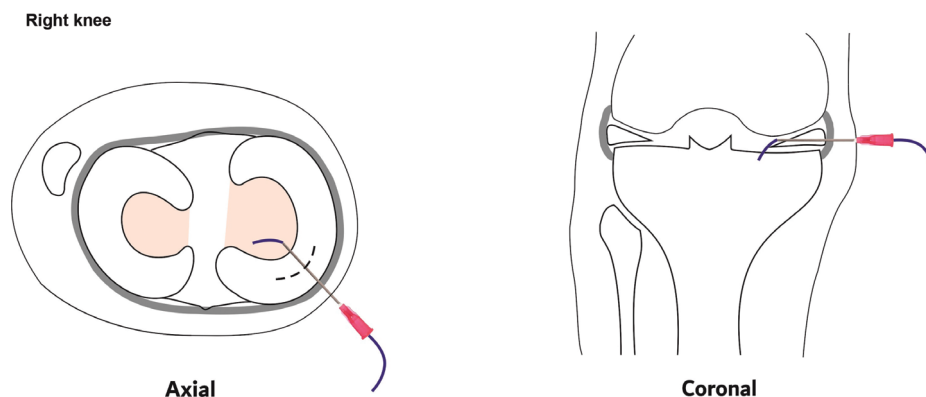
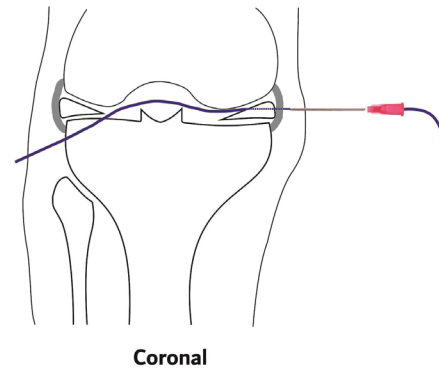
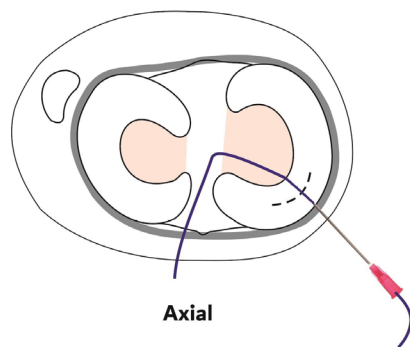
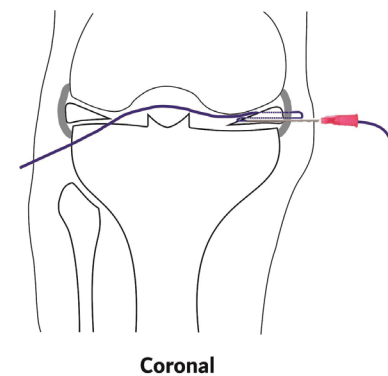
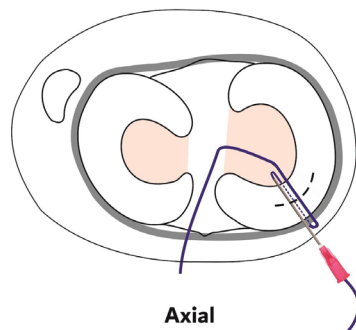


Fig. 1 Axial and sagittal view of the needle insertion with the wire, in the interarticular line of the knee, transfixing the injured region.

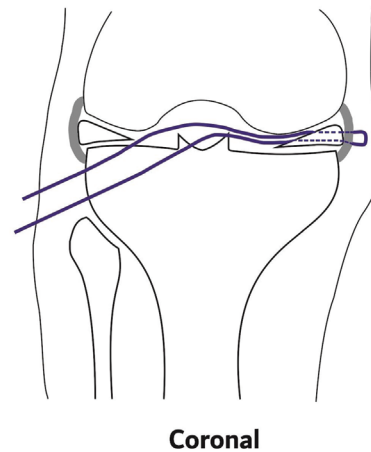
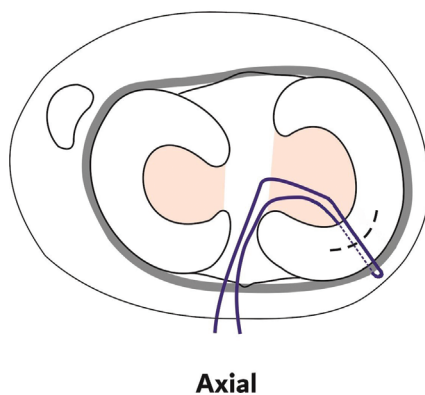
Right knee

**Fig. 2** Axial and sagittal view of the needle removal from the meniscus, stopping between the capsule and the skin.

Right knee

**Fig. 3** Axial and sagittal view of needle and wire reintroduction into the meniscus near the first insertion.

Right knee

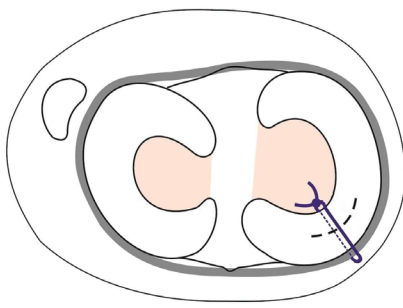
**Fig. 4** Axial and sagittal view of the ends of the wire outside the joint.

few companies, thus consequently presenting a higher cost than other techniques.⁴ In this scenario, the authors present a modification of the all-inside suture technique using a disposable 40×12 mm procedure needle. The variation takes place in the instrument used, which enables the use of the technique in a more democratic way due to the low cost and to the availability of the materials used.

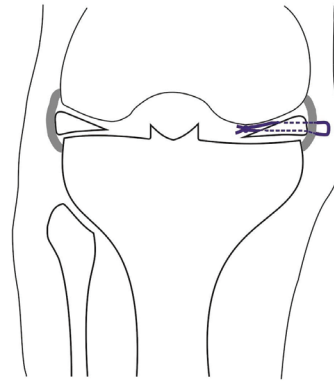
A successful repair requires stabilization of the injured meniscal tissue during the healing process, in which many

factors can influence the final result, including the choice of the repair technique, repair methods and number of sutures.⁵ Although there are several meniscal repair techniques available, the outside-in technique is still considered the gold standard for meniscal repair. However, the all-inside technique has the advantage of not requiring an additional incision, leading to a decrease in operative time.⁴ Furthermore, in a recent systematic review of Fillingham, when comparing all-inside and outside-in repair techniques, no

Right knee



Axial



Coronal

Fig. 5 Axial and sagittal view of the final result of knot making.

differences in failure rates, functional results or complication rates were observed.⁶ Thus, the all-inside technique has been an increasingly used method for most meniscal lesions due to its advantages of avoiding the opening of accessory portals and additional incisions, easy applicability, use of bioabsorbable implants and relatively lower risk of lesions in posterior neurovascular structures.⁴

The choice of the technique to be used for meniscal repair depends on several factors, such as the site of the injury, type, etiology, time, association with ligament injury, expectations and age of the patient, in addition to the experience of the surgeon with the technique to be used. The authors believe that the microinvasive meniscal suture technique is best indicated for longitudinal lesions of the body and of the anterior horn. On the other hand, the authors do not indicate the use of the technique for lesions close to noble structures, because the risk of inadvertent injury of these structures is high for any percutaneous technique.

Although it is a promising technique, the modification of the all-inside technique proposed by the authors presents some difficulties. One of them is to reach the site of the injury, since the procedure starts with the needle in the skin and goes towards the meniscus. Another important point is not to have the movement blocked by contact of the needle with the tibial plateau or with the femoral condyle. In addition, it is necessary that the surgeon has the ability to perform the extra-joint point and lead it to the meniscus. This may be a limiting factor, since such a skill is not common to knee surgeons, being more practiced in arthroscopic shoulder surgeries. For the above reasons, all-inside suture devices tend to be faster than manually performed sutures, as proposed by the present study.

In general, in recent decades, there has been an increase in treatment costs in the medical area, due to the introduction of more modern technologies and new medication.⁷ This ends up becoming a problem for universal public health systems, such as the Brazilian Unified Health System (SUS, in the Portuguese acronym), and private health insurance, which adds to the lack of resources or emergence of these new technologies, making health management even more difficult in the country.⁷ In this context, there is a worldwide

trend towards efficient solutions that allow the use of new approaches that can benefit the patient associated with cost control.⁸ For example, currently, there is difficulty in releasing all-inside meniscal suture devices in the insurances and in the SUS, since the final price of surgery is expensive. This limits the use of the technique, even when it would be the best approach option for the patient. The authors believe that the proposed modification to the technique can make it more popular, enabling the use of the microinvasive technique in places with limited resources.

Financial Support

There was no financial support from public, commercial, or non-profit sources.

Conflict of Interests

The authors have no conflict of interests to declare.

References

- 1 Dandy DJ, Jackson RW. The diagnosis of problems after meniscectomy. *J Bone Joint Surg Br* 1975;57(03):349–352
- 2 Xu C, Zhao J. A meta-analysis comparing meniscal repair with meniscectomy in the treatment of meniscal tears: the more meniscus, the better outcome? *Knee Surg Sports Traumatol Arthrosc* 2015;23(01):164–170
- 3 Zhang AL, Miller SL, Coughlin DG, Lotz JC, Feeley BT. Tibiofemoral contact pressures in radial tears of the meniscus treated with all-inside repair, inside-out repair and partial meniscectomy. *Knee* 2015;22(05):400–404
- 4 Abrams GD, Frank RM, Gupta AK, Harris JD, McCormick FM, Cole BJ. Trends in meniscus repair and meniscectomy in the United States, 2005–2011. *Am J Sports Med* 2013;41(10):2333–2339
- 5 Beaufils P, Pujol N. Meniscal repair: Technique. *Orthop Traumatol Surg Res* 2018;104(1S):S137–S145
- 6 Fillingham YA, Riboh JC, Erickson BJ, Bach BR Jr, Yanke AB. Inside-out versus all-inside repair of isolated meniscal tears. An updated systematic review. *Am J Sports Med* 2017;45(01):234–242
- 7 Souza AA, Guerra M, Avelar EA. Proposta de metodologia para a implantação do sistema de custeio baseado em atividades para organizações hospitalares. In: Paper presented at: XVI Congresso Brasileiro De Custos, 2009, Fortaleza, CE. 2009
- 8 Silva JLV, Namba MM, Pereira FA, et al. Sutura meniscal “inside-out” com agulha de anestesia peridural. *Rev Bras Ortop* 2004;39(05):264–269