

# Coiling Using Dual Microcatheter Technique—A Novel Approach

Arvind Kumar<sup>1</sup>, Swarup Sohan Gandhi<sup>1</sup> Ashok Gandhi<sup>1</sup> Trilochan Srivastav<sup>1</sup> Devendra Purohit<sup>1</sup>

<sup>1</sup>Department of Neurosurgery, Sawai Man Singh Medical College, Jaipur, Rajasthan, India

**Address for correspondence** Swarup Sohan Gandhi, MCh, Department of Neurosurgery, Sawai Man Singh Medical College and Hospital, Jaipur, Rajasthan, India (e-mail: swarup.gandhi11@gmail.com).

Indian J Neurosurg 2022;11:80–82

## Abstract

Posterior circulation aneurysms are difficult to treat, and if an incorporated artery is arising from the neck of aneurysm, management becomes much more challenging. Here, we are describing a novel technique used to treat a patient with a large, wide-necked left vertebral artery (VA)-posterior inferior cerebellar artery (PICA) junctional aneurysm. PICA seems to be arising from the aneurysm neck, but the aneurysm neck was not very clearly defined. So, we placed a second microcatheter into PICA, which not only allowed the coils to be placed in the aneurysm, without disrupting the flow through PICA but also helpful in assessing the aneurysmal occlusion. This technique allowed coils to be placed successfully without compromising flow through PICA.

## Keywords

- ▶ Aneurysms
- ▶ endovascular treatment
- ▶ dual microcatheter

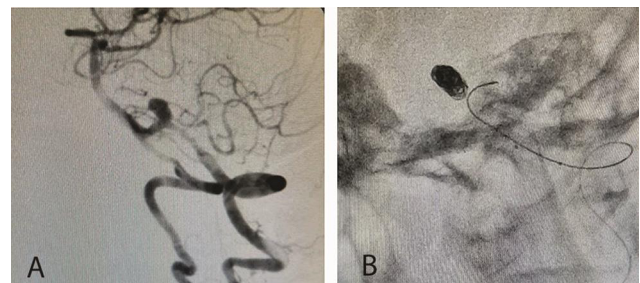
## Introduction

The surgical treatment of ruptured posterior circulation aneurysm is challenging because of the proximity with the vital structures.<sup>1</sup> Endovascular coiling is an attractive alternative, because it does not dissect important posterior fossa structures.<sup>2-4</sup> Also, coiling of aneurysms with an incorporated artery (IA) is a challenge because ischemic stroke is the most common complication due to unintentional vascular compromise. To prevent this complication, device-assisted endovascular techniques have been described.<sup>5,6</sup> We have a case of a wide-necked aneurysm, with a branch (posterior inferior cerebellar artery [PICA]) originating from the neck of aneurysm, successfully coiled with the help of a double microcatheter without any assisted device.

## Case Description

A 59-year-old woman presented to emergency with subarachnoid hemorrhage (SAH) of grade 3 as per Hunt and

Hess classification with modified Rankin scale (mRS) score of 1, angiography revealed a left PICA-vertebral artery (VA) junctional aneurysm, with PICA arising from aneurysm neck (▶**Fig. 1A**). Intravenous (IV) heparin “with bolus of 5000 U and intermittent boluses of 1000 U/h were used” during the procedure as per the activated clotting time (ACT). With an



**Fig. 1** (A) Left vertebral artery (VA) and posterior inferior cerebellar artery (PICA) junction aneurysm. (B) Showing braced coils in aneurysm with microcatheter in left PICA origin

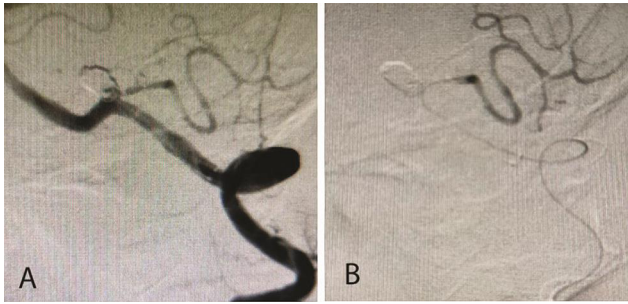
published online  
January 13, 2022

DOI <https://doi.org/10.1055/s-0041-1730875>  
ISSN 2277-954X

© 2022, Neurological Surgeons' Society of India.

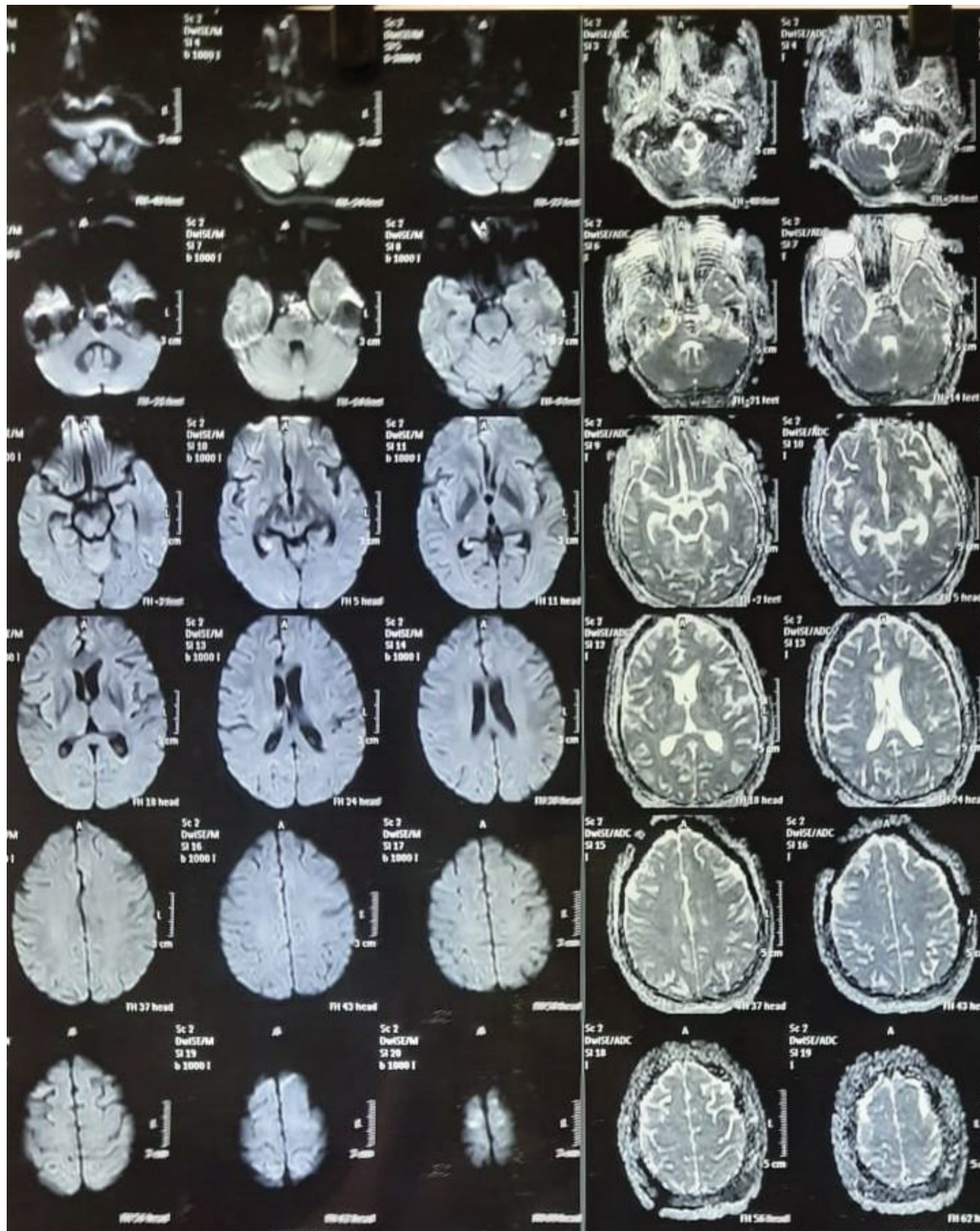
This is an open access article published by Thieme under the terms of the Creative Commons Attribution-NonDerivative-NonCommercial-License, permitting copying and reproduction so long as the original work is given appropriate credit. Contents may not be used for commercial purposes, or adapted, remixed, transformed or built upon. (<https://creativecommons.org/licenses/by-nc-nd/4.0/>).

Thieme Medical and Scientific Publishers Pvt. Ltd. A-12, 2nd Floor, Sector 2, Noida-201301 UP, India



**Fig. 2** (A) Left vertebral artery (VA) arteriogram following coiling showing almost complete occlusion of aneurysm. (B) Digital subtraction angiography (DSA) showing microcatheter in left posterior inferior cerebellar artery (PICA).

Excelsior XT-17 microcatheter, we reached the sac of PICA aneurysm placed through a 6F guiding catheter in the left VA. Another microcatheter was placed via same 6F guiding catheter into the PICA distal to origin of the aneurysm. Two detachable coils (5 mm × 20 cm helix and 5 mm × 10 cm 3D) were placed through microcatheter into the aneurysmal sac. A stable coil mass was formed in the aneurysmal sac with intact flow through left PICA (►Fig. 2A) and resulting in almost complete occlusion (►Fig. 2A) of aneurysm. More coils could not be placed, as coils were herniating into the left VA, compromising flow through left PICA (►Figs. 1 and 2) With the aneurysmal sac well occluded, the procedure was halted. Postoperatively, patient was stable with no neurological deficits. As dual microcatheters were used during the coiling of



**Fig. 3** Showing postoperative diffusion-weighted MRI brain imaging with tiny infarct in left cerebellar hemisphere.



aneurysm, so antiplatelets in form of low-molecular weight heparin (LMWH) was given in postoperative period for a period of 3 days in dose of 0.6 mL BD subcutaneously (SC). As a part of the standard postoperative protocol, when using dual microcatheters, as there is a risk of thromboembolic complications, we did diffusion-weighted MRI brain imaging, which revealed tiny infarct in left cerebellar hemisphere (► Fig. 3), but the patient was asymptomatic for the same. On discharge, the patient had mRS score of 0 with no symptoms and no deficits.

## Discussion

Large, wide-necked aneurysms, especially with a vessel arising from neck of aneurysm, are technically challenging to treat with endovascular treatment. Complete occlusion of aneurysmal sac is often not attained, owing to concern of compromising parent vessel flow or migration of coils or compromise of branch vessel.<sup>7,8</sup> There are various methods described in the literature to save the branching vessel like partial coiling, dual microcatheter placement in aneurysmal sac, balloon assisted coiling, and stent assisted coiling.<sup>9,10</sup> In 1998, Baxter et al was the first to report a dual microcatheter technique that embolized wide-neck intracranial aneurysms with excellent outcome.

In our case, we have used a novel technique of placement of one catheter into origin of branch vessel, that is, left PICA and another negotiated into the aneurysmal sac. With appropriate size of coils, compact packing of sac of aneurysm was achieved. After the removal of the microcatheter from the PICA, the coil mass remained stable. Check digital subtraction angiography (DSA) revealed patent flow through left PICA. Then coil was detached and microcatheter was removed. Coil mass remained stable with patent flow through left PICA. In this technique, there is always a possibility that after placement of coils, coils may protrude into vessel and occlude the branch, but this technique is very cost-effective, as it does not require balloon or stent and can be an effective alternative, especially in a government setup where placing a stent or balloon is not possible considering financial constraints. The placement of a second microcatheter for preservation of branch vessel is not only technically demanding but also increases the risk of thromboembolism. Precautions like systemic heparin and continuous catheter infusions should be considered. Ideally, these types of aneurysm require balloon-assisted coiling and stent-assisted coiling, but considering cost constraints, this technique was selected and performed successfully with good clinical outcome.

## Conclusion

Dual microcatheter technique like the one described above has been used in coiling, when there is a risk “of coil instability or parent vessel or branch vessel flow being compromised during coiling of” large, wide-necked aneurysms. This technique could be extrapolated to be used in the case like we have described, when use of a stent or balloon is not possible, owing to financial constraints. The potential for complications with dual microcatheter technique entails that clear indications should be there before this technique is considered.

### Funding

None.

### Conflict of Interest

None declared.

## References

- 1 Mukonoweshuro W, Laitt RD, Hughes DG. Endovascular treatment of PICA aneurysms. *Neuroradiology* 2003;45(3):188–192
- 2 Liew D, Ng PY, Ng I. Surgical management of ruptured and unruptured symptomatic posterior inferior cerebellar artery aneurysms. *Br J Neurosurg* 2004;18(6):608–612
- 3 Sejkorová A, Cihlář F, Hejčl A, Lodin J, Vachata P, Sameš M. Microsurgery and endovascular treatment of posterior inferior cerebellar artery aneurysms. *Neurosurg Rev* 2016;39(1):159–168, discussion 168
- 4 Naggara ON, White PM, Guilbert F, Roy D, Weill A, Raymond J. Endovascular treatment of intracranial unruptured aneurysms: systematic review and meta-analysis of the literature on safety and efficacy. *Radiology* 2010;256(3):887–897
- 5 Gordhan A. Microcatheter neck bridging and incorporated branch vessel protection for coil embolization of a wide-neck ruptured aneurysm: technical case report. *Neurosurgery* 2011;68(1(Suppl Operative)):40–43, discussion 43–44
- 6 Islak C, Kizilkilic O, Kocak B, Saglam M, Yildiz B, Kocer N. Use of buddy wire to facilitate Y-configure stent placement in middle cerebral artery bifurcation aneurysms with daughter branches arising from the sac: a technical note. *Oper Neurosurg (Hagerstown)* 2014;10:167–171
- 7 Guglielmi G, Viñuela F, Duckwiler G, et al. Endovascular treatment of posterior circulation aneurysms by electrothrombosis using electrically detachable coils. *J Neurosurg* 1992;77(4):515–524
- 8 Fernandez Zubillaga A, Guglielmi G, Viñuela F, Duckwiler GR. Endovascular occlusion of intracranial aneurysms with electrically detachable coils: correlation of aneurysm neck size and treatment results. *AJNR Am J Neuroradiol* 1994;15(5):815–820
- 9 Baxter BW, Rosso D, Lownie SP. Double microcatheter technique for detachable coil treatment of large, wide-necked intracranial aneurysms. *AJNR Am J Neuroradiol* 1998;19(6):1176–1178
- 10 Levy DI, Ku A. Balloon-assisted coil placement in wide-necked aneurysms. Technical note. *J Neurosurg* 1997;86(4):724–727