



Madelung Deformity – Esthetic and Functional Outcomes from the Surgical Treatment with Distal Radial Dome Osteotomy and Vickers Ligament Section*

Deformidade de Madelung – Resultado estético e funcional do tratamento cirúrgico com osteotomia em cúpula do rádio distal e secção do ligamento de Vickers

Marcos Carvalho¹  Pedro Sá Cardoso¹ Cristina Alves¹ Inês Balacó¹ Tah Pu Ling¹ Gabriel Matos¹

¹ Pediatric Orthopedic Service, Hospital Pediátrico, Centro Hospitalar e Universitário de Coimbra, Coimbra, Portugal

Address for correspondence Marcos Carvalho, MD, MSc, Av. Afonso Romão, Coimbra, 3000-602, Portugal
(e-mail: marcosfernandescarvalho@gmail.com).

Rev Bras Ortop 2022;57(1):113–119.

Abstract

Objective The present study aimed to evaluate esthetic and functional outcomes from the surgical treatment of Madelung deformity in children.

Method This is a retrospective study of pediatric patients with Madelung deformity who were surgically treated with dome osteotomy of the distal radius and Vickers ligament section from 2015 to 2018. Patients with a minimum postoperative follow-up period of 12 months were included. Demographic data, surgical technique, clinical and radiographic outcomes were analyzed. Pre and postoperative radiographic evaluation consisted of ulnar tilt, lunate subsidence, lunate fossa angle, and palmar carpal displacement measurements. The postoperative clinical evaluation consisted of ranges of motion of the wrist, visual analog scale (VAS) and Disabilities of the Arm, Shoulder and Hand (DASH) score.

Results Four patients were included, two with idiopathic Madelung deformity and two with bone dysplasia. All patients were females and presented bilateral disease. Six wrists were operated on. The median age at surgery was 15.5 years old, and the median postoperative follow-up time was of 37.5 months. The postoperative radiographic analysis revealed an average correction of $8.8 \pm 7.5^\circ$ for ulnar tilt, 3.0 ± 3.9 mm for lunate subsidence, $8.2 \pm 6.6^\circ$ for lunate fossa angle, and 4.7 ± 2.6 mm for palmar carpal displacement. Average postoperative ranges of motion of the wrist joint were $75.8 \pm 3.4^\circ$ for flexion, $62.5 \pm 14.1^\circ$ for extension, $25.7 \pm 2.9^\circ$ for radial deviation,

Keywords

- ▶ bone diseases, developmental
- ▶ osteotomy
- ▶ radius (anatomy)
- ▶ ulna
- ▶ child

* Study developed at the Pediatric Orthopedic Service, Hospital Pediátrico – Centro Hospitalar e Universitário de Coimbra, Coimbra, Portugal

received
June 3, 2020
accepted
January 8, 2021
published online
October 1, 2021

DOI <https://doi.org/10.1055/s-0041-1731362>.
ISSN 0102-3616.

© 2021. Sociedade Brasileira de Ortopedia e Traumatologia. All rights reserved.

This is an open access article published by Thieme under the terms of the Creative Commons Attribution-NonDerivative-NonCommercial-License, permitting copying and reproduction so long as the original work is given appropriate credit. Contents may not be used for commercial purposes, or adapted, remixed, transformed or built upon. (<https://creativecommons.org/licenses/by-nc-nd/4.0/>)

Thieme Revinter Publicações Ltda., Rua do Matoso 170, Rio de Janeiro, RJ, CEP 20270-135, Brazil

Resumo

40.0 ± 2.9° for ulnar deviation, 88.3 ± 2.4° for pronation, and 82.5 ± 2.5° for supination. The median VAS was 1 for residual pain, 0 for functional deficit, 0 for esthetic impairment, and 10 for recommending the surgical procedure. The median DASH score was 0.

Conclusion Madelung deformity treatment using dome osteotomy of the distal radius and Vickers ligament section results in excellent esthetic and functional outcomes.

Objetivo Avaliar o resultado estético e funcional do tratamento cirúrgico da deformidade de Madelung em idade pediátrica.

Método Estudo retrospectivo dos pacientes com deformidade de Madelung em idade pediátrica tratados cirurgicamente através de osteotomia em cúpula do rádio distal e secção do ligamento de Vickers entre 2015 e 2018. Foram incluídos doentes com tempo de seguimento pós-operatório mínimo de 12 meses. Foram analisados dados demográficos, técnica cirúrgica, resultados clínicos e radiográficos. A avaliação radiográfica pré e pós-operatória consistiu na medição da inclinação ulnar, do afundamento semilunar, do ângulo da fossa semilunar e do desvio palmar do carpo. A avaliação clínica pós-operatória consistiu na medição das amplitudes articulares do punho, escala visual analógica (EVA) e score Disabilities of the Arm, Shoulder and Hand (DASH, na sigla em inglês).

Resultados Foram incluídos quatro pacientes, dois com Madelung idiopática e dois com displasia óssea, todos do sexo feminino e com doença bilateral. Foram operados 6 punhos, a idade mediana à data de cirurgia foi 15,5 anos, e o tempo mediano de seguimento pós-operatório foi de 37,5 meses. Na análise radiográfica pós-operatória, verificou-se uma correção média de 8,8 ± 7,5° da inclinação ulnar, de 3 ± 3,9 mm do afundamento semilunar, de 8,2 ± 6,6° do ângulo da fossa semilunar e de 4,7 ± 2,6 mm do desvio palmar do carpo. Na avaliação da amplitude articular média pós-operatória, registrou-se flexão de 75,8 ± 3,4°; extensão de 62,5 ± 14,1°; desvio radial de 25,7 ± 2,9°; desvio cubital de 40,0 ± 2,9; pronação de 88,3 ± 2,4°; e supinação de 82,5 ± 2,5°. Registrou-se EVA mediana para dor residual = 1, défice funcional = 0, prejuízo estético = 0, e recomendação de procedimento cirúrgico = 10. A mediana do score DASH foi 0.

Conclusão O tratamento da deformidade de Madelung através da osteotomia em cúpula do rádio distal e secção do ligamento de Vickers permite obter um excelente resultado estético e funcional.

Palavras-chave

- ▶ doenças do desenvolvimento ósseo
- ▶ osteotomia
- ▶ rádio (anatomia)
- ▶ ulna
- ▶ criança

Introduction

Madelung deformity is characterized by an ulnar deviation of the articular surface of the distal radius, volar subluxation, and ulnar impaction of the carpus. It represents 1.7% of all congenital anomalies of the upper limb.¹⁻³ Its onset is attributed to the partial closure of the medial and volar portion of the distal physis of the radius, which is potentially associated with the local presence of a thickened fibrous band (corresponding to the short radiolunate ligament), the so-called Vickers ligament.^{4,5} This ligament has a restrictive, compressive effect over the growth of the distal radius, worsening the deformity.^{4,6} The progressive anatomical change results in a modification of the radiocarpal and ulnocarpal joint congruence, which evolves from an initial phase of mere esthetic perception to potentially significant pain at the wrist level, limited range of motion, grip strength loss, and a marked impact on daily life

activities.⁷⁻⁹ This deformity is more common in female adolescents and it is often bilateral. Madelung deformity is etiologically classified as idiopathic and associated with bone dysplasia, chromosomal abnormalities, or post-trauma situations.¹⁰⁻¹² Hereditary, autosomal dominant inheritance is frequently described, with genetic screening for X-linked and *SHOX* gene mutations usually employed to exclude conditions such as Turner syndrome or Léri-Weill dyschondrosteosis.^{6,11-13}

Clinical evaluation of affected patients often reveals a prominent distal ulna and volar carpal subluxation in relation to the forearm. Wrist extension and forearm supination may vary depending on the severity of the deformity, and the distal radioulnar joint may be loose or unstable. In the presence of clinical suspicion, a radiographic evaluation is usually requested and peremptory for diagnostic confirmation. Validated diagnostic criteria consider different clinical

characteristics and/or radiographic variables, including ulnar tilt, lunate subsidence lunar fossa angle, palmar carpal displacement, and ulnar variance.¹⁴⁻¹⁶ There are several options for surgical treatment according to the severity of the deformity and the age of the patient. Surgery is usually indicated in cases with persistent pain, functional limitation, and progressive bone deformity in a skeletally immature subject.^{2,17}

The present study aimed to evaluate esthetic and functional outcomes from the surgical treatment of Madelung deformity in pediatric patients using the distal radial dome osteotomy technique and Vickers ligament section.

Materials and Methods

Retrospective descriptive study analyzing clinical files from patients with Madelung deformity who were surgically treated from 2015 to 2018. The inclusion criteria were age < 18 years old, surgical treatment consisting in dome osteotomy of the distal radius and Vickers ligament section, and a minimum postoperative follow-up period of 12 months. The primary surgical indication was wrist progressive deformity with (radial/ulnocarpal) pain refractory to reduced activity, anti-inflammatory medication, orthosis, or physical therapy for a minimum period of 6 months.

The following parameters were analyzed: demographic data (gender, age at diagnosis, and laterality), age at surgery, surgical technique, bone healing time, and radiographic and clinical outcomes. The pre and postoperative radiographic evaluation consisted in ulnar tilt, lunate subsidence lunar fossa angle, and palmar carpal displacement measurements,¹⁴ which were determined using radiographic images of the wrist and the forearm (in anteroposterior and lateral views) obtained at our institution. Preoperative radiographies were those closest to the date of surgery. A postoperative clinical evaluation was carried out in a medical visit and consisted of the ranges of motion of the wrist and forearm joints, visual analog scale (VAS) for pain, functional deficit, esthetic impact, and surgical treatment recommendation, and Disabilities of the Arm, Shoulder and Hand (DASH) score.¹⁸ The present study was authorized by the Ethics Committee of the Hospital, and patients and their families signed an informed consent form.

Surgical Technique

The patient was placed in the supine position, and antibiotic prophylaxis was administered (usually with intravenous

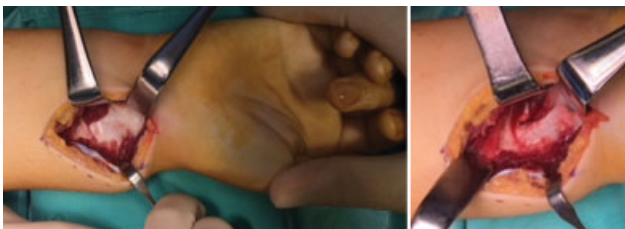

Fig. 1 Volar approach to the radius for identification, section, and excision of the Vickers ligament.

cefazolin at a 30 mg/kg dose). A tourniquet was placed at the proximal region of the arm and was inflated at 200 mm/Hg.

A volar approach to the radius was performed through a longitudinal incision (± 7 cm), exploring the space between the flexor carpi radialis and the radial artery. The pronator quadratus muscle was identified and a distal based "L" flap was elevated to expose the volar face of the radius. The Vickers ligament was identified, divided, and excised (**►Figure 1**). Under direct observation and fluoroscopic support, the metaphyseal region of the radius soon to be osteotomized was identified, avoiding damage to the distal radioulnar joint and the radial distal physis (when present). A circumferential radial subperiosteal dissection was performed and the dome (distally concave) fenestration of the distal volar and dorsal metaphysis cortex began using a 1.2/1.6 mm Kirshner (K) wire (**►Figure 2**). Two 2.0/2.4 mm K wires were placed percutaneously in parallel or diverging position through the radial styloid and oriented towards the fenestrated region of the osteotomy, without passing beyond it (**►Figure 3**). Radial dome osteotomy was performed using curved osteotomes (**►Figure 4**); next, a reduction maneuver was performed with longitudinal traction, radial deviation, pronation, and dorsal deviation of the distal fragment. While the main surgeon sustained this reduction, the assistant surgeon advanced the K wires through the osteotomy focus up to the cortical fixation at the proximal fragment.

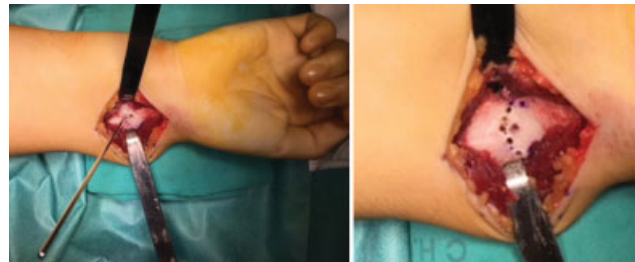

Fig. 2 Dome fenestration of the distal concavity of the volar and dorsal cortex of the metaphyseal region of the distal radius with a Kirschner wire (1.6 mm).

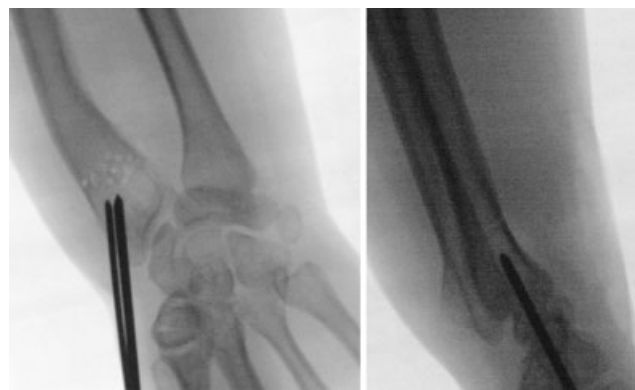

Fig. 3 Introduction of two Kirschner wires (2.0/2.4 mm) parallel or divergent to each other at the level of the radial styloid, towards the metaphyseal region of the previously fenestrated distal radius, without passing beyond it.

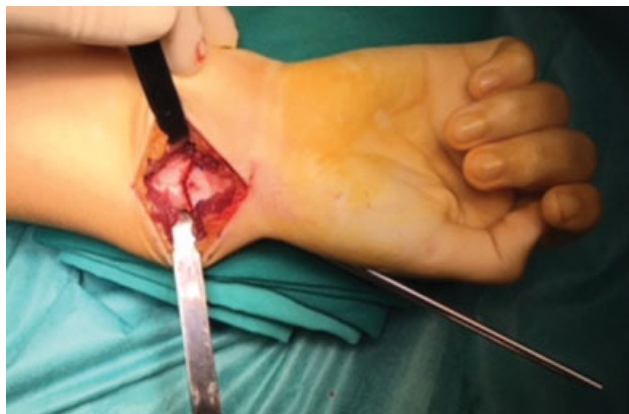

Fig. 4 Osteotomy at the distally concave dome of the metaphyseal region of the distal radius with curved osteotomes.

Reduction and fixation were confirmed fluoroscopically (►Figure 5). The K wires were folded and cut, leaving an end outside the skin to allow their removal during a medical visit. A limited volar fasciotomy was performed prophylactically, and closure began by partially reapproximating the pronator quadratus flap with absorbable sutures. Subcutaneous tissue and skin were closed with absorbable sutures. The limb was immobilized with a split short arm plaster cast to prevent postsurgical edema/compartament syndrome.

Postoperative Protocol

The immediate postoperative period focused on limb elevation, neurovascular surveillance, and active finger mobility. The average postsurgical length of stay in our institution was of 3 days, and the patients met the discharge criteria when they were comfortable with the plastered immobilization and with no pain at rest, digital edema, or neurovascular deficits. At a visit 5 to 6 weeks postsurgery, the plastered immobilization was removed, the surgical wounds were verified, and the K wires were removed without the need for an anesthetic procedure. During this visit, a radiograph of the forearm (in anteroposterior and lateral views) was performed to evaluate the reduction obtained and the quality of the bone callus/consolidation. When callus formation was deemed incipient, another short arm cast was placed and maintained until achieving unequivocal bone consolidation. The patients were subsequently evaluated clinically and radiographically in visits at 3, 6 and 12 months after surgery and then once a year.

Results

From 2015 to 2018, 4 children with Madelung deformity were surgically treated at our institution. Two of these patients had an idiopathic deformity and two subjects presented it in the context of bone dysplasia due to Léri-Weill dyschondrosteosis. All patients were females with bilateral disease. Six wrists were operated on. The primary indication for surgery was disabling pain. The median follow-up time was 37.5 months (range, 2 to 44 months). The median age at the 1st visit was 13 years old (range: 11 to 15 years old) and

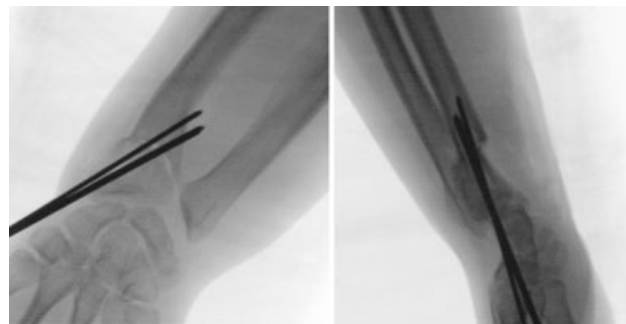


Fig. 5 Fluoroscopic control of the reduction and fixation achieved during the metaphyseal osteotomy at the dome of the distal radius with Kirschner wires (anteroposterior and lateral views).

the median age at surgery was 15.5 years old (range: 13 to 17 years old). The surgical approach consisted of a dome osteotomy of the distal radius with Vickers ligament section, fixation with Kirshner wires and plaster cast immobilization. These procedures were performed by three specialized surgeons. The mean bone healing time up to the removal of the plastered immobilization was 11.6 ± 2.4 weeks. The radiographic evaluation comparing pre and postoperative findings revealed an average correction of $8.8 \pm 7.5^\circ$ for ulnar tilt, 3.0 ± 3.9 mm for lunate subsidence $8.2 \pm 6.6^\circ$ for lunate fossa angle, and 4.7 ± 2.6 mm for palmar carpal displacement (►Table 1). Average postoperative ranges of motion of the wrist joint were $75.8 \pm 3.4^\circ$ for flexion, $62.5 \pm 14.1^\circ$ for extension, $25.7 \pm 2.9^\circ$ for radial deviation, $40.0 \pm 2.9^\circ$ for ulnar deviation, $88.3 \pm 2.4^\circ$ for pronation, and $82.5 \pm 2.5^\circ$ for supination (►Figure 6; ►Table 1). Postoperatively, the median VAS was 1 for residual pain (range: 0 to 4), 0 for functional deficit (range: 0 to 2), 0 for negative esthetic impact (range: 0 to 3), and 10 for recommending the surgical procedure to other patients (range: 8 to 10) (►Table 1). The median DASH score was 0 (range: 0 to 5), including for its specific sport module (range: 0 to 50). There was a minor postoperative complication of decreased sensitivity at the radial edge of the wrist, with complete spontaneous resolution in 8 weeks.

Discussion

The patients with Madelung deformity included in our study showed a gender and age trend similar to that described in the literature, with a predominance of female adolescents and bilateral disease.^{7,17,19} Etiologically, two patients presented a deformity associated with bone dysplasia (Léri-Weill dyschondrosteosis); both were referred to a genetic consultation due to the clinical picture of wrist deformity, short stature, mesomelic limb shortening, and family history of a similar phenotype. One of these patients also had lunate-pyramidal synostosis in agreement with the spectrum of bone dysplasia-associated skeletal anomalies.²⁰ According to the literature and consistent with our work, these patients have a more severe condition affecting the entire radius.²¹ One of the patients underwent a genetic study that revealed a heterozygous mutation at the *SHOX* gene. The other patient did not

Table 1 Results of the radiographic (pre and postoperative) and clinical (postoperative) evaluation of patients with Madelung deformity who underwent distal radial dome osteotomy and Vickers ligament section

Pre- and Postoperative Radiographic Assessment													
	Wrist 1		Wrist 2		Wrist 3		Wrist 4		Wrist 5		Wrist 6		Average Δ Correction
	Pre-	Post-	Pre-	Post-	Pre-	Post-	Pre-	Post-	Pre-	Post-	Pre-	Post-	
Ulnar tilt ($^{\circ}$)	39	17	49	48	66	64	24	16	29	24	45	30	8.8 $^{\circ}$
Lunate subsidence (mm)	15	4	10	10	9	4	8	7	4	3	0	0	3 mm
Lunate fossa angle ($^{\circ}$)	27	25	54	53	68	58	41	32	51	30	41	35	8.2 $^{\circ}$
Palmar carpal displacement (mm)	25	20	29	20	21	15	21	20	21	16	21	19	4.7 mm
Postoperative Clinical Evaluation													
	Wrist 1	Wrist 2	Wrist 3	Wrist 4	Wrist 5	Wrist 6	Average						
Joint mobility ($^{\circ}$)													
Flexion/extension	80/70	75/60	75/35	75/80	80/60	70/70	75.8 $^{\circ}$ /62.5 $^{\circ}$						
Radial/ulnar deviation	25/40	30/40	25/40	25/45	25/40	20/35	25 $^{\circ}$ /40 $^{\circ}$						
Pronation/supination	90/80	90/80	85/85	90/85	85/80	90/85	88.3 $^{\circ}$ /82.5 $^{\circ}$						
	Wrist 1	Wrist 2	Wrist 3	Wrist 4	Wrist 5	Wrist 6	Median						
DASH Score [0-100]	0	0	0	0	5	1,7	0						
VAS [0-10]													
Residual pain	0	1	1	0	4	1	1						
Negative esthetic impact	0	0	0	0	1	2	0						
Functional deficit	0	0	0	0	1	2	0						
Surgical procedure recommendation	10	10	10	10	8	10	10						

Abbreviations: Δ , variation; DASH, Disabilities of the Arm, Shoulder and Hand; VAS, visual analog scale.

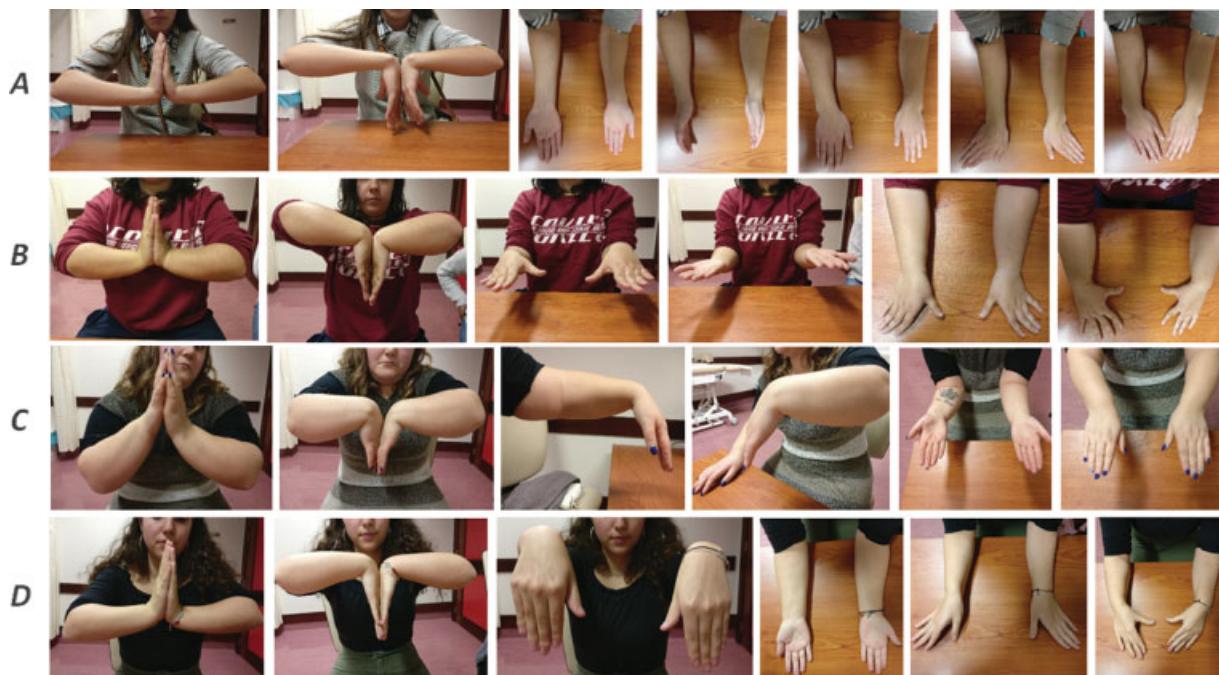

Fig. 6 Clinical photograph of postoperative wrist and forearm mobility. A - patient submitted to a bilateral surgical procedure; B - patient submitted to a bilateral surgical procedure; C - patient submitted to a surgical procedure on the left wrist; D - patient submitted to a surgical procedure on the right wrist.

undergo a genetic study, and she was instructed on the dominant character of the disease and the risk of transmitting it in a future parental project. There is no mandatory orientation for immediate genetic testing of these patients, since the added information does not imply in a relevant benefit for their lives; in addition, apart from the skeletal changes described, apparently there are no complications of associated systemic diseases.¹⁷ On the other hand, in some patients with Madelung deformity of unknown etiology and clinical characteristics that are not part of the usual clinical spectrum, a genetic study should be considered to identify any potential chromosomal change.² Our service offers a multidisciplinary approach with genetics consultation for patients with Madelung deformity and a phenotype suggesting bone dysplasia or atypical clinical characteristics. The decision to request genetic testing is up to our colleagues at the Medical Genetics service from our hospital. Surgical indication varies in the literature, and it considers different factors such as pain, age, esthetic impact, functional limitation, deformity progression, compressive nerve injury, or associated tendon rupture.^{2,17,22,23} In the present study, the primary surgical indication for all patients was disabling wrist pain. Regarding surgical procedures, adolescents with symptomatology and structured deformity such as those in the present study often are submitted to corrective osteotomies, and the distal radial dome osteotomy is one of the most attractive options due to good clinical and radiographic outcomes.²⁴⁻²⁷ Dome osteotomy allows an intraoperative, three-dimensional, partial or total restitution of the radiocarpal and radioulnar alignment and a decreased ulnar variance by distal translation of the lunate facet associated with a distal radius segment rotation.^{26,27} In addition, in cases of greater severity with ulnocarpal impaction, ulnar shortening can be performed at the same time or at a second procedure for wrist balance and to minimize ulnocarpal or distal radioulnar joint pain.⁷ The present study did not consider the need for additional ulnar procedures, maintaining the absence of ulnar pain or ulnocarpal impaction symptoms during the median postoperative follow-up period of 37.5 months. It is worth mentioning that distal ulna epiphysiodesis with radius osteotomy remains an option in skeletally immature patients > 10 years old because it minimizes the likelihood of worsening of the ulnocarpal deformity and the potential need for late ulnar shortening osteotomies.²⁷ Some surgeons also indicate a prophylactic surgery in asymptomatic, skeletally immature subjects with no marked deformity, opting for a distal radius physiolysis (Langenskiöld procedure) and Vickers ligament section as an approach to minimize or prevent deformity onset or progression.^{4,28} The radiographic evaluation revealed a pre and postoperative variation with correction of all parameters evaluated, consistent with other studies considering the same procedure and some of the same parameters.^{24,26} The literature reports studies with a wide range of surgical procedures and radiographic analysis based on different radiological criteria;^{4,15,16} therefore, comparative analysis is necessarily limited. It should be noted that, although with no marked correction of these radiographic parameters, surgical treatment was associated with excellent clinical and functional outcomes (median VAS of 0 for residual pain and functional

deficit). This data suggests the importance of factors other than bone correction of the deformity for the clinical outcome, such as radiolunate decompression through section of the Vickers ligament. At the postoperative clinical evaluation, all patients reported an important reduction in pain and improvement in joint range of motion, consistent with the description of Peymani in a systematic review about different approaches to the surgical treatment of Madelung deformity.² Patient satisfaction with the surgical procedure is also highlighted, with a median VAS of 0 for esthetic impact and 10 for recommending the treatment to other patients. The median DASH score was also maximum, including for its specific sport module, reflecting the enormous postsurgical satisfaction and functionality. A neuropraxia of the sensitive radial nerve, with spontaneous resolution after 8 weeks, was the single complication in our patients. Although K wires were introduced percutaneously, avoiding the presumed nerve territory and advanced with the motor in oscillatory mode, the literature states that the translation of distal radial fragment shifts the orientation of the K wires to a longitudinal position, which may be enough to create a local nervous compressive effect during reduction.⁴ This compressive effect usually is transitory and tends to resolve after extraction of the K wires, as in our case. The limitations of the present study included the lack of a clinical evaluation for range of motion and preoperative DASH score determination. As an improvement and future guidance on data standardization for further studies on Madelung deformity, we will adopt the protocol proposed by Peymani² in our service.

Conclusions

The surgical treatment of Madelung deformity is associated with excellent clinical and functional outcomes. The degree of radiographic correction of the deformity through a dome osteotomy of the distal radius does not seem to be the single determining factor for clinical outcomes, suggesting the importance of other factors associated with osteotomy and deformity correction, such as radiolunate decompression by section of the Vickers ligament. In our experience, the dome osteotomy of the distal radius with Vickers ligament section in symptomatic adolescents with structured Madelung deformity results in excellent esthetic outcomes, high satisfaction, and excellent functional outcomes.

Financial Support

There was no financial support from public, commercial, or non-profit sources.

Conflict of Interests

The authors have no conflict of interests to declare.

References

- 1 Flatt AE. *The Care of Congenital Hand Anomalies*. St Louis, MO: C. V. Mosby Co; 1994
- 2 Peymani A, Johnson R, Dowlatsahi AS, et al. Surgical Management of Madelung Deformity: A Systematic Review. *Hand (N Y)* 2019;14(06):725-734

- 3 Arora AS, Chung KC, Otto W. Madelung and the recognition of Madelung's deformity. *J Hand Surg Am* 2006;31(02):177-182
- 4 Vickers D, Nielsen G. Madelung deformity: surgical prophylaxis (physiolysis) during the late growth period by resection of the dyschondrosteosis lesion. *J Hand Surg Br* 1992;17(04):401-407
- 5 Kim HK. Madelung deformity with Vickers ligament. *Pediatr Radiol* 2009;39(11):1251
- 6 Knutsen EJ, Goldfarb CA. Madelung's Deformity. *Hand (N Y)* 2014;9(03):289-291
- 7 dos Reis FB, Katchburian MV, Faloppa F, Albertoni WM, Laredo Filho J Jr. Osteotomy of the radius and ulna for the Madelung deformity. *J Bone Joint Surg Br* 1998;80(05):817-824
- 8 Fagg PS. Wrist pain in the Madelung's deformity of dyschondrosteosis. *J Hand Surg Br* 1988;13(01):11-15
- 9 Houshian S, Schröder HA, Weeth R. Correction of Madelung's deformity by the Ilizarov technique. *J Bone Joint Surg Br* 2004;86(04):536-540
- 10 Henry A, Thorburn MJ. Madelung's deformity. A clinical and cytogenetic study. *J Bone Joint Surg Br* 1967;49(01):66-73
- 11 Belin V, Cusin V, Viot G, et al. SHOX mutations in dyschondrosteosis (Leri-Weill syndrome). *Nat Genet* 1998;19(01):67-69
- 12 Clement-Jones M, Schiller S, Rao E, et al. The short stature homeobox gene SHOX is involved in skeletal abnormalities in Turner syndrome. *Hum Mol Genet* 2000;9(05):695-702
- 13 Schwartz RP, Sumner TE. Madelung's deformity as a presenting sign of Turner's syndrome. *J Pediatr* 2000;136(04):563
- 14 McCarroll HR Jr, James MA, Newmeyer WL 3rd, Manske PR. Madelung's deformity: diagnostic thresholds of radiographic measurements. *J Hand Surg Am* 2010;35(05):807-812
- 15 Dannenberg M, Anton JI, Spiegel MB. Madelung's Deformity: consideration of its roentgenological diagnostic criteria. *AJR Am J Roentgenol* 1939;42:671-676
- 16 Steyers CM, Blair WF. Measuring ulnar variance: a comparison of techniques. *J Hand Surg Am* 1989;14(04):607-612
- 17 Waters PM, Bae DS. *Pediatric Hand and Upper Limb Surgery*. Wolters Kluwer 2012
- 18 Disabilities of the Arm, Shoulder and Hand (DASH) Score. Available from: <http://www.dash.iwh.on.ca/scoring>
- 19 Schmidt-Rohlfing B, Schwöbel B, Pauschert R, Niethard FU. Madelung deformity: clinical features, therapy and results. *J Pediatr Orthop B* 2001;10(04):344-348
- 20 Langer LO. Dyschondrosteosis, a heritable bone dysplasia with characteristic roentgenographic features. *Am J Roentgen Radium Ther. Nucl Med (Stuttg)* 1965;95:178-188
- 21 Zebala LP, Manske PR, Goldfarb CA. Madelung's deformity: a spectrum of presentation. *J Hand Surg Am* 2007;32(09):1393-1401
- 22 Luchetti R, Mingione A, Monteleone M, Cristiani G. Carpal tunnel syndrome in Madelung's deformity. *J Hand Surg Br* 1988;13(01):19-22
- 23 Schulstad I. Madelung's deformity with extensor tendon rupture. Case report. *Scand J Plast Reconstr Surg* 1971;5(02):153-155
- 24 Harley BJ, Brown C, Cummings K, Carter PR, Ezaki M. Volar ligament release and distal radius dome osteotomy for correction of Madelung's deformity. *J Hand Surg Am* 2006;31(09):1499-1506
- 25 Carter PR, Ezaki M. Madelung's deformity. Surgical correction through the anterior approach. *Hand Clin* 2000;16(04):713-721
- 26 Steinman S, Oishi S, Mills J, Bush P, Wheeler L, Ezaki M. Volar ligament release and distal radial dome osteotomy for the correction of Madelung deformity: long-term follow-up. *J Bone Joint Surg Am* 2013;95(13):1198-1204
- 27 Farr S, Kalish LA, Bae DS, Waters PM. Radiographic Criteria for undergoing an ulnar shortening osteotomy in Madelung deformity: A long-term experience from a single institution. *J Pediatr Orthop* 2016;36(03):310-315
- 28 Otte JE, Popp JE, Samora JB. Treatment of Madelung deformity with Vicker ligament release and radial physiolyse: a case series. *J Hand Surg Am* 2019;44(02):158.e1-158.e9