


# Predicting Cardiac Anatomy, Physiology, and Surgical Management Based on Fetal Echocardiography in Heterotaxy Syndrome

Jennifer Romanowicz, MD<sup>1</sup>  Pranava Sinha, MD<sup>2</sup> Mary T. Donofrio, MD<sup>1</sup>  
David N. Schidlow, MD, MMus<sup>3</sup>

<sup>1</sup>Division of Cardiology, Children's National Hospital, Washington, District of Columbia

<sup>2</sup>Division of Cardiac Surgery, Children's National Hospital, Washington, District of Columbia

<sup>3</sup>Department of Cardiology, Boston Children's Hospital, Boston, Massachusetts

**Address for correspondence** Jennifer Romanowicz, MD, Division of Cardiology, Children's National Hospital, 111 Michigan Avenue, Washington, DC 20010 (e-mail: jromanowicz09@gmail.com).

Am J Perinatol 2023;40:1081–1087.

## Abstract

**Objective** Heterotaxy syndrome (HS) is often associated with complex congenital heart disease (CHD). While fetal echocardiography (FE) permits accurate prenatal identification of most CHD, the high level of disease complexity in HS may pose challenges in predicting postnatal findings and outcomes. This study aimed to define the accuracy of FE in predicting postnatal anatomy, physiology, and surgical management of CHD in the setting of HS.

**Study Design** Retrospective single-center cohort study including all patients with a prenatal diagnosis of HS from 2003 to 2018. Anatomic diagnoses from FE reports were compared with postnatal echocardiogram, catheterization, and operative reports. Prenatal predictions were compared with postnatal outcomes with a focus on ductal dependence, time to first intervention (immediate, neonatal period, 1–6 months, or older than 6 months), and surgical approach (single or biventricular).

**Results** There were 102 pregnancies with fetal HS resulting in 21 terminations, 5 fetal losses, and 76 live births. Of the live births, 55 had significant CHD and available postnatal data for review. Among this group, survival to 1 year was 62% and was no different comparing single versus biventricular surgical approach. FE diagnostic accuracy varied by anatomic feature and was the lowest for diagnosis of venous anatomy. Determination of postnatal care was most accurate for predicting single versus biventricular surgical approach (91%), followed by ductal dependence (75%). Accuracy for predicting time to first intervention was the lowest at 69%. The most common reason for an incorrect prediction was difficulty in assessing the severity of pulmonary stenosis.

**Conclusion** FE permits accurate predictions regarding surgical approach. Characterizing systemic and pulmonary veins is challenging, as is predicting ductal dependence and time to first intervention. These data suggest that despite the high diagnostic accuracy of CHD in HS, a circumspect approach may be reasonable with regard to predicting some anatomic details and postnatal management decisions.

## Keywords

- ▶ heterotaxy syndrome
- ▶ fetal echocardiography
- ▶ congenital heart disease
- ▶ postnatal outcomes
- ▶ prenatal counseling

## received

December 12, 2020

## accepted after revision

June 17, 2021

## article published online

July 19, 2021

© 2021. Thieme. All rights reserved.  
Thieme Medical Publishers, Inc.,  
333 Seventh Avenue, 18th Floor,  
New York, NY 10001, USA

**DOI** <https://doi.org/10.1055/s-0041-1732457>.  
**ISSN** 0735-1631.

## Key Points

- In HS, FE was most accurate for intracardiac anatomy.
- Diagnostic accuracy of venous anatomy was less reliable.
- Predicting surgical approach (single ventricle vs. biventricular) was highly accurate.
- Predicting ductal dependence and time-to-intervention were more challenging in some instances.

Heterotaxy syndrome (HS) comprises abnormalities in multiple organ systems and is associated with irregularities of viscerotaxial situs. HS commonly causes pulmonary, gastrointestinal, and immunologic abnormalities<sup>1</sup>; however, the associated complex congenital heart disease (CHD) most often drives outcomes.<sup>2-4</sup> While HS is rare, occurring in 0.8 to 1 of 10,000 pregnancies<sup>5,6</sup> and coinciding with up to 6% of all CHD,<sup>6,7</sup> infants with HS and CHD are among the highest risk group for mortality in the CHD population.<sup>8-10</sup>

HS is frequently identified on obstetric ultrasound during the fetal period.<sup>11</sup> This permits timely referral to a pediatric cardiologist for formal fetal echocardiography (FE) in most instances. As with other forms of prenatally diagnosed CHD, FE affords the opportunity to educate parents regarding the diagnosis and for providers to plan for a potentially complex delivery and perinatal period. In many instances of CHD, predictions regarding anatomy, physiology, and surgical management are highly accurate.<sup>12</sup>

Nevertheless, the degree of complexity in HS may pose challenges,<sup>13,14</sup> even for the experienced sonographer and cardiologist. This study assesses cardiologists' ability to predict the anatomic diagnosis, physiology, urgency of intervention, and surgical approach among infants with prenatally detected CHD associated with HS.

## Materials and Methods

This was a retrospective cohort study. Fetuses diagnosed with HS between January 1, 2004, and December 31, 2018, were identified using the Children's National Heart Institute's fetal cardiology program database. HS was defined as having two or more thoracoabdominal situs abnormalities. There were no exclusion criteria. FE reports and prenatal cardiology consultation notes were reviewed. Demographic and clinical data pertaining to fetuses and neonates were recorded. Permission to conduct the study was granted by the Children's National Institutional Review Board. Informed consent was waived due to the use of deidentified data from existing medical records.

FE reports were reviewed for anatomic diagnosis. Anatomic diagnosis components were coded into nominal or ordinal categories as detailed in ▶Table 1. Prenatal cardiology consultation notes were reviewed for three predictions as follows: (1) physiology, specifically ductal-dependence; (2) surgical strategy; and (3) time to first intervention. In instances where predictions changed during pregnancy, the documentation closest to the time of birth was used for analysis.

Ductal dependence was defined as pulmonary or systemic blood flow requiring a prostaglandin (PGE1) infusion to

**Table 1** Fetal echocardiogram anatomic diagnosis categories

|                                  |
|----------------------------------|
| Cardiac position                 |
| • Levocardia                     |
| • Dextrocardia                   |
| • Mesocardia                     |
| Ventricular looping              |
| • D                              |
| • L                              |
| • X                              |
| Significant VSD                  |
| • Absent                         |
| • Present                        |
| Systemic veins                   |
| • Normal                         |
| • Interrupted inferior vena cava |
| • Bilateral superior vena cavae  |
| Pulmonary veins                  |
| • Normal                         |
| • PAPVC                          |
| • TAPVC                          |
| • Obstructed TAPVC               |
| Pulmonary outflow obstruction    |
| • Normal                         |
| • Pulmonary stenosis             |
| • Pulmonary atresia              |
| Systemic outflow obstruction     |
| • Normal                         |
| • Aortic stenosis                |
| • Aortic atresia                 |
| • Coarctation of the aorta       |
| AV valve regurgitation           |
| • Mild or less                   |
| • Moderate or more               |
| Fetal cardiac rhythm             |
| • Normal sinus rhythm            |
| • Complete heart block           |

Abbreviations: AV, atrioventricular; PAPVC, partial anomalous pulmonary venous connection; TAPVC, total anomalous pulmonary venous connection; VSD, ventricular septal defect.

Note: Each anatomic component was coded into the listed categories based on what was documented in the fetal echocardiogram (FE) report.

maintain adequacy. Infants initiated on PGE1 who were later successfully weaned were considered not dependent on ductal flow. Conversely, infants initially not on PGE1, who ultimately required it to support the circulation, were considered dependent.

Surgical strategy was defined as single-ventricle palliation (SVP) culminating in a Fontan circulation or biventricular repair (BVR) comprising a physiologic repair with separate systemic and pulmonary ventricles. Patients who died prior to Fontan completion but were documented to be on an SVP pathway were counted as SVP. Patients who initially underwent SVP procedures (e.g., Blalock–Taussig–Thomas shunt or bidirectional Glenn) but ultimately underwent BVR were counted as BVR.

Time to first intervention was grouped as follows: immediate (as soon as possible after delivery), <1 month, 1 to 6 months, and >6 months. Interventions included both surgical and catheter-based procedures. Immediate interventions included urgent balloon atrial septostomy, pacemaker placement, extracorporeal membrane oxygenation (ECMO) cannulation, and repair of obstructed total anomalous pulmonary venous connection (TAPVC).

The primary outcome of interest was the accuracy of prenatal predictions regarding physiology, surgical approach, and time to first intervention. The secondary outcome was accuracy of anatomic diagnoses. Accuracies of prenatal predictions and anatomic diagnoses are presented as a percentage of correct per total analyzed (–Table 2). Predictions and anatomic diagnoses were considered to be correct if they correctly matched the clinical course or postnatal findings, respectively. When two outcomes or anatomic diagnoses were described as equally likely (equivocal), it was counted as incorrect because FE was insufficient to make a specific prediction. When no prenatal prediction or anatomic diagnosis was documented (no comment), it was excluded from accuracy analysis. When the postnatal outcome or diagnosis was not delineated, it was also excluded from accuracy analysis. Fetuses with normal cardiac anatomy were not analyzed. When predictions were incorrect, the FEs were reviewed to identify potential reasons. A

Fisher’s exact test was used to compare mortality between SVP and BVR groups. Pearson’s correlation coefficient was used to define the association between gestational age at first FE and the total number of FEs. Chi-square test was used to assess the effect of gestational age and number of FEs on prediction accuracy. Significance was defined as  $p < 0.05$  using a two-tailed approach.

## Results

### Patients

During the 15-year period, there were 102 fetal diagnoses of HS (–Fig. 1). These resulted in 76 live births. Among the 26 without live birth, 21 were due to termination of pregnancy, and 5 were due to intrauterine fetal demise. Among live births, 13 had normal cardiac anatomy, 6 were provided palliative care, 2 were lost to follow-up, and 55 were transferred to our institution for treatment of complex CHD. These 55 infants were included for analysis.

Among the 55 infants in our analysis, 35 (64%) underwent SVP, 14 (25%) underwent BVR, and 6 (11%) died prior to surgical intervention. Overall survival to 1 year of age was 62% (34/55). There was no difference in survival to 1 year of age when comparing SVP (71% survival) to BVR (64% survival;  $p = 0.51$ , odds ratio [OR] = 1.67, 95% confidence interval [CI]: 0.47–5.91).

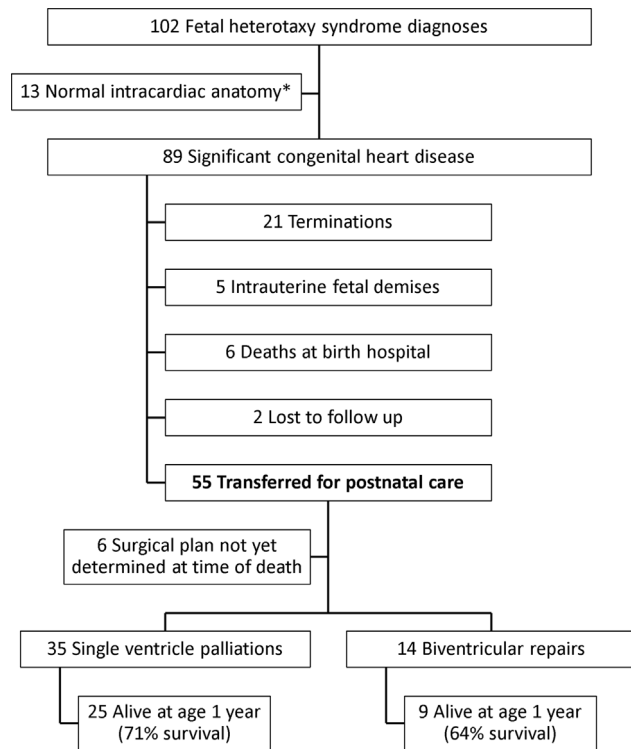
### Prediction Accuracy

In total, 39% (21/54) of patients had at least one inaccurate prediction. One patient was excluded from this analysis as all three predictions were either not specified (no comment) or there was an unclear postnatal outcome. The gestational age at the time of the first FE was negatively correlated with the total number of FEs performed ( $r[53] = -0.75$ ,  $p < 0.0001$ ; –Fig. 2A). Patients who had their first FE prior to 23 weeks of gestation had the highest prediction accuracy at 65% (–Fig. 2B) but this did not reach significance. Among those who had just one FE, only 33% (two of six) had all three predictions correct (–Fig. 2C). We observed increased accuracy with the addition of a second and third, but not a fourth

| Correct   | Incorrect  | Excluded  |
|---|--|---|
| <b>Prenatal predictions</b>   |  |   |
| Prenatal prediction matches postnatal management strategy (correct) | Prenatal prediction does not match postnatal management strategy (incorrect)                         | No prenatal prediction documented (no comment)                              |
|   | Prenatal prediction describes multiple postnatal management strategies as equally likely (equivocal) | Postnatal outcome is not clear (unclear outcome)                            |
| <b>FE anatomic diagnoses</b>  |  |   |
| FE diagnosis matches postnatal diagnosis (correct)                  | FE diagnosis does not match postnatal diagnosis (incorrect)  | FE diagnosis was not documented (no comment)                                |
|   | FE report describes multiple diagnoses as equally likely (equivocal)                                 | Postnatal diagnosis was not clearly delineated (not delineated postnatally) |

Abbreviation: FE, fetal echocardiogram.

Note: Accuracies are reported as total correct over total analyzed.



**Fig. 1** Patient outcomes. \*May include small left-to-right shunt lesions not requiring intervention (e.g., atrial septal defect, ventricular septal defect, and patent ductus arteriosus).

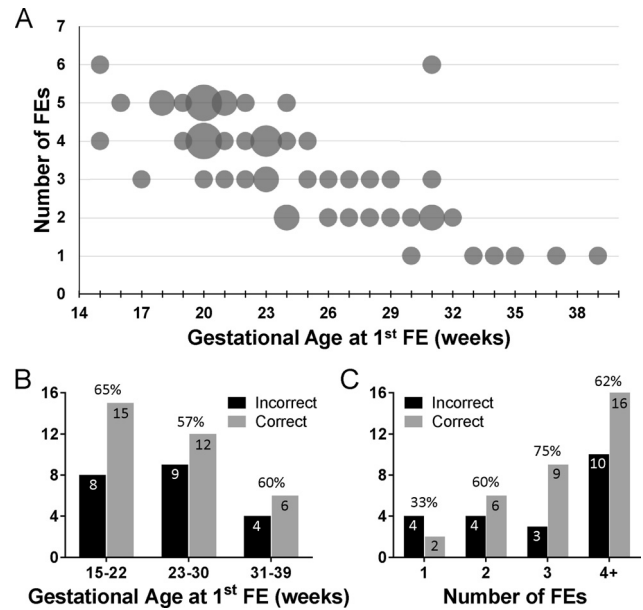
FE; however, our study was underpowered to detect an association between the number of FEs and prediction accuracy.

**Physiology (Ductal Dependence)**

Prediction accuracy for postnatal ductal dependence was 75% (40/53; ▶ **Table 3**). Incorrect predictions (▶ **Fig. 3A**) were due to difficulty determining severity of pulmonary stenosis (7 of 13), unrecognized aortic arch obstruction (5 of 13), and failure to identify major aortopulmonary collateral arteries (1 of 13). In one instance, elective cannulation to venoarterial ECMO in the delivery room for obstructed TAPVC made determination of postnatal PGE1 need unclear, and this patient was excluded from analysis. Additional details can be found in the ▶ **Supplementary Appendix** (available in the online version).

**Surgical Approach**

Prediction accuracy for surgical approach was 91% (42/46; ▶ **Table 3**). Among the four predictions that were



**Fig. 2** Gestational age at first fetal echocardiogram (FE) and total number of FEs. (A) Bubble plot demonstrating each patient,  $n = 55$ . Bubble area corresponds with patient number, ranging from 1 to 4. (B, C) Incidence of any incorrect prediction, by gestational age at first FE (B) and total number of FEs (C). Accuracy for each group is listed above the histogram bars for that group.  $n = 54$ , as one patient was excluded due to no comment and unclear outcome predictions.

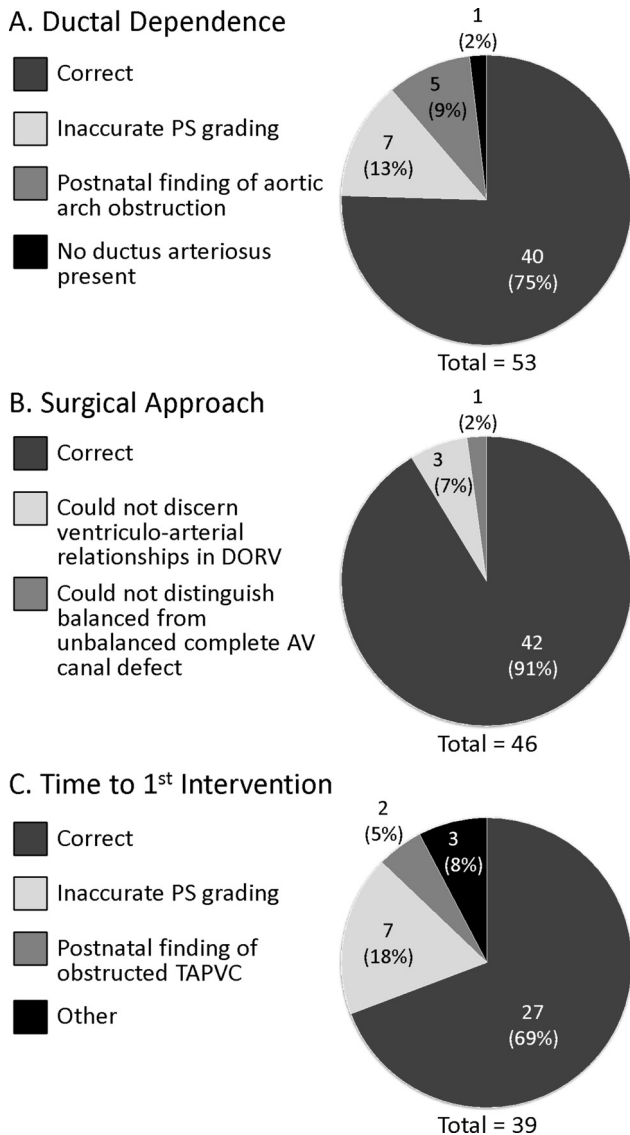
not correct (▶ **Fig. 3B**), three had a complex double-outlet right ventricle and it was difficult to reliably determine the ventriculoarterial relationship and whether BVR would be feasible. One incorrect prediction was due to difficulty distinguishing a balanced complete atrioventricular canal from a right-dominant defect. Six patients died prior to determination of surgical approach, and these were excluded from analysis.

**Time to Intervention**

Prediction accuracy for time to first intervention was 69% (27/39; ▶ **Table 3**). Among the 12 predictions that were not correct (▶ **Fig. 3C**), 4 interventions occurred later than predicted, 5 occurred earlier than predicted, and 3 equivocal cases acknowledged difficulty predicting the severity of pulmonary stenosis. Among the four interventions that occurred later than predicted, all were because adequate pulmonary blood flow was present (three antegrade and one via major aortopulmonary collateral arteries) when a need for an alternative source was predicted. Among the five interventions occurring earlier than predicted, two were

| Prediction                 | Correct | Incorrect | Equivocal | No comment | Unclear outcome | Accuracy    |
|----------------------------|---------|-----------|-----------|------------|-----------------|-------------|
| Ductal dependence          | 40      | 11        | 2         | 1          | 1               | 75% (40/53) |
| Surgical approach          | 42      | 1         | 3         | 3          | 6               | 91% (42/46) |
| Time to first intervention | 27      | 9         | 3         | 13         | 3               | 69% (27/39) |

Note: Accuracy is presented as a percentage of correct per total included in the analysis. "Equivocal" was counted as incorrect. "No comment" and "unclear outcome" were excluded from analysis. Excluded groups were subtracted from  $n = 55$  to make the denominator in the accuracy calculation.



**Fig. 3** Possible contributing factors to incorrect predictions. AV, atrioventricular; DORV, double-outlet right ventricle; PS, pulmonary stenosis; TAPVC, total anomalous pulmonary venous connection.

due to unrecognized obstructed TAPVC, one was due to urgent need for pacemaker, one was due to progressive atrioventricular valve insufficiency, and one was due to inadequate pulmonary blood flow. No prediction was made for 13 fetuses. Three patients died before a first intervention was planned, and these were excluded from analysis.

**Anatomic Diagnostic Accuracy**

Accuracy of FE anatomic diagnoses is given in **Table 4**. Diagnostic accuracy for cardiac position (93%, 51/55), ventricular looping (96%, 53/55), presence of significant ventricular septal defect (VSD; 91%, 50/55), presence of pulmonary (91%, 50/55) or systemic outflow obstruction (82%, 45/55), and severity of atrioventricular valve regurgitation (91%, 49/54) was fairly accurate.

In contrast, correct identification of the systemic and pulmonary venous anatomy was less frequently achieved at 54% (28/52) and 75% (36/48), respectively. Incorrect systemic venous diagnoses were most often attributable to missed prenatal detection of bilateral superior vena cavae (11 of 23) or interrupted inferior vena cava (5 of 23). Missed prenatal detection of TAPVC was the most common cause of pulmonary venous misdiagnoses (5 of 7). In total, there were four cases of obstructed TAPVC that were not detected prenatally as follows: (a) one thought to be unobstructed TAPVC, (b) two thought to be normal pulmonary veins, and (c) one with no comment prenatally. Notably, all four cases of undetected obstructed TAPVC were in patients who underwent SVP. Overall pulmonary venous anatomic accuracy trended higher in BVR patients (85%) compared with SVP patients (70%); however, this difference did not achieve statistical significance. Pulmonary venous anatomy was the anatomic component most frequently associated with an uncertain prenatal diagnosis (equivocal) or no prenatal diagnosis (no comment).

**Discussion**

In this retrospective analysis of fetal patients diagnosed with HS, we demonstrated that FE allows for reasonably accurate

| Echo component                | Correct | Incorrect | Equivocal | No comment | Not delineated postnatally | Accuracy    |
|-------------------------------|---------|-----------|-----------|------------|----------------------------|-------------|
| Cardiac position              | 51      | 4         | 0         | 0          | 0                          | 51/55 (93%) |
| Ventricular looping           | 53      | 2         | 0         | 0          | 0                          | 53/55 (96%) |
| Significant VSD               | 50      | 5         | 0         | 0          | 0                          | 50/55 (91%) |
| Systemic veins                | 28      | 23        | 1         | 3          | 0                          | 28/52 (54%) |
| Pulmonary veins               | 36      | 7         | 5         | 5          | 2                          | 36/48 (75%) |
| Pulmonary outflow obstruction | 50      | 5         | 0         | 0          | 0                          | 50/55 (91%) |
| Systemic outflow obstruction  | 45      | 10        | 0         | 0          | 0                          | 45/55 (82%) |
| AV valve regurgitation        | 49      | 5         | 0         | 1          | 0                          | 49/54 (91%) |

Abbreviations: AV, atrioventricular; VSD, ventricular septal defect. Note: Accuracy is presented as a percentage of correct per total included in the analysis. “Equivocal” was counted as incorrect. “No comment” and “not delineated postnatally” were excluded from analysis. Excluded groups were subtracted from  $n = 55$  to make the denominator in the accuracy calculation.

prediction of many aspects of postnatal cardiac outcomes. Nevertheless, the degree of anatomic and physiologic complexity is such that a completely accurate representation of postnatal course is challenging. While predicting a single versus biventricular surgical approach was most accurate, accuracy regarding the postnatal physiology (ductal dependence) and time to first intervention was more difficult. With regard to anatomic diagnosis, as demonstrated by previous authors,<sup>13</sup> complete delineation of the venous anatomy is challenging, whereas assessment of the intracardiac anatomy is usually highly accurate.

We observed that assessing the adequacy of pulmonary blood flow—and by extension PGE1 need and time to first intervention—proved challenging in some cases. Reversed ductus arteriosus flow is considered a reliable indicator of postnatal ductal-dependent pulmonary blood flow.<sup>15</sup> Nevertheless, in this series, ductus arteriosus flow was occasionally difficult to discern or suggested physiology different from that encountered postnatally. In some instances, a tortuous ductus made discerning the direction of flow difficult. In other instances, the ductus was simply difficult to visualize on late-gestation FE. In one instance, normal fetal right-to-left ductus arteriosus flow suggested adequate postnatal pulmonary blood flow; however, multilevel pulmonary obstruction caused progressive cyanosis, requiring initiation of a PGE1 infusion until intervention was possible. In contrast, two patients with pulmonary outflow obstruction had systemic-to-pulmonary ductus arteriosus flow in utero but ultimately did not require PGE1. Again, this is unusual, as the direction of ductal flow is typically a reliable indicator of postnatal ductal dependence. Comparison of single and biventricular circulations with regard to this assessment would be valuable, but our study was underpowered for such an analysis.

Another diagnostic challenge was identifying postnatal aortic arch obstruction. Fetal diagnosis of aortic arch obstruction is intrinsically challenging<sup>15,16</sup> because coarctation of the aorta typically occurs definitively at the time of ductal closure postnatally. The additional complexity associated with HS adds to the challenge in making this diagnosis, as the indicator of right-to-left size discrepancy may not be readily discernible or confounded by other anatomic or functional disturbances.<sup>17</sup>

Also of note, there were challenges in identifying pulmonary venous anatomy. Seven infants in this group were born with obstructed TAPVC. In three instances, obstructed TAPVC was not identified. In one instance, TAPVC was identified but obstruction was not. Perhaps this was related to increased postnatal flow across the vertical vein. Of note, all four of these cases were in patients with single-ventricle heart disease. Although our data did not reveal a significant diagnostic accuracy advantage for pulmonary venous anatomy in patients with a biventricular circulation, it is possible that our subgroup analysis was underpowered to detect this difference. In several instances, a description of pulmonary venous anatomy was equivocal or not included, pointing to the potential difficulty of this part of the FE examination. This may have clinical implications, as obstructed TAPVC

frequently requires urgent intervention in the neonatal period.

It should be noted that in several instances, no comment was made about certain aspects of the anatomy and physiology. This may be understandable given the degree of complexity germane to HS. Nevertheless, as with all forms of CHD, a standardized approach to counseling and documentation is beneficial. For fetuses with HS, a standardized approach would include documentation of the anatomy and physiology, the anticipated need for PGE1, and the anticipated surgical approach strategy, including both type and timing of intervention. Of course, given the complexity of HS, there certainly may be some ambiguity in some of these predictions. Specifically addressing the limitations of each prediction may be helpful for providers to understand the range of potential postnatal care strategies and will set expectations for parents. For example, one might describe that SVP versus BVR will depend on the relationship between the VSD and the semilunar valves in a patient with complex double-outlet right ventricle. Similarly, one might note ambiguity regarding the degree of pulmonary obstruction and that ductal-dependence and timing of first intervention will depend on adequacy of postnatal antegrade pulmonary blood flow.

## Limitations

Limitations of our study include the inherent limitations of a retrospective review and small sample size. The study was underpowered to identify individual associations with inaccurate predictions. In addition, when cataloguing the predictions, we were limited to the information documented by the provider in the fetal clinic visit note. It is possible that additional aspects of anatomy, physiology, and likely management strategies were discussed as part of prenatal counseling but ultimately not documented in the medical record. Finally, surgical decisions—particularly type and timing of intervention—are primarily decided by the cardiac physiology and clinical needs but may be significantly influenced by noncardiac issues that confound the endpoints, such as provider preference and extracardiac disease. Further, the surgical management of these complex patients is likely influenced by the institution's philosophy, and may vary from one center to another. In this single-center study with consistent stakeholders, it should be reasonable to assume that surgical decision-making followed the same standards throughout the study period.

## Conclusion

The complexity of CHD in HS makes assessment of anatomy and physiology by FE challenging. Although predictions regarding surgical approach are fairly accurate, predictions regarding ductal dependence and time to first intervention remain more difficult. These data suggest that despite the high FE diagnostic accuracy of CHD in HS, a circumspect approach may be reasonable with regard to predicting some anatomic details and postnatal management decisions.

**Conflict of Interest**

None declared.

**References**

- 1 Gottschalk I, Stressig R, Ritgen J, et al. Extracardiac anomalies in prenatally diagnosed heterotaxy syndrome. *Ultrasound Obstet Gynecol* 2016;47(04):443–449
- 2 Buca DIP, Khalil A, Rizzo G, et al. Outcome of prenatally diagnosed fetal heterotaxy: systematic review and meta-analysis. *Ultrasound Obstet Gynecol* 2018;51(03):323–330
- 3 Taketazu M, Loughheed J, Yoo SJ, Lim JSL, Hornberger LK. Spectrum of cardiovascular disease, accuracy of diagnosis, and outcome in fetal heterotaxy syndrome. *Am J Cardiol* 2006;97(05):720–724
- 4 Escobar-Diaz MC, Friedman K, Salem Y, et al. Perinatal and infant outcomes of prenatal diagnosis of heterotaxy syndrome (asplenia and polysplenia). *Am J Cardiol* 2014;114(04):612–617
- 5 Lin AE, Krikov S, Riehle-Colarusso T, et al; National Birth Defects Prevention Study. Laterality defects in the national birth defects prevention study (1998–2007): birth prevalence and descriptive epidemiology. *Am J Med Genet A* 2014;164A(10):2581–2591
- 6 Fyler D. Report of the New England Regional Infant Cardiac Program. *Pediatrics* 1980;65(2, pt 2):375–461
- 7 Lim JSL, McCrindle BW, Smallhorn JF, et al. Clinical features, management, and outcome of children with fetal and postnatal diagnoses of isomerism syndromes. *Circulation* 2005;112(16):2454–2461
- 8 Alsoufi B, McCracken C, Schlosser B, et al. Outcomes of multistage palliation of infants with functional single ventricle and heterotaxy syndrome. *J Thorac Cardiovasc Surg* 2016;151(05):1369–77.e2
- 9 Duong SQ, Godown J, Soslow JH, et al. Increased mortality, morbidities, and costs after heart transplantation in heterotaxy syndrome and other complex situs arrangements. *J Thorac Cardiovasc Surg* 2019;157(02):730–740.e11
- 10 Jacobs JP, Pasquali SK, Morales DLS, et al. Heterotaxy: lessons learned about patterns of practice and outcomes from the congenital heart surgery database of the society of thoracic surgeons. *World J Pediatr Congenit Heart Surg* 2011;2(02):278–286
- 11 Friedberg MK, Silverman NH, Moon-Grady AJ, et al. Prenatal detection of congenital heart disease. *J Pediatr* 2009;155(01):26–31, 31.e1
- 12 Donofrio MT, Levy RJ, Schuette JJ, et al. Specialized delivery room planning for fetuses with critical congenital heart disease. *Am J Cardiol* 2013;111(05):737–747
- 13 Cohen MS, Schultz AH, Tian ZY, et al. Heterotaxy syndrome with functional single ventricle: does prenatal diagnosis improve survival? *Ann Thorac Surg* 2006;82(05):1629–1636
- 14 Berg C, Geipel A, Smrcek J, et al. Prenatal diagnosis of cardiosplenic syndromes: a 10-year experience. *Ultrasound Obstet Gynecol* 2003;22(05):451–459
- 15 Donofrio MT, Moon-Grady AJ, Hornberger LK, et al; American Heart Association Adults With Congenital Heart Disease Joint Committee of the Council on Cardiovascular Disease in the Young and Council on Clinical Cardiology, Council on Cardiovascular Surgery and Anesthesia, and Council on Cardiovascular and Stroke Nursing. Diagnosis and treatment of fetal cardiac disease: a scientific statement from the American Heart Association. *Circulation* 2014;129(21):2183–2242
- 16 Kailin JA, Santos AB, Yilmaz Furtun B, Sexson Tejtelt SK, Lantin-Hermoso R. Isolated coarctation of the aorta in the fetus: A diagnostic challenge. *Echocardiography* 2017;34(12):1768–1775
- 17 Familiari A, Morlando M, Khalil A, et al. Risk factors for coarctation of the aorta on prenatal ultrasound: a systematic review and meta-analysis. *Circulation* 2017;135(08):772–785