

Case Report (III)

RHABDOMYOSARCOMA ARISING FROM UNUSUAL SITES

S. SIRISHA RANI, L. APPAJI, ARUNA KUMARI, GEETASHREE MUKERJEE, KUMARA SWAMY, M PADMA AND H.S. MAMATA

INTRODUCTION

Rhabdomyosarcoma(RMS) is the most common soft tissue sarcoma of childhood, which accounts for two-thirds of all sarcomas in children aged between 1-14 years of age.¹ Among the extracranial solid tumours of childhood RMS is the third most common neoplasm after neuroblastoma and Wilms' tumour. Incidence of RMS peaks between 1-4 years and falls afterwards until 14 years of age.^{1,2} RMS is highly malignant tumour and is thought to arise from the primitive mesenchymal cells committed to develop in to skeletal muscle lineage.² Its association with Li-Fraumeni syndrome (LFS), Beckwith-Weideman syndrome, neurofibromatosis, central nervous system(CNS) abnormalities and genitourinary abnormalities suggests that genetic factors play major role in its etiology¹. The two major histological types of RMS described are embryonal and alveolar type which accounts for 75% of rhabdomyosarcomas and the rest of 25% is formed by pleomorphic, undifferentiated and others. RMS can arise anywhere in the body including sites where striated muscle would not be normally found.² Here we are reporting two cases of RMS, which arose from unusual sites like brain and lung.

CASE -1: A 13 year old girl presented with headache of one month duration with history of loss of consciousness once and one episode of generalized tonic seizures. Her general physical examination was normal. CNS examination revealed bilateral papilloedema and left sided

facial nerve palsy of upper motor neuron (UMN) type. No obvious motor or sensory deficit was noticed except positive left upper limb pronator drift. Other systems were unremarkable. FLAIR image of MRI brain showed iso to hypointense irregular lesion in right temporal area measuring 6x5x4cm, with mass effect, and associated with minimal midline shift (fig. 1). She underwent gross total excision of lesion on September 2002. Postoperative CT scan revealed areas of hypodensities and pneumocephalus seen in same area with minimal subdural collection, suggestive of residual lesion. Subsequently she was referred to us for further management. On examination of CNS system, mild residual left sided UMN facial paralysis was noticed. General physical examination and systemic was within normal limits. Hemogram, serum biochemistry, chest X-ray, Ultra sound abdomen, bone marrow aspiration, cerebrospinal fluid cytology (CSF) and ECG did not reveal any abnormality. Histopathological examination of the excised specimen was suggestive of spindle cell sarcoma.

Immunohistochemistry showed positive desmin and vimentin, negative for cytokeratin, EMA and synaptophysin - suggestive of Rhabdomyosarcoma. Final diagnosis of Rhabdomyosarcoma of right temporal area of the brain -stage III was made and patient was started on chemotherapy as per IRS III protocol with concurrent cranial radiotherapy. Now the patient is on maintenance chemotherapy, consisting of vincristine, cyclophosphamide, actinomycin-D and adriamycin. Repeat CT scan head done after radiotherapy and induction chemotherapy was normal (fig. 2).

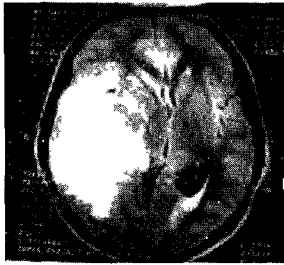

Fig 1 Flair image of MRI brain mass lesion in right temporal lobe with mid line shift

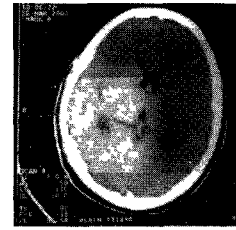


Fig 2 CT Head done post surgery, radiotherapy and while on chemotherapy is normal




Fig 3 Spindle cells in a loose stroma showing rhabdomyoblasts in the center (H&E 40x)




Fig 4 Higher magnification showing rhabdomyoblasts (H+E, 100x)

CASE 2:

Three year old boy presented with on and off episodes of cough and breathlessness since 1 year. He was diagnosed outside to have recurrent episodes of right pneumothorax and was treated with intercostal drainage. Chest x-ray showed pneumothorax with mass lesion in lower paravertebral region of right lung for which he under went thoracotomy and excision of mass lesion. He presented to us in june,1996. On examination, he was found to have moderate degree of pallor. Other general examination findings and systemic examination were unremarkable. His hemogram was normal except for hemoglobin of 7.5 gm%. Serum biochemistry, ultrasound abdomen, bone marrow aspiration, did not reveal any abnormality. Histopathology review of excised specimen was suggestive of Embryonal Rhabdomyosarcoma. Final diagnosis of Rhabdomyosarcoma of right lung, embryonal type, stage II was made and the patient received chemotherapy as per IRS III protocol. Post chemotherapy re-evaluation including CT scan thorax were normal. Child is

off therapy for the past 5 years. On follow up his clinical examination and re-evaluation work up did not reveal any abnormality.

DISCUSSION:

The common sites for occurrence of the tumour are head and neck, trunk, extremities and genitourinary areas. Occasionally rare sites like liver, lung, brain, ovary, breast may harbor the primary RMS.² The clinical features of RMS depends on the site of the tumour and extent of tumour at presentation. Tumour arising from extremities is generally noticed after trauma and the most common presenting feature is mass with or without pain.³ When it arises from nasopharynx, orbit, parameningeal, middle ear, genitourinary sites, the symptoms are related to displacement or obstruction of normal structures. In case 1 the symptoms are explained in the same way.

Where as in case 2 the symptoms are attributed to the congenital cyst of the lung with secondary pneumonia associated with the lung mass leading to recurrent episodes of

pneumothorax. Primary RMS of lung is a rare entity. The youngest patient reported in literature to the best of our knowledge is a 13-month-old child who presented with left lung upper lobe RMS originating within the congenital cystic adenomatoid malformation.⁴ A case of alveolar RMS of left lung presenting like lung mass reported in 2002 by Saha et al has been described as long term survivor who was treated with surgery, radiotherapy and chemotherapy.⁵ The index case 2 in which the primary site is right lung can also be considered as long term survivor as the child is free of disease for the past 6 years.

The primary intracranial RMS involving brain parenchyma or meninges is a rare entity, the meningeal being rarer than the parenchymal one. Only 4 cases of meningeal rhabdomyosarcomas are reported in literature.⁶ Our index case 1 child underwent craniotomy and gross total excision of tumour, received cranial radiotherapy and is on chemotherapy for the past 9 months who is clinically and radiologically in remission.

The confirmation of diagnosis of RMS is by presence of characteristic cross striations on light microscopy, actin-myosin bundles or Z band material on electron microscopy and positive muscle specific protein staining like actin and myosin, desmin, myoglobin, Z band protein and Myo-d on immunohistochemical staining.² This is substantiated by the most consistent translocations of t (2;13) in 55% of alveolar RMS & t (1;13) in another 22% of alveolar RMS.¹ The major histological subtype of embryonal RMS is known to have loss of heterozygosity at the 11p15 locus.^{1,2}

These tumours are highly radiosensitive. The combined approach of surgery, radiotherapy and chemotherapy improved the survival from 25% in 1970's to 80-90% (in case of resectable tumours) in 1990's.¹ The treatment is based on primary tumour location and stage of the disease, some patients are given preoperative chemotherapy in an attempt to reduce the extent of the surgery and to preserve vital organs particularly in genitourinary organs. However the outcome depends on the (a) site of the tumour: favorable sites include - orbit, Para testicular and vagina and the high risk sites are parameningeal and extremities (b) histology - alveolar has poorer outcome than the embryonal (c) stage- totally resectable tumours will have better outcome, while the residual disease post biopsy, nodal or metastatic disease have poorer outcome¹. The overall 5 years survival is 72% in these cases.

REFERENCES:

1. H P Mc Dowell. Update on childhood Rhabdomyosarcoma. *Arch Dis Child* 2003;88:354-357.
2. Wexler LH, Crist WM, Helman LJ. Rhabdomyosarcoma and the undifferentiated sarcomas. In: *Principles and practice of Pediatric Oncology*, 4th edition, Eds Philip A Pizzo and David G Poplack; Philadelphia, Lippincott Williams and Wilkins 2002;p939-963.
3. Crist WM, Arndt CAS. Soft tissue sarcomas. In: *Nelson Text book of Pediatrics*, 16th edition, Eds Behrman RE, Kleigman RM; Philadelphia, WB Saunders company 2000;22:p1556-1558.
4. Ozcan CA, Zetel U. Primary pulmonary Rhabdomyosarcoma within cystic adenomatoid malformation. A case report and review of literature. *J Pediatr Surg* 2001;36:1062-5.
5. Saha SP, Rogers AG, Earle GF et al. Primary pulmonary Rhabdomyosarcoma a longterm survivor. *J Ky Med Assoc* 2002;100:496-8.
6. Xu F, Delas Casas LE, Dobbs LJ. Primary meningeal Rhabdomyosarcoma in a child with Hypo melanosis of Ito. *Arch Pathol Lab Med* 2000;124:762-5.

