

Case Report-V

Delayed Isolated Abdominal Wall Recurrence in a Case of Ovarian Dysgerminoma

AMITA MAHESHWARI, SUDEEP GUPTA, REKHA WUNTKAL, SUMEET GUJRAL, SAMIR SHAH, HEMANT TONGAONKAR.

ABSTRACT

A-22 year old lady with dysgerminoma of ovary, stage IA was kept on surveillance. She relapsed 36 months later in anterior abdominal wall, Patient achieved complete response following cisplatin based chemotherapy. Presently, she is alive and disease-free.

INTRODUCTION

Ovarian germ cell tumours, particularly dysgerminomas have very favourable prognosis with modern treatment modalities. Many series consistently show long-term survival rates in excess of 90%, even for advanced stage patients.^{1,2} The recommended treatment policy for surgically stage 1A dysgerminomas is fertility preserving surgery followed by close observation. The majority of recurrences occur within 2 years of diagnosis.³ The common sites of recurrence in dysgerminomas are retroperitoneal lymph nodes, pelvis, contralateral ovary and visceral sites like lungs and liver.^{4,5} We report a case of late relapse at an unusual site in a case of stage-1A dysgerminoma.

CASE REPORT

A-22-year old, unmarried female presented to our hospital in Jan 2001 with complaint of lump in lower abdomen for 20 days. She attained menarche at the age of 13 years. Examination revealed a 20 cm, mobile, abdomino-pelvic mass. Ultrasound showed a large right sided abdomino-pelvic mass. The β -HCG level was 111 IU/L.

Department of Medical Oncology and Gynaecologic Oncology
Tata Memorial Hospital Dr. E. Borges Parel, Mumbai-400 012
Correspondence to : **SUDEEP GUPTA**
E-mail : sudeepgupta04@yahoo.com

Serum CA-125, AFP and CEA were normal. Standard staging laparotomy with right salpingo-oophorectomy was done. The histopathology report of right ovarian mass showed dysgerminoma, stage IA. As per our hospital policy, the patient was kept under close observation. β -HCG level came down to normal after surgery.

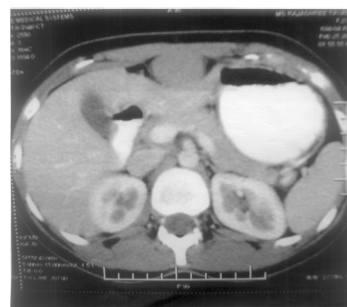

Figure 1: CT scan of recurrent anterior abdominal wall dysgerminoma posterior to the rectus sheath.

The patient was asymptomatic for 36 months following primary treatment. In Feb 2004, she presented with pain in upper abdomen. Examination revealed 4 x 4 cm firm fixed mass in the epigastric region. The CT scan

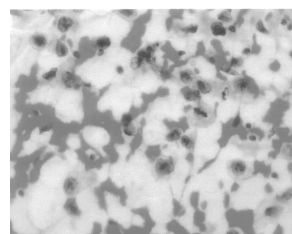


Figure 2: Fine needle aspiration cytology from the abdominal wall recurrence.

of abdomen and pelvis revealed 4 x 2.8 cm well defined midline mass, in epigastric region just

posterior to the rectus sheath (Figure 1). There were no other sites of recurrence and the tumour markers and chest radiograph were normal. Ultrasound guided fine needle aspiration cytology (FNAC) revealed recurrence of dysgerminoma (Figure 2). The patient was treated with 4 cycles of cisplatin (20 mg/m², days 1-5) plus etoposide (100 mg/m², days 1-5) given once every 3 weeks with standard hydration and anti-emetics. The patient tolerated this regimen well, with temporary cessation of menstrual function during chemotherapy. The repeat CT scan after the 4th cycle of chemotherapy showed complete resolution of the epigastric mass. The patient is currently in remission and kept on regular follow-up.

DISCUSSION :

Peritoneal site recurrences including omentum are sometimes seen in patients of dysgerminoma; however this is usually seen in the context of relapse at other sites.^{4,5} Isolated single site peritoneal relapse is very rare.

Our patient relapsed 36 months after primary surgery in the upper anterior abdominal wall just posterior to the rectus sheath. After confirmation of the diagnosis with FNAC, she was successfully treated with 4

cycles of cisplatin based chemotherapy. With more patients of dysgerminoma being treated with conservative surgery and surveillance, it is possible that late recurrences at unusual sites may be seen in the future. It is prudent to continue to follow-up these patients for prolonged periods up to several years after the completion of primary treatment, since the vast majority of relapsed patients can be successfully salvaged with chemotherapy.

REFERENCES :

1. Williams SD, Blessing JA, Hatch KD, Homesley HD. Chemotherapy of advanced dysgerminoma: Trials of the Gynecologic Oncology Group. *J Clin Oncol* 1991;9:1950-1955
2. Brewer M, Gershenson DM, Herzog CE, Mitchell MF, Silva EG, Whrton JT. Outcome and reproductive function after chemotherapy for ovarian dysgerminoma. *J Clin Oncol* 1999;17:2670-2675.
3. Dark GG, Bower M, Newlands ES, Paradinas F, Rustin GJS. Surveillance policy for stage 1 ovarian germ cell tumours. *J Clin Oncol* 1997;15:620-624.
4. Zanetta G, Bonazzi C, Cantu MG, et al. Survival and reproductive function after treatment of malignant germ cell ovarian tumours. *J Clin Oncol* 2001;19:1015-1020
5. Segelov E, Campbell J, Ng M, et al. Cisplatin-based chemotherapy for ovarian germ cell malignancies. The Australian experience. *J Clin Oncol* 1994;12:378-384.

