

Case Report-III

Squamous Cell Carcinoma of Face With Xeroderma Pigmentosa – A Case Report

S. PATHY, K.K. NAIK, SUMAN BHASKER, M.C. SHARMA, P.K. JULKA, AND G.K. RATH

ABSTRACT

Xeroderma pigmentosa with squamous cell carcinoma of skin has been infrequently reported. A nine year old boy having xeroderma pigmentosa presented with extensive ulceration in the face. On investigations, the ulceration was found to be squamous cell carcinoma. The details of this case are presented and management with a short course of palliative radiotherapy is discussed.

INTRODUCTION

Xeroderma pigmentosum (XP) is a heterogenous group of genetic diseases which result from faulty DNA repair mechanism. It is a rare autosomal recessive disease characterized by photosensitivity, pigmentary changes, premature skin aging, neoplasia and abnormal DNA repair. Xeroderma pigmentosa was recognised in late 1800 by Maritz Kaposi.¹ XP has been reported world wide in all races with an over all prevalence of 1–4 per million population. Basal cell carcinoma is found to be associated with XP in majority of the reported cases in Indian literature.²⁻³ Very few adult patients revealed squamous cell lesions.

Here we report a case of squamous cell carcinoma of the face in a young boy co-existing with xeroderma pigmentosa. A significant family history was also elicited.

CASE

A 9 year old boy presented to our tumour clinic with history of skin pigmentation over face,

neck and trunk, freckles over face and photophobia since 6 months of age. Ulceration on the left side of face was present for 8 months. The pigmentation was progressive and more so after exposure to sunlight and over exposed areas.

A detailed history revealed similar symptoms in his sibling aged 12 years with non-progressive lesion. The child was immunized with no significant perinatal history. Development of milestones was normal.

Local examination revealed extensive ulcero-proliferative lesion on left side of face involving left eye, temporal region, 7x7 cm extending from supraorbital ridge above, to angle of mouth below with purulent discharge, areas of haemorrhage and everted margins, and another lesion measuring 4 x 3cm on the right side of the face with crusting and haemorrhage (Figure 1a and 1b). Small papular lesion was seen on the rest of the face. Multiple pigmented lesions and skin freckles were noticed all over the body. There was no significant cervical lymphadenopathy. Systemic examination including neurological functions was essentially normal. Haemogram and serum biochemistry was within normal limits. Chest radiography and ultrasonography of abdomen were normal.

Biopsy of the skin lesion revealed squamous cell carcinoma with keratin pearls (Fig 2). The patient was offered conservative treatment with antibiotics and wound care followed by palliative radiotherapy to the primary lesion as surgical excision was not feasible. A dose of 30Gy in 15 fractions over 3 weeks was planned by direct field on Co60 unit. Subsequently there was adequate symptom

Department of Radiation Oncology & Pathology
All India Institute of Medical Sciences, New Delhi-110 029.
Correspondence to : **SUSHMITA PATHY**
E-mail : drsush_p@yahoo.co.in

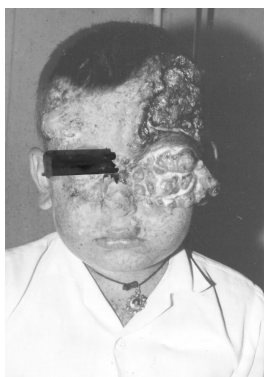

Figure 1a : Ulceroproliferative lesion left side of face involving left eye, temporal region,

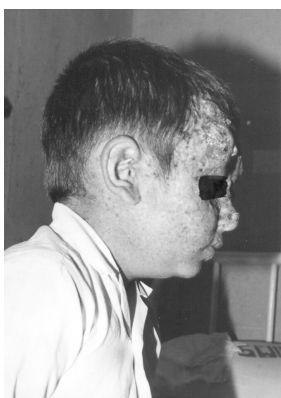


Figure 1b : Ulceroproliferative lesion on right side of the face 4 x 3 cm with crusting and haemorrhage.

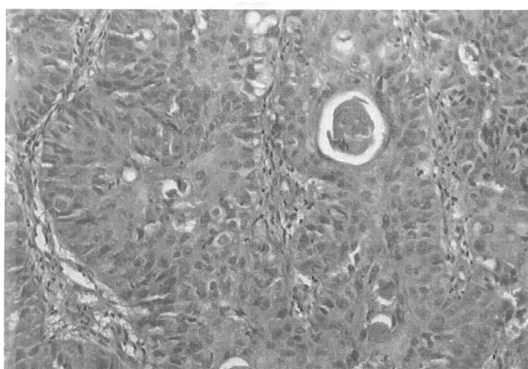


Figure 2 : Photograph showing rests of squamous cell carcinoma with keratin pearls (H&E x 100)

control. The patient was then continued on symptomatic treatment. Appropriate counselling was offered to both the parents emphasizing the need for early recognition of malignancy.

DISCUSSION

The incidence of xeroderma pigmentosa is approximately 1 in 250,000 population.⁴ The exact genetic defects are still not fully understood in all forms of xeroderma pigmentosa, but defective excision repair of UV induced DNA damage is found in most individuals. Defective repair replication was later reported with dermal fibroblasts, lymphocytes and conjunctival cells.⁵

There are 10 genetic complementation groups; while one group exhibits defective, post replication repair (XP variant), nine are deficient in excision repair (XP group A-I) . Owing to impaired ability to repair, defective or damaged DNA is retained. Retention of the damaged DNA leads to heritable chromosomal mutation and cell death, which possibly cause neoplastic and atrophic clinical abnormalities.

Skin changes are noticed between 12-36 months in 75% cases, in the case reported initial symptoms were noticed at 6 months of age.

The cutaneous stages are well defined and similar cutaneous changes are also observed in porphyria and aminoaciduria, however no humoral substances have been demonstrated in xeroderma pigmentosa.

Ocular manifestations include-photo-phobia as the earliest symptom which is a feature of keratitis. This was also seen in the present case study. Other ocular complications include exposure keratitis, vascularization, ulceration, nodular dystrophy and uveitis. Neurologic defects are detected in 20-30% of patients with XP. Microcephaly, delayed motor development, dementia, sensorineural deafness are common disorders.⁶

The disease is a progressive and accelerated degeneration of skin, eyes and nervous system take place. If left untreated most

of the patients die before the completion of second decade. The course of the disease can be modified by appropriate preventive measures against exposure to sunlight. Prophylactic treatment with topical application (titanium dioxide cream, para-amino benzoic acid in alcohol) may be administered early.

Amniocentesis and in vitro cell culture and detection of defective DNA repair may suggest prenatal diagnosis.⁷

Cutaneous neoplasia are generally treated with electrodesiccation and curettage or by excision. In the case reported above excision was not feasible due to the extensive lesion, multiple satellite lesions and poor general condition. Therefore palliative radiotherapy was offered and the patient achieved adequate palliation.

REFERENCES :

1. Hebra F, Kaposi M. *On diseases of the skin including the exanthemata* 3rd ed. London. The Men Sydenham Society 1874;pp.252-58.
2. Sarojini PA, Malhotra YK, Bhutani LK, Kandhari KC. *The de-sanctis cacchione syndrome*. *Indian J Derm Vener* 1969;35:247.
3. Kunwar KB, Kumar S. *Xeroderma pigmentosa with basal cell carcinoma*. *J Indian Med Assoc* 1967;48:273.
4. Knaemer KH, Lee MM, Scotto J *Xeroderma pigmentosum – cutaneous, ocular and neurologic abnormalities in 830 published cases*. *Arch Dermatol* 1987;123:241-50.
5. Newsome DA, Kraemer KH, Robbins JH. *Repair of DNA in xeroderma pigmentosum conjunctiva*. *Arch Ophthalmol* 1975;93:660-2.
6. Lambert WC, Kno HR, Lambert MW. *XP (Review)* *Dermatol Clin* 1995;13:169-209.
7. Ramsay CA, Cultart TM, Blunt S, Pawsey SA and Giannelli F. *Prenatal diagnosis of xeroderma pigmentosum : Report of first successful case*. *Lancet* 1974;2:1109-1112.



IJMPO would like to publish 'Profile of a Cancer Centre' or an Oncology department in a major teaching institute/hospital in India outlining its history, facilities available, and achievements in the field of research, teaching and patient care. Please send your write-up (up to 2000 words) with 2-3 photographs.