

Case Report-IV

Primary Liposarcoma of Orbit

SRIDHAR P. S., D. N. SHARMA, P. K. JULKA AND G. K. RATH

ABSTRACT

Primary liposarcoma of orbit is extremely rare. We report 2 cases of orbital liposarcoma who presented with proptosis. Pertinent literature is reviewed .

INTRODUCTION

Liposarcoma is most common soft tissue sarcoma among adults and constitutes about 16% of all soft tissue sarcomas. Common sites are thigh and retroperitoneum. Primary liposarcoma of orbit is extremely rare 0.3%.

Case 1: A 40 year old lady presented in July 2003 with progressive left side proptosis of past 3 years duration. Examination revealed VIth nerve palsy with protosis left eye. Rest of the systemic examination was within normal limits. CAT scan & MRI showed ill-defined intraconal mass lesion involving retro bulbar fat and medial rectus muscle in left orbit (Fig 1 & 2). Lesion was seen around the optic nerve but optic nerve was normal. Inferolateral displacement with proptosis of left eye globe was noted. Right eye and globe were normal. She underwent bicornal scalp flap with left fronto-orbital craniotomy and tumour excision. Per-operative, there was multilobulated cystic lesion, grayish white in colour, and firm 1.5x1 cms, vascular lesion. Histopathological examination revealed a well-differentiated liposarcoma. Chest X-ray and Ultrasound of abdomen was normal. She was

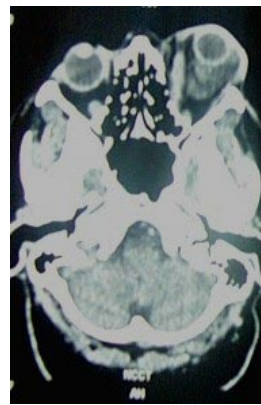


Fig. 1

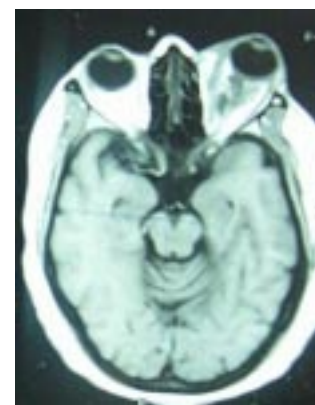


Fig. 2

treated with postoperative radiotherapy 25Gy in 5 fractions over one week and exentration of left eye for residual lesion.

Case 2: A 50 year male presented in Feb 2001 with swelling of left orbit for 6 months and diminution of vision of 5 months duration. Examination revealed left eye diffuse proptosis with eye ball deviated downwards with gross chemosis. CECT scan showed extra conal mass in left orbit, 3x2 cms in superior lateral part, homogenously enhancing pushing the left eye ball anteriorly, inferiorly indenting the globe. Right eye was normal. He underwent left frontal orbitomy and gross total excision of intraorbital extra conal tumour. Histopathological examination revealed features of myxoid liposarcoma. He received postoperative radiotherapy 60 Gy in 30 fractions over 6 weeks.

DISCUSSION

Primary orbital liposarcoma is rare. Only 25 cases have been reported so far.¹⁻⁷ Most patients present with proptosis, diplopia, and occasionally diminution of vision. CAT Scan and

Department of Radiotherapy All India Institute of Medical Sciences, New Delhi-110029, India.

Correspondence to : **SRIDHAR P.S**
E-mail-docsridharps@yahoo.com

MRI scan help in diagnosis. CAT scan showed well-defined rounded intraconal mass of low density.^{1,2} MRI scan may delineate abnormally high signal from part of the orbital fat. Differential diagnosis includes- lipoma, haemangioma, inflammatory process, pseudo tumor and metastases. Metastases from Primary liposarcoma elsewhere should be ruled out. Surgery in the form of orbital exentration is primary treatment of choice. Vision sparing wide excision for localized tumour has also been attempted. Radiotherapy is used either as pre or postoperative adjuvant treatment.¹⁻⁷ Biopsy is confirmatory. Well differentiated tumours are common, dedifferentiated variety is rare. Overall prognosis is good.

REFERENCES.

1. *Lmonteiro MR. Liposarcoma of the orbit presenting as an enlarged medial rectus muscle on CT scan.Br.J.Oph. 2002;86(12):1450-51.*
2. *McNabb AA, Masely I. Primary orbital liposarcoma: Clinical and computed tomographic features.Br. J. Oph. 1990;74:437-9.*
3. *Naser P, Mastrom U. Liposarcoma of the orbit.a clinico pathological case report.Br.J.Oph 1982;66:190-3.*
4. *Lane CM, Wright JE, Garner A. Primary myxoid liposarcoma of the orbit.Br.J.Oph. 1988;72:912-17.*
5. *Cai YC, McMenamin ME, Rose G, et al. Primary liposarcoma of the orbit: a clinicopathologic study of seven cases. Ann Diagn Pathol. 2001;5(5):255-66.*
6. *Wagle AM, Biswas J, Subramaniam N, Mahesh L. Primary liposarcoma of orbit:a clinicopathological study. Orbit. 1999;18(1):33-36.*
7. *Stiglmeier N, Jandrokovic S, Miklic P, Hutinec Z. Atypical lipoma: well-differentiated liposarcoma of the orbit with dedifferentiated areas. Orbit. 2003;22(4):311-6.*



IJMPO would like to publish 'Profile of a Cancer Centre' or an Oncology department in a major teaching institute/hospital in India outlining its history, facilities available, and achievements in the field of research, teaching and patient care. Please send your write-up (up to 2000 words) with 2-3 photographs.