

Letters to the Editor

Thymic Carcinoma with Long Term Survival

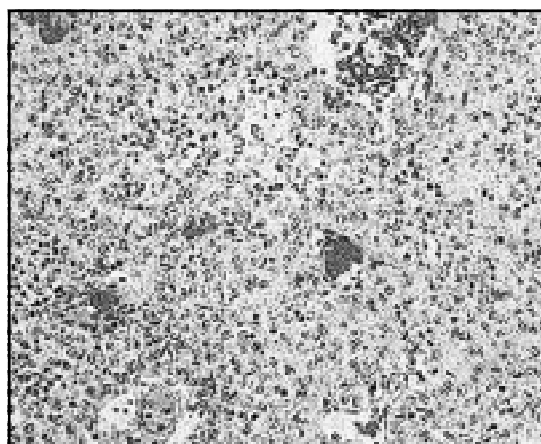
Sir,

Thymic carcinoma is a rare aggressive neoplasm that has a poor prognosis. Like Thymoma, it is an epithelial tumour, but cytologically it exhibits malignant features. The optimal treatment of thymic carcinoma remains undefined, but currently a multimodality approach, including surgical resection, postoperative radiation, and chemotherapy, is followed by most investigation. Overall survival rate at 5 years is 35%. We report here a case of high grade thymic carcinoma who was disease free for more than five years after diagnosis following multimodality treatment.

CASE: A 55 year old male, smoker presented in April 2000 with complaints of mild uneasiness in the retro sternal region. X-ray and CAT scan of chest revealed anterior mediastinal mass. General and systemic examination was within normal limits. Investigations including the hemogram, liver and renal function tests were normal. Serum AFP and b-HCG were negative. He underwent thoracotomy. During surgery the mass was found to arise from the thymus. A complete resection was done with pathologically proven negative margins. Histopathology: revealed well differentiated carcinoma with foci of keratinisation (fig 1). Stains for LCA and AFP were negative. Cytokeratin (CK) was strongly positive. A diagnosis of thymic carcinoma was made and patient received post-operative radiotherapy (total dose-40 Gy in 25 fractions). After 3 weeks of completion of radiotherapy he received six cycles of chemotherapy using Cyclophosphamide (650mg/m²), Vincristine (1.4mg/m² maximum of 2 mg) and Adriamycin (60mg/m²) every 3 weeks. Patient remains disease free till his last follow up in September 2005.

COMMENTS

Thymic carcinoma is a rare neoplasm with approximately 150 cases being reported in the literature.¹ It usually presents in 4th to 6th decade



Histopathology of the thymectomy Specimen (H&E X40) showing well differentiated carcinoma.

and nearly half of the patients are asymptomatic at diagnosis with 90% presenting as anterior mediastinal mass. In remaining cases, patients may present with cough, chest pain, and signs of upper airway congestion or paraneoplastic autoimmune syndromes associated with thymomas.²

Treatment of this highly malignant tumour is still not standardized owing to its rarity. Currently multimodality approach, including surgical resection, postoperative radiation, and chemotherapy is recommended.¹ One analysis noted a 9.5-month median survival after resection and postoperative electron-beam radiation therapy.¹ Combinations of doxorubicin, cyclophosphamide, and vincristine are effective.³ Use of neoadjuvant chemotherapy has also been reported in a small number of patients.¹ The histology in thymic carcinoma is the best indicator of prognosis. Results reported by Kuo et al in 13 patients suggested that all those with low grade histology had a long survival whereas those with high grade tumour had a shorter survival (median 9.5 months).^{3,4}

The present case responded well to the treatment and is disease-free after five years. We suggest that chemotherapy should be considered in the management of thymic carcinoma.

AVS Suresh, Hemant K Dadhich, Girish H Mallesara, G. Anupama, PP Bapsy, K. Govind Babu

Department of Medical Oncology,
Kidwai Memorial Institute of Oncology,
Bangalore.-560029 E-mail: sureshattili@yahoo.com

REFERENCES:

1. Cameron RB, Loehrer PJ Sr, Thomas CR Jr: *Neoplasms of the mediastinum*. In: DeVita VT Jr, Hellman S, Rosenberg SA, eds.: *Cancer: Principles and Practice of Oncology*. 7th ed. Philadelphia, Pa: Lippincott Williams & Wilkins, 2005;845-58.
 2. Schmidt-Wolf IG, Rockstroh JK, Schüller H, et al.: *Malignant thymoma: current status of classification and multimodality treatment*. *Ann Hematol* 2003;82(2):69-76.
 3. Kuot-T, Chang J-P, Lin F-J, Wu W-C, Chang C-H: *Thymic carcinomas: Histopathologic varieties and Immunohistochemical study*. *Am J Surg Pathol* 1990;14:24-34.
 4. Weide LG, Ulbright T.M :*Thymic carcinoma-A distinct clinical entity responsive to chemotherapy*: *Cancer*. 1993;71(4):1219-2.
-