

Original Article-I

Neoadjuvant Chemotherapy in Advanced Epithelial Ovarian Cancer : A Retrospective Study

SHEKHAR SHARMA, D.K. VIJAYKUMAR, CHITRATHARA K, ALTAF GAUHAR HAJI, ROBIN C. GEORGE AND PAVITHRAN K.

ABSTRACT

Background: Even though primary debulking surgery is the established standard of care in advanced ovarian cancer (EOC), optimal cytoreduction is not feasible in all patients. The purpose of this study was to audit our experience with reference to primary cytoreduction vs. neoadjuvant chemotherapy (NACT).

Design: Retrospective study

Methods: Case records of patients with EOC operated between March 2004 to June 2006 at the department of Surgical Oncology were reviewed. Analysis was done using statistical software SPSS 11.0. Fischer's exact two-tailed test was used for analysis of significance and Kaplan Meier Graph for survival statistics.

Results: Eighty-five cases of EOC were operated (mean age 53.6 years) during the study period. Majority (84.7%) were advanced stage (70.6% stage IIIC & 14% stage IV). Of these 44.5% underwent primary cytoreductive surgery while 55.5% received NACT followed by interval debulking. The probability of optimal

cytoreduction was higher in the NACT group than with primary surgery (88.6% vs. 50.0%; $p < 0.0001$). With a median follow up of 399 days, there were 32 cases (44.4%) of recurrence and nine (12.5%) with CA-125 rise only. In both the groups pattern and rate of failure (distant, local and CA-125 rise) were similar ($p = NS$).

Conclusions: In our experience NACT improves resectability in advanced ovarian cancer and provides a basis for argument for prospective randomized controlled clinical trials to explore the role of NACT in advanced ovarian cancer.

INTRODUCTION

Treatment of advanced EOC is a therapeutic challenge.¹ Inverse correlation between survival and the residual tumour after primary surgery was suggested in 1975 in a seminal report by Griffiths in 1975.² However, there are no randomized trials to establish primary cytoreduction as the standard of care for patients of ovarian cancer.³ Still primary cytoreductive surgery followed by platinum and paclitaxel based chemotherapy is currently standard treatment for advanced ovarian cancer.⁴

The aim of our review was to audit our own experience and to add our data to the

Department of Surgical Oncology (Shekhar Sharma, D.K. Vijaykumar, Chitrathara K, Altaf Gauhar Haji, Robin C. George) and Department of Medical Oncology (Pavithran K) AIMS, Edapally, Ernakulam - 682026

Correspondence to: SHEKHAR SHARMA
E-mail: drshekharsharma@gmail.com

published literature in an attempt to search for some answers to the vexing issue of timing of surgery and chemotherapy in ovarian cancer.

METHODS

In this retrospective analysis, we reviewed case records of all patients operated for carcinoma of ovary between March, 2004 to June, 2006 to evaluate the outcome of surgical effort in terms of optimal cytoreduction and recurrence rates.

The diagnosis of carcinoma of ovary was established using a combination of ascitic cytology, CA-125 estimation, and histology (FNAC or Core biopsy) and imaging.

All patients who received both chemotherapy and cytoreductive surgery were included. Criteria for administering NACT were: Stage IV disease at presentation; Co-morbid conditions or general condition of the patient precluding any immediate surgical intervention; Patient refusal for surgery at presentation (patients who refused surgical cytoreduction even after NACT were excluded) and Bulky disease deemed inoperable at presentation by the treating surgeon (due to

clinical or imaging features like fixed pelvic mass with parametrial infiltration, plaque like peritoneal deposits on undersurface of diaphragm, bulky supra-renal adenopathy or infiltration of hollow or solid viscera).

STATISTICAL ANALYSIS

Information was captured and analyzed using SPSS 11.0 statistical tool. Fischer's exact two-tailed test and Kaplan Meier Survival graph were the statistical models used.

RESULTS

A total of 85 patients were identified who underwent surgery during the study period. Of these 72 (84.7%) had advanced stage and were included in the final analysis. Patient characteristics are shown in table 1.

The most common symptom at the time of presentation was abdominal discomfort (98%) mainly in the lower abdomen followed by abdominal distention (86%).

Forty patients (55.5%) received NACT while 32 patients (44.5%) underwent primary cytoreductive surgery. Chemotherapy details are given in table 1.

Table 1: Patient Characteristics

Characteristic	
Age in years: mean (range)	53.62 (19 – 78)
Duration of symptoms in months: median (range)	6 (1-24)
FIGO Stage	
Early (I-II)	13 (8.2%)
Advanced (III-IV)	72 (84.7%)
Pre-treatment (Median) CA-125 U/ml	631 (7.31 – 13500) U/ml
Chemotherapy regimen	
Refused / Interrupted chemotherapy after surgery	5 (5.8%)
Platinum + Taxane	49 (57.6)
Single agent platinum	12 (14%)
Platinum with other drug	19 (22.4%)
NACT cycles (range & mean)	2-6 (2)

The main reasons to choose single agent chemotherapy or other drugs with platinum were-poor general condition or financial constraints of the patient. The overall rate of optimal cytoreduction in advanced ovarian cancer was 71.7% (50.0% for primary surgery vs. 88.6% for NACT; $p < 0.0001$). This assumes more significance due to the fact that there may have been an inherent bias to give NACT to patients with bulky disease or patients with poor general condition who may not have tolerated an initial optimal debulking attempt at the time of presentation.

Relapse: 32 (44.6%) patients had evidence of recurrence on clinical and radiological examination and 9 (12.5%) had CA-125 rise alone (biochemical relapse) while four patients (5.5%) were lost to follow up. Sites of relapse were: peritoneal disease-18 patients, retro peritoneal lymph nodes-5, pulmonary-6, liver/spleen-4 patients each and intracranial in one patient.

Recurrence rate in the two arms was similar (50.0% for primary surgery vs. 42.5% for NACT; $p = \text{NS}$).

Survival: The median overall up follow was 399 days (range 26 to 1014 days). The disease free survival was 40.6% for primary surgery and 57.5% for NACT; $p = \text{NS}$. All the four patients lost to follow-up were in advanced stage disease and had undergone primary surgery and subsequently had refused chemotherapy.

Kaplan Meier survival curve (Fig. 1) shows trend towards better survival in patients who received NACT ($p = \text{NS}$). However the difference as well as the duration of follow up is insufficient to make any definite conclusions.

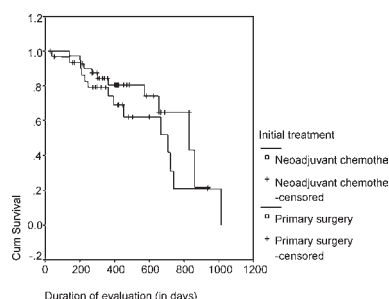


Fig 1: Kaplan Meier Survival graph for patients with advanced ovarian cancer undergoing either NACT or primary surgery.

DISCUSSION

Despite controversies in the definition of optimal cytoreduction, all investigators agree that patients who fail to undergo optimal debulking at the first attempt have a much poorer prognosis.⁵ Not only the volume of residual disease, but also the initial metastatic tumour load is of prognostic significance.

Even though aggressive surgery is important in the treatment of ovarian cancer, tumour biology also co-determines the success of surgery as is shown by several observers.⁶⁻⁸ Advanced stage at presentation and biology of the tumour co-determine the abysmal 5-year survival figures of about only 25% in these patients.

The primary aim of our audit was not to debate on the role of primary surgery, which remains the gold standard of care, but to establish better resectability (and the equivalent overall survival) with use of NACT in advanced ovarian cancer. An approach that provides equivalent survival with better (lesser) treatment related morbidity should ideally be the treatment of choice (*Primum non nocerum*). Essentially our observations are similar to those made by Kuhn et al⁷ in the first prospective study on NACT in ovarian cancer.

NACT followed by interval debulking surgery has been proposed as an alternative approach for the initial management of bulky ovarian cancer, aiming at the improvement of surgical efficacy and patients' quality of life. The interest in NACT in advanced ovarian cancer grew out of observation of good overall response rate using platinum and taxane based chemotherapy in sub optimally cytoreduced patient. Published literature (Table-3) consists predominantly of retrospective observations and it appears that NACT followed by interval cytoreduction improves the prognosis and quality of life in selected groups of patients.⁹⁻²⁸ It is significant to note that these studies have been limited to patients bearing medical conditions that precluded an immediate surgical intervention. Out of the studies quoted here only 2 have compared the use of NACT as the primary

Table 2: Review of Literature

Investigator	n	Survival (months)	Conclusions of authors / Remarks
Vergote et al [4]	75	NA	Crude survival higher when selecting about half of the patients for NACT
Kuhn et al [9]	37	42 (IDS+); 23 (IDS-)	Better median survival for patients treated with NACT vs. primary debulked group
Wils et al [10]	50	3 years: 25%	NACT appears to enhance the cure rate in advanced ovarian carcinoma
Neijt et al [11]	47	3 years: 30%	Survival not prolonged after optimal interval cytoreduction following induction chemotherapy / Study criticized due to non comparable groups
Lawton et al [12]	36	NR	Resection rates better with NACT / No survival data offered
Ng et al [13]	27	NR	NACT is a feasible option / No survival data offered
Jacob et al [14]	22	16	Same survival with NACT as with 18 matched controls
Lim et al [15]	30	10.2	NACT can make patients operable
Redman et al [16]	79	15 (IDS+); 12 (IDS -)	Interval debulking surgery may not improve survival in patients with advanced ovarian cancer.
van der Burg et al [17]	278	26 (IDS+); 20 (IDS -)	Patients with good response to NACT had better survival compared to those with partial response
Surwit et al [18]	29	21	Median survival after NACT was 21 months
Schwartz et al [19]	59	17.5 (IDS+); 8 (IDS -)	Similar survival compared with those treated during same period with primary surgery
Huober et al [20]	38	NR	NACT improves the resection rates with lesser morbidity / No survival data offered
Kayıkçıoğlu et al [21]	45	27	NACT followed by interval debulking surgery does not appear to worsen prognosis
Ansquer et al [22]	54	22	Better survival for patients treated with NACT vs. nondebulked tumour
Vrscaj et al [23]	20	24.7	NACT does not have unfavourable effect on prognosis
Ushijima et al [24]	65	NA	Survival similar in NACT group compared with primary debulking group with potential benefits for the patients with clinically aggressive ovarian cancer who are unable to receive standard treatment.
Fanfani et al [25]	73	40 (IDS+)**; other DNS	NACT followed by successful interval debulking surgery can achieve good results in terms of survival outcomes
Shibita et al [26]	29	NR [§]	Long term outcome was not statistically different in patients given NACT
Morice et al [27]	57	NR [@]	Survival rates were similar in patients with advanced stage ovarian cancer who underwent interval debulking surgery or primary debulking surgery but interval debulking surgery patients had lesser morbidity
Mazzeo et al [28]	45	44 (CR); 27 (PR)	NACT followed by optimal interval debulking surgery may be a safe treatment alternative in patients with primarily unresectable advanced ovarian cancer

CR = Complete response to chemotherapy; DNS = data not shown; IDS = Interval debulking surgery; NA = full article access was not available; NACT = Neoadjuvant chemotherapy; NR = not reported; PR = Partial response to chemotherapy

** - this is the reported median survival for patients who had an optimal cytoreduction at time of IDS

§ - this study reports comparable survival based on survival graphs with maximum follow up for >2800 days

@ - this study reports comparable survival based on survival graphs with a range of follow up of 6-64 months (median 20 months).

modality prior to any surgical intervention¹⁸⁻¹⁹ as against the use of chemotherapy after an initial unsuccessful surgical attempt (in which case the chemotherapy is better termed as induction chemotherapy).

Our study, although retrospective in nature, includes patients who could have been eligible candidates for surgery upfront but received NACT due to refusal for surgery or treating oncologist's assessment.

Taken together these studies have shown that use of NACT followed by interval debulking reduces perioperative morbidity²⁹⁻³⁰ in terms of significant reduction in estimated blood loss, duration of postoperative intensive care unit stay and overall hospitalization, does not worsen the prognosis, and more importantly improves the quality of life.³¹

These studies have been reviewed^{20,32} and except for one study¹¹ have shown to clearly establish the safety and feasibility of NACT in advanced ovarian cancer. Not only is this approach safe in terms of treatment related morbidity but also, more importantly, it does not adversely affect the survival (overall or disease free). The lone differing study¹¹ has been criticized for biased results due to non-comparable groups (primarily optimally cytoreduced vs. primarily sub optimally cytoreduced) and a small size of study population.

The argument in favour of NACT is multifactorial. First, given the advanced stage at diagnosis (84.7% in our study), patients are usually nutritionally depleted and in poor general condition. Following NACT, patient's performance status is improved prior to surgery, owing to the reduction in tumour volume, ascites and pleural effusion. With the disease under control and relief of distressing symptoms of abdominal distension and discomfort, nutritional improvement ensues resulting in improved perioperative outcome as also the need for a less extensive surgery due to reduced tumour bulk. Finally, surgical cytoreduction may be improved, which in turn leads to a better prognosis and survival. An additional advantage of NACT is that it allows the in vivo assessment

of tumour chemo sensitivity, which permits the clinician to choose appropriate therapeutic options.

Kuhn et al⁹ in 2001 showed a significantly higher rate of optimal cytoreduction ($p = 0.04$) and a longer median survival time (42 vs. 23 months; $p = 0.007$) in patients receiving NACT in the first non-randomized prospective series evaluating NACT (3 cycles of carboplatin plus paclitaxel) followed by interval debulking vs. primary debulking followed by cisplatin (with or without paclitaxel) based chemotherapy in stage III C ovarian cancer ($n = 63$). The only other prospective (but non-randomized) trial by Chan et al³¹ focused on the impact of NACT on patients' quality of life.

More recently Bristow et al³²⁻³³ have published a systematic review of neoadjuvant chemotherapy and interval cytoreduction in which they conclude that the survival outcome achievable with initial chemotherapy is inferior to successful upfront cytoreductive surgery and also that survival outcome was inversely proportional to an increasing number of pre-operative chemotherapy cycles with each additional cycle associated with a 4.1 month reduction in median survival time. However whether the two groups are really comparable is a matter of debate. Most patients taken for neoadjuvant chemotherapy have a poorer general condition, more volume disease and possibly poorer tumour biology and hence one would expect a poorer result in this group. A true comparison would be made if all the inoperable patients (by whatever criteria used) were randomized separately into the two arms and then analyzed for outcome.

Our observations are similar to those of Deo et al who reported 73% optimal debulking rate following NACT.³⁴ In our experience, neoadjuvant chemotherapy followed by interval debulking surgery resulted in significant subjective and objective improvement with outcome similar to that achieved with standard approach ie. primary surgery followed by chemotherapy.

There are certain limitations of our study, major ones being-retrospective nature and small

sample size. Other limitations include short follow up, incomplete data with reference to quality of life and disease free progression.

Acknowledgements:

The contribution and help of Dr. K.R. Sundaram, Prof and Head, Dept of Biostatistics, in the analysis of the data is gratefully acknowledged. We also acknowledge the contributions of Dr. Rajni Parikh in collating the data in analysable format.

REFERENCES:

1. Deppe G, Baumann P. Advances in ovarian cancer chemotherapy. *Current Opin Oncol* 2000;12:481-91.
2. Griffiths CT. Surgical resection of tumour bulk in the primary treatment of ovarian carcinoma. *Natl Cancer Inst Monogr* 1975;42:101-4.
3. Thingpen T. The if and when of surgical debulking for ovarian cancer. *N Engl J Med* 2004;351(24):2544-46.
4. Vergote I, Gorp TV, Amant F, Neven P, Berteloot P. Neoadjuvant chemotherapy for ovarian cancer. *Oncology* 2005;19(12):1615-22.
5. Bristow RE, Tomacruz RS, Armstrong DK, et al. Survival effect of maximal cytoreductive surgery for advanced ovarian carcinoma during the platinum era: A meta-analysis. *J Clin Oncol* 2002;20:1248-59.
6. Hoskins WJ, Bundy BN, Thigpen JT, et al. The influence of cytoreductive surgery on recurrence-free interval and survival in small-volume stage III epithelial ovarian cancer: A Gynecologic Oncology Group study. *Gynecol Oncol* 1992;47:159-166.
7. Gadducci A, Sartori E, Maggino T, et al. Analysis of failures after negative second-look in patients with advanced ovarian cancer: An Italian multicenter study. *Gynecol Oncol* 1998;68:150-55.
8. Pecorelli S, Odicino F, Favalli G. Ovarian cancer: Best timing and applications of debulking surgery. *Ann Oncol* 2000;11(suppl 3):141-44.
9. Kuhn W, Rutke S, Spathe K, et al. Neoadjuvant chemotherapy followed by tumour debulking prolongs survival for patients with poor prognosis in International Federation of Gynecology and Obstetrics Stage IIIC ovarian carcinoma. *Cancer* 2001;92:2585-91.
10. Wils J, Blijham G, Naus A, et al. Primary or delayed debulking surgery and chemotherapy consisting of cisplatin, doxorubicin, and cyclophosphamide in stage III-IV epithelial ovarian carcinoma. *J Clin Oncol* 1986;4:1068-73.
11. Neijt JP, ten Bokkel Huinink WW, et al. Randomized trial comparing two combination chemotherapy regimens (CHAP-5 v CP) in advanced ovarian carcinoma. *J Clin Oncol* 1987;5:1157-68.
12. Lawton FG, Redman CW, Luesley DM, et al. Neoadjuvant (cytoreductive) chemotherapy combined with intervention debulking surgery in advanced, unresected epithelial ovarian cancer. *Obstet Gynecol* 1989;73:61-65.
13. Ng LW, Rubin SC, Hoskins WJ, et al. Aggressive chemosurgical debulking in patients with advanced ovarian cancer. *Gynecol Oncol* 1990;38:358-63.
14. Jacob JH, Gershenson DM, Morris M, et al. Neoadjuvant chemotherapy and interval debulking for advanced epithelial ovarian cancer. *Gynecol Oncol* 1991;42:146-50.
15. Lim JT, Green JA. Neoadjuvant carboplatin and ifosfamide chemotherapy for inoperable FIGO stage III and IV ovarian carcinoma. *Clin Oncol (R Coll Radiol)* 1993;5:198-202.
16. Redman CW, Warwick J, Luesley DM, et al. Intervention debulking surgery in advanced epithelial ovarian cancer. *Br J Obstet Gynaecol* 1994;101:142-146.
17. van der Burg ME, van Lent M, Buyse M, et al. The effect of debulking surgery after NACT on the prognosis in advanced epithelial ovarian cancer. Gynecological Cancer Cooperative Group of the European Organization for Research and Treatment of Cancer. *N Engl J Med* 1995;332:629-34.
18. Surwit E, Childers J, Atlas I, et al. Neoadjuvant chemotherapy for advanced ovarian cancer. *Int J Gynecol Cancer* 1996;6:356-61.
19. Schwartz PE, Rutherford TJ, Chambers JT, et al. Neoadjuvant chemotherapy for advanced ovarian cancer: Long-term survival. *Gynecol Oncol* 1999;72:93-99.
20. Huober J, Meyer A, Wagner U, et al. The role of neoadjuvant chemotherapy and interval laparotomy in advanced ovarian cancer. *J Cancer Res Clin Oncol* 2002;128:153-160.
21. Kayikcioglu F, Kose MF, Boran N, et al. Neoadjuvant chemotherapy or primary surgery in advanced epithelial ovarian carcinoma. *Int J Gynecol Cancer* 2001;11:466-470.
22. Ansquer Y, Leblanc E, Clough K, et al. Neoadjuvant chemotherapy for unresectable ovarian carcinoma: A French multicenter study. *Cancer* 2001;91:2329-34.
23. Vrscaj MU, Rakar S. Neoadjuvant chemotherapy for advanced epithelial ovarian carcinoma: A retrospective case-control study. *Eur J Gynaecol Oncol* 2002;23:405-10.
24. Ushijima K, Ota S, Komai K, et al. Clinical assessment of neoadjuvant chemotherapy and interval cytoreductive surgery for unresectable advanced ovarian cancer. *Int Sur* 2002;87:185-90.
25. Fanfani F, Ferrandina G, Corrado G, Fagotti A, Zakut HV, Mancuso S, et al. Impact of interval debulking surgery on clinical outcome in primary unresectable FIGO stage IIIC ovarian cancer patients. *Oncology* 2003;65(4):316-22.

26. *Shibata K, Kikkawa F, Mika M, et al. Neoadjuvant chemotherapy for FIGO stage III or IV ovarian cancer: Survival benefit and prognostic factors. Int J Gynecol Cancer 2003;13(5):587-92.*
27. *Morice P, Dubernard G, Rey A, et al. Results of interval debulking surgery compared with primary debulking surgery in advanced stage ovarian cancer. Am Coll Surg 2003;197(6):955-63.*
28. *Mazzeo F, Beliere M, Kerger J, et al. Neoadjuvant chemotherapy followed by surgery and adjuvant chemotherapy in patients with primarily unresectable, advanced-stage ovarian cancer. Gynecol Oncol 2003;90:163-69.*
29. *Chambers JT, Chambers SK, Voynick IM, et al. Neoadjuvant chemotherapy in stage X ovarian carcinoma. Gynecol Oncol 1990;37:327-31.*
30. *Pestasides D, Farmakis D, Koumariou A. The role of neoadjuvant chemotherapy in the treatment of advanced ovarian cancer. Oncology 2005;68:64-70.*
31. *Chan YM, Ng TY, Ngan HY, Wong LC: Quality of life in women treated with neoadjuvant chemotherapy for advanced ovarian cancer: A prospective longitudinal study. Gynecol Oncol 2003;88:9-16.*
32. *Bristow RE, Eisenhauer EL, Santillan A, Chi DS. Delaying the primary surgical effort for advanced ovarian cancer: A systematic review of neoadjuvant chemotherapy and interval cytoreduction. Gynecol Oncol 2007;104(2):480-90.*
33. *Bristow RE, Chi DS. Platinum-based neoadjuvant chemotherapy and interval cytoreduction for advanced ovarian cancer: a meta-analysis. Gynecol Oncol 2006;103(3):1070-6.*
34. *Deo SVS, Goyal H, Shukla NK, et al. Neoadjuvant chemotherapy followed by surgical cytoreduction in advanced epithelial ovarian cancer. Ind J Cancer 2006;43(3):117-20.*

