

Images in Clinical Oncology

MEIG'S SYNDROME

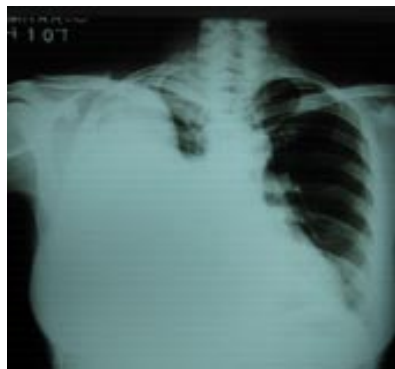

Fig 1A: Pre operative chest X ray showing massive right sided pleural effusion

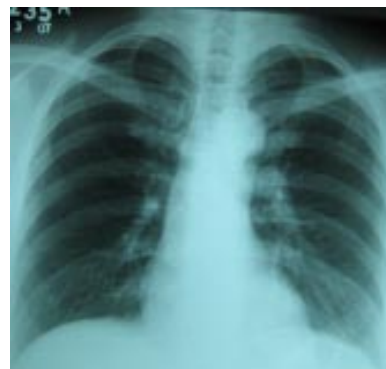

Fig 1B: post operative chest X ray showing resolution of pleural effusion

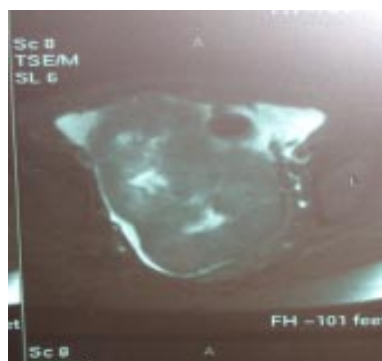

Fig 2: MRI pelvis showing heterogenous pelvic mass

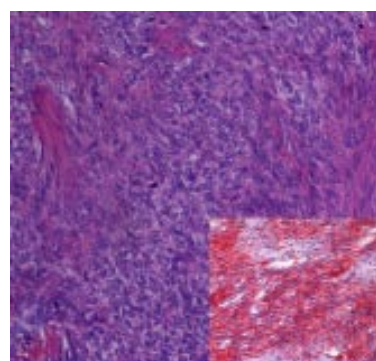


Fig 3: Histopathology of right ovary showing fibrothecoma (H & E, 200x), Inset showing oil red O staining of cytoplasmic lipid

Mrs. SS, 47-year-old school teacher presented with progressively increasing breathlessness of 6 weeks duration. Clinical examination revealed good general condition, right-sided pleural effusion, ascites and abdomino pelvic mass measuring about 8x8 cms. Investigations showed: normal haemogram and biochemistry, CA125-803 U/ml, chest X ray- right sided massive pleural effusion (Fig 1A), MRI abd/pelvis revealed bilateral heterogenous pelvic mass with ascites (Fig 2), upper and lower GI endoscopy was normal. A tentative diagnosis of ovarian carcinoma was made. Ascitic cytology and pleural cytology done thrice were negative for malignant cells. She underwent laparotomy; panhysterectomy, infracolic omentectomy and pelvic lymphadenectomy was done. Intraoperatively, there was 1000ml of ascitic fluid, right ovarian tumour 8x10 cm, left ovary normal, uterus normal size and omentum was free of tumour. Histopathology revealed fibrothecoma of right ovary (Fig 3). Left ovary and tube, right fallopian tube, uterus, omentum and pelvic lymph nodes were all free of tumour. Her right pleural effusion resolved after surgery (Fig 1B). Presently patient is asymptomatic and disease free.

Meigs' syndrome first described in 1937 is a triad of benign ovarian tumour accompanied by ascites and hydrothorax. The commonest tumours of ovary associated with this syndrome are fibroma and fibrothecoma. Surgery is the treatment of choice. Pleural effusion and ascites resolves after surgical debulking.

Navdeep Singh, Roopa Hariprasad, Sunesh Kumar
 Department of Medical Oncology & Gynecology
 IRCH, All India Institute of Medical Science,
 New Delhi-110029