

Case Report-II

Coexisting Carcinoma Cervix and Hydatidiform Mole-A Case Report

ROBIN GEORGE C, SEKHAR SHARMA, DK VIJAY KUMAR AND ALTAF GAUHAR HAJI

ABSTRACT

Coexistence of carcinoma cervix and hydatidiform mole is a hereto unreported presentation. We report here a case of carcinoma cervix with hydatidiform mole with final histological correlation and serum marker studies.

INTRODUCTION

Carcinoma cervix is the most frequent of all genital tract malignancies. Cervical cancer is the second cancer related death among females worldwide. An extensive literature search did not reveal any report of carcinoma of cervix coexisting with hydatidiform mole. We report here one such case.

CASE: A thirty-seven year old female had presented to the outpatient department with complaints of increased bleeding per vaginal since 2 months. She also had white discharge per vaginum. This multiparous lady had 3 children, all full term normal deliveries. She had conceived for the fourth time 4 years back but had abortion at 3 months gestational age and since then she had polymenorrhea. She had no co-morbidities. On evaluation her general and systemic examination were within normal limits. Her abdominal examination did not reveal any significant findings. Speculum examination revealed a midposed cervix with erosive lesion on both lips of cervix extending into endocervix, clinically stage IB1. On bimanual examination her uterus was normal

size, anteverted, anteflexed with restricted mobility. Vagina and parametria were clinically uninvolved. Her hemogram, renal function tests were within normal limits. She was investigated with USG pelvis, which was reported as normal study. PAP smear done was reported as inflammatory smear with squamous metaplasia. She underwent cervical biopsy, which was suggestive of adenosquamous carcinoma (moderately differentiated). She underwent endocervical curetting, which was unremarkable, and showed late secretory endometrium. MRI pelvis revealed an area of abnormal signal seen in lower cervix in central left aspect measuring 2.5cm. Endometrial cavity appeared expanded with evidence of fluid signal within it. With these findings she underwent radical hysterectomy with bilateral pelvic lymph node dissection. Per-operatively she had minimal fluid in the peritoneal cavity with bulky uterus, enlarged left pelvic nodes, elongated cervix with erosive lesion extending into the endocervix. Surgical specimen, when grossed, revealed a villous projection from the fundic region measuring about 1cm (fig. 1).

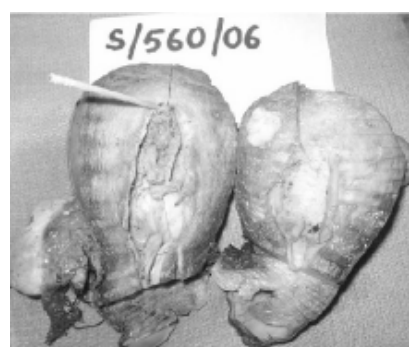


Figure 1: Surgical specimen

Department of Surgical Oncology, Amrita Institute of Medical Sciences and Research Centre Kochi, India.

Correspondence to: **ROBIN GEORGE C.**
Email: robin.g.007@gmail.com

Her final histology was reported as adenosquamous carcinoma of cervix with < 5mm depth of invasion stage IA2 (fig. 2) and an endomyometrial mass suggestive of trophoblastic tissue with villi confined to the cavity with no muscle invasion (fig. 3), and a leiomyomatous nodule near the fundus. Right ovary showed hemorrhagic corpus luteum, left ovary had follicular cyst. She withstood the surgery well and her post-operative period was uneventful.

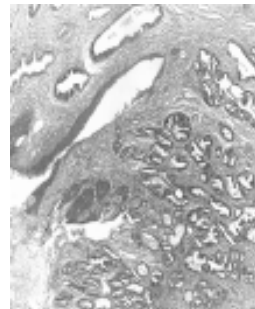


Fig. 2: Histopathology slide photograph showing areas of adenosquamous carcinoma of cervix

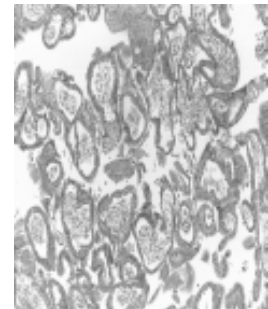

Fig. 3: Histopathology slide photograph showing areas of hydatidiform mole

Table 1: β -HCG values in the Post-operative Period

Post-operative day (POD)	β -HCG value (mIU/ml)
8 th POD	1220.0
12 th POD	313.0
16 th POD	117.0
20 th POD	46.28
24 th POD	21.14
28 th POD	9.5
32 nd POD	3.79
36 th POD	2.74
40 th POD	2.1
44 th POD	1.9

Table 2: Risk score categorization as per the WHO prognostic scoring system (FIGO modification) (1)

Criteria	Score
Age (years)	0
Antecedent Pregnancy	1
Interval from index pregnancy	4
Pretreatment serum HCG level	Not done *
Largest tumour size	0
Site of metastasis	No metastasis
Number of metastasis identified	nil
Previous chemotherapy failed	nil

* - If the pretreatment value is considered to be at least as high as the first postoperative value then the score under this heading will be 1

DISCUSSION

Till date no cases have been reported with coexisting carcinoma cervix and gestational trophoblastic disease. The recommended treatment for stage IA2 carcinoma cervix is radical hysterectomy with bilateral pelvic lymph node dissection. She had her β -HCG levels measured after her final histology showed coexistent hydatidiform mole with carcinoma cervix. She had her first β -HCG levels done on 8th postoperative day, which was 1220 mIU/ml. Her weekly values of β -HCG are as in Table 1.

It would be imperative to assume a very high preoperative β -HCG value since the levels dropped rapidly in the post-operative period and the first reading was obtained on the 8th post-operative day after receiving the final histopathology report. According to the WHO prognostic scoring system as modified by FIGO

she would be categorized in low risk group as shown in Table 2.¹

In this case the maximum possible score is 6 (calculated by adding individual scores for each prognostic factor). Total score of less than 6 is considered to be low risk, and a score of more than 7 is categorized as high risk.¹ It was interesting to note the final histology and the falling β -HCG levels as the two diseases are different entities and the protocol for management of each is according to its nature of progression. Currently she is on regular follow up.

REFERENCE:

1. Kohorn EI, Goldstein DP, Hancock BW, et al. Combining the staging system of the International Federation of Gynecology and Obstetrics with the scoring system of the World Health Organization for trophoblastic neoplasia. Report of the Working Committee of the International Society for the Study of Trophoblastic Disease and the International Gynecologic Cancer Society. *Int J Gynecol Cancer* 2000;(10):84-88.

