




Stereotactic Intracavitary Irradiation for Cystic Craniopharyngiomas with Rhenium-186

Irradiação estereotóxica intracavitária para craniofaringiomas císticos com Rênio 186

Walter Fagundes^{1,3}  Rodolpho Albuquerque Souza³ Gustavo Touzet¹ Philippe Carpentier²
Patrick Dhellemmes¹ Serge Blond¹

¹ Department of Neurosurgery, Roger Salengro Hospital Center, Lille University, Lille, France

² Department of Nuclear Medicine, Oscar Lambret Center, Lille, France

³ Centro de Ciências da Saúde, Universidade Federal do Espírito Santo, Vitória, Espírito Santo, Brazil

Address for correspondence Walter J. Fagundes-Pereyra, MD, MSc, PhD, Centro de Ciências da Saúde, Universidade Federal do Espírito Santo, rua Manoel Feu Subtil 110, Vitória, Espírito Santo, 29050-400, Brazil (e-mail: drwalterfagundes@gmail.com).

Arq Bras Neurocir 2023;42(4):e288–e294.

Abstract

Objective The intracavitary irradiation of cystic tumors has been used as a therapeutic alternative modality in the management of cystic craniopharyngiomas. In the present study, we review our experience, considering the technical issues, outcomes, and complications associated with the use of stereotactic intracavitary irradiation (SICI) with colloidal rhenium-186 (¹⁸⁶Re) for cystic craniopharyngioma.

Material and Methods The records of 33 patients with cystic craniopharyngiomas treated by SICI with colloidal ¹⁸⁶Re were retrospectively reviewed. The median radiation dose to the cyst wall was of 408 Gy (range: 175 Gy to 500 Gy). All tumors were composed of a large cyst cavity, and 9 (27.3%) also had a solid component. The mean follow-up period was of 3.7 years.

Results After SICI, 31 (93.9%) patients showed radiological evidence of cyst regression, and, in 2 (6.1%), no response was observed. An improvement in the visual deficits was observed in 8 cases (24.2%), and an improvement in endocrinological disturbances, in 2 cases (6.1%). We observed complications in 3 patients (9.1%): diabetes insipidus in 1 case (3%), aggravation of visual acuity in 1 case (3%), and severe headache after infusion of the colloid in 1 case (3%); and 1 patient (3%) died after meningitis.

Conclusion Stereotactic intracavitary irradiation with colloidal ¹⁸⁶Re is a safe procedure, with satisfactory results in the present series, and should be considered, in the management of cystic craniopharyngiomas, the first-intention therapy or as an adjuvant to other therapeutical modalities, with acceptable morbidity and mortality rates.

Keywords

- ▶ craniopharyngioma
- ▶ rhenium
- ▶ stereotactic techniques
- ▶ stereotactic radiation therapy

received
June 10, 2020
accepted
March 9, 2021

DOI <https://doi.org/10.1055/s-0041-1733864>.
ISSN 0103-5355.

© 2023. Sociedade Brasileira de Neurocirurgia. All rights reserved. This is an open access article published by Thieme under the terms of the Creative Commons Attribution-NonDerivative-NonCommercial-License, permitting copying and reproduction so long as the original work is given appropriate credit. Contents may not be used for commercial purposes, or adapted, remixed, transformed or built upon. (<https://creativecommons.org/licenses/by-nc-nd/4.0/>)
Thieme Revinter Publicações Ltda., Rua do Matoso 170, Rio de Janeiro, RJ, CEP 20270-135, Brazil

Resumo

Objetivo A irradiação intracavitária tem sido empregada como modalidade terapêutica alternativa no manejo dos craniofaringiomas císticos. No presente estudo, revisamos nossa experiência, considerando parâmetros técnicos, resultados e complicações associadas ao uso da irradiação estereotáxica intracavitária (IEIC) com rênio-186 (¹⁸⁶Re) coloidal em pacientes com craniofaringiomas císticos.

Material e Métodos Os prontuários de 33 pacientes com craniofaringiomas císticos tratados por IEIC com ¹⁸⁶Re coloidal foram revisados retrospectivamente. A dose média de radiação na parede do cisto foi de 408 Gy (variação: 175 Gy a 500 Gy). Todos os tumores eram compostos por uma grande porção cística, e, em 9 casos (27,3%) havia também um componente sólido. O período médio de seguimento foi de 3,7 anos.

Resultados Após a IEIC, 31 (93,9%) pacientes apresentaram evidência radiológica de regressão do cisto, e em 2 (6,1%) não foi observada resposta. Melhora do déficit visual foi observada em 8 casos (24,2%), e dos distúrbios endocrinológicos, em 2 casos (6,1%). Complicações ocorreram em 3 pacientes (9,1%): diabetes insipidus em 1 caso (3%), piora da acuidade visual em 1 caso (3%), e cefaleia intensa após a infusão do coloide em 1 caso (3%); e 1 paciente (3%) faleceu após meningite.

Conclusão A IEIC com ¹⁸⁶Re coloidal é um procedimento seguro, com resultados satisfatórios nesta série, e deve ser considerada no manejo de craniofaringiomas císticos, seja como intervenção primária, seja como adjuvante a outras modalidades terapêuticas, com taxas de morbidade e mortalidade aceitáveis.

Palavras-chave

- ▶ craniofaringioma
- ▶ rênio
- ▶ técnicas estereotáxicas
- ▶ radiocirurgia estereotáxica

Introduction

Craniopharyngiomas are benign neoplasms (grade I according to the classification of the World Health Organization [WHO]) of epithelial origin that arise from the remnants of the Rathke pouch in the sellar region. They account for 4.5% of all brain tumors¹ with a bimodal incidence, presenting peaks between 5 and 15 and 45 and 60 years of age,² and contributing to 1.2% to 4% of all intracranial tumors in children. Despite the benign histology, these tumors should be considered low-grade malignancies because of their location and progression without treatment, which generally results in a reduction in life expectancy and a 5-year overall survival rate of 80%.³

In large series, 54% to 94.4% of the patients have tumors with a significant cystic portion.⁴ Total surgical removal is the best option, but it may be associated with significant postoperative morbidity. Ophthalmological deterioration (13% to 15%), hypothalamic obesity (26% to 52%), and an endocrinological decline (> 90%) are the complications described.⁵ Moreover, high rates of recurrence are known, from 13% to 30% in cases of gross total resection (GTR), from 71% to 90% in cases of subtotal resection (STR), and of 21% in STR associated with external beam irradiation (EBI).⁶

In this context, adjuvant therapies have been considered, such as radiotherapy, radiosurgery, stereotactic drainage and intracavitary injection of radioactive colloidal solutions, or chemotherapeutic agents.⁷

Intracavitary contact irradiation was introduced by Leksell and standardized by Backlund, and intracavitary irradiation with rhenium-186 (¹⁸⁶Re), by Szikla.⁸⁻¹⁰

In the present study, we review our experience, considering the technical issues, outcomes, and complications associated with the use of stereotactic intracavitary irradiation (SICI) with colloidal ¹⁸⁶Re for cystic craniopharyngiomas.

Material and Methods**Patient Population**

Between October 1986 and November 2001, 45 patients were considered to be treated by SICI using colloidal ¹⁸⁶Re for cystic craniopharyngiomas. In total, 33 patients were considered fit for this retrospective analysis. The other 12 cases were excluded because of insufficient follow-up data for evaluation in 2 cases, leakage during the gamma camera test in 4 cases, technical problems with the injection of ¹⁸⁶Re in 2 cases, poor clinical status in 1 case, and other reasons in 3 cases. Patients with tumors of other origin treated by SICI at our institution were excluded from the study.

All patients were submitted to neurological, ophthalmological, endocrinological, and neuroradiological examinations, including computed tomography (CT) scans and magnetic resonance image (MRI) scans.

Insertion of Intracavitary Catheter

Insertion of the cyst catheter was performed under stereotactic conditions, using a Talairach stereotactic frame under general anesthesia. The precise location of the cyst was determined, the target point (the center of the cyst) and best trajectory were defined, avoiding vascular structures, as well as the ventricular system, if possible. After perforation of the cyst wall, the contents of the cyst were aspirated,

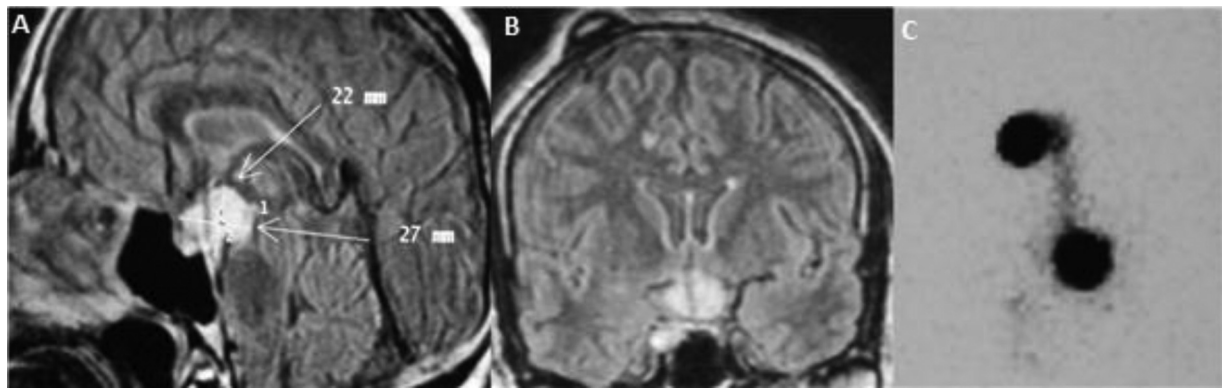


Fig. 1 Sagittal (A) and coronal (B) views of an MRI scan showing the satisfactory position of the intracystic catheter. And a gamma-camera control image without leakage of the radioisotope (C).

enabling partial decompression, and sent for a pathological examination. Finally, the catheter was attached to a subcutaneous Ommaya reservoir placed posteriorly to the incision (►Fig. 1).

A postoperative MRI scan was obtained to assess the position of the catheter and the decompression of the cyst.

Control Examination Before Irradiation

The integrity of the cyst wall was controlled postoperatively by gamma camera using a reduced dose of colloidal ¹⁸⁶Re (500 µCi) (►Fig. 1). This test aimed to detect an eventual leakage of the radioisotope. In case of a leak to the subarachnoid space, intracavitary irradiation was not performed until a new test confirming the absence of a leak.

Another MRI scan was performed to confirm the position of the catheter and to evaluate the volume of the cyst after the gamma camera control, and immediately before the SICI, considering to control.

Rhenium-186 and Dosimetry

Dosimetry was based on the volume of the cyst as determined by the gamma camera. The dosage used ranged from 2 mCi to 20 mCi (mean: 9.0 mCi). The mean cumulative dose delivered to the cyst wall was of 408.4 Gy (range: 175 Gy to 500 Gy). The dose was calculated based on the formula proposed by Backlund.⁹

The optimal dose should destroy the epithelium of the cyst with minimal side effects to the surrounding structures. According to Vanhauwaert et al.,¹¹ doses lower than 100 Gy were related with frequent early cyst recurrence, while doses higher than 1,000 Gy were associated with a high risk of complications; therefore, they suggested that doses between 200 Gy and 250 Gy could present a lower complication rate, with minimal recurrence.

Postirradiation Care

Brain and hepato-splenic scintigraphy were performed immediately and daily following the injection of colloidal ¹⁸⁶Re. An examination of the urine to find traces of the radioisotope was also performed to confirm the absence of leakage. During the treatment, the patient was confined to an isolated bedroom because of gamma emissions.

Radioisotope evacuation of the cyst was performed between four and five days after the therapeutic injection. If a leakage of cerebrospinal fluid (CSF) was detected, a complete evacuation and washing of the cavity was immediately performed.

The CT scan was performed routinely before hospital discharge.

The follow-up period ranged from 3 months to 10 years (mean: 3.7 years). The survival time was calculated from the date of the intracavitary irradiation.

The volume of the cyst was reassessed by a postoperative MRI and compared with previous exams. Volume changes were labeled, according to the proportion of decrease, as ≥ 90%, 90% to 25%, and < 25% regression, or no regression (►Table 1).

The follow-up included ophthalmologic, endocrinologic, neurological and radiological evaluations (including MRI) to assess the clinical conditions and cyst volume after irradiation, and they were obtained at three and six months after the treatment, and at six-month intervals.

Statistical Analysis

The Pearson Chi-squared (χ^2) test was used for the parametric values, and the Student *t*-test for the non-parametric values. The Fisher exact and Bonferroni correction were used when the values were inferior to five. The Epi-Info 2000 (version 1.1.2, Centers for Disease Control and Prevention, Atlanta, GA, US) software, version 1.1.2, was used.

Table 1 Reduction in cystic volume regarding craniopharyngiomas treated by SICI using colloidal ¹⁸⁶Re

| Reduction in cystic volume (%) | Number of cases (%) |
|--------------------------------|---------------------|
| ≥ 90% | 15 (45.45%) |
| 90%–25% | 05 (15.15%) |
| < 25% | 11 (33.33%) |
| 0% | 02 (6.06%) |
| Total | 33 (100%) |

Abbreviations: ¹⁸⁶Re, rhenium-186; SICI, stereotactic intracavitary irradiation;

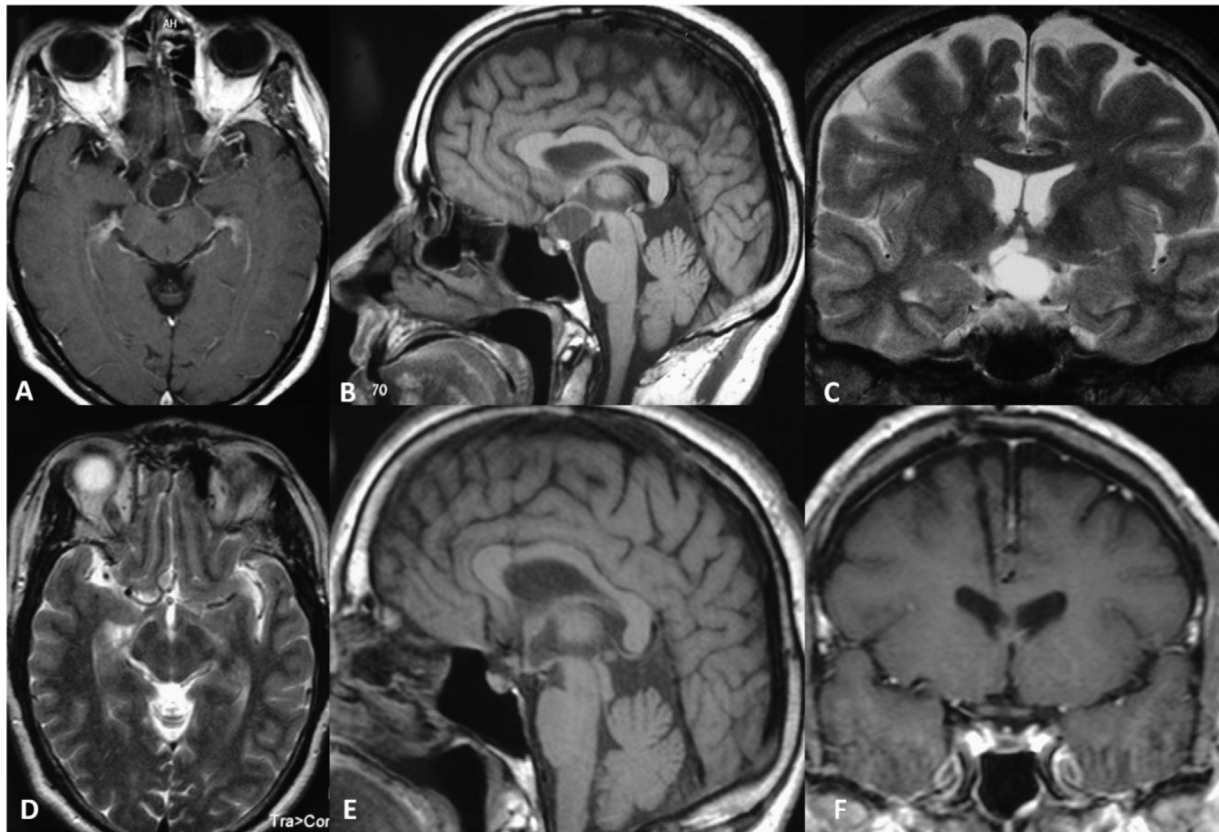


Fig. 2 Case 1. An MRI scan showing the cystic craniopharyngioma before treatment: (A) axial T1-weighted image; (B) sagittal T1-weighted image; and (C) coronal T2-weighted image. control MRI 30 months after the treatment: (D) axial T2-weighted image; (E) sagittal T1-weighted image; and (F) coronal T1-weighted image showing complete obliteration of the cyst after stereotactic intracavitary irradiation with colloidal ^{186}Re .

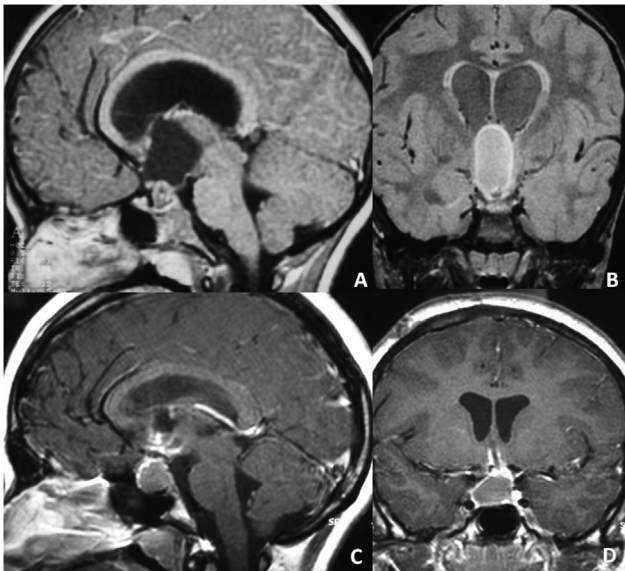


Fig. 3 Case 2. An MRI scan showing the cystic craniopharyngioma: (A) sagittal T1-weighted image; and (B) coronal fluid-attenuated inversion recovery (FLAIR) before treatment. Control MRI 48 months after the treatment: (C) sagittal T1-weighted image; and (D) coronal T1-weighted image showing complete obliteration of the cystic portion of the tumor after stereotactic intracavitary irradiation with colloidal ^{186}Re .

Ethical Issue

The present study was approved by the Committee of Ethics in Research of the Health Sciences Center at Universidade Federal do Espírito Santo (Vitória, state of Espírito Santo, Brazil), in accordance with Brazilian law and the regulations governing research involving human beings, instituted by resolution No.466/2012 of the Brazilian National Health Council, under CAAE number 85930818.7.0000.5060, advice number 2.631.734.

Results

The results of the SICI in the 33 patients in the sample are summarized in ►Table 1.

There were 20 male (60.6%) and 13 female (39.4%) patients, with a mean age of 41.8 years (range: 5 to 86 years). In total, 10 patients (30.3%) were under 15 years of age.

In 9 cases (27.2%), the craniopharyngioma was purely cystic, and, in 24 cases (72.7%), there was a solid portion associated. A total of 18 patients (54.5%) had previously undergone additional treatments, and surgery was performed in 7 (38.8%) of them, and intralesional chemotherapy and/or radiosurgery were performed in 11 (61.2%). A combination of radiosurgery for the solid component of the tumor

and ¹⁸⁶Re intracavitary irradiation was performed in 1 patient (3.0%) with satisfactory results.

In 31 patients (93.9%), there was radiological evidence of a decrease in cyst volume after the instillation of ¹⁸⁶Re. The **Fig. 2** and **3** presents two cases of wide cyst regression with the treatment. It was labeled, according to the proportion of the decrease in volume, as $\geq 90\%$, 90% to 25%, and $< 25\%$ regression (**Table 1**).

In 12 patients (36.4%), a radioisotope leak was observed in the first test before irradiation. These patients underwent a second test, which indicated that 9 (27.2%) of them presented spontaneous resolution, enabling the irradiation. In the remaining 3 (9.1%), the leak persisted, requiring surgical repositioning of the catheter before the irradiation. A total of 4 patients (12.1%) underwent a second session of irradiation, 2 (9%) presented cyst recurrence, 2 (9%) developed a new cyst, and another 2 (9%) had a leak after the radioisotope instillation, followed by complete aspiration, without clinical repercussion.

We observed complications in 3 patients (9.1%): diabetes insipidus in 1 case (3%), aggravation of visual acuity in 1 case (3%), and severe headache after infusion of the colloid in 1 case (3%).

During the follow up period, there were four deaths in the present series, but only one of them was directly related to the SICI therapy, because of meningitis followed by septicemia.

Curiously, we observed one case in which, after catheter implantation followed by aspiration of the contents of the cyst and the gamma camera test, a leak was observed, and the instillation of ¹⁸⁶Re was not possible. Nevertheless, complete obliteration of the cyst was observed during the four years of follow-up.

Discussion

Stereotactic intracavitary irradiation has been used mostly for the treatment of cystic craniopharyngiomas, with satisfactory results.³

Comparing the results of patients treated with stereotactic endocavitary irradiation for craniopharyngiomas, using yttrium-90 (⁹⁰Y) and ¹⁸⁶Re, Netzeband et al.¹² observed better results with ⁹⁰Y, although the number of patients treated with ¹⁸⁶Re was too small to obtain statistical significance.

Intracavitary irradiation was introduced by Leksell and Liden,⁸ and standardized by Backlund,⁹ employing radioac-

tive chromic phosphate. The subsequent application of this technique using a variety of different beta and gamma radiation-emitting isotopes has been reported.^{10,12,13} (**Table 2**)

The use of colloidal ¹⁸⁶Re was introduced by Szikla et al.¹⁰ in 1984, for the treatment of cystic craniopharyngiomas, and, later, for cystic gliomas. Those authors considered the advantageous physical properties of ¹⁸⁶Re in comparison to those of other radioisotopes (**Table 2**): the relatively low-energy beta radiation (358 KeV), which enables a restricted penetration of soft tissue and limits the depth of the necrosis of the cyst wall to 1 mm instead of 3 mm using ⁹⁰Y. This property might reduce the risk of damage in the adjacent structures, posed by the late effect of radiation, as seen in patients treated with ⁹⁰Y, that tend to present radiation-induced edema in peripheral areas.

The phosphorus-32 (³²P) and ⁹⁰Y isotopes are pure beta emitters, while gold-198 (¹⁹⁸Au) and ¹⁸⁶Re are also gamma emitters. The gamma emission of ¹⁸⁶Re (137 KeV) enables an excellent scintigraphic control of a possible leakage of radioactivity to CFS spaces before and during SICI.

Intracavitary irradiation aims to destroy the epithelium of the cyst without damaging the surrounding structures, and an adequate dose of the radionuclide must be employed and no radioisotope leaks must be present.

Szikla et al.¹⁰ suggested that the injected radiocolloid progressively migrates to the cyst wall during the treatment. Szeifert et al.¹⁴⁻¹⁶ demonstrated by histologic studies that, regarding the cyst wall of craniopharyngiomas following intracavitary irradiation with ⁹⁰Y, the lining of the layer of epithelial cells was damaged and the cyst wall shrank, with thickening of the capillary walls and proliferation of endothelial cells and subendothelial connective tissue with focal calcification and narrowed lumens of small vessels with a large amount of thick collagen bundles showing hyaline degeneration.

Netzeband et al.¹² compared the results of SICI for craniopharyngiomas using ⁹⁰Y and ¹⁸⁶Re; they observed more CSF leaks using ¹⁸⁶Re, and considered that the higher tendency of this complication could be due to the chemical properties of ¹⁸⁶Re, which is a sulfide and tends to convert to a water-soluble perrhenate. Berenger et al.¹⁷ considered this observation the result of a better resolution of scintigraphic images using the ¹⁸⁶Re, which enables a precise determination of even small leaks, which is usually not possible with

Table 2 Properties of the radioisotopes used in the stereotactic intracavitary irradiation of cystic tumors¹⁰

| Feature | ¹⁸⁶ Re | ¹⁹⁸ Au | ⁹⁰ Y | ³² P |
|--|-------------------|-------------------|-----------------|-----------------|
| Physical half-life (days) | 3.8 | 2.7 | 2.7 | 14.3 |
| Maximum beta energy (KeV) | 1076 | 966 | 2284 | 1710 |
| Mean beta energy (KeV) | 358 | 322 | 761 | 695 |
| Maximum range in the soft tissue (mm) | 4.5 | 4 | 10.9 | 7.9 |
| Half-value depth in the soft tissue (mm) | 1 | 0.9 | 2.9 | 0.8 |
| Maximum gamma energy (Kev) | 137 | 412 | – | – |

Abbreviations: ³²P, phosphorus-32; ⁹⁰Y, yttrium-90; ¹⁸⁶Re, rhenium-186; ¹⁹⁸Au, gold-198.

^{90}Y or ^{32}P . Those authors pointed out that the lower granulometry of ^{186}Re may have some implication in its tendency to leak, because sometimes, although the cyst wall is intact, it is permeable to colloidal isotopes of low granulometry. On the other hand, this feature enables a homogeneous distribution inside the cyst, and, even in case of an undesirable leak to the subaracnoid space, it is possibly less toxic.

The mean desired dose to the cyst wall is 400 Gy, ranging from 200 Gy to 600 Gy according to different criteria, including histology, volume, and location of the tumors. Sometimes it is difficult to calculate the exact dose due to factors such as the irregular shape of the cyst or multiple cavities, which complicate the estimation of the volume.¹⁰

Stereotactic intracavitary irradiation has been used mostly for the treatment of cystic craniopharyngiomas, with satisfactory results,^{10,18–20} but reports of its use in cases of cystic gliomas are very limited in the literature.

Szikla et al.¹⁰ treated 29 cystic gliomas by intracavitary irradiation with colloidal ^{186}Re with a mean wall dosage of 580 Gy. In total, 17 patients presented low-grade tumors, and 8 patients had high-grade gliomas. They observed a decrease or stabilization of the volume of the cyst in all patients with low-grade gliomas, with white matter edema in two cases. regarding the high-grade gliomas, in six patients the volume of the cyst decreased or stabilized, without major complications. In one patient, although the cyst had decreased, tumor progression compensated rapidly the clinical improvement due to inactivation of the cyst. The mean survival time in this last group was of five months.

Our results are similar to those reported in the literature. In the present study, it was not possible to define the isolated significance of SICI with ^{186}Re , considering that only one patient did not undergo additional therapy, and a multivariate analysis was not possible because of the small sample and the absence of mortality in the group with pilocytic astrocytomas.

It is important to point out that this technique it is indicated for the cystic portion of the tumor, although in two cases we have observed a decrease, and in one case, stabilization of the solid portion of the tumor. Stereotactic intracavitary irradiation can be repeated if no response is initially obtained, or even in the case of recurrence of the cyst, as we have performed successfully in two patients, as well as Pollack et al.¹³ The response of the intracavitary irradiation or the cystic shrinkage may take some months, and becomes stable after one year, and unfortunately cannot be previously preview.^{18,19}

The possible complications of this technique can be related to the stereotactic procedure itself (what is uncommon) or to the radioisotope injection, and they include intracerebral hematoma after cyst puncture,²¹ meningitis,^{18,19} and necrotic hemorrhage. All of these complications have been observed in the treatment of craniopharyngiomas using ^{90}Y . In the study by Berenger et al.,¹⁷ there was one death related to a leak in the treatment for craniopharyngioma using ^{86}Re .

Palsy of the third nerve was observed in one case in the present series. It was probably related to temporary damage

to the nerve caused by the radiation, as was also observed by other authors.⁵ Brain edema was observed in one patient, and it was probably related to unsatisfactory aspiration of the radioisotope after the irradiation because of technical difficulties.

Removal of the cyst must be considered, but this may be hazardous depending on its location. The cyst may be treated with aspiration alone, but it usually recollects. The subsequent blockage of the catheter is a potential problem, considering the protein content. In some cases, SICI may be considered as a primary therapy, although the best indication is for patients with persistent symptoms due to cystic lesions following surgery, radiotherapy or even radiosurgery, which keep reaccumulating despite repeated aspiration.

Young children under 5 years of age are not candidates for SICI; but, in specific situations, implantation of an intracavitary catheter followed by intermittent aspiration and subsequent and timely irradiation is not contraindicated.

An alternative approach to intracavitary irradiation is bleomycin, an antineoplastic agent, which has been proposed by several authors,^{22–24} with satisfactory results. However, the risk of a toxic effect from a leak may be more severe with bleomycin than with ^{186}Re .

Stereotactic intracavitary irradiation using the radioisotopes is an alternative therapeutic modality for cystic tumors, including craniopharyngiomas, gliomas, and even other tumors composed of a considerable cyst cavity. However, to date, this technique has not been used much, for different reasons, particularly because of the need to have a multidisciplinary team and special conditions to manipulate the radioisotopes, and specially because there are no studies with class-I level of evidence showing the real benefits of this kind of therapy, and the samples of the series in the literature are very limited.^{25–27}

Nowadays with the development of radiosurgery, SICI can play an important role in the treatment of mixed tumors with a cystic portion. Combined therapy, using radiosurgery for the solid portion, and intracavitary ^{186}Re for the cystic component, can be performed, as we did in one case, with an excellent result.^{28–30}

Conclusion

Stereotactic intracavitary irradiation with colloidal ^{186}Re seems to be a safe procedure, with satisfactory results in the present series, and it should be considered in patients with cystic craniopharyngiomas, alone or combined with other treatment modalities, considering clinical and tumoral features, aiming to provide the best outcomes to the patients.

Conflict of Interests

The authors have no conflict of interests to declare.

References

- Shahzadi S, Sharifi G, Andalibi R, Zali A, Ali-Asgari A. Management of cystic craniopharyngiomas with intracavitary irradiation with ^{32}P . *Arch Iran Med* 2008;11(01):30–34

- 2 Furtado AD, Panigrahy A, Fitz CR. Handbook of Clinical Neurology; Chapter 59 - CNS and spinal tumors. Joseph C, Masdeu RGG, editor; Elsevier; 2016
- 3 Enriquez-Marulanda A, Sierra-Ruiz M, Pabón LM, Lobato-Polo J. Intracavitary Irradiation as a Safe Alternative for Cystic Craniopharyngiomas: Case Report and Review of the Literature. *Case Rep Med* 2016; 5 pgs, 2016:3601395
- 4 Voges J, Sturm V, Lehrke R, Treuer H, Gauss C, Berthold F. Cystic craniopharyngioma: long-term results after intracavitary irradiation with stereotactically applied colloidal beta-emitting radioactive sources. *Neurosurgery* 1997;40(02):263–269, discussion 269–270
- 5 Kickingereeder P, Maarouf M, El Majdoub F, et al. Intracavitary brachytherapy using stereotactically applied phosphorus-32 colloid for treatment of cystic craniopharyngiomas in 53 patients. *J Neurooncol* 2012;109(02):365–374
- 6 Maarouf M, El Majdoub F, Fuetsch M, et al. Stereotactic intracavitary brachytherapy with P-32 for cystic craniopharyngiomas in children. *Strahlenther Onkol* 2016;192(03):157–165
- 7 Zhao R, Deng J, Liang X, Zeng J, Chen X, Wang J. Treatment of cystic craniopharyngioma with phosphorus-32 intracavitary irradiation. *Childs Nerv Syst* 2010;26(05):669–674
- 8 Leksell L, Liden K. A therapeutic trial with radioactive isotopes in cystic brain tumor. In: Establishment AER, editor. *Radioisotope Techniques: Medical and physiological applications*; H.M. Stationery Office. 1951
- 9 Backlund EO. Colloidal radioisotopes as part of a multi-modality treatment of craniopharyngiomas. *J Neurosurg Sci* 1989;33(01):95–97
- 10 Szikla G, Musolino A, Miyahara S, Schaub C, Askienazy S. Colloidal Rhenium-186 in endocavitary beta irradiation of cyst craniopharyngiomas and active glioma cysts. Long term results, side effects and clinical dosimetry. *Acta Neurochir (Wien)* 1984;33:1–339
- 11 Vanhauwaert D, Hallaert G, Baert E, Van Roost D, Okito JP, Caemaert J. Treatment of cystic craniopharyngioma by endocavitary instillation of yttrium⁹⁰ radioisotope—still a valuable treatment option. *J Neurol Surg A Cent Eur Neurosurg* 2013;74(05):307–312
- 12 Netzeband G, Sturm V, Georgi P, et al., Eds. *Results of Stereotactic Intracavitary Irradiation of Cystic Craniopharyngiomas. Comparison of the Effects of Yttrium-90 and Rhenium-186* 1984; Vienna: Springer Vienna
- 13 Pollack IF, Lunsford LD, Slamovits TL, Gumerman LW, Levine G, Robinson AG. Stereotactic intracavitary irradiation for cystic craniopharyngiomas. *J Neurosurg* 1988;68(02):227–233
- 14 Szeifert GT, Bálint K, Sipos L, Sarker MH, Czirják S, Julow J. Pathological findings in cystic craniopharyngiomas after stereotactic intracavitary irradiation with yttrium-90 isotope. *Prog Neurol Surg* 2007;20:297–302
- 15 Szeifert GT, Julow J, Slowik F, Bálint K, Lányi F, Pásztor E. Pathological changes in cystic craniopharyngiomas following intracavitary 90yttrium treatment. *Acta Neurochir (Wien)* 1990; 102(1-2):14–18
- 16 Szeifert GT, Julow J, Szabolcs M, Slowik F, Bálint K, Pásztor E. Secretory component of cystic craniopharyngiomas: a mucino-histochemical and electron-microscopic study. *Surg Neurol* 1991; 36(04):286–293
- 17 Berenger N, Lebtahi R, Piketty M, et al. Traitement endocavitaire par le rhénium 186 des kystes de crâniopharyngiomes. *Med Nucl (Paris)* 1993;•••:120–128
- 18 Julow J, Lányi F, Hajda M, et al. Treatment of cystic craniopharyngiomas with yttrium-90 colloid solution. *Neurosurg Focus* 1997;3(06):e6
- 19 Julow J, Lányi F, Hajda M, et al. Stereotactic intracavitary irradiation of cystic craniopharyngiomas with yttrium-90 isotope. *Prog Neurol Surg* 2007;20:289–296
- 20 Musolino A, Munari C, Blond S, et al. [Stereotactic treatment of expanding cysts in craniopharyngiomas by endocavitary beta-irradiation (Re-186; Au-198; Y-90)]. *Neurochirurgie* 1985;31 (03):169–178
- 21 Sturm V, Rommel T, Strauss L. Preliminary results of intracavitary irradiation of cystic craniopharyngioma by means of stereotactically applied 90 yttrium. *Adv Tech Stand Neurosurg* 1981; •••:401–404
- 22 Fahlbusch R, Honegger J, Paulus W, Huk W, Buchfelder M. Surgical treatment of craniopharyngiomas: experience with 168 patients. *J Neurosurg* 1999;90(02):237–250
- 23 Gildenberg PL, Woo SY. Multimodality program involving stereotactic surgery in brain tumor management. *Stereotact Funct Neurosurg* 2000;75(2-3):147–152
- 24 Hasegawa T, Kondziolka D, Hadjipanayis CG, Lunsford LD. Management of cystic craniopharyngiomas with phosphorus-32 intracavitary irradiation. *Neurosurgery* 2004;54(04):813–820, discussion 820–822
- 25 Karavitaki N, Brufani C, Warner JT, et al. Craniopharyngiomas in children and adults: systematic analysis of 121 cases with long-term follow-up. *Clin Endocrinol (Oxf)* 2005;62(04):397–409
- 26 Wen PY, Huse JT. 2016 World Health Organization Classification of Central Nervous System Tumors. *Continuum (Minneapolis)* 2017;23(6, Neuro-oncology):1531–1547
- 27 Kobayashi T, Kageyama N, Ohara K. Internal irradiation for cystic craniopharyngioma. *J Neurosurg* 1981;55(06):896–903
- 28 Nicolato A, Foroni R, Rosta L, Gerosa M, Bricolo A. Multimodality stereotactic approach to the treatment of cystic craniopharyngiomas. *Minim Invasive Neurosurg* 2004;47(01):32–40
- 29 Proust F, Coche-Dequeant B, Carpentier P, et al. [Combination treatment for pilocytic astrocytoma: stereotactic radiosurgery and endocavitary radiotherapy]. *Neurochirurgie* 1998;44(01):50–54
- 30 Van den Berge JH, Blaauw G, Breeman WA, Rahmy A, Wijngaarde R. Intracavitary brachytherapy of cystic craniopharyngiomas. *J Neurosurg* 1992;77(04):545–550