

# The Large Focal Isolated Chondral Lesion

Jorge Chahla, MD, PhD<sup>1</sup> Brady T. Williams, MD<sup>2</sup> Adam B. Yanke, MD, PhD<sup>1</sup> Jack Farr<sup>3</sup>

<sup>1</sup>Department of Orthopedic Surgery, Rush University Medical Center, Chicago, Illinois

<sup>2</sup>Department of Orthopedic Surgery, University of Colorado, Aurora, Colorado

<sup>3</sup>Knee Preservation and Cartilage Restoration Center, OrthoIndy, Indianapolis, Indiana

Address for correspondence Jorge Chahla, MD, PhD, Department of Orthopedic Surgery, Rush University Medical Center, 1611 W Harrison Street, Suite 300, Chicago Excelsior, IL 55331 (e-mail: jorge.chahla@rushortho.com).

J Knee Surg 2023;36:368–381.

## Abstract

Focal chondral defects (FCDs) of the knee can be a debilitating condition that can clinically translate into pain and dysfunction in young patients with high activity demands. Both the understanding of the etiology of FCDs and the surgical management of these chondral defects has exponentially grown in recent years. This is reflected by the number of surgical procedures performed for FCDs, which is now approximately 200,000 annually. This fact is also apparent in the wide variety of available surgical approaches to FCDs. Although simple arthroscopic debridement or microfracture are usually the first line of treatment for smaller lesions, chondral lesions that involve a larger area or depth require restorative procedures such as osteochondral allograft transplantation or other cell-based techniques. Given the prevalence of FCDs and the increased attention on treating these lesions, a comprehensive understanding of management from diagnosis to rehabilitation is imperative for the treating surgeon. This narrative review aims to describe current concepts in the treatment of large FCDs through providing an algorithmic approach to selecting interventions to address these lesions as well as the reported outcomes in the literature.

## Keywords

- ▶ cartilage
- ▶ focal chondral defect
- ▶ osteochondral
- ▶ knee
- ▶ regenerative

Treatment of large articular cartilage defects of the knee can be difficult, particularly in young athletic patients. Such lesions are common in young individuals (<40 years), with an overall incidence of 4.2 to 6.2%, and up to 36% in athletes.<sup>1–5</sup> In a series of nearly 1,000 arthroscopies, full-thickness cartilage defects meeting criteria for repair were found in 11% of knees, with 55% of lesions being greater than 2 cm<sup>2</sup>.<sup>2</sup> If left unaddressed, cartilage defects can worsen over time and may progress to diffuse degenerative changes.<sup>6</sup> Surgical management of larger FCDs has evolved over the last decade with the advent of improved biotechnology and surgical techniques to address FCDs with promising outcomes reported in the literature. In particular, there has been a shift toward reparative and regenerative procedures in an effort to restore cartilage, improve patient symptoms, and reduce morbidity.

Currently, several procedures are considered when treating large FCDs (>2.5 cm<sup>2</sup>) that have demonstrated favorable and reproducible outcomes.<sup>7–16</sup> Commonly employed procedures include osteochondral allograft transplantation (OCA), matrix-induced autologous chondrocyte implantation (MACI/ACI), minced cartilage procedures, cryopreserved osteochondral surface allografts, and augmented marrow stimulation in combination with extracellular matrix scaffolds. Given the array of treatment options, the challenge lies in determining which intervention or combination of interventions is most appropriate given patient- and defect-specific characteristics, while considering important comorbidities such as mechanical alignment, meniscal pathology, and ligamentous stability.

The purpose of this narrative review is to describe current concepts in the treatment of large FCDs, providing an

received

December 27, 2019

accepted after revision

June 25, 2020

article published online

September 10, 2021

© 2021. Thieme. All rights reserved.  
Thieme Medical Publishers, Inc.,  
333 Seventh Avenue, 18th Floor,  
New York, NY 10001, USA

DOI <https://doi.org/10.1055/s-0041-1735278>.  
ISSN 1538-8506.

algorithmic approach to selecting interventions to address these lesions along with reviewing the reported outcomes in the literature. In addition, both conservative and surgical approaches to the treatment of these defects are described, as well as recommended postoperative rehabilitation.

## Diagnosis

Given the progressive nature of these lesions, successful treatment of FCDs is predicated on diagnosis early in the disease process to provide a window of opportunity for intervention. Early diagnosis can allow for more treatment options to restore articular surfaces, contact pressures, and kinematics. In addition to the timing of the diagnosis, it is equally important to establish an etiology to prevent progression and recurrence insofar as it is able to be addressed (e.g., weight loss, repairable meniscal tears, ligament injury, and malalignment). Missed or delayed diagnoses can potentially have significant consequences on patient function and quality of life, as symptoms continue to progress, possibly contributing to downstream osteoarthritis (OA).<sup>17,18</sup> To ensure accurate and timely diagnosis, clinicians must perform a comprehensive assessment including a thorough history and physical exam, radiographs, and magnetic resonance imaging (MRI) when indicated.

## Patient History

Evaluation of a patient with knee pain begins with a thorough patient history including a detailed characterization of the pain and associated symptoms, historic and present activity level, prior injuries, and any previous treatments. Pain and swelling are the most common presenting symptoms in patients with FCDs. Details of the pain, including onset, location, and associated symptoms can lend insight into the underlying diagnosis. For example, gradual onset is more commonly seen in conditions such as osteochondritis dissecans, while sudden onset pain is more commonly seen in acute injury and trauma. Although it should be noted that an acute traumatic event may not be the cause of the FCD, but rather the provocative event that uncovered a previously asymptomatic FCD.

Intuitively, the location of the pain and the corresponding position of the knee helps identify the site of injury. Pain is often localized to the affected compartment with joint loading, which is distinct from the diffuse pain secondary to progressive osteoarthritis and synovitis. For patients with patellofemoral FCDs, pain is typically anterior, but can also include retro- and peripatellar pain, and even popliteal-area pain in the case of trochlear defects. Since the cartilage itself lacks innervation, it is thought that the pain is a summation of inputs from a variety of sources, including synovial inflammation and overloading of the subchondral bone.<sup>19</sup>

In addition to current activity limitations, history should include a detailed account of a patient's prior activities. Participation in athletics and injuries should be elicited, given that sport is a common inciting and exacerbating activity.<sup>1,2,20</sup> A systematic review of the literature reported a prevalence of full-thickness chondral defects in more than

one-third of athletes identified.<sup>1</sup> In addition to providing clues to the mechanism and location of injury, prior activities may also help identify patient-specific goals of treatment. Lastly, it is important to know what has been done before including prior injections, surgeries, and physical therapy.

## Physical Exam

Patients with FCDs often do not have specific physical exam findings. Regardless, a systematic approach should be taken to ensure thorough assessment including inspection and palpation, range of motion, ligamentous stability, alignment, including gait and patellar tracking, and manual or instrumented strength assessment.<sup>21</sup> Inspection and palpation may reveal varying degrees of swelling, joint effusions, and joint line tenderness, which may often be more pronounced over the lesion itself. Ligamentous stability of the knee is important to assess as ligament injury or gross laxity may be contributing to altered kinematics and cartilage loading. Similarly, mechanical alignment, gait analysis, rotational deformity, and muscular imbalance can also provide valuable information with respect to cartilage loading and potential lesion locations. Gait patterns can provide additional clues as to the location of lesions, including intoeing and abductor weakness in patellofemoral FCDs.

## Imaging

Although physical exam findings can be suggestive of FCDs, imaging is required to determine the location and severity of these lesions. Imaging begins with weight-bearing plain radiographs to evaluate alignment and degenerative changes. Most commonly, views include standing full length anteroposterior films from the hip to the ankle, lateral and patellofemoral sunrise views of the knee, anteroposterior projections in full extension, and posteroanterior views in flexion.<sup>22</sup> Lesions are not best visualized on X-ray, although some lesions, such as a larger osteochondritis dissecans (OCD) lesions, are often visible on plain films. However, plain films provide additional valuable information regarding degenerative changes and mechanical alignment that may require surgical correction.<sup>23</sup> Properly calibrated radiographs can also be used for preoperative planning of meniscal transplants to ensure correct size-matching of allografts.<sup>24</sup>

Magnetic resonance imaging is useful for the evaluation of articular cartilage and subchondral bone. However, clinicians should be aware that MRI findings can be misleading, both underestimating the size of the lesion and often failing to correlate with clinical symptoms.<sup>25,26</sup> To more completely evaluate the articular cartilage, additional MR imaging techniques have been developed. These techniques include T2 mapping and delayed gadolinium-enhanced MRI of cartilage (dGEMRIC). Both techniques are useful in assessing specific biochemical properties of cartilage with biomechanical implications. T2 mapping provides quantitative data that can be used to measure collagen content, which may provide applications for postoperative evaluation for both quantity and quality of defect filling.<sup>27-29</sup> In contrast, dGEMRIC is used to measure glycosaminoglycan content, which can be used to assess compressive stiffness of cartilage.<sup>27,30-32</sup>

**Role of Arthroscopy**

Although patient history, physical exam, and imaging can be supportive of the diagnosis, arthroscopy remains the gold standard for diagnosing the size and depth of FCDs. During arthroscopy, the depth can be reported by using one of several cartilage grading scales, the most common being the International Cartilage Repair Society (ICRS) and Outerbridge Criteria. In addition to being diagnostic, arthroscopy can be therapeutic, allowing for simultaneous debridement of unstable lesions and treatment of other intra-articular pathology, such as meniscal tears, that may also contribute to the symptomatology.

**Treatment**

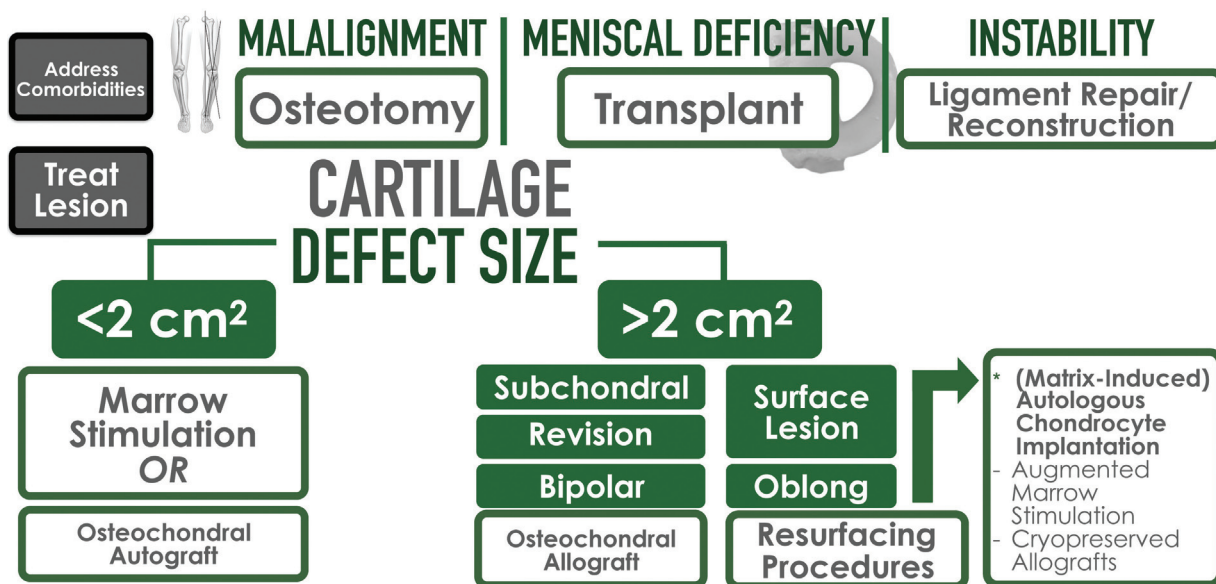
**Conservative Management**

Debate exists surrounding the role of conservative and symptomatic management of FCDs given the possible progressive nature of such lesions. Patients may report symptomatic relief from a variety of medications and injections including nonsteroidal anti-inflammatory drugs, over the counter supplements (glucosamine and chondroitin), intra-articular injections (corticosteroids and hyaluronic acid), and biologics (platelet rich plasma and bone marrow aspirate concentrate). Activity modification, weight loss, strengthening and physical therapy, and bracing may also improve symptoms. The long-term implications of conservative management are still largely unknown given that the rapidity of progression is unclear. Several studies have looked at the treatment of OCD lesions and the impact of fragment removal, effectively creating a focal cartilage defect. Following removal, Shelbourne et al demonstrated good function and outcomes at midterm follow-up. However, joint space nar-

rowing and symptoms were not reliably predicted based on factors such as defect size.<sup>33</sup> Other case series following debridement and fragment removal have demonstrated a range of outcomes, including inconsistencies between patient reported function and evidence of progression. For example, Murry et al reported on long-term outcomes on a series of 32 knees, in which the overall mean American Knee Society Score (179) was indicative of good clinical function. Yet, radiographic evidence of early degenerative joint disease was present in more than 70% of patients at long-term follow-up (>11 years).<sup>34</sup> It was noted that smaller lesions, stable (fragment preserved), and medial condyle lesions had better prognoses.

Review of the FCD literature reveals similar trends of progression. A recent systematic review of patients with untreated FCDs reported that patients were more likely to experience progression of cartilage damage; however, radiographic evidence of OA was not uniformly evident within 2 years of follow-up.<sup>18</sup> Beyond 2 years, limited data exist. Messner and Maletius reported on long-term outcomes (14-year follow-up) on a small series of athletes with radiographic confirmation of isolated chondral lesions. Despite the majority (78.6%) of patients reporting good knee function, more than half of the patients demonstrated radiographic progression, with 42.9% demonstrating a reduction in joint space.<sup>35</sup> This is in line with a growing body of evidence supporting surgical intervention of symptomatic FCDs to prevent progression of both symptoms and cartilage degeneration, with the goal of delaying or preventing the need for subsequent arthroplasty procedures.<sup>33,35-37</sup> However, limited and conflicting data exist regarding the development or progression of radiographic evidence of osteoarthritis following cartilage procedures.<sup>38-45</sup>

**FOCAL CHONDRAL DEFECT ALGORITHM**



**Fig. 1** Treatment algorithm outlining concurrent pathology and lesion specific characteristics and their impact on surgical decision-making and treatment options for focal chondral defects.

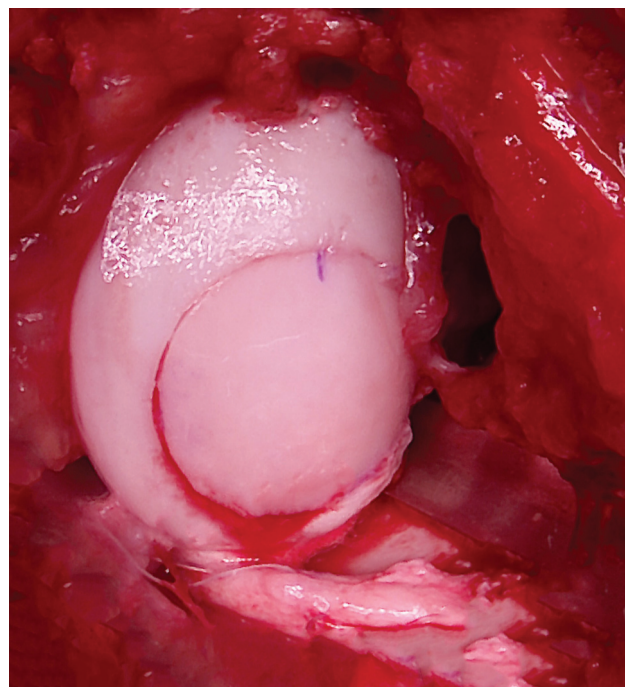
## Surgical Treatment

The goal of surgical treatment of FCDs is anatomic restoration of the joint surface and subchondral bone, to recreate normal biomechanical loading and contact pressures across the joint. The surgical intervention is determined based on the size, depth, location of the lesion, and other patient factors (→Fig. 1). However, when deciding on a surgical intervention, the constellation of concurrent knee pathology specific to each patient must factor into the treatment algorithm. This includes malalignment, concomitant meniscal pathology, and ligamentous injury, all of which can be addressed simultaneously in single stage procedures. In the case of meniscal pathology, studies to date confirm that cartilage procedures, such as osteochondral allograft transplantation and autologous chondrocyte implantation, can be performed in combination with meniscus allograft transplantation, with reliable results comparable to isolated cartilage procedures.<sup>46–49</sup> Similarly, mechanical axis malalignment can be addressed with the appropriately indicated osteotomy to correct joint loading profiles and contact pressures.<sup>50</sup> The importance of concurrently correcting alignment has been demonstrated both by improved outcomes in patients who were treated with single stage proximal tibial osteotomy (PTO) and cartilage procedures, and inferior outcomes in patients where malalignment was not addressed.<sup>51,52</sup> Similarly, patellar FCDs with evidence of maltracking can also be simultaneously corrected with anteromedializing transfer of the tibial tuberosity.<sup>53,54</sup> Lastly, any ligamentous pathology or laxity must be considered and corrected to restore knee kinematics and optimize the survivorship of any cartilage procedure. Perhaps the most well-documented example of this is the interplay of anterior cruciate ligament (ACL) reconstruction and cartilage procedures. Wang et al compared ACL-reconstructed and ACL-intact patients following OCA procedures, reporting no significant differences at 2 years.<sup>55</sup> Following comprehensive consideration and plans for correction of these contributing factors, attention can then be turned to the FCD lesion itself.

A range of treatment options exist for FCDs that are dictated based on lesion specific factors including size, depth, and location, in addition to patient characteristics such as age, activity level, symptomatology, compliance, and patient preference. In the context of large FCDs (>2.5 cm<sup>2</sup>), many of the options that exist for smaller lesions (<2 cm<sup>2</sup>), such as debridement, abrasion arthroplasty, microfracture, and subchondral drilling, are not viable options. Larger lesions are more appropriately treated with osteochondral allograft transplantation (OCA), matrix-induced autologous chondrocyte implantation (MACI/ACI), minced cartilage procedures, cryopreserved osteochondral surface allografts, and augmented marrow stimulation with extracellular matrix scaffolds.

## Osteochondral Allograft

Osteochondral allografting is a widely used technique for treatment of a variety of chondral defects of the femoral condyles, trochlea, or patella either as primary treatment or as a revision procedure for prior cartilage surgeries. Given

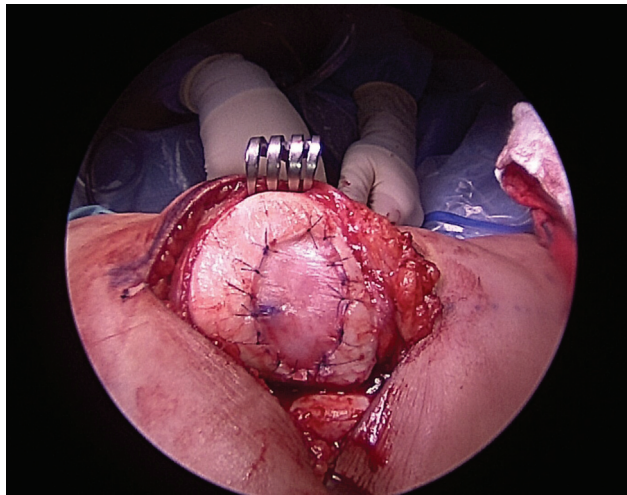


**Fig. 2** Photograph of a press-fit osteochondral allograft for a large focal chondral defect of the medial femoral condyle of a left knee. Press-fit osteochondral allografts eliminate the need for additional fixation such as headless screws.

that the allograft source eliminates issues of donor site morbidity, OCAs are useful in the treatment of large FCDs. Furthermore, OCAs can also accommodate lesions with subchondral involvement or bone loss that may exist in revision cases from prior cartilage procedures or OCDs. Surgical techniques for OCA fall into three categories, cylindrical press-fit plugs, oblong press-fit plugs, or free-shell grafts, and are largely dictated by the size and location of the lesion. Plugs are typically obtained and cut from hemicondylar allografts; however, in cases of smaller lesions, fresh precut OCA cores may also be used.<sup>56</sup> The technical aspects of these procedures have been well documented and described in the literature. The press-fit technique is preferred when possible and eliminates the need for additional fixation such as headless screws, or pins (→Fig. 2). The press-fit approach can also be implemented in a snowman or oblong configuration to adequately cover larger lesions. Instances in which the press-fit technique cannot be implemented include posterior lesions where the joint surface cannot be easily accessed perpendicularly, or lesions of the tibial plateau. In the free-shell technique, a donor graft is matched to the defect site and fixed with screws. Lesions of the plateau can also be addressed through grafting of a size-matched tibial plateau.<sup>57</sup>

## Autologous Chondrocyte/Matrix-Associated Autologous Chondrocyte Implantation

Autologous chondrocyte implantation (ACI) is a two-stage procedure in which chondrocytes are harvested from the knee, typically from the femoral notch or another nonprimary weight-bearing surface, followed by enzymatic



**Fig. 3** Medial view of a left knee demonstrating the final product of an autologous chondrocyte implantation repair of a large focal chondral defect of the patella.

processing, culture, and finally, reintroduction at the site of the defect. The chondrocytes are contained within the defect by using a periosteal or collagen membrane patch (→Fig. 3). Matrix-associated autologous chondrocyte implantation (MACI) represents an evolution of this technique utilizing a porcine collagen membrane scaffold in attempts to apply autologous chondrocytes more evenly, reduce extrusion, and eliminate the need for a patch.<sup>58–60</sup> It is also postulated that the scaffold may also act as barrier to fibroblast mediated repair.<sup>61</sup>

Surgical techniques combining the use of ACI/MACI with bone grafting have also been described for patients with large, deep lesions affecting the subchondral bone.<sup>62</sup> In such cases, subchondral defects can be filled with cancellous bone or bicortical bone graft followed by subsequent autologous chondrocyte implantation. Zellner et al reported on a series of patients treated with this approach in which the mean total size of the defects was 6.7 cm<sup>2</sup> (range = 3–14 cm<sup>2</sup>), with a mean depth of 12 mm.<sup>62</sup> Such techniques have been proposed to circumvent the need for osteochondral allografts, which may have limited availability and potentially carry additional infectious disease transmission risk.

### Minced Cartilage

The use of minced cartilage dates back to 1983 when it was initially described by Albrecht et al,<sup>63</sup> demonstrating improved healing of osteochondral defects compared with fibrin. In current practice, minced cartilage procedures commonly utilize allograft articular cartilage from juvenile donors due to chondrocyte density and proliferative capacity (DeNovo Natural Tissue).<sup>64,65</sup> Intraoperatively, the minced cartilage can be prepared within the defect or using a mold on the back table. The 1-mm<sup>3</sup> cartilage particles are subsequently inserted into the defect, ensuring they are seated beneath the rim of the defect, followed by sealing with a fibrin glue. The knee is taken through a range of motion to assess stability and ensure the graft site does not sit proud that would result in increased loading and stress. Similar

techniques have been described with autograft cartilage (Cartilage Autograft Implantation System, CAIS, Depuy/Mitek, Raynham, MA) in which articular cartilage is harvested intraoperatively from a minimally load-bearing surface, such as the notch or peripheral trochlea.<sup>66</sup> The harvested cartilage is then minced and secured to a scaffold with a fibrin sealant. The construct can then be trimmed and transferred into the defect, cartilage-side down, and affixed with biodegradable staple anchors.

### Cryopreserved Osteochondral Allografts

Cryopreserved osteochondral surface allografts are composed of human hyaline articular cartilage and have similar indications to those previously described for ACI/MACI in which there is an isolated and contained lesion with minimal subchondral bone loss.<sup>67</sup> The graft itself serves as a scaffold composed of extracellular matrix in combination with chondrogenic growth factors, proteins, and viable chondrocytes. Some of the currently available products include ProChondrix CR (Allosource, Centennial, CO) and Cartiform (Arthrex Inc., Naples, FL). These grafts have a shelf life of approximately 2 years and can be easily cut to fit the defect and fixed with varying combinations of fibrin glue, sutures, or suture anchors. These products offer additional advantages relative to ACI/MACI in that they can be used in a single stage procedure. These techniques can also be used in conjunction with other marrow stimulation techniques such as microfracture.

### Augmented Marrow Stimulation

Other extracellular matrix-based techniques have been described, including BioCartilage (Arthrex Inc., Naples, FL) and Chondro-Gide (Geistlich Pharma AG). The BioCartilage extracellular matrix is developed from cartilage allograft and is comprised of type II collagen, proteoglycans, and other cartilaginous growth factors intended to serve as a scaffold when performed in conjunction with marrow stimulation techniques such as microfracture. Purported advantages include the opportunity for single stage procedures without risk of immunogenicity that can occur from other allograft sources. Chondro-Gide is a membrane composed of collagen I/III and is used in combination with microfracture, in a technique described as autologous matrix-induced chondrogenesis (AMIC).

### Rehabilitation

Rehabilitation following surgical treatment of large FCDs is dictated both by the location of the lesion and the procedure performed, with patellofemoral lesions prioritizing weight bearing and protected range of motion and vice versa for tibiofemoral lesions. Additional factors that impact the patient specific postoperative rehabilitation program include body mass index (BMI), preoperative activity level/sport, repair technique, defect location, and concomitant procedures.<sup>68</sup> In general, patients progress through graduated use of a continuous passive motion (CPM) machine 6 to 8 hours/day for the first 4 to 6 weeks, with

incremental increases toward full weight-bearing at 6 to 12 weeks.<sup>69,70</sup>

## Clinical Outcomes

### Osteochondral Allograft Transplantation

Outcomes following OCA have been reported for a range of patient ages, BMI, activity levels, sport participation, and concomitant injuries demonstrating good to excellent outcomes and high rates of return to sport.<sup>8,9,55,71–78</sup> Outcomes data have also highlighted benefits in the form of durability of symptom relief and graft survivorship (► **Table 1**). A large database study of 1,608 OCA procedures reported a 12.2% reoperation rate within 2 years.<sup>11</sup> Similarly, within the literature, survivorship of patellofemoral OCA procedures has been reported to be 87.9% at 5 years and 77.2% at 10 years.<sup>12</sup> Longer term follow-up of smaller samples (58 patients) have demonstrated reported rates of survivorship beyond 20 years, with 91, 84, 69, and 59% survivorship reported at 10, 15, 20, and 25 years, respectively.<sup>79</sup> As previously mentioned, functional improvements translate to high rates of return to sport. A recent systematic review by Crawford et al reported rates of return to sport of 75 to 82% from a pooled sample of 772 patients with average defect sizes ranging from 2.4 to 9.6 cm<sup>2</sup>.<sup>10</sup>

Importantly, OCA has also been routinely employed as a salvage procedure for prior failed cartilage procedures. Merkely et al performed a matched-group analysis of primary OCA versus OCA revision after failed ACI, demonstrating no significant differences in patient reported outcomes, reoperation, or failure rates at final follow-up, concluding that OCA performs similarly as a revision procedure as it does for the primary treatment of large cartilage defects.<sup>80</sup> However, it should be noted that equivalent outcomes have not been observed for larger defects requiring snowman grafting. In a small patient series, reoperation and failure rates of snowman grafting have been reported to be as high as 44 and 33% respectively at 7.7 ± 5.5 years, with all failed patients converting to arthroplasty procedures.<sup>81</sup> Although patients did report improvement in clinical outcomes, failure and reoperations rates for overlapping grafts are higher than those for isolated lesions. Similarly, other patient and allograft characteristics may also increase the risk of failure including higher BMI (>35), patient activity, allografts stored >28 days, and other baseline comorbidities at the time of surgery.<sup>82</sup>

### Autologous Chondrocyte Implantation and Matrix-Associated Autologous Chondrocyte Implantation

In general, autologous chondrocyte implantation procedures provide significant short- and long-term patient benefits in a variety of patient populations from children and adolescents to middle-age adults.<sup>13,14,83,84</sup> McNickle et al reported on a series of 140 knees, with a mean single defect size of 4.1 ± 2.3 cm<sup>2</sup> (total average defect(s) area 5.2 ± 3.5 cm<sup>2</sup>).<sup>85</sup> In the short term, patients reported high rates of satisfaction (75%), with 83% of patients stating that they would have the procedure again, and only 5% reporting being dissatisfied

with the outcome.<sup>85</sup> Significant improvements were reported for all outcome scales, including Lysholm, International Knee Documentation Committee (IKDC), Knee injury and Osteoarthritis Outcome Score (KOOS) scale, and 12 item short form survey (SF-12). Of note, 15% of patients required a subsequent reoperation to debride the site of ACI, and 6.4% were deemed clinical failures, with increasing age and workers' compensation being predictive of inferior outcomes. Beris et al reported similar rates of improvement, with reoperation and clinical failure rates of 11.1 and 4.4%, respectively.<sup>86</sup> Ebert et al demonstrated comparable results at 2 years following MACI for tibiofemoral and patellofemoral lesions, with concurrent correction of patellar maltracking when indicated.<sup>87</sup> Success has also been demonstrated in treatment of deeper lesions involving the subchondral bone. Zellner et al reported on patients with large and deep lesions (6.7 cm<sup>2</sup>, range = 3–14 cm<sup>2</sup>, mean depth of 12 mm) treated with combined subchondral bone augmentation, also demonstrating good short-term outcomes with significant improvements in IKDC and Cincinnati scores at 3 years, with MRI evidence of subchondral regeneration.<sup>62</sup>

Mid- to long-term follow-up has demonstrated sustained improvements in pain and function. Multiple studies have corroborated rates of survivorship ranging from 74 to 78% at 5 years and 50 to 74% at 10 to 12 years.<sup>15,16</sup> Nawaz et al noted that failure rates were significantly higher (hazard ratio = 4.72) in patients in which ACI/MACI was not their first cartilage procedure.<sup>15</sup> Other factors impacting survivorship of the graft included severity and site of repair, with higher grade lesions, and those located on the patella or medial femoral condyle demonstrating higher rates of failure. Interestingly, size of the lesion did not impact rates of failure, with a reported mean defect size of 409 mm<sup>2</sup> (range = 44–2,075 mm<sup>2</sup>).<sup>15</sup> Moradi et al reported on 7- to 14-year outcomes following first generation ACI treatment of lesions with a mean size of 4.3 ± 2 cm<sup>2</sup> (range = 2.5–11.25 cm<sup>2</sup>), noting significant improvement in all outcomes measures, with younger patients, smaller defects, and shorter duration of preoperative symptoms predicting superior outcomes.<sup>88</sup>

Investigations of complication rates demonstrate that ACI/MACI is not only efficacious, but a reproducibly safe 2-stage procedure. Complication rates following ACI/MACI are less than 1%, and are more commonly associated with earlier generation ACI, including graft hypertrophy, insufficient regeneration or fusion with surrounding cartilage, or repair delamination.<sup>14,89,90</sup>

### Minced Cartilage

Limited data exist regarding the use of minced cartilage for the treatment of large osteochondral defects. Farr et al reported on the results of a small patient series (25 patients), demonstrating symptomatic improvement as early as 3 months and MRI findings demonstrative of good defect filling at 24 months postoperatively following DeNovo NT.<sup>91,92</sup> Wang et al also reported on the use of DeNovo NT in patellofemoral lesions with a mean follow-up of 3.84 years, demonstrating improvements in IKDC and Knee Outcome Survey-Activities of Daily Living (KOS-ADL), with 69.2%

**Table 1** Clinical outcomes following surgical treatment of large focal chondral defects

Study (year)	Treatment	Age (mean, y)	Patients (knees)	Duration of follow-up	Outcomes/Conclusion
Osteochondral allograft transplantation					
Thomas et al (2019) <sup>8</sup>	OCA (MFC, LFC, P, Tr)	31.7	61	46.2 mo	VAS pain improved from $4.10 \pm 2.17$ to $2.68 \pm 2.73$ (9.8%) required revision chondral procedures 39 (63.9%) returned to military duties
Balazs et al (2018) <sup>72</sup>	OCA (MFC, LFC, P, Tr)	22.8	11	Min. 1 y	80% returned to play at prior level of play (NBA or collegiate) Median time-to-return was 14 mo (range = 6–26)
Cotter et al (2018) <sup>81</sup>	OCA (MFC, LFC, P, Tr)	31.9	22	Snowman: 7.4 y Multifocal: 6.4 y	Unicondylar snowman OCA grafts had 44.4% reoperation rate, and 33.3% failure rate (mean = $7.7 \pm 5.5$ y) Multifocal OCA grafts had 20% reoperation rates and 6.7% failure ( $n = 1$ ) at 4.5 y
Frank et al (2018) <sup>76</sup>	OCA (MFC, LFC, P, Tr)	<40 y (27.6) >40 y (44.9)	170	5.0 y	No differences in reoperation rate, time-to-reoperation, or failure rates between patients <40 and >40 y at the time of surgery Patients >40 y had higher KOOS symptom subscores at final follow-up
Frank et al (2018) <sup>74</sup>	OCA (MFC, LFC) ± MAT	31.7	100	4.9 y	No difference in reoperation rates, time-to-reoperation, failure rates, of PRO scores with concurrent MAT Failure rate of 14% in both groups
Tirico et al (2018) <sup>73</sup>	OCA (MFC, LFC, P, Tr, TP) ± ACL	35.0 34.8	31 OCA + ACL 62 OCA	6.2 y	No difference in clinical failure rates (9.7%) or reoperation rates (33.5%) 5- and 10-y survivorship were 94.7 and 82.3% for the OCA + ACL group and 93.4 and 79.6% for the OCA group, respectively
Wang et al (2018) <sup>75</sup>	OCA (MFC, LFC, P, Tr)	48	51 (52)	3.6 y	21 knees (40%) required reoperation, 14 (27%) deemed clinical failures at a mean of 33 mo 2- and 4-y survivorship rates were 88 and 73%, respectively
Wang et al (2018) <sup>77</sup>	OCA (MFC, LFC, Tr)	35.4	31	4.1 y	In patients with BMI >30 (mean = $32.9 \text{ kg/m}^2$ ), 2- and 5-y graft survivorship were 87 and 83%, respectively
McCarthy et al (2017) <sup>9</sup>	OCA (MFC, LFC)	19.2	13 (14)	5.9 y	7 returned to sport at $7.9 \pm 3.5$ mo, 5 of which returned to preinjury level of play Improvements were noted in all PROs except KOOS-Sport, WOMAC-Stiffness, and SF-12 mental subscales
Nielsen et al (2017) <sup>71</sup>	OCA (MFC, LFC, P, Tr, TP)	31.2	142 (149)	6 y	75.2% of knees returned to sport or recreational activity 25.5% underwent additional surgery, 9.4% deemed allo-graft failures

**Table 1** (Continued)

Study (year)	Treatment	Age (mean, y)	Patients (knees)	Duration of follow-up	Outcomes/Conclusion
Nuelle et al (2017) <sup>82</sup>	OCA (MFC, LFC)	34.2	75	19.5 mo	Success defined as VAS improvement of 2 pts (or 0 overall) Preoperative activity level, BMI <35, and graft storage <28 d were associated with greater rates of success
Wang et al (2017) <sup>55</sup>	OCA (MFC, LFC, P, Tr) ± ACL	36.2	75	3.9 y	Survivorship of OCA was 90 and 96% at 2 y and 79 and 85% at 5 y in ACL-intact and ACL-reconstructed patients, respectively
Raz et al (2014) <sup>79</sup>	OCA (MFC, LFC)	63	28	21.8 y	13/58 failed at a mean of 11 y Survivorship of 91% at 10 y, 84% at 15 y, 69% at 20 y, and 59% predicted at 25 y
Krych et al (2012) <sup>78</sup>	OCA (MFC, LFC, Tr)	43	32.9	2.5 y	Return to sport was possible in 88%, with full return to preinjury level in 79%, with average time-to-return of 9.6 ± 3.0 mo Age ≥25 y and duration of symptoms >12 mo negatively impacted return to play
<b>Autologous chondrocyte and matrix-associated autologous chondrocyte implantation</b>					
Ebert et al (2017) <sup>87</sup>	MACI (MFC, LFC, P, Tr)	37.8	194	Min. 2 y	MACI for the treatment of PFJ defects with concurrent correction of maltracking results in comparable clinical and radiological outcomes compared with femoral condyle defects At 24 mo, the overall MRI composite score was classified as good/excellent in 98 TF patients (77%) and 54 PF patients (81%)
Niethammer et al (2017) <sup>83</sup>	MACI (MFC, LFC, P)	<20 y (16) Adult (36.7)	<20 y (40) Adult (40)	Min. 3 y	Children and adolescents had superior IKDC and VAS pain scores at all postoperative time points compared with adults
Zellner et al (2017) <sup>62</sup>	MACI + bone grafting (MFC, LFC, P, Tr)	28.2	46	2 y	Significant improvements in IKDC and Cincinnati scores at follow-up Subchondral bone regeneration and integration of bone grafts MOCA score of 82.6 at 1 y without a deterioration at the later follow-up time point Revision required in 4 patients (8.7%)
Biant et al (2014) <sup>16</sup>	ACI (MFC, LFC, P, Tr)	30.2	104	10.4 y	26% failed at a mean 5.7 y Of grafts that did not fail, results were excellent (63%), good (25%), fair (8%), and poor (4%)
Nawaz et al (2014) <sup>15</sup>	ACI versus MACI (MFC, LFC, P, Tr)	34	827	6.2 y	Overall graft survival rates were 78.2% at 5 y and 50.7% at 10 y, with no significant differences between ACI and MACI 5 times greater failure in patients with prior regenerative procedure compared with untreated lesions

(Continued)



Table 1 (Continued)

Study (year)	Treatment	Age (mean, y)	Patients (knees)	Duration of follow-up	Outcomes/Conclusion
Zak et al (2014) <sup>13</sup>	MACI (MFC, LFC, Tr, P)	30.8	28	Min. 2 y	Significant improvements in all PROs at 2 y, except KOOS-symptoms subscale At 2 y, mean MOCART scores was 73.2 ± 12.4 and 3D MOCART score was 73.4 ± 9.7
Beris et al (2012) <sup>86</sup>	ACI (MFC, LFC, Tr)	28.9	42 (45)	96 mo	Significant improvements in all PROs at final follow-up 5 patients underwent reoperation, 2 deemed failures due to graft degeneration or detachment
Moradi et al (2012) <sup>88</sup>	ACI (MFC, LFC)	30.5	23	9.9 y	Significant improvement in all clinical outcome parameters Deterioration between intermediate and final follow-up Younger patients, smaller defect, and shorter duration of symptoms had greater benefit 52.3% of patients had complete filling of defect on final follow-up MRI
McNickle et al (2009) <sup>85</sup>	ACI (MFC, LFC, P, Tr)	30.3	137 (140)	4.3 y	Significant improvement in all PROs 75% completely/mostly satisfied 16% required debridement, 6.4% were clinical failures Age and WC are predictors of postoperative Lysholm's score
Niemeyer et al (2008) <sup>90</sup>	ACI and MACI (MFC, LFC, P, Tr)	35.2	309	4.5 y	Primary complications include symptomatic hypertrophy, disturbed fusion, delamination, and graft failure Complication rate and hypertrophy were higher for periosteum-cover ACI and for patellar defects
Rosenberger et al (2008) <sup>84</sup>	ACI (MFC, LFC, P, Tr, TP)	48.6	56	4.7 y	72% reported good/excellent outcomes 8 (14%) failed and 24 (43%) required additional arthroscopic procedures
Minced cartilage					
Wang et al (2018) <sup>93</sup>	Juvenile allograft (DeNovo NT) (P, Tr)	29.9	27	3.84 y	IKDC and KOS-ADL scores continued to improve until 2 y postoperatively with no significant improvement in VAS 69.2% of lesions demonstrated at least 67% defect-filling
Farr et al (2014) <sup>92</sup>	Juvenile allograft (DeNovo NT) (MFC, LFC, Tr)	37	25	Min. 2 y	Significant improvement in IKDC and KOOS subscales at 2 y with significant improvements as early as 3 mo MRI demonstrated good defect filling with improving T2-weighted scores at 2 y (increasing percentage approximating levels of normal articular cartilage)
Cole et al (2011) <sup>66</sup>	Autograft (CAIS) vs. microfracture (FC, Tr)	33.3 vs 32.7	29	Min. 2 y	Significantly greater improvements in IKDC and various KOOS subscales at 12 mo in CAIS group. Significant differences were maintained at 24 mo.

Table 1 (Continued)

Study (year)	Treatment	Age (mean, y)	Patients (knees)	Duration of follow-up	Outcomes/Conclusion
Cryopreserved osteochondral allografts					
Melugin et al (2020) <sup>95</sup>	Cryopreserved allograft (Cartiform) (P, Tr)	31	19	3.5 y	Significant improvements in VR-12, IKDC, KOOS, and Tegner's scores (minimum 2 y) 21.1% reoperation rate, 12.5% conversion rate to patellofemoral arthroplasty
Vangness et al (2018) <sup>94</sup>	Cryopreserved allograft (Cartiform) (MFC, TP)	20, 28, 52	3	Min. 2 y	3 patients (2 MFC, 1 TP) demonstrating symptomatic improvement, return to activities, and MRI findings indicative of good defect filling
Augmented marrow stimulation					
De Girolamo et al (2019) <sup>102</sup>	AMIC vs. AMIC + BMAC (MFC, LFC, PFJ)	30	24	100 mo	Both AMIC and AMIC + BMAC demonstrated comparable improvements in pain and function lasting as long as 9 y AMIC + BMAC treated group had higher Lysholm's and lower VAS scores at 12 mo
Fossum et al (2019) <sup>104</sup>	AMIC vs. ACI-C (MFC, LFC, P, Tr)	38.3 vs. 37.2	41	2 y	Significant improvements in clinical outcomes (KOOS, Lysholm, VAS) with no significant differences between groups 2 patients in AMIC treated group progressed to arthroplasty
Bertho et al (2018) <sup>100</sup>	AMIC (MFC, LFC, P)	29	13	2 y	Significant improvements in IKDC and KOOS 2 patients with poor outcomes, 1 had multiple prior procedures, the other was 51 y old with 6.9 cm <sup>2</sup> defect area
Schiavone et al (2018) <sup>101</sup>	AMIC (MFC, LFC, P, Tr)	39	21	7 y	Significant improvements in IKDC and Lysholm's scores at final follow-up 76.2% satisfied or extremely satisfied, 66.6% showed good quality repair tissue on MRI
Volz et al (2017) <sup>103</sup>	AMIC vs. microfracture (MFC, LFC, P, Tr)	37	47	5 y	Significant improvements in modified Cincinnati and modified ICRS pain at 2 y for both groups. AMIC treated patients had significantly higher mean modified Cincinnati's scores at 5 y AMIC treated patients had greater proportion of patients with >2/3 defect filling at 2 and 5 y

Abbreviations: ACI, autologous chondrocyte implantation; ACI-C, autologous chondrocyte implantation with collagen patch; ACL, anterior cruciate ligament; AMIC, autologous matrix-induced chondrogenesis; BMAC, bone marrow aspirate concentrate; BMI, body mass index; FC, femoral condyle; ICRS, international cartilage repair society; IKDC, international Knee Documentation Committee score; KOOS, knee injury and osteoarthritis outcome score; KOS-ADL, knee outcome survey - activities of daily living; LFC, lateral femoral condyle; MAT, meniscal allograft transplantation; MFC, medial femoral condyle; MOCART, Magnetic resonance observation of cartilage repair tissue; MRI, magnetic resonance imaging; NBA, national basketball association; P, patella; PF, patellofemoral joint; PRO(s), patient reported outcome (s); SF-12, 12 item short-form survey; TF, tibiofemoral; Tr, tibial plateau; Tr, trochlea; VAS, visual analog scale for pain; VR-12, Veterans RAND 12 Item Health Survey; WC, workers' compensation; WOMAC, Western Ontario and McMaster Universities Osteoarthritis Index.

of lesions demonstrating filling greater than two-thirds.<sup>93</sup> Using autologous cartilage harvest intraoperatively, Cole et al reported on 2-year outcomes after CAIS in a series of 29 patients randomized to either CAIS or microfracture, demonstrating significantly higher IKDC scores beginning at 12 months in the CAIS group compared with microfracture.<sup>66</sup> Other significant differences were also noted in various KOOS subscales (symptoms and stiffness, pain, activities of daily living, and sports and recreation) at 12 months, and knee-related quality of life at 18 months. All of these differences were maintained at 24 months.

### Cryopreserved Osteochondral Allografts

Given the relative novelty of the technology compared with other surgical techniques, clinical outcomes following implantation of cryopreserved osteochondral allografts are currently limited. Vangsnæs et al reported on three patients treated with Cartiform (Osiris Therapeutics, Inc., Columbia, MD), including two treated for lesions of the medial femoral condyle and one treated for a lesion of the tibial plateau, demonstrating symptomatic improvement, return to activities, and MRI findings indicative of good defect filling out to 2 years postoperatively.<sup>94</sup> Melugin et al reported on a series of 19 patients with patellofemoral defects treated with Cartiform (Osiris Therapeutics, Inc., Columbia, MD). Patients demonstrated significant improvements in VR-12, IKDC, KOOS, and Tegner's scores at a minimum of 24 months follow-up. However, there was a 21.1% reoperation rate and 12.5% conversion rate to patellofemoral arthroplasty.<sup>95</sup>

### Augmented Marrow Stimulation

Outcomes after surgery with extracellular matrix scaffolds are largely limited to animal models and case series. Several techniques are described in the literature of combined Bio-Cartilage and microfracture techniques; however, outcome data are limited.<sup>96–98</sup> Other techniques, such as AMIC utilizing the Chondro-Gide collagen membrane have more clinical outcomes data, demonstrating significant improvements in clinical and functional outcomes based on systematic review.<sup>99</sup> Bertho et al reported on preliminary results in 13 patients with a mean defect area of 3.7 cm<sup>2</sup> treated with AMIC. At a minimum of 1-year follow-up, patients reported significant improvements in IKDC and KOOS scores.<sup>100</sup> Schiavone Panni et al reported on a series of 21 patients treated with AMIC for full thickness lesions >2 cm<sup>2</sup>, demonstrating significant improvements in Lysholm and IKDC with an average of 7 years of follow-up. The same study also reported 76.2% patient satisfaction rates with 66.6% of patient demonstrating reduced defect size and subchondral edema on MRI.<sup>101</sup> Another study performed by de Girolamo et al with a similar length of follow-up suggested that bone marrow aspirate concentrate (BMAC) may help augment functional improvements and pain relief in the short term (12 months).<sup>102</sup> Autologous matrix-induced chondrogenesis has also been compared with other treatments in multiple randomized trials. Volz et al compared AMIC to microfracture in a series of 47 patients with a mean defect size of 3.6 ± 1.6 cm<sup>2</sup>.<sup>103</sup> At 2 years, all groups demonstrated signifi-

cant improvements in modified Cincinnati score and modified ICRS score for pain. At 5 years, improvements were still noted for all groups; however, AMIC-treated subjects had significantly higher Modified Cincinnati scores. On 2- and 5-year MRI, AMIC-treated groups also had a greater proportion of subjects with >2/3 defect filling. In another randomized trial, Fossum et al compared 2-year outcomes in 41 patients treated with either AMIC or ACI covered with a collagen patch with mean total defect sizes of 5.2 ± 2.4 and 4.9 ± 4.4 cm<sup>2</sup>, respectively.<sup>104</sup> At 2-year follow-up, both groups demonstrated significant improvements in clinical scores (KOOS, Lysholm, and VAS pain) with no significant differences between groups with respect to the magnitude of improvement; however, two patients in the AMIC group progressed to arthroplasty by 2-year follow-up.

### Conclusion

Focal chondral defects (FCDs) of the knee with accompanying pain and dysfunction can be debilitating conditions affecting young active patients. Optimal outcomes are dependent on complete integration of clinical care from a timely and accurate diagnosis to selection of a patient- and defect-specific surgical intervention, through postoperative rehabilitation and return to activities. For lesions that involve a larger chondral area, a variety of well-established complex restorative procedures exist such as OCA and ACI/MACI, in addition to other emerging resurfacing technologies. Outcomes data have demonstrated reproducible results including long-term relief of symptoms and return to activities. Given the array of treatment options, the challenge lies in determining which intervention or combination of interventions is most appropriate, given patient- and defect-specific characteristics, while considering important comorbidities such as mechanical alignment, meniscal pathology, and ligamentous status.

### Funding

None.

### Conflict of Interest

J.C. is a board or committee member of the American Orthopaedic Society for Sports Medicine (AOSSM), Arthroscopy Association of North America (AANA), and the International Society of Arthroscopy, Knee Surgery, and Orthopaedic Sports Medicine (ISAKOS); and is a paid consultant for Arthrex, Inc, CONMED Linvatec, Ossur, and Smith & Nephew. A.B.Y. receives research support from Arthrex, Inc, Organogenesis, and Vericel; is an unpaid consultant for Patient IQ, Smith & Nephew, and Sparta Biomedical; is a paid consultant for CONMED Linvatec, JRF Ortho, and Olympus; and receives stock or stock options from Patient IQ. J.F. receives research support from Active Implants, Arthrex, Inc, Episurf, Fidia, JRF Ortho, Moximed, Novartis, Organogenesis, Samumed, Inc, Vericel, and ZimmerBiomet; is a paid consultant for Aesculap/B.Braun, CartiHeal, Cook Biotech, Exactech, Moximed, Inc, Organogenesis, Regentis, Samumed, Inc,

and ZKR orthopedics; is on the editorial or governing board of the American Journal of Orthopedics, and Cartilage; is a paid presenter or speaker for Arthrex, Inc, Moximed, Inc, Organogenesis, and Vericeal; receives IP royalties from Arthrex, Inc, Biopoly, LLC, and Organogenesis; receives stock or stock options from MedShape, Inc, and Ortho Regenerative Tech; and receives publishing royalties, financial or material support from Springer, and Thieme Medical Publishers, Inc.

## References

- Flanigan DC, Harris JD, Trinh TQ, Siston RA, Brophy RH. Prevalence of chondral defects in athletes' knees: a systematic review. *Med Sci Sports Exerc* 2010;42(10):1795–1801
- Arøen A, Løken S, Heir S, et al. Articular cartilage lesions in 993 consecutive knee arthroscopies. *Am J Sports Med* 2004;32(01):211–215
- Curl WW, Krome J, Gordon ES, Rushing J, Smith BP, Poehling GG. Cartilage injuries: a review of 31,516 knee arthroscopies. *Arthroscopy* 1997;13(04):456–460
- Hjelle K, Solheim E, Strand T, Muri R, Brittberg M. Articular cartilage defects in 1,000 knee arthroscopies. *Arthroscopy* 2002;18(07):730–734
- Zamber RW, Teitz CC, McGuire DA, Frost JD, Hermanson BK. Articular cartilage lesions of the knee. *Arthroscopy* 1989;5(04):258–268
- Davies-Tuck ML, Wluka AE, Wang Y, et al. The natural history of cartilage defects in people with knee osteoarthritis. *Osteoarthritis Cartilage* 2008;16(03):337–342
- Behery O, Siston RA, Harris JD, Flanigan DC. Treatment of cartilage defects of the knee: expanding on the existing algorithm. *Clin J Sport Med* 2014;24(01):21–30
- Thomas D, Shaw KA, Waterman BR. Outcomes after fresh osteochondral allograft transplantation for medium to large chondral defects of the knee. *Orthop J Sports Med* 2019;7(03):2325967119832299
- McCarthy MA, Meyer MA, Weber AE, et al. Can competitive athletes return to high-level play after osteochondral allograft transplantation of the knee? *Arthroscopy* 2017;33(09):1712–1717
- Crawford ZT, Schumaier AP, Glogovac G, Grawe BM. Return to sport and sports-specific outcomes after osteochondral allograft transplantation in the knee: a systematic review of studies with at least 2 years' mean follow-up. *Arthroscopy* 2019;35(06):1880–1889
- Frank RM, McCormick F, Rosas S, et al. Reoperation rates after cartilage restoration procedures in the knee: analysis of a large US commercial database. *Am J Orthop* 2018;47(06). Doi: 10.12788/ajo.2018.0040
- Chahla J, Sweet MC, Okoroha KR, et al. Osteochondral allograft transplantation in the patellofemoral joint: a systematic review. *Am J Sports Med* 2018;363546518814236
- Zak L, Albrecht C, Wondrasch B, et al. Results 2 years after matrix-associated autologous chondrocyte transplantation using the novocart 3D scaffold: an analysis of clinical and radiological data. *Am J Sports Med* 2014;42(07):1618–1627
- Harris JD, Siston RA, Pan X, Flanigan DC. Autologous chondrocyte implantation: a systematic review. *J Bone Joint Surg Am* 2010;92(12):2220–2233
- Nawaz SZ, Bentley G, Briggs TW, et al. Autologous chondrocyte implantation in the knee: mid-term to long-term results. *J Bone Joint Surg Am* 2014;96(10):824–830
- Biant LC, Bentley G, Vijayan S, Skinner JA, Carrington RW. Long-term results of autologous chondrocyte implantation in the knee for chronic chondral and osteochondral defects. *Am J Sports Med* 2014;42(09):2178–2183
- Widuchowski W, Widuchowski J, Faltus R, et al. Long-term clinical and radiological assessment of untreated severe cartilage damage in the knee: a natural history study. *Scand J Med Sci Sports* 2011;21(01):106–110
- Houck DA, Kraeutler MJ, Belk JW, Frank RM, McCarty EC, Bravman JT. Do focal chondral defects of the knee increase the risk for progression to osteoarthritis? A review of the literature. *Orthop J Sports Med* 2018;6(10):2325967118801931
- Dye SF. The pathophysiology of patellofemoral pain: a tissue homeostasis perspective. *Clin Orthop Relat Res* 2005;(436):100–110
- Gomoll AH, Minas T, Farr J, Cole BJ. Treatment of chondral defects in the patellofemoral joint. *J Knee Surg* 2006;19(04):285–295
- Mall NA, Harris JD, Cole BJ. Clinical evaluation and preoperative planning of articular cartilage lesions of the knee. *J Am Acad Orthop Surg* 2015;23(10):633–640
- Rosenberg TD, Paulos LE, Parker RD, Coward DB, Scott SM. The forty-five-degree posteroanterior flexion weight-bearing radiograph of the knee. *J Bone Joint Surg Am* 1988;70(10):1479–1483
- Godin JA, Hussain ZB, Sanchez A, et al. Multicompartmental osteochondral allografts of knee and concomitant high tibial osteotomy. *Arthrosc Tech* 2017;6(05):e1959–e1965
- Samitier G, Alentorn-Geli E, Taylor DC, et al. Meniscal allograft transplantation. Part 1: systematic review of graft biology, graft shrinkage, graft extrusion, graft sizing, and graft fixation. *Knee Surg Sports Traumatol Arthrosc* 2015;23(01):310–322
- Gomoll AH, Yoshioka H, Watanabe A, Dunn JC, Minas T. Preoperative measurement of cartilage defects by MRI underestimates lesion size. *Cartilage* 2011;2(04):389–393
- O'Connor MA, Palaniappan M, Khan N, Bruce CE. Osteochondritis dissecans of the knee in children: a comparison of MRI and arthroscopic findings. *J Bone Joint Surg Br* 2002;84(02):258–262
- Gillis A, Bashir A, McKeon B, Scheller A, Gray ML, Burstein D. Magnetic resonance imaging of relative glycosaminoglycan distribution in patients with autologous chondrocyte transplants. *Invest Radiol* 2001;36(12):743–748
- Potter HG, Foo LF. Magnetic resonance imaging of articular cartilage: trauma, degeneration, and repair. *Am J Sports Med* 2006;34(04):661–677
- Stelzener D, Shetty AA, Kim SJ, et al. Repair tissue quality after arthroscopic autologous collagen-induced chondrogenesis (ACIC) assessed via T2\* mapping. *Skeletal Radiol* 2013;42(12):1657–1664
- Tiderius CJ, Tjörnstrand J, Akeson P, Södersten K, Dahlberg L, Leander P. Delayed gadolinium-enhanced MRI of cartilage (dGEMRIC): intra- and interobserver variability in standardized drawing of regions of interest. *Acta Radiol* 2004;45(06):628–634
- Young AA, Stanwell P, Williams A, et al. Glycosaminoglycan content of knee cartilage following posterior cruciate ligament rupture demonstrated by delayed gadolinium-enhanced magnetic resonance imaging of cartilage (dGEMRIC): a case report. *J Bone Joint Surg Am* 2005;87(12):2763–2767
- Kurkijärvi JE, Nissi MJ, Kiviranta I, Jurvelin JS, Nieminen MT. Delayed gadolinium-enhanced MRI of cartilage (dGEMRIC) and T2 characteristics of human knee articular cartilage: topographical variation and relationships to mechanical properties. *Magn Reson Med* 2004;52(01):41–46
- Shelbourne KD, Jari S, Gray T. Outcome of untreated traumatic articular cartilage defects of the knee: a natural history study. *J Bone Joint Surg Am* 2003;85-A(Suppl 2):8–16
- Murray JR, Chitnavis J, Dixon P, et al. Osteochondritis dissecans of the knee; long-term clinical outcome following arthroscopic debridement. *Knee* 2007;14(02):94–98
- Messner K, Maletius W. The long-term prognosis for severe damage to weight-bearing cartilage in the knee: a 14-year clinical and radiographic follow-up in 28 young athletes. *Acta Orthop Scand* 1996;67(02):165–168

- 36 Henn RF III, Gomoll AH. A review of the evaluation and management of cartilage defects in the knee. *Phys Sportsmed* 2011;39(01):101–107
- 37 Everhart JS, Abouljoud MM, Kirven JC, Flanigan DC. Full-thickness cartilage defects are important independent predictive factors for progression to total knee arthroplasty in older adults with minimal to moderate osteoarthritis: data from the osteoarthritis initiative. *J Bone Joint Surg Am* 2019;101(01):56–63
- 38 Ogura T, Merkely G, Bryant T, Winalski CS, Minas T. Autologous chondrocyte implantation “segmental-sandwich” technique for deep osteochondral defects in the knee: clinical outcomes and correlation with magnetic resonance imaging findings. *Orthop J Sports Med* 2019;7(05):2325967119847173
- 39 Ferruzzi A, Buda R, Cavallo M, Timoncini A, Natali S, Giannini S. Cartilage repair procedures associated with high tibial osteotomy in varus knees: clinical results at 11 years’ follow-up. *Knee* 2014;21(02):445–450
- 40 Knutsen G, Drogset JO, Engebretsen L, et al. A randomized trial comparing autologous chondrocyte implantation with microfracture. Findings at five years. *J Bone Joint Surg Am* 2007;89(10):2105–2112
- 41 Knutsen G, Drogset JO, Engebretsen L, et al. A randomized multicenter trial comparing autologous chondrocyte implantation with microfracture: long-term follow-up at 14 to 15 years. *J Bone Joint Surg Am* 2016;98(16):1332–1339
- 42 Ekman E, Mäkelä K, Kohonen I, Hiltunen A, Itälä A Favourable long-term functional and radiographical outcome after osteoautograft transplantation surgery of the knee: a minimum 10-year follow-up. *Knee Surg Sports Traumatol Arthrosc* 2018;26(12):3560–3565
- 43 Gudas R, Kalesinskas RJ, Kimtys V, et al. A prospective randomized clinical study of mosaic osteochondral autologous transplantation versus microfracture for the treatment of osteochondral defects in the knee joint in young athletes. *Arthroscopy* 2005;21(09):1066–1075
- 44 Gudas R, Gudaite A, Pocius A, et al. Ten-year follow-up of a prospective, randomized clinical study of mosaic osteochondral autologous transplantation versus microfracture for the treatment of osteochondral defects in the knee joint of athletes. *Am J Sports Med* 2012;40(11):2499–2508
- 45 Ulstein S, Årøen A, Røtterud JH, Løken S, Engebretsen L, Heir S. Microfracture technique versus osteochondral autologous transplantation mosaicplasty in patients with articular chondral lesions of the knee: a prospective randomized trial with long-term follow-up. *Knee Surg Sports Traumatol Arthrosc* 2014;22(06):1207–1215
- 46 Rue JP, Yanke AB, Busam ML, McNickle AG, Cole BJ. Prospective evaluation of concurrent meniscus transplantation and articular cartilage repair: minimum 2-year follow-up. *Am J Sports Med* 2008;36(09):1770–1778
- 47 Frank RM, Cole BJ. Meniscus transplantation. *Curr Rev Musculoskelet Med* 2015;8(04):443–450
- 48 Abrams GD, Hussey KE, Harris JD, Cole BJ. Clinical results of combined meniscus and femoral osteochondral allograft transplantation: minimum 2-year follow-up. *Arthroscopy* 2014;30(08):964–70.e1
- 49 Farr J, Rawal A, Marberry KM. Concomitant meniscal allograft transplantation and autologous chondrocyte implantation: minimum 2-year follow-up. *Am J Sports Med* 2007;35(09):1459–1466
- 50 Marti RK, Verhagen RA, Kerkhoffs GM, Moojen TM. Proximal tibial varus osteotomy. Indications, technique, and five to twenty-one-year results. *J Bone Joint Surg Am* 2001;83(02):164–170
- 51 Bode G, Schmal H, Pestka JM, Ogon P, Südkamp NP, Niemeyer P. A non-randomized controlled clinical trial on autologous chondrocyte implantation (ACI) in cartilage defects of the medial femoral condyle with or without high tibial osteotomy in patients with varus deformity of less than 5°. *Arch Orthop Trauma Surg* 2013;133(01):43–49
- 52 Kahlenberg CA, Nwachukwu BU, Hamid KS, Steinhaus ME, Williams RJ III. Analysis of outcomes for high tibial osteotomies performed with cartilage restoration techniques. *Arthroscopy* 2017;33(02):486–492
- 53 Farr J. Autologous chondrocyte implantation improves patellofemoral cartilage treatment outcomes. *Clin Orthop Relat Res* 2007;463(463):187–194
- 54 Cotter EJ, Waterman BR, Kelly MP, Wang KC, Frank RM, Cole BJ. Multiple osteochondral allograft transplantation with concomitant tibial tubercle osteotomy for multifocal chondral disease of the knee. *Arthrosc Tech* 2017;6(04):e1393–e1398
- 55 Wang D, Eliasberg CD, Wang T, et al. Similar outcomes after osteochondral allograft transplantation in anterior cruciate ligament-intact and -reconstructed knees: a comparative matched-group analysis with minimum 2-year follow-up. *Arthroscopy* 2017;33(12):2198–2207
- 56 Jones KJ, Mosich GM, Williams RJ. Fresh precut osteochondral allograft core transplantation for the treatment of femoral cartilage defects. *Arthrosc Tech* 2018;7(08):e791–e795
- 57 Godin JA, Frangiamore S, Chahla J, Cinque ME, DePhillipo NN, LaPrade RF. Tibial allograft transfer for medial tibial plateau resurfacing. *Arthrosc Tech* 2017;6(03):e661–e665
- 58 Bartlett W, Skinner JA, Gooding CR, et al. Autologous chondrocyte implantation versus matrix-induced autologous chondrocyte implantation for osteochondral defects of the knee: a prospective, randomised study. *J Bone Joint Surg Br* 2005;87(05):640–645
- 59 Sohn DH, Lottman LM, Lum LY, et al. Effect of gravity on localization of chondrocytes implanted in cartilage defects. *Clin Orthop Relat Res* 2002;(394):254–262
- 60 Gikas PD, Bayliss L, Bentley G, Briggs TW. An overview of autologous chondrocyte implantation. *J Bone Joint Surg Br* 2009;91(08):997–1006
- 61 Frenkel SR, Toolan B, Menche D, Pitman MI, Pachence JM. Chondrocyte transplantation using a collagen bilayer matrix for cartilage repair. *J Bone Joint Surg Br* 1997;79(05):831–836
- 62 Zellner J, Grechenig S, Pfeifer CG, et al. Clinical and radiological regeneration of large and deep osteochondral defects of the knee by bone augmentation combined with matrix-guided autologous chondrocyte transplantation. *Am J Sports Med* 2017;45(13):3069–3080
- 63 Albrecht F, Roessner A, Zimmermann E. Closure of osteochondral lesions using chondral fragments and fibrin adhesive. *Arch Orthop Trauma Surg* 1983;101(03):213–217
- 64 Bonasia DE, Martin JA, Marmotti A, et al. Cocultures of adult and juvenile chondrocytes compared with adult and juvenile chondral fragments: in vitro matrix production. *Am J Sports Med* 2011;39(11):2355–2361
- 65 McCormick F, Yanke A, Provencher MT, Cole BJ. Minced articular cartilage—basic science, surgical technique, and clinical application. *Sports Med Arthrosc Rev* 2008;16(04):217–220
- 66 Cole BJ, Farr J, Winalski CS, et al. Outcomes after a single-stage procedure for cell-based cartilage repair: a prospective clinical safety trial with 2-year follow-up. *Am J Sports Med* 2011;39(06):1170–1179
- 67 Woodmass JM, Melugin HP, Wu IT, Saris DBF, Stuart MJ, Krych AJ. Viable osteochondral allograft for the treatment of a full-thickness cartilage defect of the patella. *Arthrosc Tech* 2017;6(05):e1661–e1665
- 68 Mithoefer K, Hambly K, Logerstedt D, Ricci M, Silvers H, Della Villa S. Current concepts for rehabilitation and return to sport after knee articular cartilage repair in the athlete. *J Orthop Sports Phys Ther* 2012;42(03):254–273
- 69 Seo S-S, Kim C-W, Jung D-W. Management of focal chondral lesion in the knee joint. *Knee Surg Relat Res* 2011;23(04):185–196
- 70 Jones DG, Peterson L. Autologous chondrocyte implantation. *Instr Course Lect* 2007;56:429–445

- 71 Nielsen ES, McCauley JC, Pulido PA, Bugbee WD. Return to sport and recreational activity after osteochondral allograft transplantation in the knee. *Am J Sports Med* 2017;45(07):1608–1614
- 72 Balazs GC, Wang D, Burge AJ, Sinatro AL, Wong AC, Williams RJ III. Return to play among elite basketball players after osteochondral allograft transplantation of full-thickness cartilage lesions. *Orthop J Sports Med* 2018;6(07):2325967118786941
- 73 Tirico LEP, McCauley JC, Pulido PA, Bugbee WD. Does anterior cruciate ligament reconstruction affect the outcome of osteochondral allograft transplantation?: a matched cohort study with a mean follow-up of 6 years *Am J Sports Med* 2018;46(08):1836–1843
- 74 Frank RM, Lee S, Cotter EJ, Hannon CP, Leroux T, Cole BJ. Outcomes of osteochondral allograft transplantation with and without concomitant meniscus allograft transplantation: a comparative matched group analysis. *Am J Sports Med* 2018;46(03):573–580
- 75 Wang D, Kalia V, Eliasberg CD, et al. Osteochondral allograft transplantation of the knee in patients aged 40 years and older. *Am J Sports Med* 2018;46(03):581–589
- 76 Frank RM, Cotter EJ, Lee S, Poland S, Cole BJ. Do outcomes of osteochondral allograft transplantation differ based on age and sex?: a comparative matched group analysis *Am J Sports Med* 2018;46(01):181–191
- 77 Wang D, Rebolledo BJ, Dare DM, et al. Osteochondral allograft transplantation of the knee in patients with an elevated body mass index. *Cartilage* 2018;1947603518754630
- 78 Krych AJ, Robertson CM, Williams RJ III Cartilage Study Group. Return to athletic activity after osteochondral allograft transplantation in the knee. *Am J Sports Med* 2012;40(05):1053–1059
- 79 Raz G, Safir OA, Backstein DJ, Lee PT, Gross AE. Distal femoral fresh osteochondral allografts: follow-up at a mean of twenty-two years. *J Bone Joint Surg Am* 2014;96(13):1101–1107
- 80 Merkely G, Ogura T, Ackermann J, Barbieri Mestriner A, Gomoll AH. Clinical outcomes after revision of autologous chondrocyte implantation to osteochondral allograft transplantation for large chondral defects: a comparative matched-group analysis. *Cartilage* 2019;1947603519833136
- 81 Cotter EJ, Hannon CP, Christian DR, et al. Clinical outcomes of multifocal osteochondral allograft transplantation of the knee: an analysis of overlapping grafts and multifocal lesions. *Am J Sports Med* 2018;46(12):2884–2893
- 82 Nuelle CW, Nuelle JA, Cook JL, Stannard JP. Patient factors, donor age, and graft storage duration affect osteochondral allograft outcomes in knees with or without comorbidities. *J Knee Surg* 2017;30(02):179–184
- 83 Niethammer TR, Holzgruber M, Gülecüyüz MF, Weber P, Pietschmann MF, Müller PE. Matrix based autologous chondrocyte implantation in children and adolescents: a match paired analysis in a follow-up over three years post-operation. *Int Orthop* 2017;41(02):343–350
- 84 Rosenberger RE, Gomoll AH, Bryant T, Minas T. Repair of large chondral defects of the knee with autologous chondrocyte implantation in patients 45 years or older. *Am J Sports Med* 2008;36(12):2336–2344
- 85 McNickle AG, L'Heureux DR, Yanke AB, Cole BJ. Outcomes of autologous chondrocyte implantation in a diverse patient population. *Am J Sports Med* 2009;37(07):1344–1350
- 86 Beris AE, Lykissas MG, Kostas-Agnantis I, Manoudis GN. Treatment of full-thickness chondral defects of the knee with autologous chondrocyte implantation: a functional evaluation with long-term follow-up. *Am J Sports Med* 2012;40(03):562–567
- 87 Ebert JR, Schneider A, Fallon M, Wood DJ, Janes GC. A comparison of 2-year outcomes in patients undergoing tibiofemoral or patellofemoral matrix-induced autologous chondrocyte implantation. *Am J Sports Med* 2017;45(14):3243–3253
- 88 Moradi B, Schönit E, Nierhoff C, et al. First-generation autologous chondrocyte implantation in patients with cartilage defects of the knee: 7 to 14 years' clinical and magnetic resonance imaging follow-up evaluation. *Arthroscopy* 2012;28(12):1851–1861
- 89 Gowd AK, Cvetanovich GL, Liu JN, et al. Management of chondral lesions of the knee: analysis of trends and short-term complications using the national surgical quality improvement program database. *Arthroscopy* 2019;35(01):138–146
- 90 Niemeier P, Pestka JM, Kreuz PC, et al. Characteristic complications after autologous chondrocyte implantation for cartilage defects of the knee joint. *Am J Sports Med* 2008;36(11):2091–2099
- 91 Farr J, Cole BJ, Sherman S, Karas V. Particulated articular cartilage: CAIS and DeNovo NT. *J Knee Surg* 2012;25(01):23–29
- 92 Farr J, Tabet SK, Margerrison E, Cole BJ. Clinical, radiographic, and histological outcomes after cartilage repair with particulated juvenile articular cartilage: a 2-year prospective study. *Am J Sports Med* 2014;42(06):1417–1425
- 93 Wang T, Belkin NS, Burge AJ, et al. Patellofemoral cartilage lesions treated with particulated juvenile allograft cartilage: a prospective study with minimum 2-year clinical and magnetic resonance imaging outcomes. *Arthroscopy* 2018;34(05):1498–1505
- 94 Vangsness CT Jr, Higgs G, Hoffman JK, et al. Implantation of a novel cryopreserved viable osteochondral allograft for articular cartilage repair in the knee. *J Knee Surg* 2018;31(06):528–535
- 95 Melugin HP, Ridley TJ, Bernard CD, et al. Prospective outcomes of cryopreserved osteochondral allograft for patellofemoral cartilage defects at minimum 2-year follow-up. *Cartilage* 2020;1947603520903420
- 96 Carter AH, Guttierrez N, Subhawong TK, et al. MR imaging of BioCartilage augmented microfracture surgery utilizing 2D MOCART and KOOS scores. *J Clin Orthop Trauma* 2018;9(02):146–152
- 97 Wang KC, Frank RM, Cotter EJ, Christian DR, Cole BJ. Arthroscopic management of isolated tibial plateau defect with microfracture and micronized allogeneic cartilage-platelet-rich plasma adjunct. *Arthrosc Tech* 2017;6(05):e1613–e1618
- 98 Schallmo MS, Marquez-Lara A, Luo TD, Rosas S, Stubbs AJ. Arthroscopic treatment of hip chondral defect with microfracture and platelet-rich plasma-infused micronized cartilage allograft augmentation. *Arthrosc Tech* 2018;7(04):e361–e365
- 99 Steinwachs MR, Gille J, Volz M, et al. Systematic review and meta-analysis of the clinical evidence on the use of autologous matrix-induced chondrogenesis in the knee. *Cartilage* 2019;1947603519870846
- 100 Bertho P, Pauvert A, Poudroux T, Robert H Orthopaedics and Traumatology Society of Western France (SOO) Treatment of large deep osteochondritis lesions of the knee by autologous matrix-induced chondrogenesis (AMIC): Preliminary results in 13 patients. *Orthop Traumatol Surg Res* 2018;104(05):695–700
- 101 Schiavone Panni A, Del Regno C, Mazzitelli G, D'Apolito R, Corona K, Vasso M. Good clinical results with autologous matrix-induced chondrogenesis (Amic) technique in large knee chondral defects. *Knee Surg Sports Traumatol Arthrosc* 2018;26(04):1130–1136
- 102 de Girolamo L, Schönhuber H, Viganò M, et al. Autologous matrix-induced chondrogenesis (AMIC) and AMIC enhanced by autologous concentrated bone marrow aspirate (BMAC) allow for stable clinical and functional improvements at up to 9 years follow-up: results from a randomized controlled study. *J Clin Med* 2019;8(03):E392
- 103 Volz M, Schaumburger J, Frick H, Grifka J, Anders S. A randomized controlled trial demonstrating sustained benefit of autologous matrix-induced chondrogenesis over microfracture at five years. *Int Orthop* 2017;41(04):797–804
- 104 Fossum V, Hansen AK, Wilsgaard T, Knutsen G. Collagen-covered autologous chondrocyte implantation versus autologous matrix-induced chondrogenesis: a randomized trial comparing 2 methods for repair of cartilage defects of the knee. *Orthop J Sports Med* 2019;7(09):2325967119868212