



# External Delta Fixator in the Postoperative Management of Microsurgical Flaps in the Lower Limb: Experience of a Tertiary Hospital\*

## *Fixador externo tipo delta no manejo pós-operatório de retalhos microcirúrgicos no membro inferior: Experiência de um hospital terciário*

Bruno Moraes Vasconcelos<sup>1</sup> Mario Matiotti Neto<sup>1</sup> Luis Guilherme Rosifini Alves Rezende<sup>2</sup>  
Amanda Favaro Cagnolati<sup>2</sup> Alex Eduardo Calderón Irusta<sup>2</sup> Nilton Mazzer<sup>3</sup>

<sup>1</sup> Hand Surgery Program of the Department of Orthopedics, Hospital das Clínicas, Faculdade de Medicina de Ribeirão Preto, Universidade de São Paulo, (HC-FMRP-USP), Ribeirão Preto, SP, Brazil

<sup>2</sup> Hand Division of the Department of Orthopedics of the Hospital das Clínicas da Faculdade de Medicina de Ribeirão Preto da Universidade de São Paulo (HC-FMRP-USP), Ribeirão Preto, SP, Brazil

<sup>3</sup> Full Professor and Head of the Hand Division of the Department of Orthopedics of the Hospital das Clínicas da Faculdade de Medicina de Ribeirão Preto da Universidade de São Paulo (HC-FMRP-USP), Ribeirão Preto, SP, Brazil

**Address for correspondence** Luis Guilherme Rosifini Alves Rezende, MD, Hospital das Clínicas, Faculdade de Medicina de Ribeirão Preto, Universidade de São Paulo, Av. Bandeirantes, 3.900-Vila Monte Alegre, Ribeirão Preto, SP, 14049-900, Brazil (e-mail: lgrezende@usp.br).

Rev Bras Ortop 2022;57(1):69–74.

### Abstract

**Objective** To evaluate the use of external fixators in the delta-type kickstand configuration as an adjuvant method in the postoperative period of patients submitted to free flaps in the lower limbs.

**Methods** A total of 17 external delta fixators were used in patients submitted to free flaps in the lower limbs. The surgical technique was performed in a standardized manner, with the distal pin located 6 cm proximally to the anastomosis, and the proximal pin, 6 cm distally to the anterior tuberosity of the tibia.

**Results** The mean age of the sample was of 34.76 years (range: 15 to 66 years). In total, 11 men and 6 women were selected. The posterior tibial artery was used in 14 cases, and the anterior tibial artery, in 3 cases. The mean time of use of the external fixators was of 3.88 weeks. The rate of reoperation was of 17.64%; that of retail loss was of 11.76%; that of success rate was of 88.23%; and the rate of infection was of 5.9%.

### Keywords

- ▶ myocutaneous flap
- ▶ perforator flap
- ▶ microsurgery
- ▶ fractures, bone

\* Study carried out at Hospital das Clínicas, Faculdade de Medicina de Ribeirão Preto, Universidade de São Paulo, Ribeirão Preto, SP, Brazil.

received  
December 29, 2020  
accepted  
April 7, 2021  
published online  
October 25, 2021

DOI <https://doi.org/10.1055/s-0041-1735832>.  
ISSN 0102-3616.

© 2021. Sociedade Brasileira de Ortopedia e Traumatologia. All rights reserved.

This is an open access article published by Thieme under the terms of the Creative Commons Attribution-NonDerivative-NonCommercial-License, permitting copying and reproduction so long as the original work is given appropriate credit. Contents may not be used for commercial purposes, or adapted, remixed, transformed or built upon. (<https://creativecommons.org/licenses/by-nc-nd/4.0/>)

Thieme Revinter Publicações Ltda., Rua do Matoso 170, Rio de Janeiro, RJ, CEP 20270-135, Brazil

## Resumo

### Palavras-chave

- ▶ retalho miocutâneo
- ▶ retalho perfurante
- ▶ microcirurgia
- ▶ fraturas ósseas

**Conclusion** The use of delta-type fixators as an adjunct method in the postoperative period is reliable; however, more studies are needed to evaluate its true role in the postoperative period.

**Objetivo** Avaliar o uso de fixadores externos, na configuração *kickstand* do tipo delta, como método adjuvante no período pós-operatório de pacientes submetidos a retalhos livres nos membros inferiores.

**Métodos** Ao todo, 17 fixadores externos do tipo delta foram utilizados em pacientes submetidos a retalhos livres nos membros inferiores. A técnica cirúrgica foi realizada de forma padronizada, com o pino distal localizado 6 cm proximal à anastomose, e o pino proximal, 6cm distal à tuberosidade anterior da tíbia.

**Resultados** A idade média da amostra foi de 34,76 anos (variação: 15 a 66 anos). Foram selecionados 11 homens e 6 mulheres. Utilizou-se a artéria tibial posterior em 14 casos, e a tibial anterior, em 3 casos. O tempo médio de uso dos fixadores externos foi de 3,88 semanas. A taxa de reoperação foi de 17,64%; a de perda do retalho foi de 11,76%; a de sucesso foi de 88,23%; e a taxa de infecção foi de 5,9%.

**Conclusão** O uso de fixadores do tipo delta como método adjuvante no pós-operatório é confiável; porém, mais estudos são necessários para avaliar seu verdadeiro papel no pós-operatório.

## Introduction

Advances in microsurgical techniques have enabled the management of lower limb coverage failure, reducing amputation rates, and providing better functionality of the affected limb.<sup>1,2</sup> Most causes of lower limb coverage failure are: traumatic, oncological, infectious, or vascular. The ultimate goal of reconstructive surgery of the lower limbs is functional restoration of the limb, and bone stabilization, adequate soft tissue coverage, absence of pain, and protective sensitivity of the limb are necessary.<sup>2,3</sup>

Despite the technical evolution and improvements in the microsurgical practice, complications are still reported. Retrospective studies<sup>4,5</sup> demonstrate case series with high variability in success rates and complications. A meta-analysis by Xiong et al.<sup>5</sup> (2016), demonstrated complication rates of 6% of loss of free flaps, 6% of vascular thrombosis and partial necrosis of the skin, 4% of hematoma formation, and 4% of surgical wound dehiscence. Therefore, adjuvant techniques to microsurgical flap management are essential for the success of limb salvage reconstructive surgery.<sup>6</sup>

The use of external fixation methods to elevate the limb and avoid compressive effects on the flap is a concept that has already been described. However, different configurations of the external fixator were developed to facilitate its applicability, offer greater stability to the limb, enable concomitant bone procedures, and relieve additional external compressions on the flap.<sup>6,7</sup> Moreover, the use of external fixators facilitates the access to the flap to monitor postoperative viability and subsequent surgical reapproaches, as needed, in addition to facilitating dressing changes, decubitus changes, clothing changes, and providing more comfortable postures to patients.<sup>7,8</sup>

The aim of the present study was to evaluate the use of external delta-type fixators as an adjunct method in the postoperative period of patients submitted to free flaps for coverage failures in the lower limbs.

## Materials and Methods

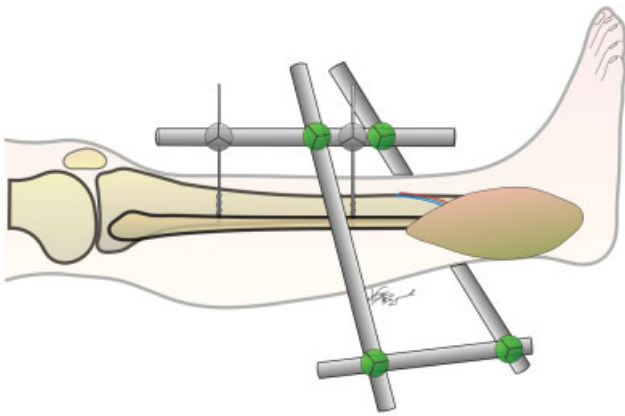
A retrospective study was carried out by reviewing the medical records of patients who underwent the use of the delta-type external fixator after the preparation of the free microsurgical flap for limb coverage failure, between March 2018 and March 2019. The study was approved by the ethics committee under CAAE number 14510719.4.0000.5440.

The variables gender, age, and previous comorbidities were evaluated, as well as the site of the lesion and its etiology. Lesions of traumatic origin were differentiated by the degree of soft-tissue injury, while lesions of tumoral origin were evaluated by the histological degree of the tumor. The variables related to the procedures were the type of microsurgical flap performed and the recipient vessel for anastomosis. The need for bed rescue intervention and its procedure, as well as the need for a reapproach in the operating room, have been documented. The total external fixation time was also evaluated.

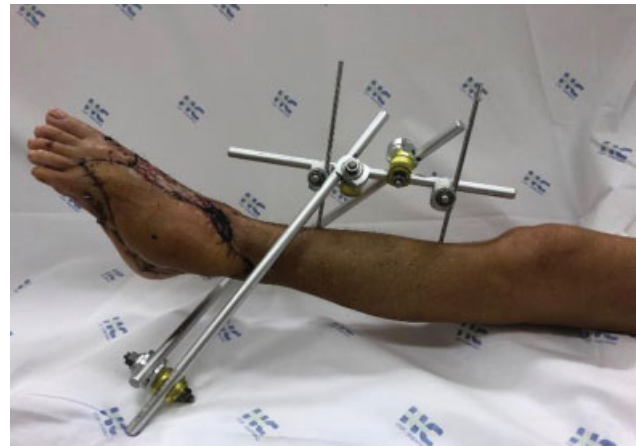The inclusion criteria were patients with coverage failure in the distal third of the leg using an external delta fixator for the maintenance of free microsurgical flaps. Patients who did not agree to participate and those who underwent pedicled flap coverage were excluded.

## Surgical Technique

The patient underwent spinal anesthesia with sedation and was placed in supine position in a radiotransparent surgical



**Fig. 1** External fixator in the delta-type kickstand configuration.



**Fig. 2** Delta-type external fixator placed in a patient, with good skin healing.

table. The procedure for the installation of the external fixator began after the completion of the microsurgical flap. The limb was positioned in extension, and fluoroscopy was used to aid the installation of the external fixator.

A modular external tibia fixator containing 2 long-length (400 mm) carbon rods, 2 medium-length (300 mm) carbon rods, 2 schanz self-threading pins of 5.0 mm in diameter, 2 tube-pin connectors, and 4 tube-to-tube connectors was placed.

We decided to position the Schanz pins perpendicularly to the anteromedial part of the tibia for the placement of the external fixator, respecting the leg safety zone, and using the vascular anastomosis site as a reference point. The first schanz pin (distal pin) was placed 6 cm proximally to the microsurgical vascular anastomosis site, and the second pin (proximal pin) was placed 6 cm distally to the anterior tuberosity of the tibia, as observed in **►Figure 1**. A tube-pin connector was placed on each Schanz pin, and the pins were interconnected by a medium-length rod, oriented longitudinally in the anteromedial region of the leg, forming a uniplanar linear system.

Two tube-to-tube connectors were coupled in the linear system, and two long-length rods were directed to the distal portion of the limb. One rod was positioned on the medial side, and another, on the lateral side, maintaining a distance between the bars and the distal portion of the limb of approximately 6 cm. At the end, the posterior medium-length rod was placed, with two tube-to-tube connectors at the ends, connecting the medial and lateral rods, respecting the height of 6 cm away from the limb, and providing the final aspect to the delta-type external fixator with a circumferential distance of 6 cm between the microsurgical flap and the bars (**►Figure 2**).

## Results

The sample consisted of 15 patients submitted to 17 microsurgical procedures using the delta external fixator. In two patients, two microsurgical flaps were required due to extensive coverage failures. The 17 procedures were analyzed separately.

Regarding these procedures, eleven were performed in male patients, and six, in female patients. The mean age of the sample was of 34.76 years (range: 15 to 66 years). In total, 5 of the patients had comorbidities. Patient comorbidities and epidemiological data are available in **►Table 1**.

Only one patient did not have a traumatic coverage failure. Regarding the traumatic cases, 10 were for type-IIIA open fractures, and 6 were for type-IIIB open fractures. The pattern of the fractures and the topographic location of the cover failures are available in **►Table 2**.

In relation to the free flaps used, thirteen were thigh anterolateral, two were great dorsal, and two were of the Chinese type (from the forearm, based on the radial artery). The recipient vessels were the posterior tibial artery in 14 cases, and the anterior tibial artery in 3 cases.

Three cases required bed intervention to loosen the dressing. In three other cases, there was need for an emergency reapproach in the operating room, one for hematoma drainage and two for pedicle approach. The causes of pedicle reapproach were arterial thrombosis, which was secondary to infection in one case. The patient with arterial thrombosis secondary to infection was managed with flap debridement, intravenous antibiotics, and submitted to a new free microsurgical flap, obtaining good results. In the other case of arterial thrombosis, we opted for the new flap of the large dorsal type, obtaining adequate coverage. Both remained with the use of the external fixator as an adjuvant method of postoperative management. These data are available in **►Table 3**.

The mean length of stay of the external fixator was of 3.88 weeks (range: 1 to 7). Some of these patients required late skin grafting or waited for final granulation of small portions of skin adjacent to the flap. The rate of reoperation was of 17.64%; that of retail loss, 11.76%; that of infection, 5.9% and the rate of success of the flap was of 88.23%.

## Discussion

Postoperative immobilization is indispensable in reconstructive surgeries for coverage failures in the lower limbs;

**Table 1** Characteristics of the patients and epidemiological aspects

Case	Age	Gender	Comorbidities	Trauma	Location of failure	Fracture	Classification of the exposed fracture
1	25	F	No	No	Posterior	Tumoral	–
2	60	F	SAH, DP	Yes	Medial	Lisfranc	IIIB
3	60	F	SAH, DP	Yes	Lateral	Lisfranc	IIIA
4	20	M	No	Yes	Lateral	Talus-cuboid	IIIA
5	48	M	No	Yes	Calcaneus	Calcaneus	IIIA
6	37	M	No	Yes	PL	Ankle	IIIA
7	38	M	No	Yes	PL	Ankle	IIIA
8	24	M	No	Yes	Lateral	Pilon-calcaneus	IIIA
9	15	M	No	Yes	PL + calcaneus	Pilon-calcaneus	IIIB
10	42	F	SAH, TBG	Yes	PL	Ankle	IIIB
11	66	F	SAH, DL, HP	Yes	Lateral	Ankle	IIIB
12	32	M	TBG	Yes	Posterior	Ankle	IIIB
13	23	M	No	Yes	Posterior	Ankle	IIIB
14	41	M	No	Yes	Medial + calcaneus	Calcaneus	IIIA
15	21	F	No	Yes	Medial	Pilon-calcaneus	IIIA
16	19	M	No	Yes	Lateral	Pilon	IIIA
17	20	M	No	Yes	PL	Pilon	IIIA

Abbreviations: DL, dyslipidemia; DP, depression; F, female; SAH, systemic arterial hypertension; HP, hypothyroidism; M, male; PL, posterolateral.

however, continuous visualization and monitoring of the flap should be allowed. The use of splints offers advantages in terms of practicality and cost; however, the numerous disadvantages routinely limit their use.<sup>9</sup>

Buford and Trzeciak<sup>9</sup> described the use of the Hoffman external fixator for ankle immobilization and free flap handling in three patients, without reporting complications. Emphasis was added to the ease in monitoring the flap, as well as the elimination of the compressive effect, of odor, and the absence of bacterial colonization. In contrast to the present study, the authors demonstrate extended fixation to the metatarsals to maintain the ankle joint in dorsiflexion, and prevention of the equine in the hindfoot. In the present study, no complications such as ankle or equine stiffness were observed, because the patients underwent motor physiotherapy for the range of motion of the ankle and foot during the period in which they used the external fixator. The external delta-type kickstand configuration fixators used in the present study were placed after osteosynthesis and the management of fractures and bone lesions, and were not used for bone management.

The technique described in the present study is of simple execution and has good reproducibility. In addition to the benefits mentioned, the use of an external fixator presents an important advantage as an adjuvant method in the treatment of complex fractures, often present in conjunction with skin coverage defects. Its assembly is the same, regardless of the specific manufacturer. The objective of the external fixator is to avoid compressive points, vascular stasis, edema control

measures, besides assisting in the postoperative care of polytraumatized patients.<sup>10</sup> The final aspect of the flap and

**Table 2** Flaps and receptor vessels

Case	Flap type	Receptor vessel
1	ALT	PT
2	ALT	PT
3	ALT	AT
4	ALT	PT
5	ALT	PT
6	GD	PT
7	ALT	PT
8	ALT	PT
9	ALT	PT
10	Chinese	PT
11	ALT	PT
12	ALT	PT
13	GD	PT
14	ALT	AT
15	ALT	PT
16	ALT	PT
17	Chinese	AT

Abbreviations: ALT, anterolateral thigh; GD, great dorsal; AT, anterior tibial artery; PT, posterior tibial artery.

**Table 3** Results and complications

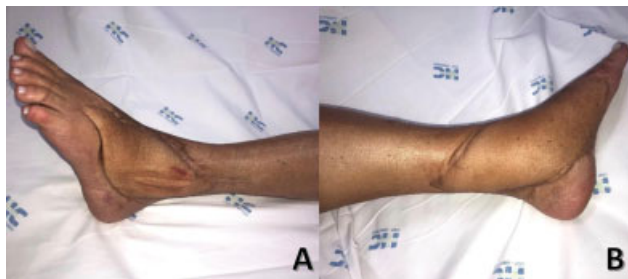
Case	Bed intervention	Type of intervention	Reapproach	Cause of reapproach	Flap loss	Reason for loss	EF time (weeks)	Additional procedure
1	No	No	No	No	No	No	4	No
2	No	No	No	No	No	No	4	No
3	No	No	No	No	No	No	5	No
4	No	No	Yes	Bleeding	No	No	7	Graining
5	No	No	Yes	Infection	Yes	Infection	1	New flap
6	No	No	Yes	Arterial insufficiency	Yes	Arterial thrombosis	1	New flap
7	Yes	Loosen dressing	No	No	No	No	4	Ilizarov (transportation)
8	No	No	No	No	No	No	4	Skin graft
9	No	No	No	No	No	No	3	No
10	No	No	No	No	No	No	5	Skin graft
11	No	No	No	No	No	No	3	No
12	No	No	No	No	No	No	4	No
13	No	No	No	No	No	No	4	No
14	Yes	Loosen dressing	No	No	No	No	3	No
15	Yes	Loosen dressing	No	No	No	No	5	Skin graft
16	No	No	No	No	No	No	4	Skin graft
17	No	No	No	No	No	No	5	Skin graft

Abbreviation: EF, external fixator.

limb after removal of the external fixator can be seen in **Figure 3**.

The support with an external fixator eliminated the compressive factor and was able to maintain adequate limb elevation during the postoperative period, and rescue measures in the bed were dispensable. In addition, the addition of an external fixator was able to remove the shear forces on the flap, being one of the main success factors in postoperative management.<sup>11</sup>

Castro-Aragón, Rapley and Trevino<sup>10</sup> used the kickstand-type external fixator in 11 coverage failures, explaining that in all cases there were no skin changes; however, they did not report the possible complications of the method. Other studies<sup>11-13</sup> have described its use and modifications in



**Fig. 3** Postoperative outcome after withdrawal. (A) Case #2, with anterolateral flap of the thigh due to failure of coverage in the lateral region. (B) Case #3, with anterolateral flap of the thigh due to failure of coverage in the medial region.

assemblies, but with smaller series, such as of the study by Kachare et al.,<sup>11</sup> who describe the success in healing in a series of 4 patients, without reporting complications.

Previous studies<sup>6,10-13</sup> have portrayed the benefits of the use of external fixators in the management of flaps or lesions in the posterior region of the hindfoot and its timely applicability in this group of patients. This is justified by the significant need for postoperative care in the monitoring of flaps.<sup>14-19</sup>

Postoperative positioning has also been an important factor in the prognosis of flaps, considering that pedicle compression can lead to complications, including flap loss.<sup>20-22</sup> Overall, the rate of non-survival of free flaps in the acute trauma scenario can reach 12%. Lower rates of flap loss, such as 4%, have also been observed, which shows us the need for specific postoperative care.<sup>23-28</sup>

Maruccia et al.<sup>29</sup> described a series of 14 patients, in which they reported infection as a complication in 2 patients, with an average time of 3.79 weeks (range: 3 to 5 weeks) in the use of the external fixator. They did not report stiffness or equine deformity in the ankles. Most studies did not record the viability rate of the flaps, although they reported a lower number of procedures than in our study, and used the kickstand-type external fixator for wound management by the use of vacuum dressing, pedicled flaps, as well as free flaps.<sup>9-13,29</sup>

The limitations of the present study are the small group of patients, the few variables available, as well as the lack of a control group or comparisons with other studies.

## Conclusion

The present study demonstrated a series of cases in which the use of the external fixator, as an adjuvant method in the postoperative care of microsurgical flaps for lower limb coverage failures, proved to be an efficient method. However, we cannot affirm that its use is correlated specifically with the success of the microsurgical procedure, since other variables were not measured and considered in the study. Further studies are needed, with a larger series of flaps and with a control group to define the applicability and advantage of the use of external fixators as an adjuvant method of postoperative management.

### Financial Support

There was no financial support from public, commercial, or non-profit sources.

### Conflict of Interests

The authors have no conflict of interests to declare.

## References

- Wei F, Al Deek NF, Lin Tay SK. Principals and techniques of microvascular surgery. In: *Plastic Surgery: Principles*. Philadelphia: Elsevier;2018:444–472
- Ninkovic M, Voigt S, Dornseifer U, Lorenz S, Ninkovic M. Microsurgical advances in extremity salvage. *Clin Plast Surg* 2012;39(04):491–505
- Benacquista T, Kasabian AK, Karp NS. The fate of lower extremities with failed free flaps. *Plast Reconstr Surg* 1996;98(05):834–840
- Perrot P, Bouffaut AL, Perret C, Connault J, Duteille F. Risk factors and therapeutic strategy after failure of free flap coverage for lower-limb defects. *J Reconstr Microsurg* 2011;27(03):157–162
- Xiong L, Gazyakan E, Kremer T, et al. Free flaps for reconstruction of soft tissue defects in lower extremity: A meta-analysis on microsurgical outcome and safety. *Microsurgery* 2016;36(06):511–524
- Zgonis T, Roukis TS. Off-loading large posterior heel defects after sural artery soft-tissue flap coverage with stacked taylor spatial frame foot plate system. *Oper Tech Orthop* 2006;16(01):32–37
- Nappi JF, Drabyn GA. External fixation for pedicle-flap immobilization: a new method providing limited motion. *Plast Reconstr Surg* 1983;72(02):243–245
- Zgonis T, Stapleton JJ. Innovative techniques in preventing and salvaging neurovascular pedicle flaps in reconstructive foot and ankle surgery. *Foot Ankle Spec* 2008;1(02):97–104
- Buford GA, Trzeciak MA. A novel method for lower-extremity immobilization after free-flap reconstruction of posterior heel defects. *Plast Reconstr Surg* 2003;111(02):821–824
- Castro-Aragon OE, Rapley JH, Trevino SG. The use of a kickstand modification for the prevention of heel decubitus ulcers in trauma patients with lower extremity external fixation. *J Orthop Trauma* 2009;23(02):145–147
- Kachare SD, Vivace BJ, Henderson JT, et al. Kickstand External Fixator for Immobilization Following Free Flap Plantar Calcaneal Reconstruction. *Eplasty* 2019;19:e11
- Berkowitz MJ, Kim DH. Using an external fixation “kickstand” to prevent soft-tissue complications and facilitate wound management in traumatized extremities. *Am J Orthop* 2008;37(03):162–164
- Roukis TS, Landsman AS, Weinberg SA, Leone E. Use of a hybrid “kickstand” external fixator for pressure relief after soft-tissue reconstruction of heel defects. *J Foot Ankle Surg* 2003;42(04):240–243
- Hirigoyen MB, Urken ML, Weinberg H. Free flap monitoring: a review of current practice. *Microsurgery* 1995;16(11):723–726, discussion 727
- Baumeister SP, Spierer R, Erdmann D, Sweis R, Levin LS, Germann GK. A realistic complication analysis of 70 sural artery flaps in a multimorbid patient group. *Plast Reconstr Surg* 2003;112(01):129–140, discussion 141–142
- Bhatnagar A. Miniwatermattress to prevent pressure sores over the heel. *Plast Reconstr Surg* 1997;99(03):927–928
- Yilmaz M, Karatas O, Barutcu A. The distally based superficial sural artery island flap: clinical experiences and modifications. *Plast Reconstr Surg* 1998;102(07):2358–2367
- Clark J, Mills JL, Armstrong DG. A method of external fixation to offload and protect the foot following reconstruction in high-risk patients: the SALSAsand. *Eplasty* 2009;9:e21
- Singh B, Cordeiro PG, Santamaria E, Shaha AR, Pfister DG, Shah JP. Factors associated with complications in microvascular reconstruction of head and neck defects. *Plast Reconstr Surg* 1999;103(02):403–411
- Noack N, Hartmann B, Küntscher MV. Measures to prevent complications of distally based neurovascular sural flaps. *Ann Plast Surg* 2006;57(01):37–40
- Price MF, Capizzi PJ, Watterson PA, Lettieri S. Reverse sural artery flap: caveats for success. *Ann Plast Surg* 2002;48(05):496–504
- Hanasono MM, Skoracki RJ, Yu P. A prospective study of donor-site morbidity after anterolateral thigh fasciocutaneous and myocutaneous freeflap harvest in 220 patients. *Plast Reconstr Surg* 2010;125:e209–e214
- Godina M. Early microsurgical reconstruction of complex trauma of the extremities. *Plast Reconstr Surg* 1986;78(03):285–292
- Karanas YL, Nigriny J, Chang J. The timing of microsurgical reconstruction in lower extremity trauma. *Microsurgery* 2008;28(08):632–634
- Coskunfirat OK, Chen HC, Spanio S, Tang YB. The safety of microvascular free tissue transfer in the elderly population. *Plast Reconstr Surg* 2005;115(03):771–775
- Griffin JR, Thornton JF. Lower extremity reconstruction. *SRPS* 2003;9(37):1–31
- Byrd HS, Cierny G 3rd, Tebbetts JB. The management of open tibial fractures with associated soft-tissue loss: external pin fixation with early flap coverage. *Plast Reconstr Surg* 1981;68(01):73–82
- Sun TB, Chien SH, Lee JT, Cheng LF, Hsu LP, Chen PR. Is dextran infusion as an antithrombotic agent necessary in microvascular reconstruction of the upper aerodigestive tract? *J Reconstr Microsurg* 2003;19(07):463–466
- Maruccia M, Elia R, Caizzi G, et al. Free flap and kickstand external fixator in foot and ankle soft tissue reconstruction. The versatility of a microsurgical-friendly application of an orthopedic device. *Injury* 2018;49(Suppl 3):S105–S109