



# Abdominal Wall Vascularized Composite Allotransplantation: A Scoping Review

Valeria P. Bustos, MD<sup>1</sup>  Joseph M. Escandón, MD<sup>2</sup>  Eric Santamaría, MD<sup>3</sup>  
 Pedro Ciudad, MD, PhD, FACS<sup>4</sup> Antonio J. Forte, MD, PhD<sup>5</sup> Roberto Hernandez-Alejandro, MD, FACS<sup>6</sup>  
 Jonathan I. Leckenby, MBBS, PhD<sup>2</sup> Howard N. Langstein, MD<sup>2</sup> Oscar J. Manrique, MD, FACS<sup>2</sup>

<sup>1</sup> Division of Plastic and Reconstructive Surgery, Department of Surgery, Beth Israel Deaconess Medical Center, Harvard Medical School, Boston, Massachusetts

<sup>2</sup> Division of Plastic and Reconstructive Surgery, Department of Surgery, Strong Memorial Hospital, University of Rochester Medical Center, Rochester, New York

<sup>3</sup> Department of Plastic and Reconstructive Surgery, Hospital General Dr. Manuel Gea Gonzalez, National Cancer Institute, Mexico City, Mexico

<sup>4</sup> Department of Plastic, Reconstructive, and Burn Surgery, Arzobispo Loayza National Hospital, Lima, Peru

Address for correspondence Oscar J. Manrique, MD, FACS, 160 Sawgrass Drive, Suite 120, Rochester, NY 14620 (e-mail: oscarj.manrique@gmail.com).

<sup>5</sup> Division of Plastic and Reconstructive Surgery, Mayo Clinic, Jacksonville, Florida

<sup>6</sup> Division of Abdominal Transplantation and Hepatobiliary Surgery, Department of Surgery, Strong Memorial Hospital, University of Rochester Medical Center, Rochester, New York

J Reconstr Microsurg 2022;38:481–490.

## Abstract

**Background** Abdominal wall vascularized composite allotransplantation (AW-VCA) is a novel reconstructive technique used for large abdominal wall defects in combination with intestinal transplantation (ITx) or multivisceral abdominal transplantation (MVTx). Since the introduction of this procedure, several studies have been published reporting their experience. This study aims to present a scoping review looking at all available evidence-based medicine information to understand the most current surgical techniques and clinical outcomes.

**Methods** This scoping review followed the Preferred Reporting Items for Systematic Reviews and Meta-analysis (PRISMA) extension for scoping reviews checklist. A comprehensive research strategy of several databases was conducted.

**Results** A total of 31 studies were included in this review, which comprised animal, cadaveric, and human studies. In human studies, four surgical techniques with high flap survival rates and low complication rates were found. In cadaveric studies, it was shown that the use of iliofemoral cuff-based flaps provided adequate tissue perfusion to the abdominal wall graft. Also, the use of thoracolumbar nerves have been described to provide functionality to the AW-VCA and prevent long-term muscle atrophy.

**Conclusion** AW-VCA is a safe and efficient alternative for patients with large and complex abdominal wall defects. The future holds a promising evolution of a functional AW-VCA, though surgeons must face and overcome the challenge of distorted anatomy frequently present in this population. Forthcoming studies with a better level of evidence are required to evaluate functionality and differences between surgical techniques.

## Keywords

- ▶ abdominal wall
- ▶ composite allotransplantation
- ▶ abdominal wall allotransplantation
- ▶ abdominal wall vascularized composite transplantation

Large abdominal wall defects after an intestinal transplantation (ITx) or multivisceral transplantation (MVTx) are difficult to repair with primary closure in 20 to 39.5% of the cases.<sup>1,2</sup> These defects can arise also from tumor resection,

intestinal failure, multiple laparotomies, enterocutaneous fistulas, trauma, infection, and radiation damage, leading to extensive scarring and significant loss of abdominal domain.<sup>3,4</sup> This complication can significantly jeopardize

received

April 26, 2021

accepted after revision

September 26, 2021

published online

December 14, 2021

© 2021, Thieme. All rights reserved.

Thieme Medical Publishers, Inc.,

333 Seventh Avenue, 18th Floor,

New York, NY 10001, USA

DOI <https://doi.org/>

10.1055/s-0041-1740121.

ISSN 0743-684X.

the abdominal wall function such as viscera protection, postural stabilization, respiration, and intra-abdominal pressure maintenance.<sup>5</sup> Therefore, when an ideal tension-free primary closure is not possible, surgeons must identify the best abdominal wall reconstruction technique to provide a functional and integral abdominal wall cover.

Several strategies have been proposed depending on the abdominal wall defects and contamination status.<sup>5</sup> The use of skin grafts, tissue expansion, locoregional and free flaps, and component separation with or without synthetic/biological meshes has been described.<sup>5</sup> However, when the exhaustion of all these strategies occurs, an abdominal wall vascularized composite allotransplantation (AW-VCA) has been proposed as a feasible solution to this problem. Since the inception and introduction of AW-VCA in 2003, all surgical approaches for abdominal wall coverage have been reported in conjunction with ITx or MVTx.<sup>2,6</sup> Nowadays, experts have not been able to arrive at a consensus on which AW-VCA should be chosen as the gold standard (i.e., based on the lowest risk-to-benefit ratio). The reason being that all the above pose major operative and patient-related challenges (i.e., ischemia time, overall operative time, and variability in the anatomy of recipient and donor, among others).<sup>6,7</sup> However, the truth is that since the introduction of this novel solution, surgeons and researchers are avid to explore the ideal AW-VCA technique reflected in various cadaveric, animal, and human studies reported so far.

To understand the AW-VCA approaches, it is essential to have a thorough understanding of the basic science behind each proposal, as well as the harvesting techniques and anatomical considerations to ultimately comprehend the revascularization approaches performed in these patients. To the best of our knowledge, there is no systematic review or scoping review that recompiles medical literature from various sources regarding AW-VCA in cadaveric, animal, and human studies. Hence, we performed a scoping review to present the synthesis of all the available evidence on AW-VCA.

## Methods

### Search Methodology

This scoping review followed the Preferred Reporting Items for Systematic Reviews and Meta-analysis (PRISMA) extension for scoping reviews checklist.<sup>8</sup> A comprehensive research strategy of several databases was conducted through November 2020. The electronic databases were the following: PubMed—1976 to 2020; EBM Reviews—Cochrane Central Register of Controlled Trials October 2020; EBM Reviews—Database of Abstracts of Reviews of Effects, 1st Quarter 2016; Ovid MEDLINE(R) ALL—1946 to November 2, 2020; and Embase—1974 to 2020. The citation index databases were Scopus and Web of Science (2001–2020). Finally, a manual search of relevant citations was performed from the reference lists of included studies identified through the electronic search strategy, and duplicates were eliminated. The research strategy was designed and conducted with controlled vocabulary and keywords. The actual strategy is available in the ► **Supplemental Data S1** (online only).

### Study Selection

A two-screening process was conducted by two reviewers (V.P. B. and J.M.E.). The first and second screening processes consisted of reviewing titles and abstracts, and the full-text form, respectively. If discordance were present during this process, a third reviewer (O.J.M.) moderated the discussion and a final decision was made. Inclusion criteria were all articles that discussed patients who underwent AW-VCA and that reported surgical techniques, animal, cadaveric, human studies, and observational or interventional studies in English, Dutch, and Spanish. Exclusion criteria were letter to editors, online abstracts, review articles, and social media observations.

### Data Extraction and Synthesis

The same procedure as the aforementioned was performed for data extraction. Extraction of the following information was performed: first author's name, year of publication, country of origin, number of participants, age, and follow-up periods. For surgical technique, we identified donor and receptor vessels, flap anatomy, flap design, ischemia time, overall surgical time, and neuroorrhaphy performance. Also, postoperative immunosuppressive medications, flap survival rate, and complications were identified.

### Quality Assessment and Grading

Case reports and case series, cadaveric dissection studies, and animal studies were included in this review. Therefore to evaluate the quality assessment of a case report and case series, the Methodological Quality and Synthesis of case series and case reports proposed by Murad et al in 2018 was used.<sup>9</sup> For cadaveric dissection studies and animal studies, the Quality Appraisal for Cadaveric Studies (QUACS scale) and Risk of Bias (RoB) tool for animal intervention studies (Systematic Review Centre for Laboratory animal Experimentation (SYRCLE) RoB tool) were used.<sup>10,11</sup>

### Aims

Our primary aim was to explore the AW-VCA surgical techniques by considering the advances in history reported in cadaveric, animal, and human studies. Our secondary aim was to explore the total surgical time, survival rate, complication rate, performance of neuroorrhaphy, and postoperative immunosuppressive medications.

## Results

### Included Studies and Quality Assessment

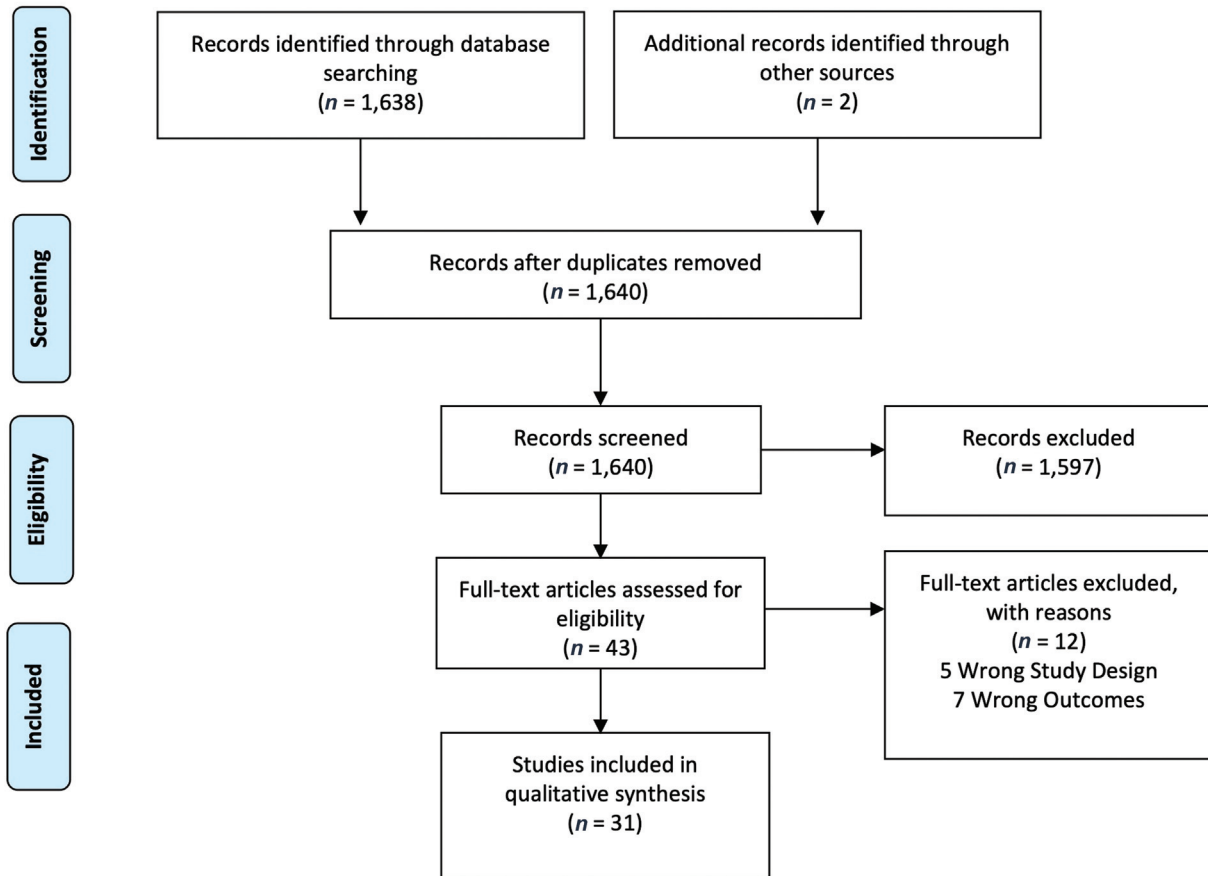
A total of 1,640 studies were identified in the search strategy. Of these, 31 articles were included in this study (► **Fig. 1**). For cadaveric, animal, and human studies, a total of 7, 4, and 20 articles were identified, respectively. In ► **Supplemental Data S2** (online only), quality assessment is presented.

### Cadaveric Studies

Study characteristics are shown in ► **Table 1**.<sup>12–15</sup> Dissection techniques were similar among studies. The anatomic landmarks were as follows: superiorly, the costal margin and xiphoid process; laterally, the anterior axillary or midaxillary



PRISMA 2009 Flow Diagram



**Fig. 1** The Preferred Reporting Items for Systematic Reviews and Meta-analysis (PRISMA) flow diagram.<sup>51</sup>

**Table 1** Cadaveric study descriptions and flap characteristics

Study	Country	No. of Cadavers	Flap components	Flap pedicle	Flap innervation	Mean flap dimensions (cm <sup>2</sup> ± SD)
Hollenbeck et al <sup>12</sup>	United States	5	Skin, SCT, superior portion of the RAM, EOM, and TAM	Iliofemoral pedicle <sup>a</sup>	N	NS
Singh et al <sup>13</sup>	United States	2	Skin, SCT, fascia, TLN and vertebrocostal ribs	DIEVs	Y <sup>b</sup>	845 ± 205
Broyles et al <sup>15</sup>	United States	3	Skin, SCT, TAM, fascia, TLN, and peritoneum	DIEVs	Y <sup>b</sup>	615 ± 120
Light et al <sup>14</sup>	United States	20	Skin, SCT, RAM, EOM, IOM, TAM, fascia, and peritoneum	Iliofemoral pedicle <sup>a</sup>	N	868 ± NS

Abbreviations: DIEVs, deep inferior epigastric vessels; EOM, external oblique muscle; IOM, internal oblique muscle; N, no; NS, not specified; RAM, rectus abdominis muscle; SCT, subcutaneous tissue; SD, standard deviation; TAM, transversus abdominis muscle; TLN, thoracolumbar nerves; Y, yes.  
<sup>a</sup>Deep circumflex inferior artery (DCIA), deep inferior epigastric artery (DIEA), superficial inferior epigastric artery (SIEA), and superficial circumflex inferior artery (SCIA).  
<sup>b</sup>Flaps innervated by the thoracolumbar nerves.

lines; and inferiorly, the anterior superior iliac spine, inguinal ligament (0–10 cm below), and the pubic tubercle.

Tissue perfusion was evaluated in two cadaveric studies. In 2011, Hollenbeck et al assessed the maximal abdominal skin surface obtainable through an iliofemoral cuff-based pedicle.<sup>12</sup> The iliofemoral cuff-based pedicle contained deep circumflex iliac vessels (DCIVs), deep inferior epigastric vessels (DIEVs), superficial inferior epigastric vessels (SIEVs), and superficial circumflex iliac vessels (SCIVs).<sup>12</sup> They identified that the mean hemiabdominal area perfused was significantly greater in the iliofemoral cuff compared with the DIEA vessel alone with a difference of 19.3%.<sup>12</sup> Also, limited perfusion in both scenarios to the upper lateral portion of the abdominal wall perfusion was found.<sup>12</sup> In 2017, Light et al evaluated the tissue perfusion including the deep circumflex system and identified an obvious difference between flaps with and without the system.<sup>14</sup> Also, the authors evidenced an improvement in perfusion on the lateral muscles with the inclusion of the DCIVs.<sup>14</sup>

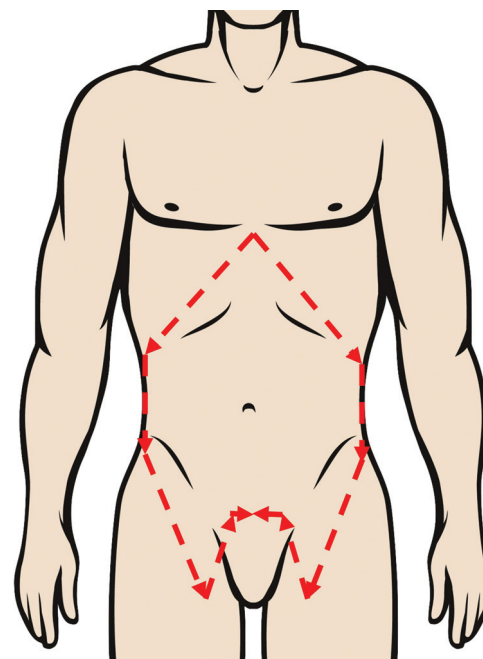
Later, in 2014 Singh et al<sup>13</sup> and Broyles et al<sup>15</sup> evaluated the feasibility of harvesting a possible functional AW-VCA. Both studies presented a similar surgical technique for rapid isolation of the thoracolumbar nerve with a two-layered component separation. They performed an incision 2 cm lateral to the linea semilunaris to enter the plane between the internal oblique and transversus abdominis muscle to identify and skeletonize the thoracolumbar nerves. Broyles et al found a total of  $5 \pm 1.4$  of thoracolumbar nerves with a skeletonized length of  $7.8 \pm 1.7$  cm and a cross-sectional diameter of more than 2 mm.<sup>15</sup> Singh et al in their model added a 6-cm segment of the three inferior vertebrochondral ribs to the flap.<sup>13</sup> They identified four thoracolumbar nerves bilaterally, with an average length of the skeletonized nerve of  $5.7 \pm 1.2$  cm.<sup>13</sup>

Finally, Light et al also presented a detailed dissection technique for a total AW-VCA.<sup>14</sup> The dissection technique is presented and described in detail in ► Fig. 2.

### Animal Studies

Study characteristics are shown in ► Tables 2 and 3.<sup>16–22</sup> The majority of the animal studies were performed to evaluate the immunosuppression regimen and feasibility of AW-VCA. The anatomic landmarks were similar among studies; superiorly, the xiphoid process and costal margin, laterally the anterior axillary lines, and inferiorly the inguinal ligament (0–1 cm) below and the pubic tubercle.

Four studies assessed the immunosuppressive regimens and response.<sup>16,17,20,21</sup> All of the studies used cyclosporine A or FK506 immunosuppressive drugs showing tissue integration and prolonged survival length compared with the studies in which these were not used.<sup>16,17,20,21</sup> Particular situations were evaluated among studies to assess the immunogenic status. The addition of vascularized bone marrow transplantation (VBMT) to an AW-VCA was proposed by Ramirez et al in 2014.<sup>16</sup> They found that the VBMT group had a better long-term survival rate and allograft tolerance compared with the other groups.<sup>16</sup> Interestingly, the study's findings suggest that allograft mass is a critical factor that



**Fig. 2** Light et al's dissection technique. The incision began over the xiphoid process and extended bilaterally on top of the fusion of the false ribs and the edge of the ribs. Then, the dissection continued to the abdominal wall along the midaxillary line and 2 to 3 cm lateral to the anterior superior iliac spine (ASIS). Once past the ASIS, the dissection was then carried 7 to 10 cm inferior and medial below the inguinal ligament, to later be carried medial and superior toward the pubic tubercle. Dissection from lateral to medial was performed to identify the superficial circumflex iliac vessels (SCIVs) and deep circumflex iliac vessels (DCIVs).

has an impact on long-term survival.<sup>16</sup> Moreover, in 2008, Nasir et al evaluated the immunologic response generated to skin antigenic load by comparing a large AW-VCA with different anatomical allografts.<sup>17</sup> Total AW-VCA had a higher chimerism level compared with the groin flaps, and a lower level compared with the full face and hemiface allografts.<sup>17</sup> Quigley et al in 2013 evaluated the ideal immunosuppressive dosage to prevent rejection with three groups receiving FK506 monotherapy at a dose of 0.25, 0.50, or 0.75 mg/kg/d<sup>20</sup> (► Table 2). They found that the use of FK506 at a dose of  $\geq 0.50$  mg/kg/d resulted in survival of all the grafts.

In 2010, Jin et al assessed the rejection and denervation of muscle evolution of a nonfunctional AW-VCA and identified a significant reduction of gross thickness with a significantly lower tensile strength of the transplanted muscle flap compared with the native muscle.<sup>18</sup> Moreover, the authors evidenced a significantly decreased muscle fiber diameter of 0.06 mm.<sup>18</sup>

### Human Studies

AW-VCA was performed in five groups (Miami,<sup>2,23–25</sup> Bologna,<sup>1,26–29</sup> Oxford,<sup>30–36</sup> Duke,<sup>6,37</sup> and Groningen<sup>38,39</sup> groups). An overlap of sample population was found among studies that made overall outcome estimations challenging. Hence, we group the series of studies according to the institution.

**Table 2** Animal study characteristics

Study	Country	Type of experimental animals	Groups	No. of experimental animals	Sex	Age (wk)	No. of AWT performed	Follow-up time (d)
Ramirez et al <sup>16</sup>	Taiwan	BN (d) and L (r) rats	<ul style="list-style-type: none"> <li>Control VCA groups<sup>a</sup></li> <li>Syngeneic groups</li> <li>VCA treatment groups</li> </ul>	47	M	8–12	47	150 <sup>e</sup>
Nasir et al <sup>17</sup>	United States	LBN (d) and L (d/r) rats	<ul style="list-style-type: none"> <li>Anatomic studies group (n8)<sup>b</sup></li> <li>Experimental TAW transplant group (n16)<sup>c</sup></li> </ul>	22	NS	NS	16	100
Jin et al <sup>18</sup>	United States	Farm swine	N/A	26	F	8	13	28
Yang et al <sup>19</sup>	United States	WK (d heart), F344 (r), and L (d TAW) rats	N/A	25	M	NS	5	20
Quigley et al <sup>20</sup>	United States	BN (d) and L (r) rats	Four groups: <ul style="list-style-type: none"> <li>Control group (n4)</li> <li>Group 1: 0.25 mg/kg per day of FK506 (n6)</li> <li>Group 2: 0.50 mg/kg per day FK506 (n6)</li> <li>Group 3: 0.75 mg/kg per day FK506 (n6)</li> </ul>	22	M/F	M 8–10; ≥ 11 F	22	100
Lao et al <sup>21</sup>	Taiwan	BN (d) and L (d/r) rats	Syngeneic group: L to L (n5) Allo-control group: <sup>d</sup> BN to L (n8) <sup>d</sup> Allo-CsA: BM to L (n5)	18	M	8–12	18	120
Grosu-Bularda et al <sup>22</sup>	Romania	BN and L rats	N/A	4	M	13–14	4	NS

Abbreviations: BN, Brown Norway; CsA, cyclosporine A; (d), donors; F, female; L, Lewis; M, male; n, number; N/A, not applicable; NS, not specified; (r), recipients; TAW, total abdominal wall; VCA, vascularized composite allotransplantation; WK, Wistar Kyoto; e, highest median observation time.

<sup>a</sup>Control VCA groups and syngeneic groups received no immunosuppressant treatment and VCA treatment groups received 0.5 mL of antilymphocyte serum 1 day before surgery and on postoperative day (POD) 10, 16 mg/kg/d of cyclosporine A from day 0 to 10, and intravenous infusions of syngeneic adipocyte-derived stem cells at 2 × 10<sup>6</sup>/dose on POD 1, 8, and 15.

<sup>b</sup>Anatomic studies group: subgroup A anatomic dissections were performed to assess vascular anatomy and determine skin island border of TAW in 4 L rats and subgroup B diameters of TAW were compared with previous composite tissue allotransplant models that included skin in two L rats (n2).

<sup>c</sup>The experimental group had two subgroups: isograft and allograft transplant with 8 L rats and 8 LBN rats, respectively.

<sup>d</sup>The allo-control group did not receive immunosuppressive medications and the Allo-CsA group received one dose of preoperative antilymphocyte serum 2.5 mg with 30 days of tapering subcutaneous cyclosporine (16 mg/kg/d × 10 days, 10 mg/kg/d × 10 days, and 5 mg/kg/d × 10 days).

<sup>e</sup>Highest median observation time.



**Table 3** Surgical and flap characteristics in animal studies

Study	Immunosuppressive medications	Flap components	Flap pedicle	Flap dimensions (cm <sup>2</sup> ), SD	Recipient vessels	Surgical time (min)	Ischemic time (min)
Ramirez et al <sup>16</sup>	Antilymphocyte serum, cyclosporine A, and SADSC	Full-thickness HAW transplant	CIVs	24	FVs	38 ± 4 HAW/49 ± 3 HAW/HLOM <sup>b</sup>	28 ± 3
Nasir et al <sup>17</sup>	Cyclosporine A	Skin and SCT	FVs	96	FVs	NS	NS
Jin et al <sup>18</sup>	Cyclosporine, MMF, and corticosteroids	Skin, SCT, unilateral RAM, and fascia	IEVs left in continuity with CIVs and the Ao and IVC	NS	EIVs	390 (360–540)	NS
Yang et al <sup>19</sup>	Cyclosporine A	NS	FVs	9	FVs	NS	64 ± 5
Quigley et al <sup>20</sup>	FK506	Skin, SCT, fascia, and underlying abdominal muscles	CIVs	80	FVs	NS	30
Lao et al <sup>21</sup>	Group 3: antilymphocyte serum and cyclosporine	Full-thickness HAW	CIVs	20	CFVs	240	60
Grosu-Bularda et al <sup>22</sup>	Cyclosporine A	Full-thickness HAW <sup>a</sup>	EIVs	NS	NS	NS	NS

Abbreviations: Ao, aorta; CIVs, common femoral vessels; CFVs, common iliac vessels; EIVs, external iliac vessels; FVs, femoral vessels; HAW, hemiabdominal wall; HLOM, hindlimb osteomyocutaneous; IL, inguinal ligament; IVC, inferior vena cava; MMF, mycophenolate mofetil; NS, not specified; RAM, rectus abdominis muscle; b, flap harvest time; SADSC, syngeneic adipocyte-derived stem cells; SCT, subcutaneous tissue.

<sup>a</sup>From skin to parietal peritoneum.

<sup>b</sup>Flap harvest time.

► **Tables 4 and 5** depict the surgical techniques considered, flap anatomy/design, and outcomes. The Miami group, in 2003, published the first AW-VCA combined with ITx and MVTx.<sup>2</sup> The authors presented an end-to-side macrovascular anastomosis of donor inferior epigastric vessels (IEVs) in continuity with the iliac vessels and femoral vessels (FVs) to recipient CIVs.<sup>2</sup> They designed a vascularized myocutaneous free flap based on skin, subcutaneous tissue, and one or both rectus abdominis muscles with their investing fascia.<sup>2</sup> This technique added extra 2 hours to the surgical time.<sup>2</sup> They presented low rates of graft rejection with this regimen.<sup>2</sup> In 2004, Bejarano et al found no suggestive correlation of rejection between ITx and MVTx and AW-VCA rejection.<sup>25</sup> Notably, the abdominal wall and intestine were from different donors in two patients.

The second surgical technique was proposed in 2007 by Cipriani et al, the Bologna group.<sup>26</sup> This procedure was also combined with ITx with different donor origin with respect to AW-VCA.<sup>26</sup> The authors presented the first microsurgical approach by performing an end-to-end microvascular anastomosis between the donor and recipient IEVs or DCIVs.<sup>26</sup> The flap components were based on bilateral rectus abdominis muscles, a small portion of the oblique muscles with the deep muscular fascia, and the parietal layer of the peritoneum.<sup>26</sup> The mean operative time was 2 hours and 15 minutes. The authors evidenced only one mild rejection at postoperative day 83.<sup>26</sup>

The Oxford group presented the third surgical technique published by Giele et al in 2014.<sup>32</sup> They presented a remote revascularization model using the forearm vessels as a temporary bank to decrease cold ischemia time, for a later transfer and anastomosis of the donor and recipient IEVs or internal mammary arteries (IMAs) with an end-to-end approach.<sup>32</sup> The flap components were both rectus abdominis muscles with the rectus sheath, the lateral sheaths of the transversus, internal and external oblique muscles, and the peritoneum.<sup>32</sup> They used the same donor for ITx and AW-VCA and found in their five-case series two occasions of early recognition of skin rejection before intestinal rejection.<sup>32</sup> The rejections were attributed to poor compliance with tacrolimus.<sup>32</sup> Also, Mannu et al in 2013 and 2014<sup>31,33</sup> and Gerlach et al in 2016<sup>35</sup> corroborated that AC-VCA may be useful for “lead time” to rejection in the visceral organ and to distinguish rejection from infection.

Additionally, Mannu et al reported another case report in 2014 of thermal trauma to the AW-VCA, demonstrating the major pitfall until now of all the AW-VCA procedures: lack of nerve supply and, therefore, revascularization of nonfunctional grafts.<sup>34</sup> Interestingly, Gerlach et al found no hernia development after AW-VCA with a mean follow-up period of 24 months.<sup>35</sup>

More recently, in 2019, Erdmann et al<sup>37</sup> from Duke reported a new AW-VCA approach. They presented the creation of an arteriovenous loop with the saphenous vein by performing an end-to-side anastomosis with the recipient common femoral artery to later transect the loop and perform an end-to-end anastomosis with the donor IEVs.<sup>37</sup> The surgical procedure lasted 14 hours.<sup>37</sup> Finally, the surgical

**Table 4** Surgery characteristics from the human studies

Combined groups	ITx vs. MMVTx vs. MVTx <sup>a</sup>	Flap pedicle	Receptor vessels	Flap size (cm <sup>2</sup> ) <sup>b</sup>	Synchronous revascularization	Microsurgery required	Surgical time (h) <sup>b</sup>
Combined University of Miami School of Medicine/Jackson Memorial Hospital Group	4:0:5	IEVs in continuity with FVs and CIVs <sup>c</sup>	CIVs/infrarenal Ao and IVC <sup>c</sup>	150–500	N	N	Added 2h
Combined University of Bologna, Policlinico S. Orsola-Malpighi Group	3:0:0	IEVs	IEVs/DCIVs	352	N	Y	2.25
Combined Oxford University Hospitals Group	12:6:0	IEVs	Remote revascularization using forearm barking, and then anastomosed to IEVs/IMAs	180–240	Y	Y/N	13
Combined Duke University Group <sup>d</sup>	1:0:0	IEVs	Arteriovenous loop with saphenous vein to CFVs, then the loop is transected and anastomosed to the IEVs	NS	Y	Y/N	14

Abbreviations: Ao, aorta; CFVs, common femoral vessels; CIVs, common iliac vessels; DCIVs, deep circumflex iliac vessels; FVs, femoral vessels; IEVs, inferior epigastric vessels; IMA, internal mammary arteries; ITx, isolated intestinal transplant; IVC, inferior vena cava; MMVTx, modified multivisceral transplant; MVTx, multivisceral transplant; N, no; Y, yes.

<sup>a</sup>Data extracted from Bejarano et al.<sup>25</sup> Cipriani et al.<sup>26</sup> Weissbacher et al.<sup>36</sup> and Atia et al.<sup>6</sup>

<sup>b</sup>Data extracted from Levi et al.<sup>2</sup> Cipriani et al.<sup>26</sup> and Gerlach et al.<sup>35</sup>

<sup>c</sup>In two children who received MVTx arterial blood supply was from the donor distal Ao and the venous drainage from the infrahepatic vena cava. Infrarenal Ao and IVC were used in one child.

<sup>d</sup>Combined University of Groningen Group used the same surgical technique.

approaches of the last two groups (Duke and Oxford) provided the possibility of performing a synchronous revascularization of the intestinal and abdominal wall graft.<sup>37</sup>

### Discussion

AW-VCA has significantly impacted the outcomes of abdominal wall reconstruction, providing the surgeons with a new perspective of reconstruction previously considered unattainable or impossible. This scoping review presents the chronological advances in medicine-based evidence in this emerging field of cadaveric, animal, and human studies.

The cadaveric studies demonstrate that a large AW-VCA should preserve the iliofemoral cuff for adequate tissue perfusion and more importantly that the addition of DIEVs and DCIVs can significantly improve tissue perfusion of the flap.<sup>12,14</sup> In fact, all the reported human studies used donor IEVs and/or DCIVs accomplishing AW graft survival rates of ≥90% in at least one year.

To achieve a better immunological tolerance in organ transplant, bone marrow transplantation has been applied concomitantly, which has been shown to prevent graft rejection and to help prolong graft survival.<sup>16,41–43</sup> It is hypothesized that this beneficial effect is due to the suppression of alloantibody production.<sup>16</sup> In 2014, Singh et al proposed an osteomyofasciocutaneous flap by using vertebrochondral ribs; however, the authors discussed the possibility of using iliac crest as a bone marrow source to achieve better chimeric tolerance.<sup>13</sup> This novel concept opens AW-VCA to a new perspective for future surgical designs; however, important considerations such as increase in operative time and risk of ischemia complications should be taken into account.

The goal of abdominal wall reconstruction is to achieve a functional abdominal wall defect cover. For this, several considerations must be taken into account. Some of them are the general state of health, operative time, location and dimensions of the abdominal wall defect, components of the defect and its extension, and concomitant ITx or MVTx, among others. In this review, all patients had concomitant ITx or MVTx, and therefore, no ethical considerations regarding immunosuppressive therapy are considered. It is important to highlight that combination of transplants does not affect the immunosuppressive regimen.<sup>39</sup>

The abdominal wall flap dimensions ranged from 150 to 500 cm<sup>2</sup>. Interestingly, these dimensions could be covered with the traditional local, pedicled, and free flaps.<sup>44</sup> Additionally, local flaps can be used in combination with free or regional flaps if a massive abdominal wall defect is found.<sup>44</sup> However, these approaches have some important pitfalls such as donor site morbidity and poor aesthetic outcomes.<sup>44–48</sup> The use of a free anterolateral thigh flap with vascularized fascia lata can cover defects of 112 to 504 cm<sup>2</sup>; however, it was found that the quadriceps femoris muscle contraction forces might be decreased after the flap harvest.<sup>45</sup> Moreover, 25.9% of wound dehiscence/healing problems have been described to be present in gracilis myocutaneous flaps and 31.2% in flaps with a skin grafted

**Table 5** Abdominal wall graft survival estimations from the human studies

Combined research groups	n	Follow-up (mo)	Immunosuppressive medications		AW graft survival (%)
			Induction	Maintenance	
Miami <sup>a</sup>	10	5.9	Alemtuzumab	Tacrolimus + steroids	90
Bologna <sup>a</sup>	3	12	Alemtuzumab	Tacrolimus	100
Oxford <sup>a</sup>	18	12, 36	Alemtuzumab	Tacrolimus	94, 57
Duke <sup>a</sup>	1	12	Thymoglobulin	Tacrolimus + MMF + corticosteroid	100
Groningen <sup>a</sup>	1	12	Methylprednisolone and antithymocyte globulin	Tacrolimus, mycophenolate mofetil + prednisolone	100

Abbreviations: AW, abdominal wall; MMF, mycophenolate mofetil; n, number of AW transplants; NS, not specified.

<sup>a</sup>Data extracted from Bejarano et al,<sup>25</sup> Cipriani et al,<sup>26</sup> and Selvaggi et al<sup>24</sup>, Weissenbacher et al,<sup>36</sup> Erdmann et al,<sup>37</sup> Atia et al.<sup>6</sup> and Trentadue et al.<sup>38</sup>

donor site.<sup>46</sup> Therefore, the prevention of these complications plus the immunosuppressive requirement secondary to ITx and MVTx makes AW-VCA a feasible alternative for abdominal wall reconstruction.

Four surgical approaches have been described until now.<sup>2,26,32,37</sup> From Levi et al<sup>2</sup> in 2003 to Erdmann et al in 2019<sup>37</sup> and Atia et al in 2020, the surgical techniques had passed from macrovascular to microvascular approaches, from nonsynchronous to synchronous revascularization, and from two anastomoses to four anastomoses. The major goal behind all these changes is to reduce ischemia time and the overall surgical time to improve patient outcomes. Indeed, a long period of ischemia has been shown to increase the risk of graft rejection and failure.<sup>49,50</sup>

The first approach was presented in 2003 by the Miami group, which described an end-to-side macrovascular anastomosis of donor IEVs in continuity with the iliac vessels and FVs to recipient CIVs.<sup>2</sup> The major advantages in this technique are that it avoids microsurgery and it is a familiar technique performed by transplant surgeons.<sup>7</sup> The major disadvantage is the inability to perform synchronous revascularization, which resulted in increased cold ischemia and operative times.<sup>7</sup>

Later, in 2007 the Bologna group presented an end-to-end macrovascular anastomosis of donor IEVs with recipient IEVs or DCIVs.<sup>26</sup> This technique requires the use of microsurgery, sparing the use of CIVs and FVs; however, as in the Miami group, this procedure cannot provide synchronous revascularization. Then, in 2014 the Oxford group presented a new surgical approach that allowed synchronous revascularization, which consisted of a remote revascularization model using the forearm vessels as a temporary bank for a later transfer and anastomosis of the donor IEVs with the recipient IEVs or IMAs with an end-to-end approach.<sup>32</sup> The major advantage of this procedure is the decrease of ischemia time, but with the limitation of a prolonged surgical time, additional forearm-site morbidity, and possibility of a second procedure depending on the patient's physiological status.<sup>7</sup> Finally, in 2019 the Duke group presented the creation of an arteriovenous loop with the saphenous vein by performing an end-to-side anastomosis with the recipient common

femoral artery.<sup>6,37</sup> With this technique, synchronous revascularization is possible, which consequently reduces ischemia time and total operative time. However, it creates donor-site morbidity in the thigh, which can lead to seroma formation.<sup>7</sup>

All of these techniques seem to be feasible and safe; however, it is important to recognize that clinical candidates usually have a significant surgical history with extensive scarring, enterocutaneous fistulas, and distortion of the anatomic repairs that make the surgical technique challenging. Hence, a previous assessment of the vascular anatomy with imaging should be performed.

### Forthcoming

All AW-VCA performed until now are nonfunctional grafts, as they do not count with nerve supply. Neurotization of the abdominal wall graft is essential for patients to recover this organ's function and prevent atrophy. The future holds a promising evolution of a functional AW-VCA; however, the major challenge surgeons might face is distorted anatomy due to extensive scarring secondary to past surgical history. This approach might help balance the decision of surgery in an end-stage abdominal wall failure generated by large debilitating hernias, since it might justify the long-term use of immunosuppressive therapy.<sup>18</sup>

### Limitations

Limitations are attributed to the significant heterogeneity among studies and inconsistent reported clinical outcomes. Case reports or case series were also included in this review, which are observational studies that come with the inherited nature of nonrandomization and, consequently, susceptibility of presenting confounding bias. Also, there was a sample size overlap for human studies, which made a quantitative analysis unfeasible.

### Conclusion

AW-VCA is a safe and efficient alternative for patients with large and complex abdominal wall defects. Its use is recommended in patients undergoing concomitant ITx and MVTx,



due to the immunosuppressive requirements. Currently, four surgical techniques with specific advantages and disadvantages are available. The future of functional and osteomyocutaneous AW-VCA is promising, even though surgeons must face and overcome the challenge of a distorted anatomy. Future studies with a better level of evidence should be directed toward the assessment of the functionality of the graft, short- and long-term outcomes, and the differences between various surgical techniques.

#### Ethical Statement

The authors are accountable for all aspects of the work in ensuring that questions related to the accuracy or integrity of any part of the work are appropriately investigated and resolved.

#### Author Contributions

Conception and design were done by Oscar J. Manrique, Valeria P. Bustos, and Joseph M. Escandón. Administrative support was provided by Oscar J. Manrique. Provision of study materials or patients, collection and assembly of data, and data analysis and interpretation were done by Oscar J. Manrique, Valeria P. Bustos, and Joseph M. Escandón. All the authors were involved in writing the manuscript and gave approval to the final manuscript.

#### Conflict of Interest

None declared.

#### References

- Zanfi C, Cescon M, Lauro A, et al. Incidence and management of abdominal closure-related complications in adult intestinal transplantation. *Transplantation* 2008;85(11):1607–1609
- Levi DM, Tzakis AG, Kato T, et al. Transplantation of the abdominal wall. *Lancet* 2003;361(9376):2173–2176
- Moffett JM, Gedalia U, Xue AS, Heller L. Intraabdominal challenges affecting abdominal wall reconstruction. *Semin Plast Surg* 2012;26(01):8–11
- Barnes J, Issa F, Vrakas G, Friend P, Giele H. The abdominal wall transplant as a sentinel skin graft. *Curr Opin Organ Transplant* 2016;21(05):536–540
- Patel NG, Ratanshi I, Buchel EW. The best of abdominal wall reconstruction. *Plast Reconstr Surg* 2018;141(01):113e–136e
- Atia A, Hollins A, Erdmann RF, et al. Synchronous abdominal wall and small-bowel transplantation: a 1-year follow-up. *Plast Reconstr Surg Glob Open* 2020;8(07):e2995
- Atia A, Hollins A, Shamma R, et al. Surgical techniques for revascularization in abdominal wall transplantation. *J Reconstr Microsurg* 2020;36(07):522–527
- Tricco AC, Lillie E, Zarin W, et al. PRISMA extension for Scoping Reviews (PRISMA-ScR): checklist and explanation. *Ann Intern Med* 2018;169(07):467–473
- Murad MH, Sultan S, Haffar S, Bazerbachi F. Methodological quality and synthesis of case series and case reports. *BMJ Evid Based Med* 2018;23(02):60–63
- Wilke J, Krause F, Niederer D, et al. Appraising the methodological quality of cadaveric studies: validation of the QUACS scale. *J Anat* 2015;226(05):440–446
- Hooijmans CR, Rovers MM, de Vries RBM, Leenaars M, Ritskes-Hoitinga M, Langendam MW. SYRCLE's risk of bias tool for animal studies. *BMC Med Res Methodol* 2014;14(01):43
- Hollenbeck ST, Senghaas A, Turley R, et al. The extended abdominal wall flap for transplantation. *Transplant Proc* 2011;43(05):1701–1705
- Singh DP, Mavrophilipos VD, Zapora JA, et al. Novel technique for innervated abdominal wall vascularized composite allotransplantation: a separation of components approach. *Eplasty* 2014;14:e34
- Light D, Kundu N, Djohan R, et al. Total abdominal wall transplantation: an anatomical study and classification system. *Plast Reconstr Surg* 2017;139(06):1466–1473
- Broyles JM, Berli J, Tuffaha SH, et al. Functional abdominal wall reconstruction using an innervated abdominal wall vascularized composite tissue allograft: a cadaveric study and review of the literature. *J Reconstr Microsurg* 2015;31(01):39–44
- Ramirez AE, Cheng H-Y, Lao WW, et al. A novel rat full-thickness hemi-abdominal wall/hindlimb osteomyocutaneous combined flap: influence of allograft mass and vascularized bone marrow content on vascularized composite allograft survival. *Transpl Int* 2014;27(09):977–986
- Nasir S, Bozkurt M, Klimczak A, Siemionow M. Large antigenic skin load in total abdominal wall transplants permits chimerism induction. *Ann Plast Surg* 2008;61(05):572–579
- Jin J, Williams CP, Soltanian H, et al. Use of abdominal wall allotransplantation as an alternative for the management of end stage abdominal wall failure in a porcine model. *J Surg Res* 2010;162(02):314–320
- Yang J, Erdmann D, Chang JC, et al. A model of sequential heart and composite tissue allotransplant in rats. *Plast Reconstr Surg* 2010;126(01):80–86
- Quigley MA, Fletcher DR, Zhang W, Nguyen VT. Development of a reliable model of total abdominal wall transplantation. *Plast Reconstr Surg* 2013;132(04):988–994
- Lao WW, Wang Y-L, Ramirez AE, Cheng H-Y, Wei F-C. A new rat model for orthotopic abdominal wall allotransplantation. *Plast Reconstr Surg Glob Open* 2014;2(04):e136
- Grosu-Bularda A, Zamfirescu D, Stefanescu A, Stoica M, Lazarescu L, Lascar I. Developing an optimal experimental model for immunological studies in VCA: vascularized composite allotransplants based on femoral vessels in rats. *J Transl Med Res* 2016;21(02):131
- Tzakis AG, Tryphonopoulos P, Kato T, et al. Intestinal transplantation: advances in immunosuppression and surgical techniques. *Transplant Proc* 2003;35(05):1925–1926
- Selvaggi G, Levi DM, Kato T, et al. Expanded use of transplantation techniques: abdominal wall transplantation and intestinal autotransplantation. *Transplant Proc* 2004;36(05):1561–1563
- Bejarano PA, Levi D, Nassiri M, et al. The pathology of full-thickness cadaver skin transplant for large abdominal defects: a proposed grading system for skin allograft acute rejection. *Am J Surg Pathol* 2004;28(05):670–675
- Cipriani R, Contedini F, Santoli M, et al. Abdominal wall transplantation with microsurgical technique. *Am J Transplant* 2007;7(05):1304–1307
- Lauro A, Dazzi A, Ercolani G, et al. Results of intestinal and multivisceral transplantation in adult patients: Italian experience. *Transplant Proc* 2006;38(06):1696–1698
- Lauro A, Zanfi C, Ercolani G, et al. Twenty-five consecutive isolated intestinal transplants in adult patients: a five-yr clinical experience. *Clin Transplant* 2007;21(02):177–185
- Lauro A, Arpinati M, Zanfi C, et al. Extracorporeal photopheresis for chronic GVHD: case report after adult bowel-abdominal wall transplantation. *Transplantation* 2013;96(02):e9–e10
- Allin BSR, Ceresa CDL, Issa F, et al. A single center experience of abdominal wall graft rejection after combined intestinal and abdominal wall transplantation. *Am J Transplant* 2013;13(08):2211–2215

- 31 Mannu GS, Vaidya A. An interesting rash following bowel and abdominal wall transplantation. *BMJ Case Rep* 2013;2013:bcr2013200951
- 32 Giele H, Bendon C, Reddy S, et al. Remote revascularization of abdominal wall transplants using the forearm. *Am J Transplant* 2014;14(06):1410–1416
- 33 Mannu GS, Vaidya A. Graft versus host disease following small bowel and abdominal wall transplantation. *BMJ Case Rep* 2014:bcr2014205983
- 34 Mannu GS, Vaidya A. Thermal trauma to abdominal wall vascularised composite allotransplant. *BMJ Case Rep* 2014:bcr2013202692
- 35 Gerlach UA, Vrakas G, Sawitzki B, et al. Abdominal wall transplantation: skin as a sentinel marker for rejection. *Am J Transplant* 2016;16(06):1892–1900
- 36 Weissenbacher A, Vrakas G, Chen M, et al. De novo donor-specific HLA antibodies after combined intestinal and vascularized composite allotransplantation: a retrospective study. *Transpl Int* 2018;31(04):398–407
- 37 Erdmann D, Atia A, Phillips BT, et al. Small bowel and abdominal wall transplantation: a novel technique for synchronous revascularization. *Am J Transplant* 2019;19(07):2122–2126
- 38 Trentadue G, Kats-Ugurlu G, Blokzijl T, et al. Safe and successful treatment of acute cellular rejection of an intestine and abdominal wall transplant with vedolizumab. *Transplant Direct* 2020;6(02):e527
- 39 Haveman JW, Tempelman TM, Hofker HS, Khoe PC, Dijkstra G, Werker PM. Eerste dunnedarm-buikwandtransplantatie in Nederland. *Ned Tijdschr Geneesk* 2016;160(16):A9788
- 40 ClinicalTrials.gov. Abdominal Wall Transplant. Accessed December 23, 2020 at: <https://clinicaltrials.gov/ct2/show/NCT03310905?cond=abdominal+wall+transplant&draw=2&rank=1>
- 41 Kawai T, Cosimi AB, Spitzer TR, et al. HLA-mismatched renal transplantation without maintenance immunosuppression. *N Engl J Med* 2008;358(04):353–361
- 42 Scandling JD, Busque S, Dejbakhsh-Jones S, et al. Tolerance and chimerism after renal and hematopoietic-cell transplantation. *N Engl J Med* 2008;358(04):362–368
- 43 Barth RN, Rodriguez ED, Munding GS, et al. Vascularized bone marrow-based immunosuppression inhibits rejection of vascularized composite allografts in nonhuman primates. *Am J Transplant* 2011;11(07):1407–1416
- 44 Roubaud MS, Baumann DP. Flap reconstruction of the abdominal wall. *Semin Plast Surg* 2018;32(03):133–140
- 45 Kuo Y-R, Kuo M-H, Lutz BS, et al. One-stage reconstruction of large midline abdominal wall defects using a composite free anterolateral thigh flap with vascularized fascia lata. *Ann Surg* 2004;239(03):352–358
- 46 Purnell CA, Lewis KC, Mioton LM, et al. Donor-site morbidity of medial and lateral thigh-based flaps: a comparative study. *Plast Reconstr Surg Glob Open* 2016;4(11):e1012
- 47 Lutz BS, Khawaja S, Ingianni G. Donor site morbidity after rectus abdominis muscle flaps. *Eur J Plast Surg* 1997;20(04):173–180
- 48 Lee K-T, Mun G-H. A systematic review of functional donor-site morbidity after latissimus dorsi muscle transfer. *Plast Reconstr Surg* 2014;134(02):303–314
- 49 Postalcioglu M, Kaze AD, Byun BC, et al. Association of cold ischemia time with acute renal transplant rejection. *Transplantation* 2018;102(07):1188–1194
- 50 Debout A, Foucher Y, Trébern-Launay K, et al. Each additional hour of cold ischemia time significantly increases the risk of graft failure and mortality following renal transplantation. *Kidney Int* 2015;87(02):343–349
- 51 Moher D, Liberati A, Tetzlaff J, Altman DG. The PRISMA Group. Preferred Reporting Items for Systematic Reviews and Meta-Analyses: The PRISMA Statement. *PLoS Med* 2009;6(07):e1000097. Doi: 10.1371/journal.pmed1000097