



# Achieving Correct Axis and Good Depth in Gender Affirming Vaginoplasties by Penile-Perineoscrotal Flap Vaginoplasty

Richie Gupta<sup>1</sup> Rajat Gupta<sup>1</sup>

<sup>1</sup>Department of Plastic, Aesthetic and Reconstructive Surgery, and Gender Identity Clinic, Fortis Hospital Shalimar Bagh, Delhi, India

Address for correspondence Richie Gupta, MS, MCh, A1/11, Jiwan Jyoti Apartments, Kabir Dass Marg, Pitampura, Delhi 110034, India (e-mail: guptarichie@yahoo.com).

Indian J Plast Surg 2022;55:188–195.

## Abstract

**Objectives** Vaginoplasty as a part of feminizing genitoplasty (FG) in transwomen helps alleviate gender dysphoria and improves mental health, sexual and psychosocial functioning, and quality of life in these individuals. Penile inversion technique (PSFV) remains the gold standard procedure for FG with least morbidity but has inherent limitations often resulting in inadequate depth and incorrect (posteroinferior) vaginal axis, precluding sexual intercourse.

**Material and Methods** Over the past 27 years, the senior author has refined his technique considerably incorporating several modifications penile perineo-scrotal flap vaginoplasty (PPSFV) to overcome the limitations in PSFV. Most of these modifications were in place by March 2015. Out of 630 primary FGs, retrospective review of all PPSFV with minimum 6 months follow-up operated during the period March 2015 to July 2020 was done for intra and postoperative complications.

**Results** There were 183 patients who underwent PPSFV during the study period. Average follow-up was 31 (6–62) months. There were no cases of injury to bladder, rectum, urethral stenosis, or neovaginal prolapse. Average operative time was 4 hours and eight (4.37%) patients required blood transfusion. The vaginal depth was 13 to 14 cm or more in 159 (86.88%), 10 to 12 cm in 17 (9.29%), and 7.5 to 9 cm in seven (3.82%) patients. Ten (5.46%) patients complained of intravaginal hair growth. Touch up procedures in the form of anterior commissure and labia plasty were required in 13 (7.10%) patients. All (100%) patients had good clitoral sensitivity and preserved posterosuperior vaginal axis. One-hundred thirty nine (75.96%) patients were able to have satisfactory penetrative sexual intercourse, while 39 (21.31%) had not attempted intercourse and five (2.73%) complained of poor sexual experience on account of inadequate vaginal dimensions.

**Conclusion** PPSFV addresses the limitations in PSFV and results in good vaginal depth and posterosuperior axis, which facilitates penetrative sexual intercourse, at the same time, avoiding potential complications of procedures such as intestinal vaginoplasties.

## Keywords

- ▶ vaginoplasty
- ▶ penile inversion vaginoplasty
- ▶ feminizing genitoplasty
- ▶ gender affirmation surgery
- ▶ gender incongruence
- ▶ gender dysphoria

published online  
July 18, 2022

Issue Theme Gender  
Incongruence

DOI <https://doi.org/10.1055/s-0041-1740530>.  
ISSN 0970-0358.

© 2022. Association of Plastic Surgeons of India. All rights reserved. This is an open access article published by Thieme under the terms of the Creative Commons Attribution-NonDerivative-NonCommercial-License, permitting copying and reproduction so long as the original work is given appropriate credit. Contents may not be used for commercial purposes, or adapted, remixed, transformed or built upon. (<https://creativecommons.org/licenses/by-nc-nd/4.0/>)  
Thieme Medical and Scientific Publishers Pvt. Ltd., A-12, 2nd Floor, Sector 2, Noida-201301 UP, India

## Introduction

Recent studies<sup>1-4</sup> indicate a sharp rise in the number of patients with gender incongruence (GI) with resultant increase in number of patients opting for gender affirming procedures including feminizing genitoplasty (FG). FG is a complex, usually single-staged procedure inclusive of vaginoplasty, clitoroplasty, labiaplasty, vestibuloplasty, shortening of urethra, and siting of urinary meatus to feminine location, orchidectomy, and corporectomy (except corpora cavernosa, all other penile components are utilized for construction of female pudenda). The procedure is known to alleviate gender dysphoria (GD) and associated mental health issues with significant increase in quality of life of these individuals. Vaginoplasties are also performed for indications like partial or complete agenesis, post malignant extirpation, post traumatic and other conditions, though the commonest indication remains, as part of FG. The first FG procedures in transwomen (TW) were performed on Dorchen Richter<sup>5</sup> and more famous Lile Elbe<sup>6</sup> (The Danish Girl) in 1931, likely with the use of skin grafts. Gillies<sup>7</sup> was the first to use penile skin flap for lining of NV cavity in a transwoman. Since then, several authors have modified the procedure to improve results (► **Table 1**).<sup>7-15</sup> As there are significant differences in biologic and TW in terms of pelvic anatomy<sup>16</sup> (► **Table 2**), only thinnest possible flaps can be used for lining in the latter population. As a result, inverted penile skin with or without scrotal skin, split and full thickness skin grafts, intestinal segments such as sigmoid, ileum, ileocecal junction, jejunum, and less common methods such as vascularized peritoneum, amnion, tissue engineered vagina, buccal mucosa, stem cell spray, etc. have been used to provide the lining of neovaginal cavity in TW. Despite the multiple methods in use/having been used for lining the neovaginal cavity, the method for dissecting a space/ cavity between bladder and vagina via a perineal approach has remained constant.

### Goals of Feminizing Genitoplasty

Normal vagina is a fibromuscular tube lined with non-keratinized stratified squamous epithelium with dimensions of 7.5 cm along anterior and 9 cm along posterior wall. It is

inclined in a posterosuperior direction. The lining is lubricated by mucus from cervical glands, as there are no glands in the vaginal lining. The procedure of FG intends to create a pudendovaginal complex which is aesthetic and resembles the normal. It should be free of scars and neuromas, sensate at least at introitus, of adequate depth and with neither absent, nor excessive lubrication. The neovaginal axis should be directed posterosuperiorly to enable normal intercourse.<sup>17</sup>

## Materials and Methods

The authors have performed 630 primary gender affirming vaginoplasties over past 27 years. Of these, 505 (80.16%) cases consisted of penile skin flap inversion vaginoplasties and modifications, inclusive of current technique. One-hundred twenty three (19.52%) were sigmoid and two (0.32%) peritoneal (started recently in 2021) vaginoplasties. Most of the modifications described below were in place by March 2015. A retrospective review of case records of all patients undergoing penile-perineoscrotal flap vaginoplasty (the modified technique, as described below) as part of primary FG in the period from March 2015 to July 2020 with minimum follow-up of 6 months were included in this retrospective review. There were 183 patients who met the inclusion criteria. Mean follow-up was 31 months and maximum follow-up 5 years and 2 months. The case records of these patients were analyzed for intra and postoperative complications. The study was approved by Institutional Review Board.

Inclusion criteria (including recommendations from WPATH SOCs 7<sup>18</sup> and ISOC 1<sup>19</sup>):

1. Has undertaken feminizing hormone therapy for minimum 12 months.
2. Has lived in desired gender role (feminine) full time for minimum 12 months.
3. Is above 18 years of age.
4. Has stopped hormone therapy at least 4 weeks before surgery.

**Table 1** Different types of procedures using penile skin flap to line part or whole of neovaginal cavity

Author, year, reference	Procedure
Gillies and Millard 1957, 7	The first to use penile skin flap (PSF) for NVP.
Jones et al 1968, 8	PSF + posteriorly based scrotal skin flap for NVP.
Pandya and Stuteville 1973, 9	Included glans skin in PSF tube in circumcised patients, to offset the absence of prepuce, and increase flap length.
Foerster and Reynolds 1979, 10	PSF for anterior vaginal wall and labia minora, skin graft for posterior wall.
Meyer and Kesselring 1980, 11	Use of penile skin as an island flap.
Eldh, 1993, 12	PSF + longer scrotal skin flap
Perovic, 1993, 13	PSF tube + urethral flap + ventral part of glans as pseudocervix + modified Stamey fixation to prevent prolapse of neovagina.
Perovic et al 2000, 14	In above procedure, sacrospinous ligament fixation instead of Stamey fixation.
Reed, 2011, 15	PSF tube + scrotal skin graft extension of tube + Stamey fixation.

**Table 2** Differences in procedures of vaginoplasty (NV) in transwomen vs biologic women

Comparison of neovaginoplasty between trans and biologic women	Neovaginoplasty in transwomen	Neovaginoplasty in biologic women	Implications
Differences in bony pelvis <sup>16</sup>	Inter-ischioramic distance is $3.95 \pm 0.25$ cm	Inter-ischioramic distance is $5.2 \pm 0.36$ cm.	There are chances of compression of NV preventing sexual intercourse, even in the presence of adequate depth. Hence, only thinnest flaps/grafts can be used for reconstruction.
Differences in pelvic soft tissue	There is no rectovesical space. It is just a septum.	Pelvis is roomier with greater space in uterovesical and rectouterine pouches.	The dissection of NV cavity is easier in biologic women. As the tissues are lax, techniques such as Vecchietti, Lap Vecchietti, and lap-assisted balloon dissection are often employed in biologic women.
Differences in pudendal organs	Organs such as penis and scrotum are present.	Organs such as clitoris, labia majora, and minora are present.	In transwomen, nearly all tissue in penis and scrotum are used for reconstruction of female pudenda, and vagina with the exception of corpora cavernosa and testes. Female pudenda do not require reconstruction in biologic women.

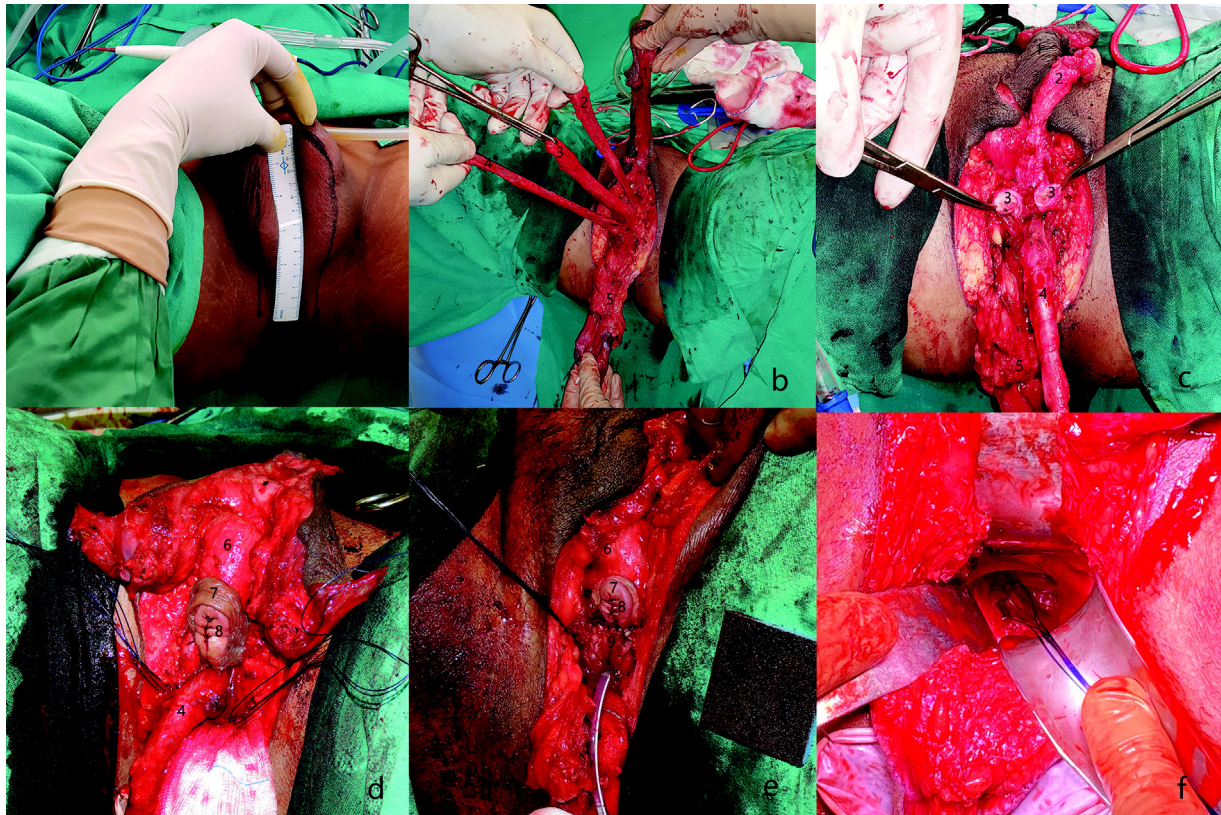
5. Has referral letters from two different mental health professionals confirming the diagnosis GD/incongruence and recommending genital gender affirmation surgery.
6. If the patient is a smoker, then she has stopped smoking at least 1 month before surgery.
7. Surgical steps included all the modifications in authors technique as described below.
8. Minimum postoperative follow-up of 6 months.

### Our Procedure of Penile-Perineoscrotal Flap Vaginoplasty

The procedure and many modifications are described in detail in earlier publications. All the modifications described below are being used together since March 2015 (→ **Figs. 1, 2**):

1. Raising a perineoscrotal flap to augment the penile skin flap. The perineoscrotal flap is marked with its base 2.5 cm anterior to the anterior margin of anal sphincter. The flap is 5 cm wide-2.5 cm on either side of midline raphe. It is marked with a gentle anterior traction on scrotum by assistant, to a length of 15 cm, gently tapering at the end. The flap incorporates central perineal and posterior scrotal skin and soft tissue, and is raised in the plane of bulbospongiosus, to the region of perineal body posteriorly.
2. Bilateral testicles are removed, and full length of cords are retained for incorporation in ipsilateral labia majora instead of high ligation of spermatic cords at external inguinal ring. The retained cords are sited in ipsilateral labium majus, giving bulk to these structures.
3. Penile disassembly and resection of corpora cavernosa is performed conventionally.

4. Neoclitoris is formed by dorsal part of trimmed glans penis on dorsal neurovascular pedicle. The pedicle includes Buck's fascia and dorsal tunica albuginea. The neoclitoris is sited at the level of combined corporal stumps and sutured to these with folding of dorsal part of prepuce in a manner resembling clitoral hood. The neoclitoral pedicle is brought upward in a gentle curve and held in midline at the level of mons with a couple of edge sutures. The pedicle is then rolled into a tube and fixed at midline with a few sutures thus simulating clitoral body.
5. Labia minora construction: the remaining ventral glans wings together with ventral part of prepuce is sutured to the lateral margins of dorsal urethral flap medially, and later, with margins of slit in penile skin flap laterally, to form labia minora.
6. Vestibuloplasty and urethral meatus: urethra is transected at a level 4 cm distal to optimum feminine location at bulb. Bulbospongiosus fibers are removed from the exposed part of bulb and a vertical incision is given in it to expose the catheter. This is carried upward to the end of divided urethra. The resultant dorsal-based urethral flap around 4 cm long and 3.5 cm wide is sutured superiorly to the inferior aspect of neoclitoris and laterally to glans wings and ventral prepuce. This flap lines the vulvar vestibule. The other margins of incision in bulb are everted and sutured to the bulb and sutured later to the remaining margins of slit in penile skin flap to form labia minora.
7. Cavity dissection: This is done conventionally through the perineal body, in the plane between prostate and rectum, superiorly till pelvic peritoneum is reached.



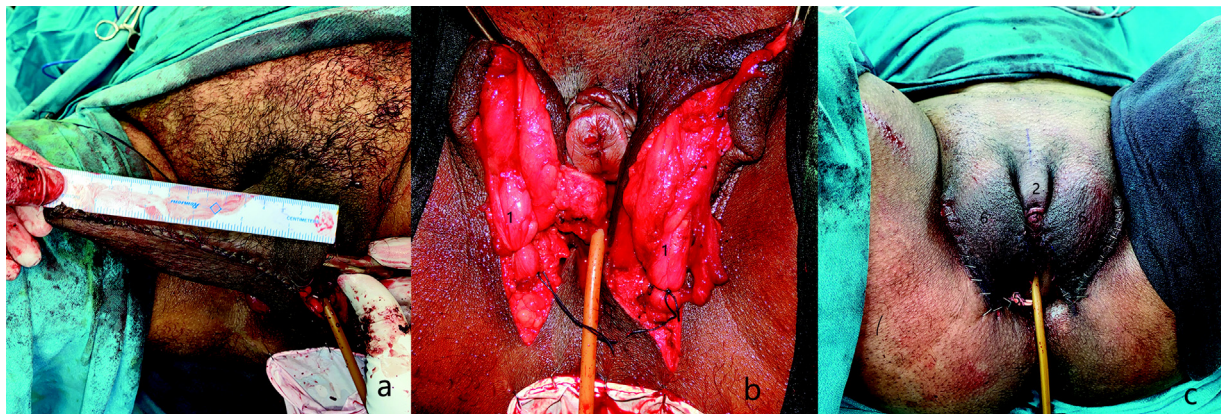
**Fig. 1** (a) Marking of perineoscrotal flap. The flap is marked 15 cm long and 5-cm wide. Its base is 2.5-cm anterior to anus. (b) Penis disassembled done into its four components. (c) Bilateral corpora cavernosa shortened to just under pubic bone. (d) Neoclitoris formed. (e) Urethra shortened and used to reconstruct part of vestibule. (f) Vaginal cavity dissected and suture taken from right sacrospinous ligament. (1) Penile skin dartos tube divided ventrally; (2) glans penis flap raised on penile dorsal NV bundle with Buck's fascia and dorsal tunica albuginea prepuce; (3) Bilateral corpora; (4) Urethra with corpus spongiosum; (5) Perineoscrotal flap; (6) Body of neoclitoris; (7) Neoclitoral hood; (8) Neoclitoral glans; (9) Dorsal part of urethral stump reconstructing vestibule.

The rectovesical pouch peritoneal reflection lies around 7.5 cm from anorectal junction, at the level of mid third of rectum. This is loosely attached to rectum and can easily be stripped away, to attain a depth of 14 to 15 cm.

8. Sacrospinous ligament fixation of neovagina: A PDS suture is taken through one of the sacrospinal ligaments

(usually right), at least 2.5 cm medial to ischial spine, to avoid injuring pudendal NV bundle, which always lies within 0.5 cm of ischial spine. A Deschamps ligature carrier is very helpful for this manoeuvre.

9. Construction of vaginal lining: the penile skin flap is now sutured to perineoscrotal skin flap with 3/0 Vicryl suture, to form neovaginal lining. The NV lining is fixed in



**Fig. 2** (a) 15-cm long and wide neovaginal lining formed by suturing of penile skin dartos flap with perineoscrotal flap. (b) Retained long lengths of cords providing bulk to labia majora. (c) Immediate postoperative perineal view. (1) Retained long length of cords; (2) Neoclitoral body; (3) Neoclitoral glans and prepuce; (4) Labia majora; (5) Pack inside vaginal cavity; (6) Labia majora.



**Fig. 3** A set of dilators used for assessing intraoperative neovaginal depth and postoperative dilatation.

position with the help of previously placed sacrospinal ligament suture. This helps prevent early postoperative prolapse of NV lining with any straining and considerably eases the early postoperative care including dilatation.

10. Exteriorization of clitoris and neourinary meatus: an incision/slit is made in midline in PSF, avoiding the branches of external pudendal vessels, for exteriorization of neoclitoris and urinary meatus.
11. Construction of labia majora: done conventionally by pulling the lateral remnants of scrotal skin dartos flaps posteriorly to be sutured on either side of base of perineoscrotal skin flap.

#### Mold and Dressing

The NV cavity is checked for depth with the help of measured dilators (►Fig. 3, ►Video 1) and packed with a sterile glove containing U foam. The area is then covered with conventional perineal dressing. Epidural analgesia and thromboembolic deterrent stockings are continued for 3 days. Patient is discharged between day 3 to 5 postoperative.

#### Video 1

Immediate intraoperative measurement and demonstration of neovaginal depth using a dilator, which is between 13 and 14 cm, in this case. Online content including video sequences viewable at: <https://www.thieme-connect.com/products/ejournals/html/10.1055/s-0041-1740530>.

#### Postoperative Regimen

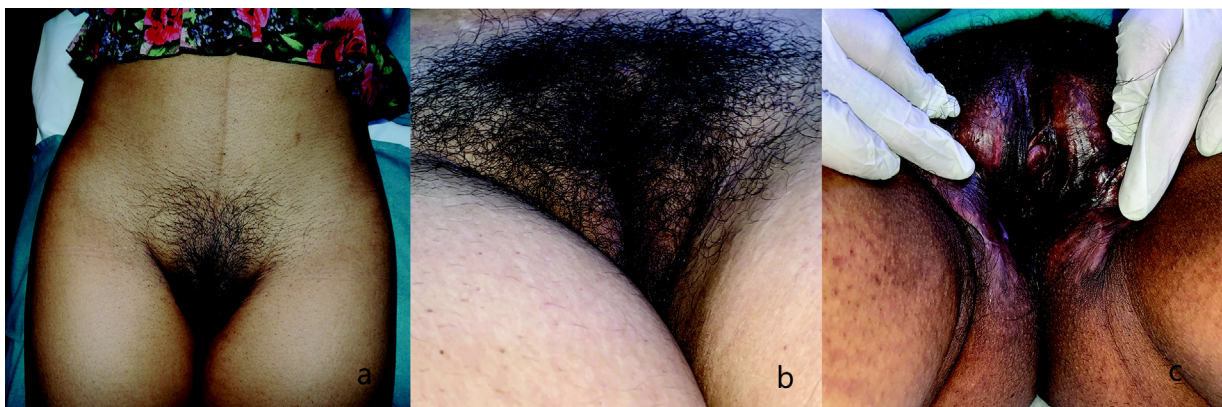
On day 7 postoperatively, the vaginal mold is removed, cavity is irrigated with betadine saline and dilatation is performed. The patient is taught to self-dilate with graduated dilators. Urinary catheter is removed at same sitting. Patient continues self-dilatation (►Video 2) for 15 minutes, three times a day. Dilatation is followed by irrigation of NV cavity. This is carried on till 3 months postoperative, at which time, sexual intercourse is allowed. In patients, who do not have a partner, dilatation continues with reduced frequency.

#### Video 2

Self dilatation of neovaginal cavity, being performed by the patient at 2 weeks postoperative in this video. Dilatation is initiated at 1-week postoperative. Online content including video sequences viewable at: <https://www.thieme-connect.com/products/ejournals/html/10.1055/s-0041-1740530>.

#### Results

In this cohort of 183 patients, whose surgery was performed between March 2015 and July 2020, the average age was 29 (18–52) years. The average follow-up was 31(6–62) months (►Fig. 4). The average surgical time was 4 hours. There was postoperative bleeding in one patient, which required return



**Fig. 4** (a) Late postoperative view; (b) Late postoperative view in another patient; (c) Late postoperative view of pudendal structures.

to OR on postoperative day 1. The bleeder was from tunica albuginea part of neoclitoral pedicle. Eight patients including the above, required blood transfusion. There was no case with loss of neoclitoris. There were six partial flap losses in five patients (four penile skin flap only and one penile skin flap + perineoscrotal skin flap-double partial flap loss). The patient with double partial flap loss required return to OR on seventh day postoperative, for debridement, suturing, and VAC application. The neovaginal cavity was skin grafted 3 days after debridement and VAC reapplied. This patient had a loss of vaginal depth to 7.5 cm at 8 months follow-up. There were six more cases of loss of vaginal depth, with final depth ranging from 7.5 to 9 cm, one of whom was a case of myasthenia gravis, and unable to adhere to the dilatation protocol. Seventeen (9.29%) patients had vaginal depth of 10 to 12 cm and remaining 159 (86.88%) being in the range of 13 to 14 cm (our largest dilator) or more at last follow-up (►Video 1). There were no cases of injury to bladder or rectum. There were no cases of urinary obstruction/meatal stenosis. There was no case of neovaginal prolapse. Ten (5.46%) patients complained of neovaginal hair growth, all of whom had been advised preoperative laser hair removal, but had opted out of it, on account of severe dysphoria and the need for early surgery. There was no case of introital stenosis. Touch up procedures were performed in 13 (7.10%) patients and consisted of labial reduction and anterior commissure-plasty at more than 6 months postoperative. All patients had good neoclitoral sensitivity. One-hundred thirty nine (75.96%) patients had satisfactory penetrative sexual intercourse, 39 (21.31%) had not attempted intercourse, due to lack of a partner or being uninclined for various reasons. Five patients (2.73%) complained of poor sexual experience on account of inadequate vaginal depth.

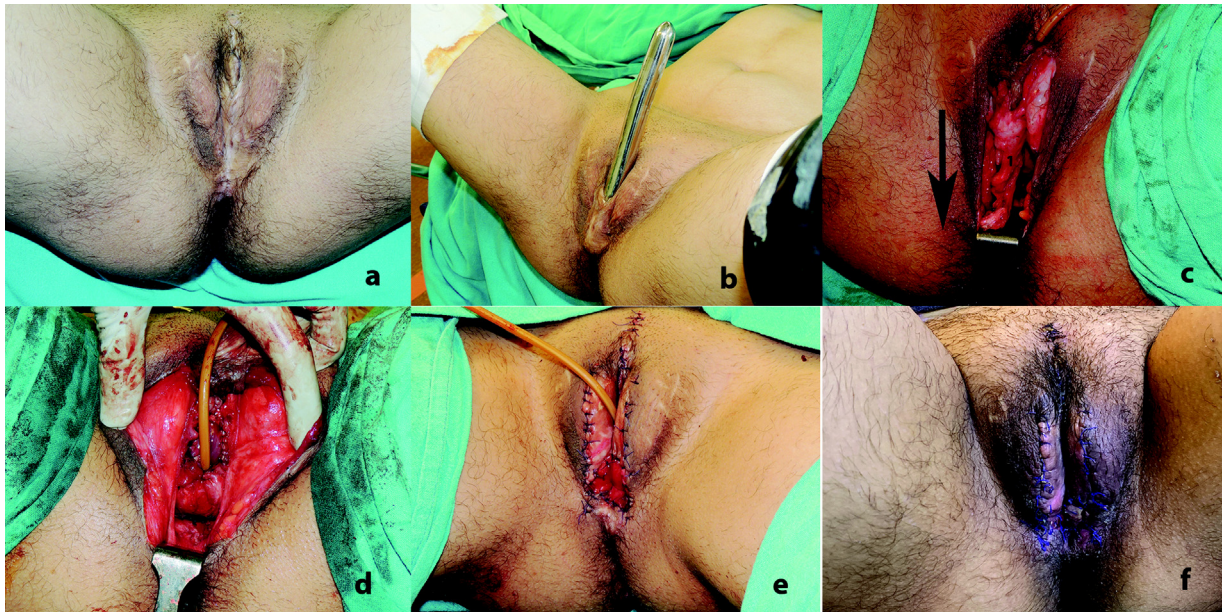
## Discussion

Neovaginoplasty, as part of FG has been performed with the help of split and full thickness skin grafts, penile inversion techniques with various modifications, pedicled intestinal flaps and peritoneal methods. Skin grafting techniques are prone to poor graft take with resultant granulations and prolonged discharge, loss of vaginal depth and shrinkage due to cavity and graft contracture, need for life-long dilatation, no lubrication, poor sensation, increased incidence of condylomatosis, human papillomavirus infections and carcinoma.<sup>20,21</sup> In contrast, being flap based, the penile inversion vaginoplasties are less prone to shrinkage, and infections and not dependent on graft take. Intestinal vaginoplasties are prone to prolonged foul smelling mucorrhoea, mucosal prolapse and may have complications like diversion/ulcerative colitis, adenocarcinoma, introital structure, and complications related to bowel and abdominal surgery such as bowel necrosis, prolonged ileus, anastomotic leak, peritonitis, etc.<sup>20,22</sup> In contrast, penile inversion vaginoplasties have less morbidity, as no abdominal procedure is required. Peritoneal vaginoplasty, though not a new procedure, has been performed in only a small number of patients, and

the long-term results of neovagina are unknown. Penile inversion is the commonest procedure used for FG. Use of penile skin flaps is a significant advance over skin grafts. There is less tendency for contracture. Sensate and usually hairless skin lines vagina. It is done in many ways: (1) abdominally based penile skin tube, (2) penile skin flap combined with perineal/scrotal skin flap, (3) penile skin flap augmented with urethral flap, (4) penile/ urethral flap extended with scrotal or other skin graft.

Authors initially used a penile skin flap only vaginoplasty, but they found that in this procedure, the flap tube needed to be pulled with high tension posteroinferiorly to reach the created NV cavity. This changed the axis of NV from the desired posterosuperior (as seen in standing position) to posteroinferior or inferior, resulting in patients reporting difficulty with intercourse, as seen in this patient operated elsewhere (►Fig. 5). Also, due to relentless anterior pull, with healing, neoclitoris and urethral meatus too may get pulled to ectopic anterosuperior location. Also, the surface area of penile skin lining is limited. In a penile skin flap dissected from a penile length of average 5 to 6 inches, 2 inches gets consumed in negotiating and going around pubic symphysis, thus leaving only 3 to 4 inches available to line the neovaginal cavity.<sup>15</sup> In circumcised patients, in those on hormone therapy and in those, who had been on puberty blockers, even lesser length is available. Hence, use of only penile skin flap to line neovaginal cavity will result in a shallow vagina in most cases irrespective of the size of dissected cavity. Harvesting of perineoscrotal skin flap, adds a 15 × 5 cm lining to neovagina, which depending on penile size, forms 50 to 60% of neovaginal lining, and the ability to line even the deepest dissected cavity. Since the flap is posteriorly based, it also balances the anterior pull on the penile skin flap, thus maintaining the neovaginal axis. Employment of perineoscrotal skin flap also ensures a posterior placement of vaginal introitus, which is necessary, to allow penetration in the narrow bony pelvis in TW. However, a limitation of this procedure remains. Even with the addition of perineoscrotal flap, it is often impossible to obtain a vaginal depth of greater than 6 to 7 inches (personal experience). In patients who desire vaginal depth in the range of 7 to 8 inches or greater, alternate procedures such as sigmoid or peritoneal lined vaginoplasties are recommended by the authors.

Our series results as detailed above compare favorably with previously published reports of complications during neovaginoplasty such as rectal injury (0.4–4.5% cases),<sup>14,15,23–29</sup> urethral injury (1.1–3.6% cases),<sup>27,30</sup> postoperative bleeding requiring transfusion (4.8%),<sup>30</sup> minor necrosis (24.6% cases)<sup>30</sup> and major necrosis (0.6% cases),<sup>30</sup> reoperation (1.5%),<sup>30</sup> introital/vaginal stenosis (1.2–12%),<sup>31,32</sup> and urethral meatus stenosis (1–39%).<sup>24,27</sup> This may be due to the use of a refined procedure with many modifications in place in this cohort, surgeries by a single surgical team consisting of a senior and junior plastic surgeon and a GI surgeon with assigned tasks and set protocols. Many authors who use penile skin flap only, have employed additional skin grafts to extend the neovaginal lining,<sup>15,30,33</sup> with risk of uncertain take, which may predispose these



**Fig. 5** Penile skin flap vaginoplasty done elsewhere. Inadequate cavity dissection and short retracted penile tube in a subcutaneous location and with faulty posteroinferior axis precluding sexual intercourse. (a) Perineal appearance depicting poor formation and abnormal location of pudendal organs; (b) the wrong axis and location, and inadequate depth of vaginal canal; (c) on dissection, the short, fibrosed and ectopically located vaginal canal. (d) Clitoris has been relocated posteroinferiorly, urinary meatus sited correctly, and vestibule constructed (e) revision has been completed. Vaginal cavity dissected and lined with sigmoid colon. (f) Two weeks postoperative appearance.

cases to neovaginal cavity contracture, intravaginal scarring (20%), loss of depth and granulations (26%) and pain (20%) extending for prolonged periods.<sup>33</sup>

The senior author has been carrying out gender affirmative surgery since past 27 years. Over a period of time, under the stimulus of increasing surgical confidence and familiarity with tissue vascularity as well as increasing demands with reference to aesthesia by patients, authors technique has undergone significant changes. The addition of perineoscrotal flap in dimension of  $15 \times 5$  cm, together with other modifications as detailed above applied sequentially, reduces some disadvantages, which are inherent to the technique of penile skin flap inversion vaginoplasty, as well as result in better sculpting of pudendal organs such as neoclitoris, clitoral hood, and labia minora. Modifications of penile skin flap vaginoplasties remain the dominant procedures today in the field of gender affirming FG.

## Conclusion

FG is an integral part of gender affirmation surgery in TW. It helps alleviate dysphoria, improves body image and quality of life in their journey toward gender congruence. Penile inversion vaginoplasty remains the dominant procedure in this field, with minimal morbidity, but has many inherent disadvantages. In this paper, the authors present their version of the technique with many modifications to improve the aesthesia, sexual and urinary functions in the set patient population.

**Financial Disclosure**  
None.

**Conflict of Interest**  
None declared.

## References

- Berli JU, Knudson G, Fraser L, et al. What surgeons need to know about gender confirmation surgery when providing care for transgender individuals: a review. *JAMA Surg* 2017;152(04):394–400
- Arcelus J, Bouman WP, Van Den Noortgate W, Claes L, Witcomb G, Fernandez-Aranda F. Systematic review and meta-analysis of prevalence studies in transsexualism. *Eur Psychiatry* 2015;30(06):807–815
- Conron KJ, Scott G, Stowell GS, Landers SJ. Transgender health in Massachusetts: results from a household probability sample of adults. *Am J Public Health* 2012;102(01):118–122
- Winter S, Diamond M, Green J, et al. Transgender people: health at the margins of society. *Lancet* 2016;388(10042):390–400
- Dora Richter from Wikipedia. Accessed March 15, 2021 at: [https://en.wikipedia.org/wiki/Dora\\_Richter](https://en.wikipedia.org/wiki/Dora_Richter)
- Lile Elbe from Wikipedia. Accessed March 15, 2021 at: [https://en.wikipedia.org/wiki/Lili\\_Elbe](https://en.wikipedia.org/wiki/Lili_Elbe)
- Gillies H, Millard RD Jr. Genitalia. In: *The Principles and Art of Plastic Surgery*. London: Butterworth; 1957:368–388
- Jones HW Jr, Schirmer HKA, Hoopes JE. A sex conversion operation for males with transsexualism. *Am J Obstet Gynecol* 1968;100(01):101–109
- Pandya NJ, Stuteville OH. A one-stage technique for constructing female external genitalia in male transsexuals. *Br J Plast Surg* 1973;26(03):277–282
- Foerster DW, Reynolds CL. Construction of natural appearing female genitalia in the male transsexual. *Plast Reconstr Surg* 1979;64(03):306–312
- Meyer R, Kesselring UK. One-stage reconstruction of the vagina with penile skin as an island flap in male transsexuals. *Plast Reconstr Surg* 1980;66(03):401–406
- Eldh J. Construction of a neovagina with preservation of the glans penis as a clitoris in male transsexuals. *Plast Reconstr Surg* 1993;91(05):895–900, discussion 901–903

- 13 Perović S Male to female surgery: a new contribution to operative technique. *Plast Reconstr Surg* 1993;91(04):703–711, discussion 712
- 14 Perovic SV, Stanojevic DS, Djordjevic ML. Vaginoplasty in male transsexuals using penile skin and a urethral flap. *BJU Int* 2000;86(07):843–850
- 15 Reed HM. Aesthetic and functional male to female genital and perineal surgery: feminizing vaginoplasty. *Semin Plast Surg* 2011;25(02):163–174
- 16 Fang RH, Chen TJ, Chen TH. Anatomic study of vaginal width in male-to-female transsexual surgery. *Plast Reconstr Surg* 2003;112(02):511–514
- 17 Gupta R, Gupta R, Mehta R, Aggarwal A, Mathur A. Gender Dysphoria. In: Agrawal K, Mahajan RK, eds. *Textbook of Plastic, Reconstructive and Aesthetic Surgery Volume IV*. Noida, Uttar Pradesh: Thieme Publishers; 2019:259–293
- 18 Coleman E, Bockting W, Botzer M, Cohen-Kettenis P, et al. Standards of Care for the Health of Transsexual, Transgender, and Gender-Nonconforming People, 7th version. 2012;13(04):165–232
- 19 Gupta R, Kaushik N, Asokan A, et al. Surgical Care: Surgical Management of Gender Incongruence. In: *Indian Standards of Care for Persons with Gender Incongruence and People with Differences in Sexual Development/Orientation Version 1*. Delhi: Wisdom Publishers; 2020:66–165
- 20 Bizic M, Kojovic V, Duisin D, et al. An overview of neovaginal reconstruction options in male to female transsexuals. *ScientificWorldJournal* 2014;2014:638919
- 21 Selvaggi G, Ceulemans P, De Cuyper G, et al. Gender identity disorder: general overview and surgical treatment for vaginoplasty in male-to-female transsexuals. *Plast Reconstr Surg* 2005;116(06):135e–145e
- 22 Parsons JK, Gearhart SL, Gearhart JP. Vaginal reconstruction utilizing sigmoid colon: complications and long-term results. *J Pediatr Surg* 2002;37(04):629–633
- 23 Gaither TW, Awad MA, Osterberg EC, et al. Postoperative complications following primary penile inversion vaginoplasty among 330 male to female transgender patients. *J Urol* 2018;199(03):760–765
- 24 Goddard JC, Vickery RM, Qureshi A, Summerton DJ, Khoosal D, Terry TR. Feminizing genitoplasty in adult transsexuals: early and long-term surgical results. *BJU Int* 2007;100(03):607–613
- 25 Krege S, Bex A, Lümmen G, Rübber H. Male-to-female transsexualism: a technique, results and long-term follow-up in 66 patients. *BJU Int* 2001;88(04):396–402
- 26 Wagner S, Greco F, Hoda MR, et al. Male-to-female transsexualism: technique, results and 3-year follow-up in 50 patients. *Urol Int* 2010;84(03):330–333
- 27 Rossi Neto R, Hintz F, Krege S, Rubben H, Vom Dorp F. Gender reassignment surgery—a 13 year review of surgical outcomes. *Int Braz J Urol* 2012;38(01):97–107
- 28 Raigosa M, Avvedimento S, Yoon TS, Cruz-Gimeno J, Rodriguez G, Fontdevila J. Male-to-female genital reassignment surgery: a retrospective review of surgical technique and complications in 60 patients. *J Sex Med* 2015;12(08):1837–1845
- 29 Wangjiraniran B, Selvaggi G, Chokrungravanont P, Jindarak S, Khobunsongserm S, Tiewtranon P. Male-to-female vaginoplasty: Preecha's surgical technique. *J Plast Surg Hand Surg* 2015;49(03):153–159
- 30 Buncamper ME, van der Sluis WB, van der Pas RSD, et al. Surgical outcome after penile inversion vaginoplasty: a retrospective study of 475 transgender women. *Plast Reconstr Surg* 2016;138(05):999–1007
- 31 Pariser JJ, Kim N. Transgender vaginoplasty: techniques and outcomes. *Transl Androl Urol* 2019;8(03):241–247
- 32 Salibian AA, Schechter LS, Kuzon WM, et al. Vaginal canal reconstruction in penile inversion vaginoplasty with flaps, peritoneum or skin grafts: where is the evidence? *Plast Reconstr Surg* 2021;147(04):634e–643e
- 33 Massie JP, Morrison SD, Van Maasdam J, Satterwhite T. Predictors of patient satisfaction and postoperative complications in penile inversion vaginoplasty. *Plast Reconstr Surg* 2018;141(06):911e–921e