



# End-to-Side Nerve Transfer for the Management of Chronic Leg Compartment Ankle Dorsiflexion Weakness

Edgardo R. Rodriguez-Collazo, DPM<sup>1</sup> Asim A.Z. Raja, DPM<sup>2,\*</sup> Shawn Christopher Ward, DPM<sup>3</sup>  
Stephanie Oexeman, DPM<sup>1</sup> Arshad A. Khan, DPM<sup>4</sup>

<sup>1</sup> Department of Surgery, Amita Health Saint Joseph's Hospital, Chicago, Illinois

<sup>2</sup> Department of Orthopedics and Rehabilitation, Womack Army Medical Center, Fort Bragg, North Carolina

<sup>3</sup> Department of Surgery, Mercy Health Saint Rita's Medical Center Lima OH, Lima, Ohio

<sup>4</sup> Department of Orthopedic Surgery, Indiana University School of Medicine, Gary/Northwest, Indiana

**Address for correspondence** Edgardo R. Rodriguez-Collazo, DPM, Department of Surgery, Ascension Saint Joseph Hospital, Laboure Outpatient Clinic, 2913 North Commonwealth Ave, Chicago, IL 60657 (e-mail: egodpm@gmail.com).

J Reconstr Microsurg Open 2022;7:e35–e43.

## Abstract

**Background** A proximal deep peroneal nerve (DPN) injury can significantly impact the functional capacity of the leg, to include compromised motor function of the tibialis anterior (TA) muscle. Clinical examination can range from weakness in ankle dorsiflexion, to complete foot drop. Diagnostic nerve conduction velocity (NCV) testing can demonstrate abnormalities at select areas of impingement (or) entrapment (i.e., regions affected by a demyelinating compression mono-neuropathy), along the proximal course of the common peroneal nerve.

**Methods** We retrospectively report on 17 patients with clinical weakness involving ankle dorsiflexion. All patients underwent surgical end-to-side anastomosis, transferring a muscular nerve branch from the superficial peroneal nerve (SPN) to a segment of the DPN responsible for TA muscle innervation. Outcomes were based on comparisons of preoperative and postoperative DPN motor function to the TA muscle, standardized to the British Medical Research Council Scale for Muscle Strength. Preoperative scores were generally M2 or below.

**Results** Postoperative outcome scores of M4 to M5 were considered good (or) successful. 94.1% of patients demonstrated successful outcomes.

## Keywords

- ▶ weakness
- ▶ ankle dorsiflexion
- ▶ deep peroneal nerve

\* The views expressed herein are those of the author(s) and do not reflect the official policy or position of the U.S. Army Medical Department, Department of the Army, Department of Defense, or the U.S. Government.

received  
May 10, 2021  
accepted after revision  
November 3, 2021

DOI <https://doi.org/10.1055/s-0041-1740979>.  
ISSN 2377-0813.

© 2022. The Author(s).

This is an open access article published by Thieme under the terms of the Creative Commons Attribution-NonDerivative-NonCommercial-License, permitting copying and reproduction so long as the original work is given appropriate credit. Contents may not be used for commercial purposes, or adapted, remixed, transformed or built upon. (<https://creativecommons.org/licenses/by-nc-nd/4.0/>)

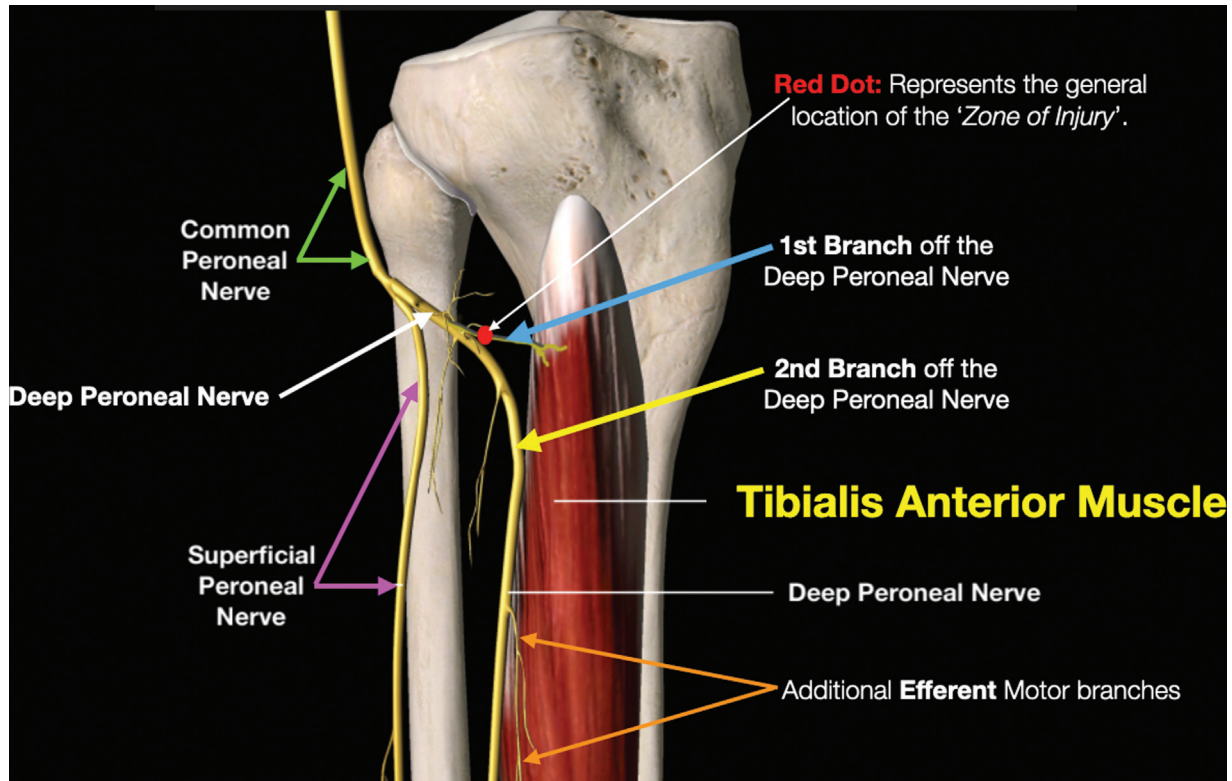
Thieme Medical Publishers, Inc., 333 Seventh Avenue, 18th Floor, New York, NY 10001, USA

**Conclusion** An end-to-side SPN motor branch anastomosis, into the motor branch of the DPN responsible for TA muscle innervation, can be a viable treatment option for weakness in ankle dorsiflexion. All reported cases involved a compromised segment of deep peroneal nerve within the proximal one-third of the leg.

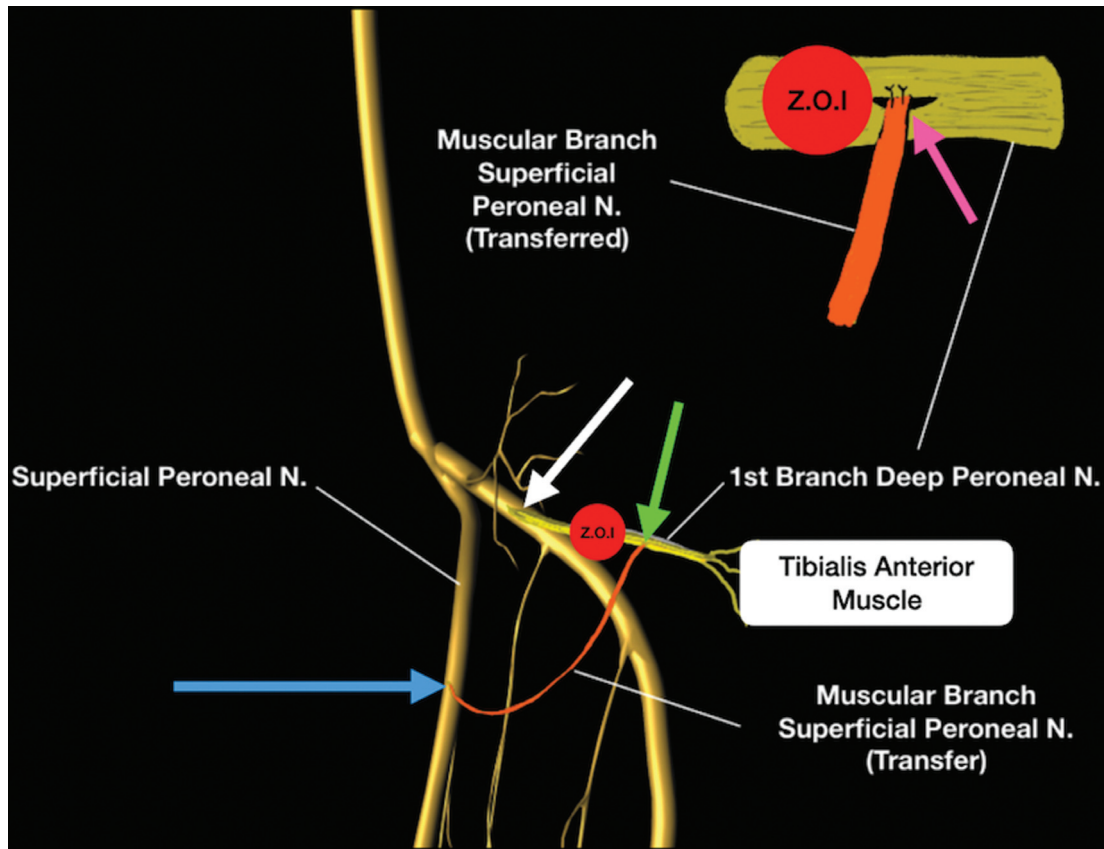
The deep peroneal nerve (DPN), and superficial peroneal nerve (SPN), both emanate from the common peroneal nerve (CPN), within the proximal one-third of the leg (►Fig. 1). The CPN can be traced to an area just below the proximal fibular head. Injury (or) insult to the DPN can result from both iatrogenic or traumatic causes.<sup>1,2</sup> Injury can result in intra-neural and/or extra-neural scarring, impingement, or swelling.<sup>3</sup> All injuries (or) insults reported in our paper, involved compromise to the DPN branch responsible for innervating the tibialis anterior (TA) muscle. All patients in this study demonstrated weakness in ankle dorsiflexion. Compromised ankle joint dorsiflexion did not involve reasons of myopathy, hereditary neuromuscular disease, bony impingement, or nerve injuries proximal to the knee.<sup>4,5</sup> The purpose of this paper is to report on improved strength and function, of the TA muscle, under select circumstances, with a surgical end-to-side motor branch nerve anastomosis from the SPN, to the DPN, past the zone of DPN nerve injury.

## Methods

The present study received an exemption from the Amita Saint Joseph Hospital Institutional Review Board (IRB), with the stipulation that the “age” demographic not be reported along with the “gender” demographic. A literature search was performed to identify other articles reporting similar nerve anastomotic techniques for strengthening ankle dorsiflexion.<sup>6–9</sup> All patients were operated on by the lead author. All surgical cases involved an end-to-side anastomosis of a single motor branch, from the SPN, being anastomosed to a segment of the DPN, past the zone of injury, as determined by intraoperative motor testing (►Fig. 2). Reported data includes, (1) gender, (2) the period of time (in months) from the inciting event creating weakness, to the time of operative end-to-side nerve anastomosis, (3) postoperative follow-up (in years), (4) the inciting event or mechanism leading to the onset of weakness (►Table 1), and (5) pre and



**Fig. 1** Illustration demonstrating the common peroneal nerve (green arrows) and its general branching scheme, to include: the deep peroneal nerve (white arrow), the first motor branch of the deep peroneal nerve to the tibialis anterior muscle (blue arrow), the second branch of the deep peroneal nerve (yellow arrow); the superficial peroneal nerve (purple arrows). The red dot represents the general (or) common location for the “zone of injury” in all reported cases. The orange arrows represent additional motor nerve branches from the deep peroneal nerve, innervating segments of the tibialis anterior muscle.



**Fig. 2** Illustration of the “end-to-side” anastomosis procedure. ZOI stands for “zone of injury,” and represents the general location of all nerve injuries noted intraoperatively. *Orange thick line (upper right)* and *thin curved line (bottom center)*: both represent the same single motor muscular nerve branch selected for transfer and anastomosis. *Blue arrow* represents the proximal branching point of the motor nerve, selected for transfer, off of the superficial peroneal nerve. *Green arrow* illustrates the location of the anastomosis, distal to the zone of injury (ZOI). *Pink arrow* illustrates an enlarged diagram of the anastomosis, demonstrating an epineurial window, with the transferred motor branch secured with either 10.0 (or) 11.0 nylon suture.

**Table 1** Patient data

Patient #	Time of injury to surgery (months)	Gender	Follow-up after surgery (years)	History of original injury	Pre-operative BMCR grade	Post-operative BMCR grade
1	38	M	3	Knee dislocation	2	4
2	17	F	3	Knee fislocation	2	5
3	10	M	3	ACL repair	1	4
4	16	M	2	Knee contusion	1	4
5	12	F	3	Ankle sprain (inversion)	2	5
6	24	F	2	Ankle sprain (inversion)	1	4
7	16	F	3	ACL reconstruction	1	4
8	16	F	2	WEBER B	1	4
9	7	M	1	Ankle sprain (inversion)	2	4
10	9	F	1	ACL reconstruction	1	4
11	14	M	1	WEBER C	1	4
12	13	F	2	TKA	2	5
13	6	M	1	TKA	2	4
14	15	M	3	TKA	1	4
15	6	M	1	WEBER C	1	5
16	13	F	2	Knee contusion	1	4
17	7	M	2	WEBER B	1	3

Abbreviations: ACL, anterior collateral ligament (knee); BMRC, British Medical Research Council; FX, fracture; TKA, total knee arthroplasty; WEBER B, Danis-Weber Ankle Fracture Classification Type B; WEBER C, Danis-Weber Ankle Fracture Classification Type C.

**Table 2** The British Medical Research Council Scale for muscle strength

Grade	Description
M5	Normal power
M4	Movement against gravity and resistance
M3	Movement against gravity (no resistance)
M2	Movement with gravity eliminated
M1	Muscle contraction with no movement/flicker
M0	Total paralysis

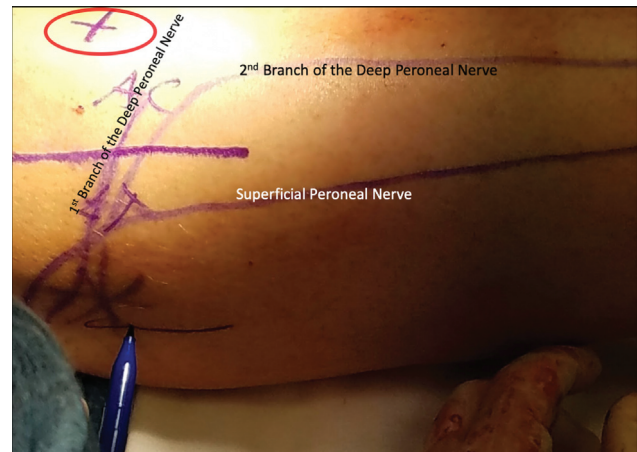postoperative clinical muscle strength grading, based on the British Medical Research Council Scale for Muscle Strength (► **Table 2**).

### Patient Selection

All patients included in the study demonstrated preoperative weakness with ankle dorsiflexion, as compared with the unaffected contralateral limb. All patients underwent preoperative nerve conduction velocity (NCV) and electromyography (EMG) studies. All testing was conducted by a musculoskeletal neurophysiologist. In all cases, motor conduction velocities of the affected limb were compared with motor conduction velocities of the uninjured, contralateral leg. There were no bilateral cases. All reported cases demonstrated a decrease in conduction velocity, within the proximal one-third of the leg. NCV motor testing, in all cases, confirmed a demyelinating mononeuropathy, i.e., focal nerve entrapment, or compression injury. EMG studies demonstrated no pathology to the muscle fibers. All patients failed nonoperative therapies and/or treatments, to include different modalities of physical therapy and bracing.

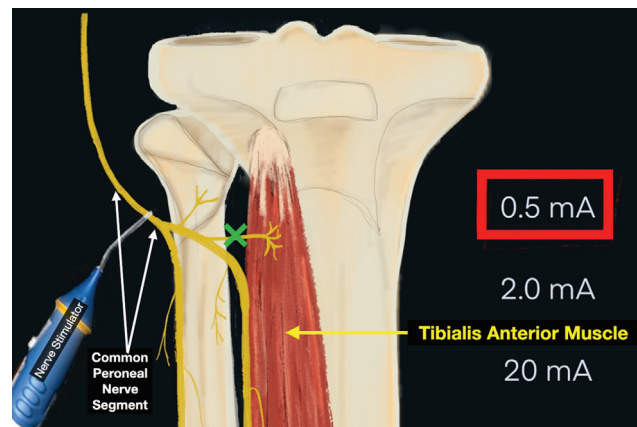
### Surgical Technique

Surgery was performed under general anesthesia with avoidance of paralytics. Nerve blocks or tourniquets were not utilized, to conduct intraoperative motor nerve stimulation testing. The procedure was performed under 4.5× to 5.5× surgical loupe magnification, with intraoperative microscope (9× to 10×) magnification when needed. All intraoperative nerve stimulations were performed with a Checkpoint handheld nerve stimulator/locator (Checkpoint, NDI Medical, Cleveland, OH 44122). Intraoperative nerve stimulation was initiated at a setting of 0.5 mA, with an increase to a maximum of 2.0 mA if needed. Patients were placed in a lateral decubitus position with the ipsilateral knee flexed at approximately 35 degrees, and the ipsilateral limb slightly internally rotated. Landmarks for the incision included the proximal head of the fibula, and the proximal tibial tuberosity (► **Fig. 3**). Surgical incisions were generally orientated 3 cm inferior to the proximal fibular head, and then advanced over the lateral, and anterior compartments of the proximal one-third of the leg. A decompression of the common, deep, and SPN was completed via, (1) the release of the overlying external aponeurotic fascia, (2) the posterior, anterior, and innominate (or “no-name”) intermuscular septa, (3) select segments of muscle fibers, and

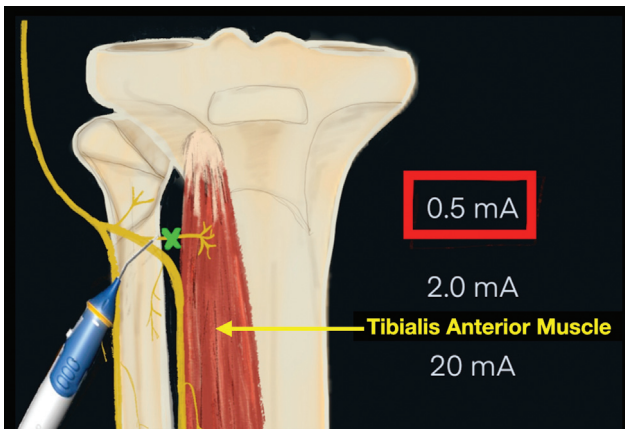


**Fig. 3** Incision marking on skin, with the lateral compartment (LT) and anterior compartment (AC) outlined on the proximal one-third of the leg. Additional marks include the tibial tuberosity (centered within the red circle), first branch of the deep peroneal nerve, the second branch of the deep peroneal nerve, and the superficial peroneal nerve.

(4) select underlying, (or) deep internal aponeurotic structures, all within the proximal one-third of the leg. Following decompression, intraoperative motor nerve stimulation was conducted, testing for ankle joint dorsiflexion. Testing was conducted along (1) the CPN, just inferior to the proximal fibular head, (2) segments of the DPN, within the anterior compartment of the proximal one-third of the leg, and (3) along the first motor branch off of the DPN, directed toward the TA muscle. Intraoperative nerve testing for motor function, was deficient in providing adequate stimulation to the TA muscle, when conducted either proximal too, or at the site of injury (► **Figs. 4 and 5**). Intraoperative nerve testing for motor function distal to (i.e., past the zone of injury) demonstrated an improved response to dorsiflexion at the ankle joint (► **Fig. 6**). Therefore, all nerve transfer anastomosis sites were located past the zone of injury, along the first motor branch off of the DPN. All nerves selected for transfer and anastomosis, were

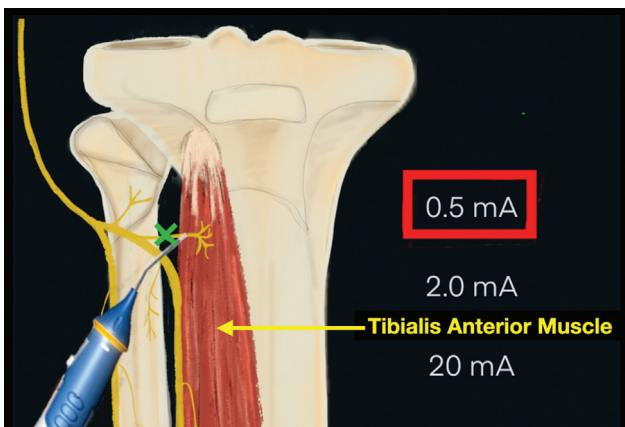


**Fig. 4** Illustration demonstrating the use of an intraoperative nerve stimulator, set at 0.5 mA, and placed on the common peroneal nerve, to test for contracture of the tibialis anterior (TA) muscle. Green “X” represents the “zone of injury” (or) entrapment hindering the ability for motor signal to reach the target muscle. Intraoperative nerve testing at this location was deficient in providing adequate stimulation to the tibialis anterior muscle.

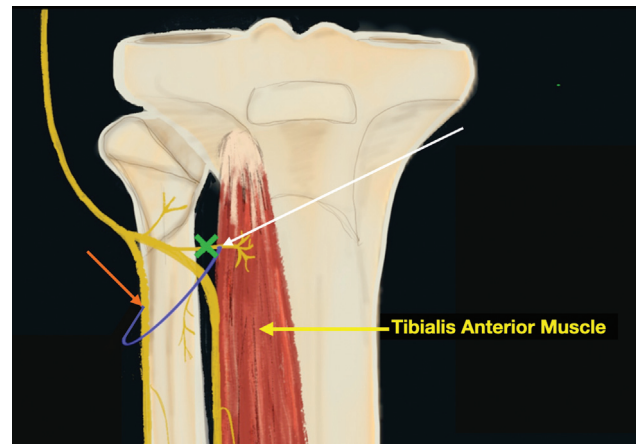


**Fig. 5** Illustration demonstrating the use of a nerve stimulator, set at 0.5 mA, being placed on the first motor branch off of the deep peroneal nerve (DPN) PROXIMAL to the “zone of injury.” Green “X” represents the “zone of injury.” Intraoperative nerve testing at this location, was deficient in providing adequate stimulation to the tibialis anterior muscle.

single (motor) muscular branches, from the neighboring SPN. Prior to selection, single motor nerve functionality was confirmed with a nerve stimulator. Furthermore, considerations were given to assure that, the transferred nerve would reach the intended recipient site, without incurring excessive tension. The transferred motor branch, was transected near its distal muscular attachment, with its proximal connection to the SPN preserved (► **Fig. 7**). Preservation of the proximal segment allowed for continued reception of motor signal to the transferred motor branch. The detached distal end was anastomosed to the recipient nerve site via creation of a small epineurial window, after which, the transferred motor branch was sutured in place utilizing 10–0 or 11–0 nylon (► **Fig. 8**). Following the anastomosis, verification of adequate TA muscle contraction was confirmed, via intraoperative motor nerve stimulation, from the proximal portion of the transferred motor nerve branch (► **Fig. 9**). Deep wound closure was performed, with skin closure achieved via the use of skin



**Fig. 6** Illustration demonstrating the use of a nerve stimulator, set at 0.5 mA, and placed distal (or) past the “zone of injury.” Green “X” represents the “zone of injury.” In all reported cases, intraoperative nerve testing for motor function distal to (i.e., past the zone of injury) demonstrated an improved response of dorsiflexion at the ankle joint.

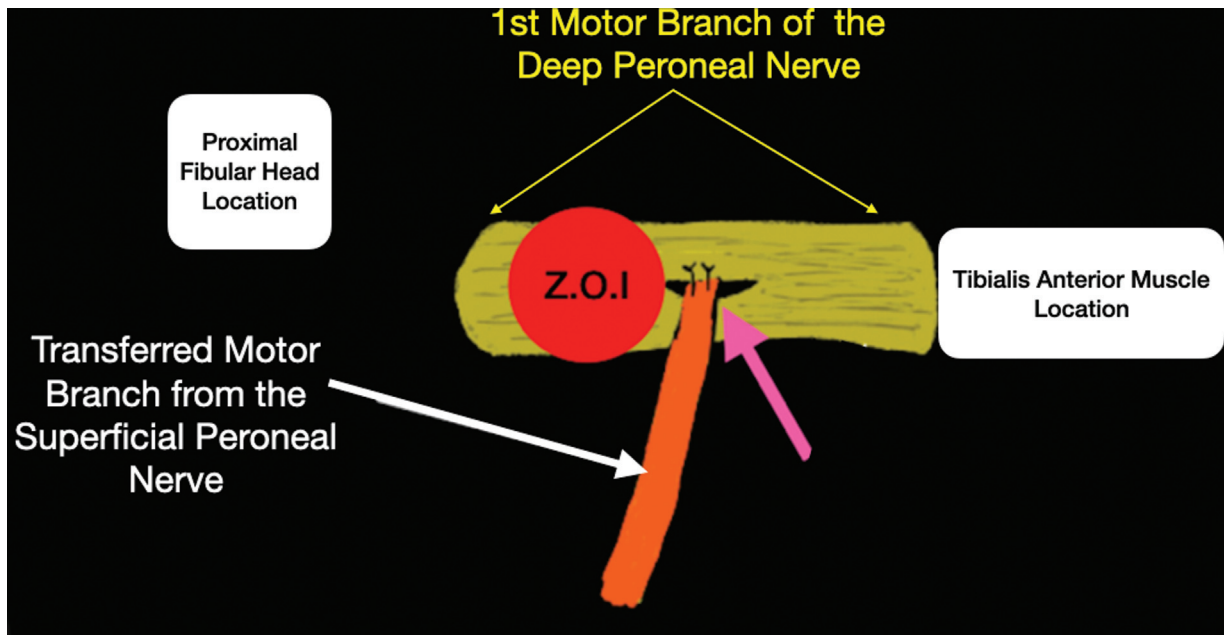


**Fig. 7** Illustration demonstrating the motor nerve transfer. The white arrow indicates the location of the transfer/anastomosis site for the end-to-side transfer. The blue semi-circle represents the transferred motor branch. The orange arrow indicates continuity of the motor branch selected for transfer, to its proximal origin (or) connection to the superficial peroneal nerve (SPN).

staples. A semi-compressive dressing was applied over the incision site, allowing for the management of postoperative edema, without running the risk of becoming overly constrictive and painful. The majority of patients were placed into a knee immobilizer, excluding those who already had been issued a prefabricated brace. The patients were instructed to partially weight bear with crutches as needed, and to elevate as much as possible until the sutures could be safely removed. In addition, the use of a night splint, or a cam-boot was encouraged to maintain a 90-degree angle at the ankle joint. On average, sutures were removed at approximately 14 days, after which, instructions were given to begin gentle range of motion of the knee joint. Compression socks extending above the knee were also encouraged for the control of postoperative edema. The patients were eventually referred to a rehabilitation facility for range of motion, proprioception, and strengthening exercises. Rehabilitation of the TA muscle was further assisted with the use of direct electrical stimulation involving the anterior compartment of the leg. Concurrent home therapy was encouraged, to include strengthening and stretching exercises, as the patients continued to progress in their scheduled physical therapy sessions.

## Results

A total of seventeen (17) patients were reported in the study; nine male (53%) and eight females (47%). The average age was 43.7 years. All patients demonstrated preoperative ankle dorsiflexion weakness, due to a disturbance involving the course of the proximal DPN, typically along its first motor branch responsible for innervating the TA muscle. The average preoperative British Medical Research Council Scale for muscle strength grade was 1.4. The average postoperative British Medical Research Council Scale for muscle strength grade was 4.2, ( $p$ -value < 0.01). Follow-up range was between 1 and 3 years, with a mean follow-up of 2.05 years.



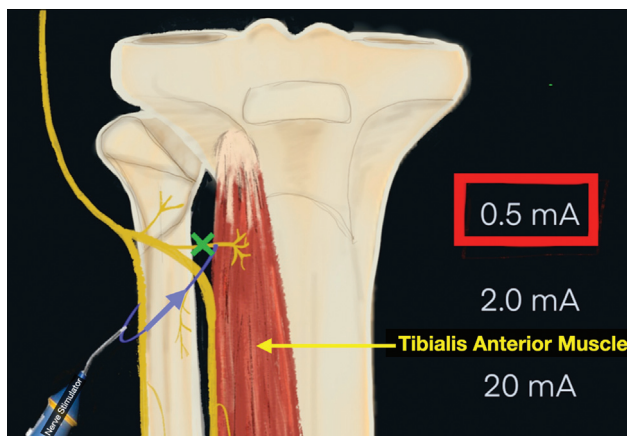
**Fig. 8** Illustrating the end-to-side anastomosis site. *White arrow* illustrates the transferred motor branch from the superficial peroneal nerve. *Pink arrow* demonstrates the site of the end-to-side nerve anastomosis. An epineural window is created and the transferred motor branch is secured in place with either 10.0 or 11.0 Nylon suture.

Average time from injury to surgery was 14.1 months (→ **Table 1**). Good to successful outcomes were based on the British Medical Research Council Scale for Muscle Strength scores of M4 or higher. Based on this criterion, 94.1% of patients were considered to have successful outcomes. There were no reported postoperative infections, no reported re-operations, or worsening of weakness following operative intervention.

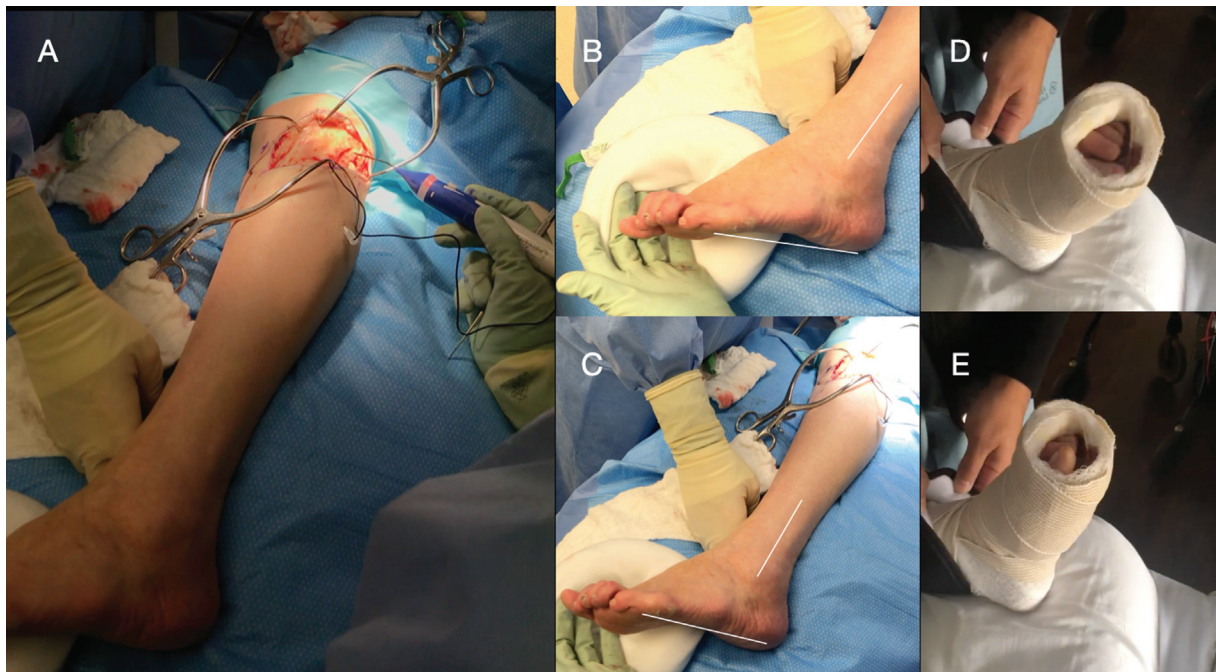
## Discussion

Peripheral nerve injuries can broadly be categorized into three types: (1) neuropraxia, representing a transient compression to the nerve, commonly due to scarring, adhesions, or edema.

External compressive forces affect, otherwise, intact neuronal structures, such as the axon, myelin sheath, endoneurium, perineurium, and epineurium; (2) Axonotmesis, represents a peripheral nerve injury of discontinuity to the axons and surrounding myelin sheath, but generally sparing (i.e., preserved continuity to varying degrees), of the additional surrounding endoneurium, perineurium, and epineurium; and (3) Neurotmesis represents a peripheral nerve injury of discontinuity to the axons, surrounding myelin sheath, and accompanying endoneurial, perineurial, and epineurial structures.<sup>10</sup> Peripheral nerve injury to the proximal one-third of the DPN, can potentially lead to weakness of the anterior tibial muscle complex. Brief et al reported on 32 cases of foot drop secondary to acute ankle inversion sprains. In all cases EMG studies were used to locate and classify the type of nerve injury incurred. Proposed mechanisms included traction and compression of the CPN, around the proximal fibular neck, as well as, possible compression by hematoma.<sup>11</sup> Weber B ankle fractures also carry a component of inversion inherent to their mechanism. Thus, such injuries also carry the potential to adversely affect the CPN.<sup>12-14</sup> In all our reported cases, intraoperative nerve testing demonstrated a zone of injury, occurring along the initial course of the DPN, typically involving the first motor branch to the TA muscle. Electrophysiological studies were conducted in a sequential or “segment by segment” manner, from proximal to distal, with a technique commonly referred to as “inching.” In this manner, a zone of injury was determined within a particular segment of the nerve, where either the amplitude was decreased and/or the signal velocities were prolonged. Decreased amplitudes commonly represent diminishing axonal recruitment, whereas prolonged signal velocities commonly represent a reduction or depletion of nerve myelin. Thus, in all cases presented, electrophysiological studies were able to determine both the

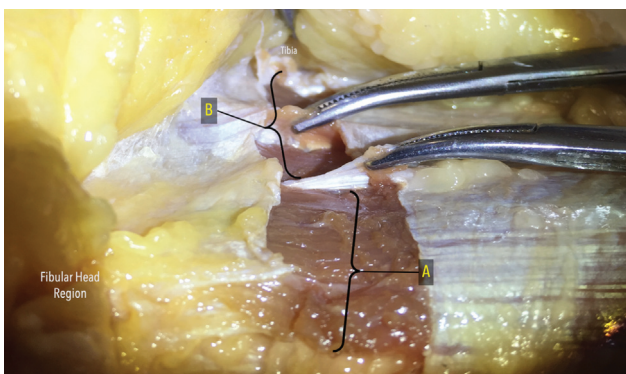


**Fig. 9** Illustrating how verification was obtained for testing improved tibialis anterior muscular contraction following end-to-side anastomosis. Testing of the transferred nerve is conducted close to its origin, near the superficial peroneal nerve (SPN). The *green “X”* represents the “zone of injury.” The *blue arrow* illustrates the direction of motor nerve conduction signal.



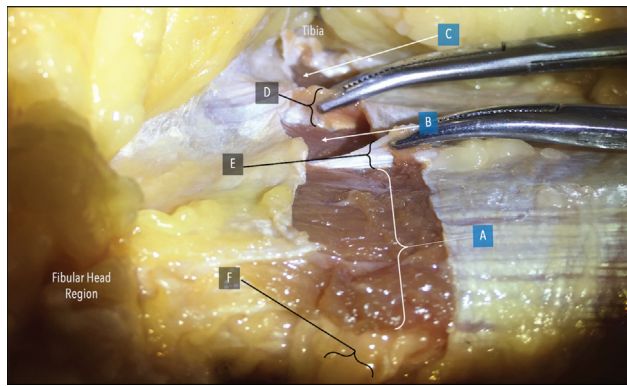
**Fig. 10** Intraoperative and postoperative assessment of ankle dorsiflexion: (A) Intraoperative nerve stimulation at the level of the common peroneal nerve, the deep peroneal nerve, and the first motor branch off of the deep peroneal nerve. (B) Intraoperative ankle position at rest. White lines demonstrate the relative position of the fibula to the relative position of the plantar lateral foot, between the plantar aspect of the heel pad, and the plantar aspect of the fifth metatarsal head. (C) Indication of intraoperative ankle dorsiflexion upon stimulation of the first branch off of the deep peroneal nerve, past the zone of injury, indicating slight dorsiflexion at the ankle joint. White lines demonstrate the relative position of the fibula to the relative position of the plantar lateral foot between the plantar aspect of the heel pad, and the plantar aspect of the fifth metatarsal head. (D) Postoperative assessment with the ankle joint relaxed. (E) Postoperative assessment with the ankle joint undergoing active dorsiflexion.

type of nerve injury incurred, as well as, the relative location of the injury along the course of the CPN. In all cases, additional intraoperative motor nerve stimulation of the TA muscle was recommended by the musculoskeletal neurophysiologists. Subsequently, intraoperative nerve stimulation testing, began at the CPN, and was continued distally along the course of the DPN. In all cases, the strongest contraction of the TA muscle was elicited with stimulation along the course of the first motor branch off of the DPN, past the zone of injury. Other more distal motor branches were also tested intraoperatively, but elicited a weaker contraction in comparison to the one elicited from the first motor branch off of the DPN. Therefore, in

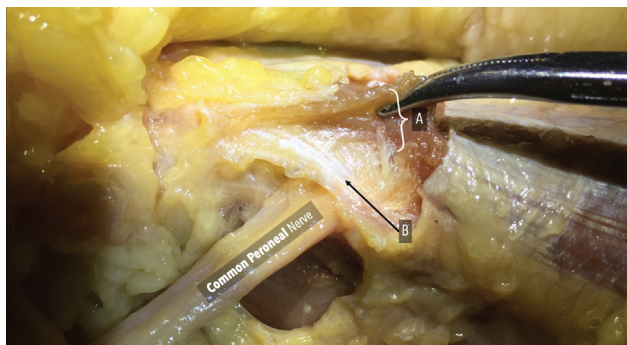


**Fig. 11** Cadaveric dissection in the proximal one-third of the leg: (A) Segment comprising the lateral compartment of leg. (B) Segment comprising the anterior compartment of the leg.

all cases, the location of the end-to-side nerve transfer, was distal to the zone of injury, along the course of the first motor branch off the DPN (► Fig. 10). Decompression in this region, involved releasing the overlying external aponeurosis, intermuscular septa, and segments of proximal muscle fiber overlying the nerve (► Figs. 11 and 12). Deep fibers of the posterior crural intermuscular septum, provide an opening (or) sling, to accommodate the course of the CPN, when the nerve first enters into the lateral compartment (► Fig. 13). Furthermore, there can exist additional extraneural fibrous structures, deep to other intermuscular septa in the region, capable of producing a point of entrapment, independent of the crural intermuscular septum above it. Cadaveric dissections, along with intraoperative findings, have brought to light one such entrapment point, comprised of fibrous bands, deep to (i.e., along the ventral or undersurface), of the anterior crural intermuscular septum. These fibers typically entrap the deep peroneal motor nerve branch, as it transitions from the lateral to anterior compartment, within the proximal one-third of the leg. We have coined this deep band of fibrous tissue, the extensor digitorum longus (EDL) deep aponeurotic sling; designating fibrous bands which typically are independent from fibers of the deeper portion of the anterior crural intermuscular septum (► Fig. 14). Such fibers are not readily visible, unless overlying muscle fiber, and the deep bands of the associated intermuscular septa are elevated and/or transected. These regions will continue to act as points of entrapment, despite the release of more superficial structures, thus

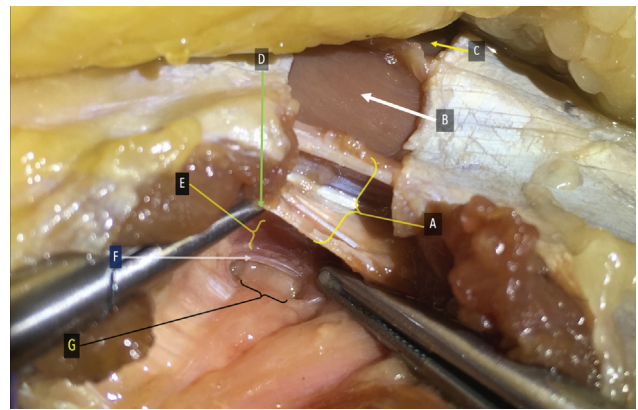


**Fig. 12** Cadaveric dissection in the proximal one-third of the leg, with the fibular head region and general location of the tibia labeled in white. (A) Peroneus longus muscle in the lateral compartment of the proximal one-third of the leg. (B) Extensor digitorum longus muscle in the anterior compartment of the proximal one-third of the leg. (C) Tibialis anterior muscle in the anterior compartment of the proximal one-third of the leg. (D) Intermuscular septum dividing the anterior compartment of the proximal one-third of the leg, between the tibialis anterior muscle and the extensor digitorum longus muscle. (E) Anterior intermuscular septum separating the anterior from the lateral compartment, within the proximal one-third of the leg. (F) Common peroneal nerve traveling beneath the peroneus longus (PL) muscle.



**Fig. 13** Cadaveric dissection in the proximal one-third of the leg: (A) Elevating a portion of the proximal peroneus longus (PL) muscle to expose underlying fibers of the posterior crural intermuscular septum. (B) Fiber bands of the underlying posterior crural intermuscular septum along the ventral surface of the peroneus longus muscle; a potential area for nerve impingement/entrapment.

increasing the possibility of continued symptoms following operative intervention. It is also important to note that, transferring a single muscular motor branch from the SPN, did not equate to de-innervating the entire muscle from which the branch was taken. Similarly, there were no sensory defects noted along the course of the SPN, since only motor nerve branches were utilized for transfer. Lastly, a distinction was made between neurogenic and myopathic changes, via EMG testing of the TA muscle. In theory, any patient with myopathic, rather than neurogenic changes, would be more amenable to bracing measures, or surgical interventions involving joint fusions, and/or tendon transfers, with adjunct tendon lengthening procedures as deemed necessary. Subsequently, all EMG testing of the TA muscle demonstrated acceptable spontane-



**Fig. 14** Cadaveric dissection in the proximal one-third of the leg, illustrating the deep peroneal (labeled "G"), after transecting a proximal portion of the peroneus longus (PL) muscle, in the proximal lateral compartment of the leg: (A) Anterior crural intermuscular septum separating the anterior, from the lateral compartment. (B) Extensor digitorum longus muscle in the anterior compartment of the proximal one-third of the leg. (C) Tibialis anterior muscle in the anterior compartment of the proximal one-third of the leg. (D) Elevating the deep (or) inferior border of the anterior crural intermuscular septum with a microinstrument. (E) Exposure of the deeper segments of the extensor digitorum longus (EDL) muscle. (F) Thickened band of fibrous tissue, inferior to the EDL muscle, representing another possible region of compression to the deep peroneal nerve, termed as "extensor digitorum longus (EDL) deep aponeurotic sling." (G) Deep peroneal branch off of the common peroneal nerve.

ous discharges, indicative of normal muscle function. Limitations of our case series include a relatively small patient sample size, missing pre and postoperative validated patient satisfaction (or) functional scores, and cases with complete drop foot on preoperative examination.

## Conclusion

This review identifies a reconstructive alternative to reestablishing appropriate innervation signal to muscle fibers of the TA muscle. This case series presents the outcomes of transferring a motor nerve branch from the SPN, to the DPN, at a location distal to the zone of injury, within the proximal one-third of the leg. The authors advocate continued observation, along with the development of future prospective protocols, to further define treatment considerations, for patients demonstrating this form of chronic anterior leg compartment weakness.

### Conflict of Interest

None declared.

## References

- 1 Bibbo C, Rodriguez-Colazzo E. Nerve transfer with entubulated nerve allograft transfers to treat recalcitrant lower extremity neuromas. *J Foot Ankle Surg* 2017;56(01):82–86
- 2 Bibbo C, Rodriguez-Colazzo E, Finzen AG. Superficial peroneal nerve to deep peroneal nerve transfer with allograft conduit for neuroma in continuity. *J Foot Ankle Surg* 2018;57(03):514–517



- 3 Kim DH, Murovic JA, Tiel RL, Kline DG. Management and outcomes in 318 operative common peroneal nerve lesions at the Louisiana State University Health Sciences Center. *Neurosurgery* 2004;54(06):1421–1428, discussion 1428–1429
- 4 Macki M, Syeda S, Kerezoudis P, Gokaslan ZL, Bydon A, Bydon M. Preoperative motor strength and time to surgery are the most important predictors of improvement in foot drop due to degenerative lumbar disease. *J Neurol Sci* 2016;361:133–136
- 5 Macki M, Lim S, Elmenini J, Fakhri M, Chang V. Clinching the cause: a review of foot drop secondary to lumbar degenerative diseases. *J Neurol Sci* 2018;395:126–130
- 6 George SC, Boyce DE. An evidence-based structured review to assess the results of common peroneal nerve repair. *Plast Reconstr Surg* 2014;134(02):302e–311e
- 7 Brown BA. Internal neurolysis in treatment of traumatic peripheral nerve lesions. *Calif Med* 1969;110(06):460–462
- 8 Houshyar KS, Momeni A, Pyles MN, et al. The role of current techniques and concepts in peripheral nerve repair. *Plast Surg Int* 2016;2016:4175293
- 9 Garozzo D, Ferraresi S, Buffatti P. Surgical treatment of common peroneal nerve injuries: indications and results. A series of 62 cases. *J Neurosurg Sci* 2004;48(03):105–112, discussion 112
- 10 Flores AJ, Lavernia CJ, Owens PW. Anatomy and physiology of peripheral nerve injury and repair. *Am J Orthop* 2000;29(03):167–173
- 11 Brief JM, Brief R, Ergas E, Brief LP, Brief AA. Peroneal nerve injury with foot drop complicating ankle sprain—a series of four cases with review of the literature. *Bull NYU Hosp Jt Dis* 2009;67(04):374–377
- 12 Mitsiokapa E, Mavrogenis AF, Drakopoulos D, Mauffrey C, Scarlat M. Peroneal nerve palsy after ankle sprain: an update. *Eur J Orthop Surg Traumatol* 2017;27(01):53–60
- 13 Kleinrensink GJ, Stoeckart R, Meulstee J, et al. Lowered motor conduction velocity of the peroneal nerve after inversion trauma. *Med Sci Sports Exerc* 1994;26(07):877–883
- 14 Le Hanneur M, Amrami KK, Spinner RJ. Explaining peroneal neuropathy after ankle sprain. *Eur J Orthop Surg Traumatol* 2017;27(07):1025–1026