



Clinical Validation of the Glenoid Track Concept in Anterior Glenohumeral Instability

Validação clínica do conceito de glenoid track na instabilidade glenoumeral anterior

Mauro Emilio Conforto Gracitelli¹ Frederico Lafraia Lobo¹ Eduardo Angeli Malavolta¹
 Jorge Henrique Assunção¹ Fernando Brandão de Andrade-Silva¹ Arnaldo Amado Ferreira Neto¹

¹Institute of Orthopedics and Traumatology, Hospital das Clínicas, Faculdade de Medicina, Universidade de São Paulo, São Paulo, SP, Brazil

Address for correspondence Frederico Lafraia Lobo, Master of Science, Departamento de Ortopedia e Traumatologia, Hospital das Clínicas HCFMUSP, Faculdade de Medicina, Universidade de São Paulo, R. Dr. Ovídio Pires de Campos, 333, Cerqueira César, São Paulo, SP, 05403-010, Brazil (e-mail: dr.lobo.frederico@gmail.com).

Rev Bras Ortop 2022;57(4):612–618.

Abstract

Objective To evaluate the correlation of the glenoid track and glenoidal bone loss with the recurrence dislocation rate and the Rowe score.

Methods Retrospective study that assessed the glenoid track and glenoidal bone loss through preoperative magnetic resonance imaging. Patients undergoing primary arthroscopic repair of anterior Bankart were included. Patients with glenoidal bone loss greater than 21%, rotator cuff tear, scapular waist fracture, and posterior or multidirectional instability were not included. Rowe score were the primary outcome, and the recurrence rate was the secondary outcome.

Results One hundred and two patients were included. Postoperative recurrent instability was reported by 8 patients (7.8%). Four patients (50%) in the group with recurrence presented glenoidal bone loss greater than 13.5% against 24 (25.5%) in the group without recurrence ($p = 0.210$), with a negative predictive value of 94.6%. Three patients (37.5%) in the recurrence group were considered off-track, against 13 (13.8%) in the group without recurrence ($p = 0.109$), with a negative predictive value of 94.2%. Patients with absolute glenoid track value ≤ 1.5 mm had worse results in relation to the recurrence group, with 6 patients (75%) presenting recurrence ($p = 0.003$).

Conclusion Off-track injury and glenoidal bone loss greater than the subcritical are not related to the recurrence rate and Rowe score, despite the high negative predictive value. The cut of the absolute value of the glenoid track at 1.5 mm had a significant relationship with the recurrence rate.

Keywords

- Bankart lesions
- glenoid cavity
- shoulder dislocation

Work developed in Shoulder and Elbow Surgery, Institute of Orthopedics and Traumatology, Hospital das Clínicas HCFMUSP, Faculdade de Medicina, Universidade de São Paulo, São Paulo, SP, Brazil.

received
 April 15, 2021
 accepted
 September 9, 2021
 published online
 February 15, 2022

DOI <https://doi.org/10.1055/s-0041-1741022>
 ISSN 0102-3616.

© 2022. Sociedade Brasileira de Ortopedia e Traumatologia. All rights reserved.

This is an open access article published by Thieme under the terms of the Creative Commons Attribution-NonDerivative-NonCommercial-License, permitting copying and reproduction so long as the original work is given appropriate credit. Contents may not be used for commercial purposes, or adapted, remixed, transformed or built upon. (<https://creativecommons.org/licenses/by-nc-nd/4.0/>)

Thieme Revinter Publicações Ltda., Rua do Matoso 170, Rio de Janeiro, RJ, CEP 20270-135, Brazil

Resumo

Objetivo Avaliar a correlação do conceito de *glenoid track* e da perda óssea da cavidade glenoidal com a taxa de recidiva de luxação e pontuação na escala de Rowe.

Métodos Estudo retrospectivo que aferiu o *glenoid track* e a perda óssea da cavidade glenoidal por ressonância magnética pré-operatória. Foram incluídos pacientes submetidos a reparo artroscópico primário de Bankart anterior. Não foram incluídos pacientes com perda óssea da cavidade glenoidal maior que 21%, rotura do manguito rotador, fratura de cintura escapular, instabilidade posterior ou multidirecional. A pontuação pela escala de Rowe foi o desfecho primário, e a taxa de recidiva foi o desfecho secundário.

Resultados Cento e dois pacientes foram incluídos. A recidiva foi relatada por 8 pacientes (7,8%). Quatro pacientes (50%) do grupo com recidiva apresentaram lesão da cavidade glenoidal maior que 13,5% contra 24 (25,5%) do grupo sem recidiva ($p = 0,210$), com valor preditivo negativo de 94,6%. Três pacientes (37,5%) do grupo com recidiva foram considerados *off-track*, contra 13 (13,8%) do grupo sem recidiva ($p = 0,109$), com valor preditivo negativo de 94,2%. Pacientes com valor absoluto do *glenoid track* menor ou igual a 1,5 mm tiveram piores resultados em relação ao grupo com recidiva, sendo que 6 pacientes (75%) apresentaram recidiva ($p = 0,003$).

Conclusão Lesão *off-track* e perda óssea da cavidade glenoidal maior que a subcrítica não apresentam relação significativa com a taxa de recidiva e a pontuação de Rowe, apesar do alto valor preditivo negativo. O corte do valor absoluto do *glenoid track* em 1,5 mm apresentou relação significativa com a taxa de recidiva.

Palavras-chave

- ▶ lesões de Bankart
- ▶ cavidade glenoide
- ▶ luxação do ombro

Introduction

The decision on the type of surgical treatment of recurrent anterior shoulder dislocation has undergone recent changes.¹ The choice between anatomical surgery (Bankart repair) and non-anatomical surgery (remplissage or Latarjet) depends on several clinical and imaging factors, with the presence of bone loss of the glenoidal cavity or humerus head being highlighted as one of the most important.²⁻⁵ Depending on the percentage of bone loss of the glenoidal cavity, the risk of failure of Bankart arthroscopic repair increases significantly.⁶

The glenoid track allows a combined evaluation of glenoidal cavity and Hill-Sachs⁷ lesions, with them being characterized as on-track or off-track.³ This concept was ratified by the finite element model,⁸ and it is believed that this evaluation may predict lesions with a higher risk of failure after arthroscopic repair of isolated Bankart.³

This concept has been widely used to assist in the choice of treatment, with several biomechanical studies demonstrating its importance.^{3,7,9-13} However, few studies have evaluated its clinical validity,^{14,15} and only one study compared its results with the isolated evaluation of the glenoidal cavity.¹⁴ No previous study compared the results of the glenoid track with the threshold of subcritical glenoidal cavity bone loss (13.5% in anteroposterior diameter).¹⁶

Our main objective was to evaluate the correlation of the glenoid track and subcritical glenoidal bone loss with the recurrence rate of dislocation and the score on the Rowe scale.

Material and Methods

The study was approved by the Ethics Committee for The Analysis of Research Projects under opinion 1,269,108.

Study design

We conducted a retrospective analysis in a single center. The surgeries were performed consecutively by four shoulder and elbow surgeons between January 2013 and February 2018.

The inclusion criteria were patients older than 14 years with one or more episodes of anterior dislocation and who underwent primary arthroscopic repair of the Bankart lesion with a minimum follow-up of 24 months, who had undergone preoperative magnetic resonance imaging (MRI).

Patients with bone loss of the anteroposterior diameter of the glenoidal cavity greater than 21%, concomitant partial or total rotator cuff tear, scapular waist fracture, and posterior or multidirectional instability as well as those submitted to remplissage procedures were excluded. Posterior and superior Bankart lesions on MRI were not considered exclusion criteria.

Treatment

Arthroscopic Bankart repair was performed in the lateral decubitus. After confirming Bankart's lesion, the glenoidal cavity edge was prepared, and glenoid labrum mobilization was performed. Associated lesions of the upper or posterior glenoid labrum were also prepared for repair with bioabsorbable suture anchors placed on glenoid edge. Then, a repair of the labrum with absorbable anchor loaded with a high-strength wire was performed.

The physiotherapy protocol consisted of 4 weeks with sling, performing active movements of elbow, wrist and fingers 3 times a day. From the 4th postoperative week on, patients could perform passive and active movements assisted, limiting external rotation to up to 30° until the 6th week. Muscle strengthening was performed only from the 8th week on.

Characteristics of the studied population and results

The primary outcome was the Rowe score¹⁷ at 24 months, and the secondary outcome was the recurrence rate of dislocation.

The initial evaluation included age at first dislocation, age at time of surgery, gender, involvement of the dominant limb, participation in sports, number of anchors used in the anterior Bankart repair, and the need for posterior or superior labrum repair.

Image analysis

Magnetic resonance images were obtained using the GE HDxt 1.5-T device (General Electric Medical System, Walchessa, WI, USA) with dedicated shoulder coil. The patients were in a supine position, with their arms next to the body in neutral rotation. T2-weighted sequences were performed with fat suppression in the three orthogonal planes, coronal sequence in proton density, and T1 sagittal sequence. Intra-articular or intravenous gadolinium was not used in any of the exams. All measurements were performed by a shoulder and elbow specialist with 14 years of experience only once and using the iSite enterprise 4.1 image communication and archiving system (Philips Medical Systems, Best, Netherlands).

The Hill-Sachs evaluation was performed in T2-weighted axial image with fat suppression. Bone loss of the humerus head was measured in axial slice, from the linear distance of the joint insertion of the rotator cuff to the medial margin of the Hill-Sachs lesion.¹⁴ Axial slice with the

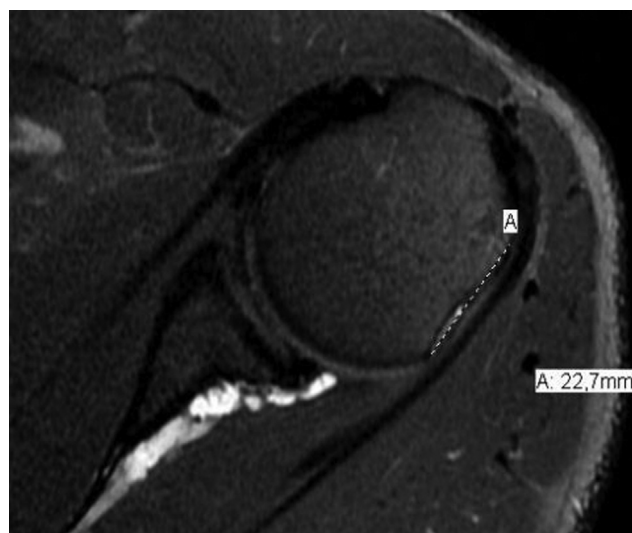


Fig. 1 Axial slice of magnetic resonance imaging for evaluation of the Hill-Sachs interval (A).

largest Hill-Sachs lesion was used to measure the Hill-Sachs interval^{14,18,19} (►Figure 1). The evaluation of the glenoid was performed using a more lateral T1-weighted oblique sagittal slice that included the glenoid. The perfect circle method (►Figure 2)^{20,21} was used, providing the relative value of glenoid bone loss. The patients were divided into 2 groups according to the threshold of “subcritical bone loss” ($\leq 13.5\%$ or $> 13.5\%$ of the anteroposterior diameter of the glenoidal cavity).¹⁶

The glenoid track was calculated as 83% of the expected glenoid diameter, minus the previous bone loss measured.³ For on-track or off-track categorization, the glenoid track value was subtracted from the Hill-Sachs range (absolute value of the glenoid track). If the Hill-Sachs range were larger than the glenoid track, the injury was categorized as off-track. Both the absolute value of the glenoid track and categorical descriptions were included in the analysis.

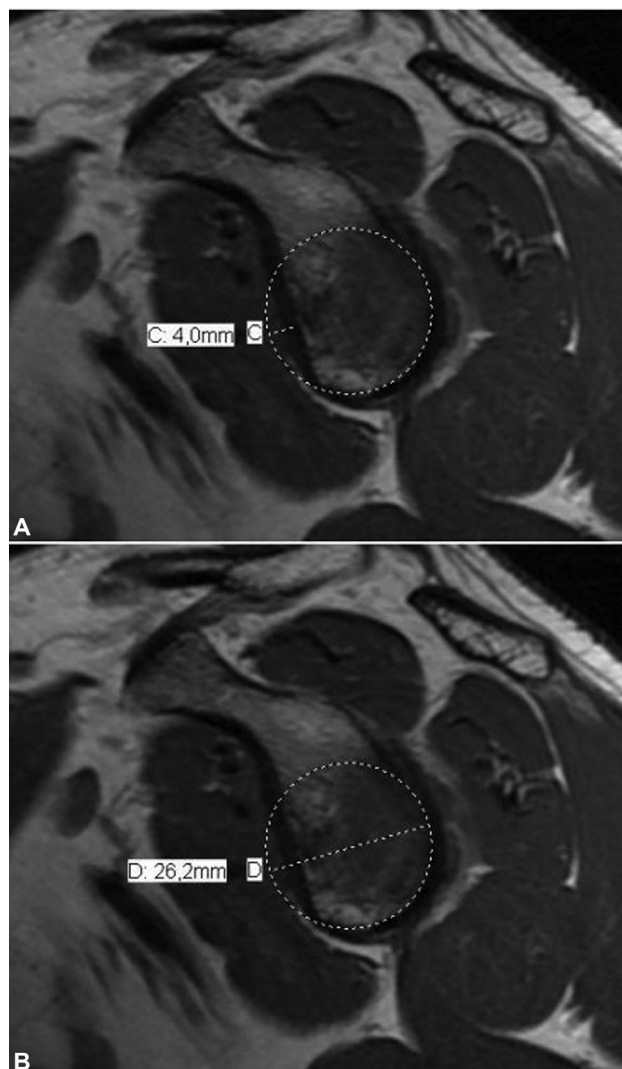


Fig. 2 Measurement of the anterior defect of the glenoid was performed by the perfect circle method in modified sagittal slice of the more lateral portion of glenoid on magnetic resonance imaging. The diameter of the glenoid (D) and the bone defect (C); calculation of the percentage of the anterior bone defect of the glenoid, using the formula: bone defect of the glenoid (%) = C/D.

Statistical analysis

Data normality was assessed by the Shapiro-Wilk test. Descriptive statistics, including means and standard deviations, were used for variables with normal distribution, and median and interquartile for non-normal distribution variables. The Fisher exact test was used for categorical variables, and the Wilcoxon and Mann-Whitney tests were used for non-normal distribution variables. The subgroup analysis was performed for the glenoid track and for the bone loss of the subcritical glenoid respecting the quartiles, division of the set into four equal parts of the sample distribution. All statistical analyses were performed in SPSS Statistics for Windows, Version 21.0 (IBM Corp., Armonk, NY, USA), and the level of statistical significance was 5%.

Results

A total of 118 patients with 24-month follow-up were evaluated. Preoperative MRI was available for 102 patients (86.4%), who were included in the study. The mean age was 31.1 years at the time of surgery and 23.4 years at the time of the first dislocation. There were 79 male patients (77.5%). No patient practiced professional sports. ► **Table 1** describes the baseline characteristics and the intervention used for each patient.

The mean score on the Rowe score in the preoperative period was 28.5 points (± 11.2) compared to 84.5 points (± 18.8) in the 24-month follow-up, with a statistically significant difference ($p = 0.004$).

Postoperative dislocation was reported by 8 patients (7.8%). Four patients underwent open Latarjet procedure, and the other four were treated non-surgically.

The overall mean anterior glenoid bone loss was 9.7%. ► **Table 2** describes the evaluation of the bone loss of the glenoid, according to the two categorization methods (glenoidal bone loss and glenoid track). ► **Table 3** describes the results of the Rowe scale scores for each of the two categories described above.

In the analysis of subcritical glenoidal bone loss, the patients were divided into two groups ($\leq 13.5\%$ or $> 13.5\%$) (► **Table 2**). Four patients (50%) in the recurrence group presented glenoidal bone loss greater than 13.5% against

Table 1 Baseline characteristics for the evaluated patients

Parameter	General (N = 102)
Age, years	31.1 (9.8)
Age at first dislocation, years	23.4 (8.2)
Male patients	79 (77.5)
Involvement of the dominant arm	56 (54.9)
Sports practitioners	34 (33.3)
Smokers	9 (8.8)
Number of previous dislocations	
1	2 (2.0)
2–5	91 (89.2)
> 5	9 (8.8)
Glenoidal anchors number	2.8 (0.4)
Posterior labrum repair	6 (5.9)
Superior labrum repair	11 (10.8)

Categorical data are presented as absolute numbers, with percentages in parentheses

*Continuous data is presented as means with standard deviations in parentheses.

24 patients (25.5%) without recurrence, with no statistically significant differences ($p = 0.210$).

The positive predictive value for a patient with glenoidal bone greater than 13.5% with recurrence was 14.3%, and the negative predictive value was 94.6% (► **Table 4**). The mean scores on the Rowe score were similar, with no statistically significant difference ($p = 0.704$) in both groups of subcritical bone loss.

In 16 patients (15.7%), the Hill Sachs' lesion was considered off-track. Regarding the influence of Hill Sachs' lesion on the recurrence rate, we found 3 patients (37.5%) in the group with recurrence with off-track lesion, compared to 13 patients (13.8%) in the group without recurrence, with no statistically significant difference ($p = 0.109$).

Regarding treatment failure, 3 of the 16 off-track patients (18.7%) and 5 of the 86 on-track patients (5.8%) recurred. The positive predictive value for a patient with an off-track lesion with recurrence was 18.8% and the negative predictive value

Table 2 General measurements of glenoidal cavity and glenoid track bone loss

	General (N = 102)			
	Average	SD	Median	IQR
Measurements of glenoidal bone loss				
Glenoidal anterior defect, mm	2.6	1.7	2.7	2.1
Diameter of the glenoid, mm	26.7	2.9	26.4	3.0
Percentage of bone loss %	9.7	6.0	10.7	7.8
Glenoid track measurements				
Hill-Sachs range, mm	15.3	4.7	14.7	5.6
Absolute glenoid track, mm	4.1	5.2	4.8	5.2

Abbreviations: SD, standard deviation; IQR, interquartile.

Table 3 Rowe score for categorical evaluations of bone loss for patients in general

	N	ROWE score				P-value
		Average	SD	Median	IQR	
Glenoidal bone loss						
≤ 13.5%	74	84.2	18.7	95.0	20.0	0.704
> 13.5%	28	85.0	19.6	92.5	25.0	
Glenoid track						
On track	86	84.9	18.6	95.0	25.0	0.566
Off track	16	81.9	20.5	85.0	19.0	

Abbreviations: SD, standard deviation; IQR, interquartile.

Table 4 Sensitivity, specificity, positive and negative predictive values for subcritical glenoidal bone loss and glenoid track in relation to recurrence

	Sensitivity	Specificity	Positive predictive value	Negative predictive value
Subcritical glenoidal bone loss	50 (15.7–84.3)	74.4 (64.4–82.9)	14.3 (7.1–26.6)	94.6 (89.7–97.3)
Glenoid track	37.5 (8.5–75.5)	86.2 (77.5–92.4)	18.8 (7.6–39.2)	94.2 (90.4–96.5)

*Continuous data is presented as means with a 95% confidence interval in parentheses.

was 94.2% (→ **Table 4**). The Rowe score was lower in the off-track group, with no statistically significant difference ($p = 0.566$).

We performed a subgroup analysis, dividing the patients according to the quartiles in relation to the absolute value of the glenoid track. We observed that patients with absolute glenoid track value ≤ 1.5 mm had worse results in relation to dislocation recurrence, with 6 patients (75%) presenting recurrence against 2 patients (25%) with values above 1.5 mm ($p = 0.003$).

We did not relate the associated patients intrinsic factors (age at first dislocation and number of dislocations) and lesions intrinsic factors (association with upper posterior or anterior lesions and number of anchors in the repair of the lesion) with the recurrence rate because it is not the objective of the study.

Discussion

As already pointed out by Momaya and Tokish,¹⁰ the concept of glenoid track is an important tool for evaluating anterior shoulder instability with bipolar injury, that is, glenoidal anterior bone loss (bone Bankart injury) associated with posterior humeral head impactation fracture (Hill-sachs injury). The concept helps in the best choice of treatment for each patient, either by arthroscopic repair of isolated Bankart^{22,23} or in association with the remplissage procedure^{24,25} or using the Bristow-Latarjet bone block technique.^{26–28}

Few studies have evaluated the influence of the concept of glenoid track on the risk of recurrence and on clinical scores, performing its clinical validation. Shaha et al.¹⁴ evaluated 57 patients submitted to arthroscopic Bankart repair, and performed MRI evaluation, similar to that used in our study.

They observed high recurrence in patients with off-track lesions (60%) against patients with on-track lesions (4%), with better positive predictive values when compared to the isolated evaluation of the glenoidal lesion. In a subanalysis of patients with bipolar lesions (30 cases), the authors report even higher recurrence values in patients with off-track lesions (86%). Locher et al.,¹⁵ in a retrospective study with 100 patients, demonstrated that 33% of patients with off-track lesions presented recurrence against 6% of those with on-track lesions.

The positive and negative predictive value are important indicators about the importance of the glenoid track and subcritical bone injury in decision-making regarding surgical treatment. The positive predictive value shows the probability of a case with off-track injury or subcritical bone injury operated by arthroscopy presenting recurrence. The negative predictive value, in turn, shows the probability of a case with on-track injury or without subcritical bone injury operated by arthroscopy of not presenting this complication. Thus, we were able to demonstrate high negative predictive values for both subcritical glenoidal bone loss ($> 13.5\%$) and for off-track lesions, with values of 94.6% and 94.2%, respectively. Shaha et al.¹⁴ and Locher et al.¹⁵ also demonstrated similar findings for off-track lesions, with negative predictive values of 92% and 94%, respectively. However, the authors did not evaluate the subcritical glenoidal bone loss. Our findings, therefore, demonstrate that for patients with on-track lesions and those with glenoidal bone loss lower than 13.5%, the risk of recurrence with arthroscopic repair is low. Our Rowe score results were not statistically different for off-track lesions and subcritical bone loss of the glenoid, in contrast to the findings of Shaha et al.¹⁴

We can present some criticism over the glenoid track method. The results of the present evaluation are categorical,

on-track and off-track, which simplifies decision-making between arthroscopic Bankart repair, associated or not with the remplissage procedure and Latarjet surgery.³ However, it does not value the wide variety of bone lesions, a fact that may hinder decision-making in borderline situations, as it does not allow a direct evaluation of the extent of bone lesions. It should be emphasized that other factors intrinsic to the patient and the lesion, such as age at the time of the first dislocation and at the time of surgical treatment; type of sport and sports level; and position and extent of the Hill-Sachs lesion, have a relevant influence on the individualized evaluation of each case for the decision to be made.

Shaha et al.¹⁴ demonstrated that “almost off-track” lesions, that is, those with a difference between the glenoid track and the Hill-Sachs interval (absolute glenoid track value) < 2 mm, presented worse results on the Western Ontario Shoulder Instability (WOSI) score when compared to “more on-track” lesions. We were able to demonstrate a great variability of the absolute values of this difference, which presented an average of 4.1 mm (± 5.2), but with a variation of -11.5 to 22 mm. In a subgroup analysis of the absolute value of glenoid track of less than 1.5 mm, we detected a greater difference between the groups, including 6 (75%) of the patients with recurrent instability.

Another criticism is that the reliability of glenoid track measurements is not high, mainly due to the difficulty of locating the insertion of the infraspinatus, either on MRI or 3D computed tomography (CT), as originally described. Schneider et al.²⁹ demonstrated, by CT, that the coefficient of variability for the Hill-Sachs lesion can reach 19.2%, compared with less than 4% for glenoidal bone loss. They also demonstrated a low level of interobserver reliability in relation to on-track or off-track classification (72%).

If we consider that measurement variations between 1.5 and 2 mm are common and that they can alter the results of the categorization between on-track and off-track, and the predictability of instability recurrence, as shown in our subgroup analysis, we consider it essential to use the absolute glenoid track value in decision making, especially in borderline cases. Just as the percentage of glenoidal bone loss is routinely used, the use of the absolute value of the glenoid track could be described in studies on the subject, as well as imaging reports.

Our study has some limitations. Magnetic resonance imaging (MRI) was used to measure the glenoid track; however, there is no validation in the literature for the use of such measure in this type of imaging examination, since it was developed for use in CT; it is noteworthy that Bottoni et al.³⁰ in 2021 used MRI in the same way as us. The images were performed by only one orthopedist in a single period. Although this standardizes the measurements, evaluated by a larger number of evaluators and with a greater number of rounds of evaluations, obtaining intra and interobserver agreement of the measurement of bone lesion measurements would increase the reliability of the data obtained and, as demonstrated by Schneider et al.,²⁹ the Hill-Sachs evaluation is probably less reliable than the evaluation of glenoidal bone loss. In a future study, we intend to evaluate

the agreement of bone lesion measurements in an enlarged series. A larger sample of recurrence cases would be beneficial to support external validity and to perform a multivariate regression analysis that included other variables intrinsic to the patient, injury, and surgery in the search for prognostic factors for arthroscopic treatment of anterior dislocation. The concept of subcritical injury was presented by Shaha,¹⁶ in 2015, in a military population; our sample included civilian patients, and only 33% of the patients were sport practitioners, a fact that may explain the discordant results and decreased the sensitivity of imaging methods for detection of recurrence. However, both populations are similar, mainly composed of young and male individuals.

Conclusion

Off-track Hill-Sachs lesion and glenoidal bone loss greater than subcritical (13.5% of anteroposterior diameter) do not present significant clinical relationship with recurrence rate and Rowe score, despite having high negative predictive value.

Financial support

There was no financial support from public, commercial, or non-profit sources.

Conflict of Interests

The authors declare that there is no conflict of interests.

References

- 1 Handoll HHG, Almaiyah MA, Rangan A. Surgical versus non-surgical treatment for acute anterior shoulder dislocation. *Cochrane Database Syst Rev* 2004;(01):CD004325
- 2 Balg F, Boileau P. The instability severity index score. A simple pre-operative score to select patients for arthroscopic or open shoulder stabilisation. *J Bone Joint Surg Br* 2007;89(11):1470-1477
- 3 Di Giacomo G, Itoi E, Burkhart SS. Evolving concept of bipolar bone loss and the Hill-Sachs lesion: from “engaging/non-engaging” lesion to “on-track/off-track” lesion. *Arthroscopy* 2014;30(01):90-98
- 4 Phadnis J, Arnold C, Elmsory A, Flannery M. Utility of the Instability Severity Index Score in Predicting Failure After Arthroscopic Anterior Stabilization of the Shoulder. *Am J Sports Med* 2015;43(08):1983-1988
- 5 Ferreira Neto AA, Camanho GL, Felix AM, et al. Tratamento artroscópico da instabilidade anterior do ombro: estudo retrospectivo de 159 casos. *Acta Ortop Bras* 2011;19(01):41-44
- 6 Burkhart SS, De Beer JF. Traumatic glenohumeral bone defects and their relationship to failure of arthroscopic Bankart repairs: significance of the inverted-pear glenoid and the humeral engaging Hill-Sachs lesion. *Arthroscopy* 2000;16(07):677-694
- 7 Yamamoto N, Itoi E, Abe H, et al. Contact between the glenoid and the humeral head in abduction, external rotation, and horizontal extension: a new concept of glenoid track. *J Shoulder Elbow Surg* 2007;16(05):649-656
- 8 Pécora JOR, Neves Junior AT, Roesler CRM, et al. Glenoid track evaluation by a validated finite-element shoulder numerical model. *Orthop Traumatol Surg Res* 2020;106(04):735-742
- 9 Yamamoto N, Kawakami J, Nagamoto H, Shiota Y, Itoi E. The relationship between the glenoid track and the range of shoulder motion: A cadaver study. *Orthop Traumatol Surg Res* 2018;104(06):793-796

- 10 Momaya AM, Tokish JM. Applying the Glenoid Track Concept in the Management of Patients with Anterior Shoulder Instability. *Curr Rev Musculoskelet Med* 2017;10(04):463–468
- 11 Gulati A, Dessouky R, Wadhwa V, Sanders D, Chhabra A. New concepts of radiologic preoperative evaluation of anterior shoulder instability: on-track and off-track lesions. *Acta Radiol* 2018;59(08):966–972
- 12 Ho A, Kurdziel MD, Koueiter DM, Wiater JM. Three-dimensional computed tomography measurement accuracy of varying Hill-Sachs lesion size. *J Shoulder Elbow Surg* 2018;27(02):350–356
- 13 Burns DM, Chahal J, Shahrokhi S, et al. Diagnosis of Engaging Bipolar Bone Defects in the Shoulder Using 2-Dimensional Computed Tomography: A Cadaveric Study. *Am J Sports Med* 2016;44(11):2771–2777
- 14 Shaha JS, Cook JB, Rowles DJ, Bottoni CR, Shaha SH, Tokish JM. Clinical Validation of the Glenoid Track Concept in Anterior Glenohumeral Instability. *J Bone Joint Surg Am* 2016;98(22):1918–1923
- 15 Locher J, Wilken F, Beitzel K, et al. Hill-Sachs Off-track Lesions as Risk Factor for Recurrence of Instability After Arthroscopic Bankart Repair. *Arthroscopy* 2016;32(10):1993–1999
- 16 Shaha JS, Cook JB, Song DJ, et al. Redefining “Critical” Bone Loss in Shoulder Instability: Functional Outcomes Worsen With “Subcritical” Bone Loss. *Am J Sports Med* 2015;43(07):1719–1725
- 17 Rowe CR, Patel D, Southmayd WW. The Bankart procedure: a long-term end-result study. *J Bone Joint Surg Am* 1978;60(01):1–16
- 18 Assunção JH, Gracitelli ME, Borgo GD, Malavolta EA, Bordalo-Rodrigues M, Ferreira Neto AA. Tomographic evaluation of Hill-Sachs lesions: is there a correlation between different methods of measurement? *Acta Radiol* 2017;58(01):77–83
- 19 Miyazaki AN, Silva LA, Santos PD, Sella GDV, Nagaya LH, Checchia SL. Hill-Sachs lesion measurement with tridimensional models in anterior shoulder instability. *Rev Bras Ortop* 2018;53(03):357–363
- 20 Chuang TY, Adams CR, Burkhart SS. Use of preoperative three-dimensional computed tomography to quantify glenoid bone loss in shoulder instability. *Arthroscopy* 2008;24(04):376–382
- 21 Itoi E, Lee SB, Amrami KK, Wenger DE, An KN. Quantitative assessment of classic anteroinferior bony Bankart lesions by radiography and computed tomography. *Am J Sports Med* 2003;31(01):112–118
- 22 Godinho GG, Freitas JMA, França FdeO, de Lago E Santos FM, Aragão AA, Barros MK. Bankart arthroscopic procedure: comparative study on use of double or single-thread anchors after a 2-year follow-up. *Rev Bras Ortop* 2014;50(01):94–99
- 23 de Almeida Filho IA, de Castro Veado MA, Fim M, da Silva Corrêa LV, de Carvalho Junior AE. Functional assessment of arthroscopic repair for recurrent anterior shoulder instability. *Rev Bras Ortop* 2015;47(02):214–221
- 24 França FO, Godinho AC, Carneiro Leal DPC, Mantovani MM, Frazão RR, Mariz RF. Clinical and Image Outcomes of the Hill-Sachs Injury Approach by the Remplissage Technique on the Anterior Shoulder Instability. *Rev Bras Ortop* (Sao Paulo) 2019;54(01):13–19
- 25 Gracitelli MEC, Helito CP, Malavolta EA, et al. Results from filling “Remplissage” arthroscopic technique for recurrent anterior shoulder dislocation. *Rev Bras Ortop* 2015;46(06):684–690
- 26 Ikemoto RY, Murachovisky J, Nascimento LGP, et al. Results from Latarjet Surgery for treating traumatic anterior shoulder instability associated with bone erosion in the glenoid cavity, after minimum follow-up of one year. *Rev Bras Ortop* 2015;46(05):553–560
- 27 Ferreira AA, Malavolta EA, Gracitelli MEC, et al. Treatment of recurrent anterior shoulder dislocation with Bristow-Latarjet procedure. *Acta Ortop Bras* 2021;29(01):39–44
- 28 da Silva LA, da Costa Lima ÁG, Kautsky RM, Santos PD, do Val Sella G, Checchia SL. Evaluation of the results and complications of the Latarjet procedure for recurrent anterior dislocation of the shoulder. *Rev Bras Ortop* 2015;50(06):652–659
- 29 Schneider AK, Hoy GA, Ek ET, et al. Interobserver and intraobserver variability of glenoid track measurements. *J Shoulder Elbow Surg* 2017;26(04):573–579
- 30 Bottoni CR, Johnson JD, Zhou L, et al. Arthroscopic Versus Open Anterior Shoulder Stabilization: A Prospective Randomized Clinical Trial With 15-Year Follow-up With an Assessment of the Glenoid Being “On-Track” and “Off-Track” as a Predictor of Failure. *Am J Sports Med* 2021;49(08):1999–2005