



# Histomorphometry of Bone Microarchitecture in Rats Treated with Vitamin D and Bisphosphonate in the Management of Osteoporosis

## *Histomorfometria da microarquitetura óssea em ratas tratadas com vitamina D e bisfosfonato no manejo da osteoporose*

José Reginaldo Alves de Queiroz Júnior<sup>1</sup> Marina Falcão de Souza Cartaxo<sup>2</sup> Sylvania Tavares Paz<sup>3</sup>  
Fernanda das Chagas Ângelo Mendes Tenório<sup>4</sup> Ana Janaína Jeanine Martins de Lemos<sup>5</sup>  
Carina Scanoni Maia<sup>4</sup>

<sup>1</sup> Center of Medical Sciences, Universidade Federal de Pernambuco, Recife, PE, Brazil

<sup>2</sup> Keizo Adami Immunopathology Laboratory, Universidade Federal de Pernambuco, Recife, PE, Brazil

<sup>3</sup> Department of Pathology, Universidade Federal de Pernambuco, Recife, PE, Brazil

<sup>4</sup> Department of Histology and Embryology, Universidade Federal de Pernambuco, Recife, PE, Brazil

<sup>5</sup> Center for Biological and Health Sciences, Department of Animal Morphology and Physiology, Universidade Federal de Campina Grande, Campina Grande, PB, Brazil

Address for correspondence Carina Scanoni Maia, PhD, Av. da Engenharia, 50730-120, Recife, PE, Brasil  
(e-mail: carina.scanoni@gmail.com).

Rev Bras Ortop 2022;57(2):267–272.

### Abstract

**Objective** To verify how the combined administration of alendronate (ALN) and vitamin D3 (VD) acts on the bone microarchitecture in rats with glucocorticoid-induced osteoporosis.

**Methods** The experiment used 32 90-day-old female Wistar rats weighing between 300 and 400g. The induction of osteoporosis consisted of intramuscular administration of dexamethasone at a dose of 7.5 mg/kg of body weight once a week for 5 weeks, except for the animals in the control group. The animals were separated into the following groups: G1 (control group without osteoporosis), G2 (control group with osteoporosis without treatment), G3 (group with osteoporosis treated with ALN 0.2 mg/kg), G4 (group with osteoporosis treated with VD 10,000UI/500µL), and G5 (group with osteoporosis treated with ALN + VD). The right femurs of the rats were fixed in 10% buffered formaldehyde, decalcified, and processed for inclusion in paraffin.

### Keywords

- ▶ alendronate
- ▶ vitamin D
- ▶ menopause
- ▶ femur
- ▶ rats

Work developed at the Department of Histology and Embryology of the Universidade Federal de Pernambuco, Recife, PE, Brazil.

received  
May 28, 2021  
accepted  
September 9, 2021  
published online  
March 11, 2021

DOI <https://doi.org/10.1055/s-0041-1741023>.  
ISSN 0102-3616.

© 2021. Sociedade Brasileira de Ortopedia e Traumatologia. All rights reserved.

This is an open access article published by Thieme under the terms of the Creative Commons Attribution-NonDerivative-NonCommercial-License, permitting copying and reproduction so long as the original work is given appropriate credit. Contents may not be used for commercial purposes, or adapted, remixed, transformed or built upon. (<https://creativecommons.org/licenses/by-nc-nd/4.0/>)

Thieme Revinter Publicações Ltda., Rua do Matoso 170, Rio de Janeiro, RJ, CEP 20270-135, Brazil

Histological sections were stained with hematoxylin-eosin for histomorphometric analysis. Cortical thickness and medullary cavity were measured in cross-sections.

**Results** There was a statistical difference ( $p < 0.05$ ) between groups G3 and G5 compared with the positive control group (G2), both related to the measurement of cortical thickness and to the total diameter of the bone. In the evaluation of the spinal area, only the G3 group has shown to be statistically different from the G2 group.

**Conclusion** Concomitant treatment with daily ALN and weekly VD is effective in preventing glucocorticoid-induced bone loss. However, there was no difference between the therapy tested and treatment with ALN alone.

## Resumo

**Objetivo** Verificar como a administração conjunta de alendronato de sódio (ALN) e vitamina D<sub>3</sub> (VD) atua na microarquitetura óssea em ratas com osteoporose induzida por glicocorticoide.

**Métodos** O experimento utilizou 32 ratas da linhagem Wistar, com peso médio de 300 a 400g, com 90 dias de vida. A indução da osteoporose consistiu na administração de dexametasona na dose de 7,5 mg/kg de peso corporal, por via intramuscular, 1 vez por semana durante 5 semanas, à exceção dos animais do grupo controle. Os animais foram distribuídos nos seguintes grupos: G1 (grupo controle sem osteoporose), G2 (grupo controle com osteoporose sem tratamento), G3 (grupo com osteoporose tratado com ALN 0,2 mg/kg), G4 (grupo com osteoporose tratado com VD 10.000UI/500µL) e G5 (grupo com osteoporose tratado com ALN + VD). Os fêmures direitos das ratas foram fixados em formol a 10% tamponado, descalcificados e processados para inclusão em parafina. Os cortes histológicos foram corados com hematoxilina-eosina para análise histomorfométrica. A espessura cortical e a cavidade medular foram medidas em cortes transversais.

**Resultados** Houve diferença estatística ( $p < 0,05$ ) entre os grupos G3 e G5 em relação ao grupo controle positivo (G2), tanto em relação à medida da espessura cortical quanto em relação ao diâmetro total do osso. Na avaliação da área medular, apenas o grupo G3 se mostrou estatisticamente diferente do grupo G2.

**Conclusão** O tratamento concomitante com ALN diário e VD semanal é eficaz para prevenir a perda óssea induzida por glicocorticoide. No entanto, não houve diferença entre esta terapia testada e o tratamento apenas com o ALN.

## Palavras-chave

- ▶ alendronato
- ▶ vitamina D
- ▶ menopausa
- ▶ fêmur
- ▶ ratos

## Introduction

Osteoporosis is a disease marked by loss of mineralized bone mass, making it fragile and vulnerable to fractures. Anatomically, there is a decrease in cortical thickness and porosity, a reduction in the number and size of spongy bone trabeculae, and an enlargement of the medullary spaces.<sup>1,2</sup> Currently, the world is experiencing an expansion of the incidence of osteoporosis in both genders, especially in women > 50 years old, as a result of the continuous aging of the population.<sup>3</sup>

Worldwide, osteoporosis is a disease that affects > 200 million people. Even though it is a disease that can affect both genders, postmenopausal women are the main risk group, with an estimated prevalence of 30% in Western countries.<sup>4</sup> For the year 2050, it is estimated that 70% of the hip fractures that will occur in Africa, Asia, and Latin America will be related to osteoporosis; therefore, osteoporosis of great clinical importance.<sup>5</sup>

Several effective therapies are competent to produce an attenuation in the risk of fractures, especially in postmenopausal women. Nitrogen bisphosphonates (BFs) are the most recommended class of drugs for the treatment of postmenopausal osteoporosis. They act by inhibiting bone resorption with few side effects.<sup>1</sup> Among the most used BFs, sodium alendronate (ALN) stands out.<sup>1,6</sup>

Vitamin D (VD) is a steroid hormone that has varied biological actions in different target tissues.<sup>7</sup> There is already significant evidence that low serum calcium and VD levels accelerate bone loss.<sup>8</sup>

The biomechanical competence of bone is related not only to the amount of bone present, but also to its microstructure.<sup>9</sup> Thus, bone histomorphometry is one of the conventional methods to analyze its microarchitecture, which allows, in a safe way, to qualify and quantify bone structures.<sup>10</sup> Thus, it plays a prominent role in the study of certain metabolic disorders and their treatments.

Thus, the aim of the present study was to verify how the combined administration of ALN and VD acts on bone microarchitecture in the treatment groups of Wistar rats with glucocorticoid-induced osteoporosis.

## Materials and Methods

All procedures were approved by the Ethics Committee on the Use of Animals (CEUA) of the Universidade Federal de Pernambuco (UFPE, in the Portuguese acronym), Recife, state of Pernambuco, Brazil (Protocol No. 034/2020).

### Experimental procedure

An experimental, double-blind animal study (evaluator and pathologist) was carried out. In the present work, 32 female Wistar rats (*Rattus norvegicus albinus*) between 8 and 10 weeks old and weighing between 300 and 400g from the Physiology Bioterium of the UFPE were used.

The animals were housed in individual polypropylene cages with metal lids, kept in rooms with a controlled ambient temperature of 22°C, with luminosity of 60 lux, kept in a light/dark cycle of 12 hours controlled by time sensor, on a shaving bed, fed with feed for rats and water *ad libitum*.

After a period of 60 days, the animals were randomly divided into 5 groups, as shown in ►Table 1. Groups G2, G3, G4, and G5 had osteoporosis induced with the use of intramuscular dexamethasone, while the animals of group G1 were kept without induction of osteoporosis to establish the parameter of the negative control group.

The process of induction of osteoporosis was performed with the administration of glucocorticoid dexamethasone intramuscularly at a weekly dose of 7.5 mg/kg of body weight for 5 weeks. At the end of the 5<sup>th</sup> week of the administration of dexamethasone, the animals were submitted to pharmacotherapeutic treatment.

The daily volume of therapeutic drugs administered to all groups was 0.03mL of vehicle. Sodium alendronate administration alone occurred at a dosage of 0.2mg/kg daily for 45 days. Vitamin D<sub>3</sub> was administered at a dose of 500 µL (10,000IU/500µL) once a week during the 8-week supplementation period. The same period and dosage were used for weekly administration in the combination of the two drugs. The control group animals received distilled water for the

same period and in the same amount as the experimental groups. The medications were administered orally (gavage method) by appropriate cannulas.

### Histomorphometry

After completing the therapeutic regimen, the rats were euthanized with anesthetic deepening based on xylasin hydrochloride at 2% associated with ketamine hydrochloride 10% for removal of the right and left femurs using a scalpel blade no. 11 and 15 to perform histological analyses, which were stored in 10% formaldehyde in properly labeled containers, according to the sample group of each animal.

After collection of femoral bones, 64 specimens were obtained, fixed in 10% formaldehyde, and kept for a period of 48 hours, necessary for fixation, until the moment of preparation. The 64 specimens were divided as follows: the right femurs were submitted to histological evaluation, while the left femurs were macroscopically evaluated. The preparation followed the routine patterns for histological study in all right femurs. After the fixation period, the 32 femurs were decalcified with a solution of nitric acid (HNO<sub>3</sub>) at 5%, changed daily, for 5 days.

After decalcification, the samples were washed in distilled water and placed in the histotechnical processor Leica and subsequent inclusion in paraffin Paraplast. With the aid of a microtome (Hestion), all blocks containing the femoral fragments were sectioned longitudinally at a thickness of 4 µm and placed on slides previously greased with Mayer albumin and kept in a regulated oven at 37°C for 24 hours for drying and gluing.

Subsequently, they were cordoned by hematoxylin and eosin (H&E) according to the methodology of Junqueira et al.<sup>11</sup> The samples were then analyzed under a light microscope and the sections were photographed in a Nikon 50E Trinocular Biological Microscope with VT 480 videomicroscopy and image analyzer. All stages of the histological procedure were performed at the Graduate Laboratory in Translational Health of the UFPE.


For the study of the compact bone, cross-sections of the diaphysis of the right femur of each animal were used. In these sections, cortical bone thickness was analyzed by acquiring images of the medial part of the diaphysis. Four measurements were made in each histological section, prioritizing the upper, lower, and lateral regions of each section.<sup>12</sup> To determine the thickness, cortical bone was measured from the periosteal surface to the endosteal surface using the properly calibrated IMAGE-Pro Plus program (►Figure 1A). From this, the mean cortical thickness for each bone was calculated.

In the measurement of the area of the medullary cavity of the bones, the automatic measurement performed by the image analysis system IMAGE-Pro Plus, previously calibrated (►Figure 1B), and with the functions determined by a specific macro, was used.

For the calculation of bone diameter, the methodology developed by Parfitt et al. was used.<sup>13</sup> In this evaluation, the bone is approximated to a cylinder. Thus, with the measurement of the medullary area, it is possible to calculate the

**Table 1** Groups used for the tests of the present study

Group	Number of animals	Group description	Induction of osteoporosis
G1	6	Distilled water orally	No
G2	6	Distilled water orally	Yes
G3	7	Oral sodium alendronate	Yes
G4	7	Vitamin D <sub>3</sub> orally	Yes
G5	6	Sodium alendronate and Vitamin D <sub>3</sub> orally	Yes



**Fig. 1** (A) Measurement of cortical thickness ( $\mu\text{m}$ ) in femur under final increase of 40X. (B) Automatic measurement of the delineated medullary area ( $\mu\text{m}^2$ ).

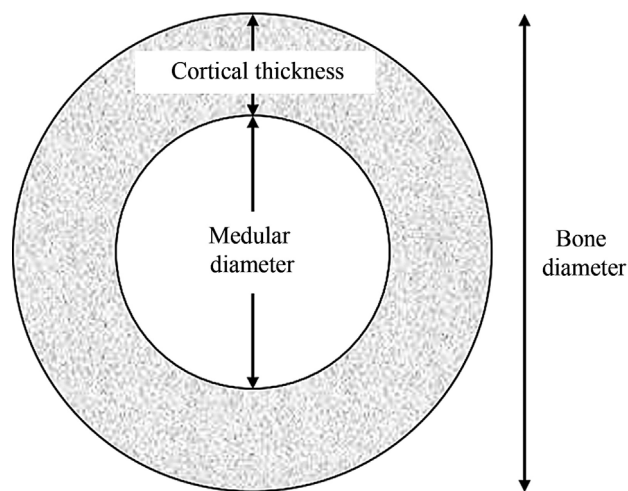
medullary diameter so that, together with the cortical thickness value, it is possible to arrive at the estimate of the bone diameter ( $\rightarrow$ Figure 2).

**Statistical analysis**

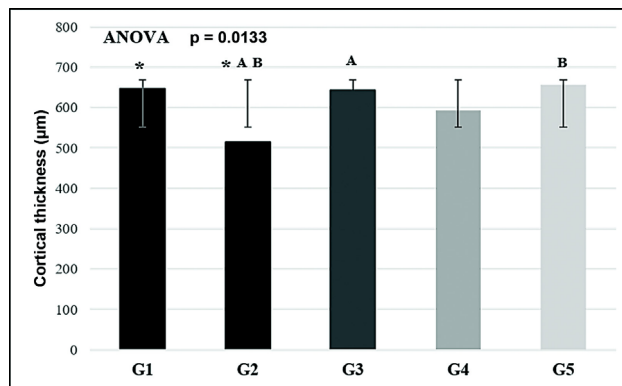
All statistical analyses were performed with the Minitab software, version 19. The data were reported as mean with standard deviation (SD). The variables were also tested for their normality through the Shapiro-Wilk test, obtaining a parametric distribution. For the analysis of the results, the one-way analysis of variance (ANOVA) test was used, followed by the Bonferroni post-test. Statistical significance was defined for a p-value < 0.05. All p-values shown are two-tailed.

**Results**

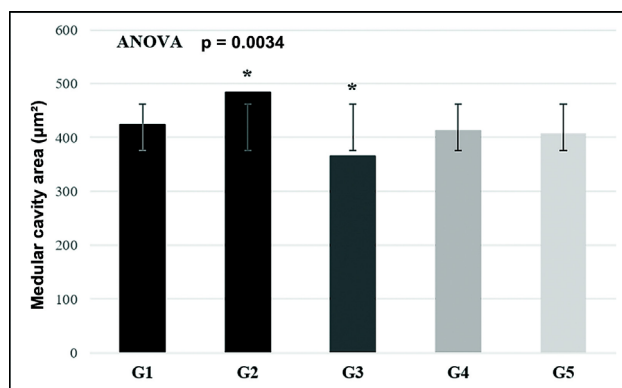
In all analyses performed ( $\rightarrow$ Figures 3, 4 and 5), a statistically significant difference was found ( $p < 0.05$ ; one-way ANOVA test) between the tested groups. Analyzing  $\rightarrow$ Figure 2 the femoral diaphysis of the rats, a significantly higher value can be observed in the cortical thickness ( $\mu\text{m}$ ) of groups G1 ( $648.22 \pm 77.51$ ), G3 ( $643.15 \pm 59.03$ ), and G5



**Fig. 2** Histomorphometry of the bone diameter of the femoral diaphysis of the rats. Average  $\pm$  standard deviation. Presence of statistically significant difference ( $p < 0.05$ ) between pairs marked with the same superscript symbol.



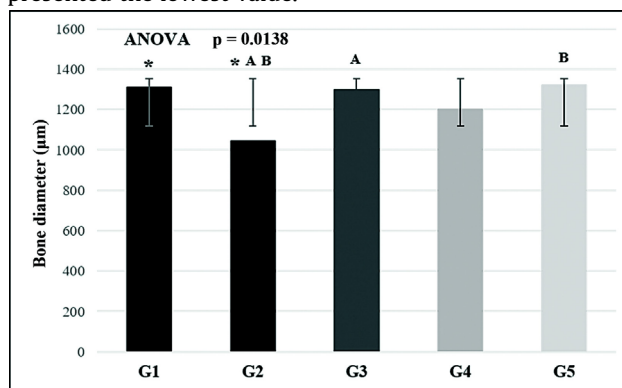
**Fig. 3** Cross-sectional representation of femoral diameter for bone diameter calculation. Adapted from Parfitt et al.<sup>13</sup>.



**Fig. 4** Histomorphometry of cortical thickness of the femoral diaphysis of the rats. Average  $\pm$  standard deviation. Presence of statistically significant difference ( $p < 0.05$ ) between pairs marked with the same superscript symbol.

( $654.57 \pm 79.00$ ) compared with that of group G2 ( $515.53 \pm 76.38$ ).

In the measurement of the medullary area ( $\mu\text{m}^2$ ) ( $\rightarrow$ Figure 4), the group that underwent monotherapy with ALN (G3) ( $365.18 \pm 49.99$ ) was statistically different only when compared with group G2 ( $484.02 \pm 46.36$ ), which presented the lowest value.



**Fig. 5** Histomorphometry of the area of the medullary cavity of the femoral diaphysis of the rats. Average  $\pm$  standard deviation. Presence of statistically significant difference ( $p < 0.05$ ) between pairs marked with the same superscript symbol.

Regarding the analysis of the femoral diameter of the rats (► **Figure 5**), a significantly higher value was observed in groups G1 ( $1309.54 \pm 154.89$ ), G3 ( $1298.45 \pm 117.65$ ), and G5 ( $654.57 \pm 79.00$ ) compared with the group with osteoporosis and without treatment (G2) ( $1321.97 \pm 158.40$ ).

## Discussion

Within the spectrum of pharmacological treatments of osteoporosis, therapeutic agents can be divided into two major classes: antiresorptive compounds and bone formation stimulants.<sup>14</sup> The former reduce osteoclastic activity, which forms gaps in the surface of the bones, allowing them to be filled by a new matrix before the remodeling cycle restarts. The second compounds, also called anabolic agents, intensify the action of osteoblasts, which, in each remodeling cycle, increases the deposition of osteoid matrix.<sup>14,15</sup>

Among the drugs with antiresorptive action, we can mention BFs, calcitonin, estrogens, and selective modulators of estrogen receptors. Fluoride, parathyroid hormone, and teriparatide are examples of anabolic agents.<sup>15</sup>

Bisphosphonates form a class of chemicals that act as inhibitors of bone resorption.<sup>16</sup> Sodium alendronate is a powerful second-generation BF, which initially fixates on the bone matrix and is later assimilated by osteoclasts to, then, inhibit its action. It inhibits farnesyl diphosphate synthesis by blocking the signaling pathway of mevalonate in osteoclasts, also inhibiting the activation factors thereof, such as receptor activator of nuclear factor kappa-B ligand (RANKL), which is the main mediator of osteoclastic differentiation, activation, and proliferation.<sup>17</sup> However, there are concerns regarding adverse effects related to chronic use of BFs, such as musculoskeletal pain, atypical fracture of the femur, osteonecrosis of the jaw, and severe suppression of bone remodeling.<sup>18</sup>

Vitamin D plays a crucial role in a multitude of physiological functions, such as in modulating calcium homeostasis and skeletal phosphate; it exerts a significant influence on the growth and differentiation of various tissues; it has immunomodulatory functions; and it also acts on bone mineralization, muscle functions, and balance.<sup>19,20</sup>

Vitamin D deficiency is common in patients with osteoporosis and hip fractures. Inadequate VD levels are considered one of the potential factors for failure of drug treatment of osteoporosis (significant loss of bone mineral density and fractures).<sup>16</sup>

1,25 dihydroxycholecalciferol, or calcitriol, is the active metabolite of VD and is responsible for regulating the expression of genes encoding several proteins, including calcium and bone matrix transporters. In addition, VD modulates genes involved in the protein cycle that decrease proliferation and increase cell differentiation, such as osteoclastic precursors. This property may explain the action of VD on bone resorption, on intestinal calcium transport, and on the skin.<sup>21,22</sup>

According to Ferreira Junior et al.,<sup>23</sup> the histomorphometric study of bone is an extremely valuable method for the dynamic evaluation of the bone remodeling process and to

determine the extent of bone loss and of bone tissue formation, being able to identify osteometabolic changes such as osteoporosis.

Dexamethasone-induced osteoporosis is characterized by two phases: a rapid phase in which bone mineral density (BMD) is reduced, probably due to excessive bone resorption, via osteoclasts, and a late, progressive, phase in which BMD decreases due to impairment in bone formation.<sup>24</sup> Analyzing the results obtained for positive control for osteoporosis (G2), it is possible to verify that the osteoporotic induction process was successful, since, when compared with the negative control (G1; without osteoporosis), there was a reduction in cortical thickness and an increase in medullary spaces, both measurements with a statistically significant difference in relation to the negative control group (G1). These characteristics, along with other measurements not explored in the present study, are marks of osteoporosis.<sup>25</sup>

The results of the present study also demonstrated that, when analyzing bone cortical thickness, both ALN monotherapy and combination therapy with ALN + VD were able to preserve bone structure. However, there was no difference when commencing these therapeutic regimens. Isolated VD therapy has not been shown to be statistically capable of preserving bone mass in osteoporotic states. This same evaluation can be applied to bone diameter analysis.

Regarding the other histomorphometric measurement evaluated, the area of the medullary cavity, it was observed that only therapy with ALN was able to demonstrate an important effect on the preservation of bone mass. Thus, there was less effect on trabecular bones when neither the combination therapy focused on this study nor the isolated treatment with VD was used. This result differs from others found in the literature, which demonstrated that VD alone was able to significantly increase bone mass in rats.<sup>26-28</sup> However, it is noteworthy that, although there was no statistical difference in the paired evaluation, in all global analyses of the three variables (cortical thickness, medullary area, and bone diameter), the *p*-values were statistically significant.

## Conclusion

Together, the data presented in the present study demonstrate that concomitant treatment with daily ALN and weekly VD is effective in the prevention of glucocorticoid-induced bone loss. However, there was no difference between the therapy tested and treatment only with ALN. Since prolonged use of BFs, such as ALN, can cause serious adverse effects, its association with VD may be clinically a good choice to replace ALN, since histomorphometric analyses showed similarities in bone mass preservation results and VD, due to its properties, may possibly avoid and/or minimize these problems associated with ALN therapy.

### Financial Support

The present study received no financial support from public, commercial, or not-for-profit sources.



**Conflict of Interests**

The authors have no conflict of interests to declare.

**References**

- Radominski SC, Bernardo W, Paula AP, et al. Diretrizes brasileiras para o diagnóstico e tratamento da osteoporose em mulheres na pós-menopausa. *Rev Bras Reumatol* 2017;57(S 2):S452–S466
- Cosman F, de Beur SJ, LeBoff MS, et al. National Osteoporosis Foundation. Clinician's Guide to Prevention and Treatment of Osteoporosis. *Osteoporos Int* 2014;25(10):2359–2381 [published correction appears in *Osteoporos Int* 2015;26(7):2045–2047]
- Si L, Winzenberg TM, Chen M, Jiang Q, Palmer AJ. Residual lifetime and 10 year absolute risks of osteoporotic fractures in Chinese men and women. *Curr Med Res Opin* 2015;31(06):1149–1156
- NIH Consensus Development Panel on Osteoporosis Prevention, Diagnosis, and Therapy. Osteoporosis prevention, diagnosis, and therapy. *JAMA* 2001;285(06):785–795
- Lazaretti-Castro M, Eis SR, Marques Neto JF. A prevenção da osteoporose levada a sério: uma necessidade nacional. *Arq Bras Endocrinol Metabol* 2008;52(04):712–713
- Kocijan R, Klaushofer K, Misof BM. Osteoporosis Therapeutics 2020. *Handb Exp Pharmacol* 2020;262:397–422
- Mabey T, Honsawek S. Role of Vitamin D in Osteoarthritis: Molecular, Cellular, and Clinical Perspectives. *Int J Endocrinol* 2015;2015:383918
- Rosen CJ. The Epidemiology and Pathogenesis of Osteoporosis. In: Feingold KR, Anawalt B, Boyce A, et al., editors. *Endotext* [Internet]. South Dartmouth, MA: MDText.com, Inc.; 2000 Available from: <https://www.ncbi.nlm.nih.gov/books/NBK279134/>
- Gameiro VS, Schott PCM. A osteoporose em fraturas proximais do fêmur: estudo histomorfométrico. *Rev Bras Ortop* 2006;41(03):61–69
- Arlot ME, Jiang Y, Genant HK, et al. Histomorphometric and microCT analysis of bone biopsies from postmenopausal osteoporotic women treated with strontium ranelate. *J Bone Miner Res* 2008;23(02):215–222
- Junqueira LCU, Junqueira LMM. Técnicas básicas de citologia e histologia. São Paulo: Editora Santos; 1983
- Carvalho ACB, Henriques HN, Pantaleão JAS, et al. Histomorfometria do tecido ósseo em ratas castradas tratadas com tibolona. *J Bras Patol Med Lab* 2010;46(03):235–243
- Parfitt AM, Drezner MK, Glorieux FH, et al. Bone histomorphometry: standardization of nomenclature, symbols, and units. Report of the ASBMR Histomorphometry Nomenclature Committee. *J Bone Miner Res* 1987;2(06):595–610
- Mata PR, Martins PA, Brito LG, Ramos MMP, Santos Junior MC. Tratamento farmacológico para a osteoporose. *Geriatr Gerontol Aging* 2012;6(04):422–431
- Radominski SC, Bernardo W, Paula AP, et al. Brazilian guidelines for the diagnosis and treatment of postmenopausal osteoporosis. *Rev Bras Reumatol Engl Ed* 2017;57(Suppl 2):452–466
- Oliveira MM, Mendonça JCG, Masocatto DS, Oliveira JM, Jardim ECG. Osteonecrose dos Maxilares Associada ao uso de Bisfosfonato. *Salusvita*, Bauru 2015;34(02):341–352
- Vidal MA, Medina C, Torres LM. Seguridad de los bifosfonatos. *Revista Soc Esp Dolor* 2011;18(01):43–55
- Shane E. Evolving data about subtrochanteric fractures and bisphosphonates. *N Engl J Med* 2010;362(19):1825–1827
- Sutton AL, MacDonald PN. Vitamin D: more than a “bone-a-fide” hormone. *Mol Endocrinol* 2003;17(05):777–791
- Jehan F, Voloc A. Actions classiques de la vitamine D : apport de la génétique humaine et de modèles de souris génétiquement modifiées. *Biol Aujourd'hui* 2014;208(01):45–53
- Khajuria DK, Razdan R, Mahapatra DR. Medicamentos para o tratamento da osteoporose: revisão. *Rev Bras Reumatol* 2011;51(04):365–382
- Harvey RA, Ferrier DR. *Bioquímica ilustrada*. 5ª. ed. Porto Alegre: Artmed; 2012
- Ferreira DB Junior, Pinto AS, Del Carlo RJ, et al. Efeitos de bifosfonatos e estatinas na reparação de fraturas em tíbias de ratas com osteoporose induzida com dexametasona. *Rev Cienc Farm Basica Apl* 2008;29(02):203–207
- Canalis E, Mazziotti G, Giustina A, Bilezikian JP. Glucocorticoid-induced osteoporosis: pathophysiology and therapy. *Osteoporos Int* 2007;18(10):1319–1328
- Valente FL, Ferreira APB, Costa LD, Mouzada MJQ, Patarroyo JH, Vargas MI. Effects of chronic mild stress on parameters of bone assessment in adult male and female rats. *Pesq Vet Bras* 2016;36(01):106–112
- Aerssens J, van Audekercke R, Talalaj M, Geusens P, Bramm E, Dequeker J. Effect of 1alpha-vitamin D3 and estrogen therapy on cortical bone mechanical properties in the ovariectomized rat model. *Endocrinology* 1996;137(04):1358–1364
- Shiraishi A, Takeda S, Masaki T, et al. Alfacalcidol inhibits bone resorption and stimulates formation in an ovariectomized rat model of osteoporosis: distinct actions from estrogen. *J Bone Miner Res* 2000;15(04):770–779
- Nishikawa T, Ogawa S, Kogita K, et al. Additive effects of combined treatment with etidronate and alfacalcidol on bone mass and mechanical properties in ovariectomized rats. *Bone* 2000;27(05):647–654