



Isolated Complete Distal Biceps Femoris Tendon Tears: Case Series and Literature Review

Christine Azzopardi¹ David Beale² Steven L. James¹ Rajesh Botchu¹

¹Department of Musculoskeletal Radiology, Royal Orthopaedic Hospital, Birmingham, United Kingdom

²Department of Radiology, Heath Lodge Clinic, Knowle, United Kingdom

Address for correspondence Rajesh Botchu, MBBS, Department of Musculoskeletal Radiology, The Royal Orthopedic Hospital, Bristol Road South, Northfield, Birmingham, United Kingdom (e-mail: drbrajesh@yahoo.com).

Indian J Radiol Imaging 2021;31:998–1001.

Abstract

The Biceps femoris is a vital component of the posterolateral corner of the knee. We report two cases of isolated rupture of the biceps femoris, discuss the possible mechanism of injury, and review the literature.

Keywords

- ▶ biceps femoris
- ▶ tear
- ▶ isolated

Introduction

The biceps femoris forms an integral part of the posterior compartment of the thigh and plays a pivotal role in knee flexion.¹ Distally the biceps femoris tendon forms part of the posterolateral corner structures of the knee.¹ Injury to these structures is usually associated with rotational trauma. It is rare to have an isolated distal biceps femoris tendon disruption as this injury is often associated with other posterolateral corner structure injuries and intra-articular pathology such as ACL tears.²

We present two cases of isolated complete biceps femoris tendon disruption proximal to the fibular head insertion together with a review of the current literature.

Background

The biceps femoris tendon is an essential component of the posterolateral corner acting as a dynamic stabilizer, while the lateral collateral ligament, along with the popliteus tendon and popliteofibular ligament act as static stabilizers.³ Altogether, they prevent varus and external rotation forces and posterior tibial translation.³

The biceps femoris muscle is the strongest of the hamstring complex. It is composed of a long and a short head. The long head of the biceps femoris muscle originates from the medial aspect of the ischial tuberosity and the inferior aspect of the sacrotuberous ligament, while the short head of the biceps femoris muscle arises from the lateral lip of the linea aspera of the femur, proximal two-thirds of the supracondylar line, and the lateral intermuscular septum.⁴ Because the short and long heads of the biceps femoris muscle are innervated by the peroneal and tibial components of the sciatic nerve, respectively, this may result in an increased risk of sports injury as a result of uncoordinated muscle contractions.

Distally, the biceps femoris tendon inserts predominantly onto the head of the fibula and has two tendinous insertions. A direct arm that attaches to the posterolateral edge of the fibular head and a reflected arm blends into the iliotibial tract. Also, crossing lateral to the lateral collateral ligament is the anterior arm¹ (▶**Fig. 1**). The biceps femoris is the strongest hamstring involved in knee flexion and also contributing to external rotation. It plays an important role in varus angulation, controlling tibial internal rotation. In collaboration with the medial hamstrings, it also prevents excessive tibiofemoral anterior translation.⁶

published online
January 10, 2022

DOI <https://doi.org/10.1055/s-0041-1741106>.
ISSN 0971-3026.

© 2022. Indian Radiological Association. All rights reserved.

This is an open access article published by Thieme under the terms of the Creative Commons Attribution-NonDerivative-NonCommercial-License, permitting copying and reproduction so long as the original work is given appropriate credit. Contents may not be used for commercial purposes, or adapted, remixed, transformed or built upon. (<https://creativecommons.org/licenses/by-nc-nd/4.0/>)

Thieme Medical and Scientific Publishers Pvt. Ltd., A-12, 2nd Floor, Sector 2, Noida-201301 UP, India

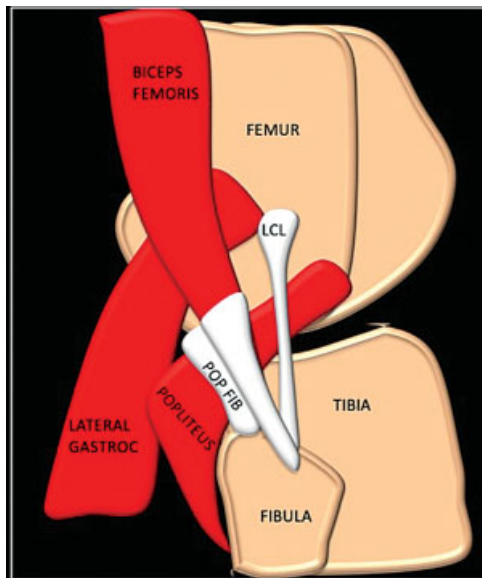


Fig. 1 Schematic showing the posterolateral corner structures POP FIB, popliteofibular ligament; LCL, lateral collateral ligament; Lateral Gastroc, lateral gastrocnemius.

We present two cases of isolated biceps femoris tendon injury immediately proximal to the fibular attachment.

Case 1

A 60-year-old gentleman presented with acute onset knee pain following an attempt at kicking a football. He reported a snapping sound followed by sudden onset swelling.

On examination, there was tenderness to palpation over the fibular head and associated overlying bruising and swelling. As a general rule, the clinical examination should include assessment of ligamentous stability to anterior and posterior drawer tests as distal biceps injury rarely occurs in isolation. As the peroneal nerve is closely related to the distal biceps, femoris a neurological examination should be performed to exclude associated injury.⁷

An MRI was performed a week after the injury that demonstrated a full-thickness tear of the biceps femoris just proximal to the fibular insertion with moderate soft tissue edema and a small hematoma. A short distal stump of the biceps femoris tendon was attached to the fibula head (► **Fig. 2**). There was no bony avulsion of the fibular head. The rest of the posterolateral corner was intact. The peroneal nerve was also preserved.

Case 2

A 23-year-old gentleman presented to the clinic after a sudden knee flexion with external rotation during a football game. On examination, the patient demonstrated tenderness on palpation of the fibular head. This was exacerbated on resisted prone knee flexion, particularly nearing a full extension.

An MRI performed within days after the injury demonstrated hematoma and edema in the lateral aspect of the knee with a near full-thickness tear of the distal biceps femoris tendon proximal to its insertion. A small distal

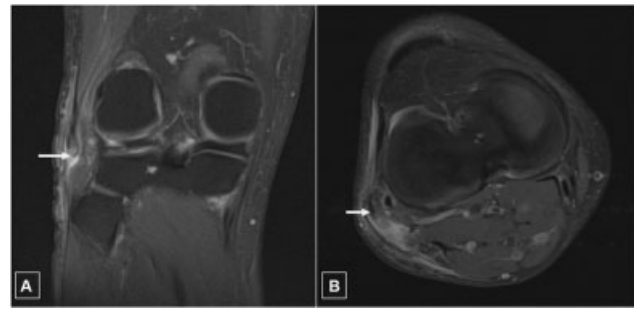


Fig. 2 Coronal (A) and axial (B) proton density fat-saturated images of the knee, demonstrating peritendinous edema around the distal biceps femoris tendon with tear and some retraction of the tendon proximally (image A, white arrow). A short distal stump of the biceps femoris tendon remains attached to the fibula head (image B, white arrow).

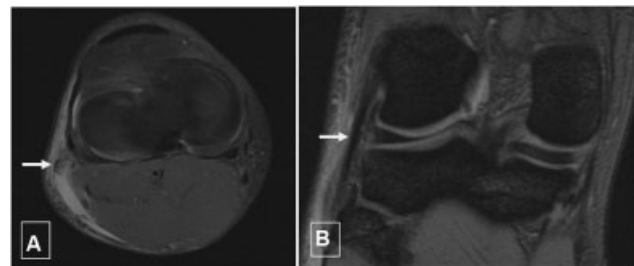


Fig. 3 Axial (A) and coronal (B) proton density fat-saturated images of the knee, demonstrating hematoma and edema in the lateral aspect of the knee. Intra-tendinous high signal intensity in keeping with hemorrhage and edema in the torn biceps femoris tendon (white arrow: image A) and intact lateral collateral ligament (arrow: image B).

tendon stump was noted. The lateral collateral ligament and remaining posterolateral stabilizing structures and peroneal nerve were also intact (► **Figs. 3** and **4**).

Both our patients were treated conservatively with relatively good function. The functional result following conservative treatment is reported in the literature as having a better outcome than cases treated surgically.⁸ Predisposing factors for isolated ruptures of the distal biceps femoris include pre-existing tendinopathy.⁹ In the cases we presented, there were no predisposing factors.

Discussion

Injuries to the distal biceps femoris tendon do not tend to occur in isolation. It often occurs in conjunction with injury to the posterolateral corner components. Isolated distal biceps femoris injuries are therefore rare and only a few cases are reported in the literature.¹

The biceps femoris is therefore often injured in conjunction with other posterolateral corner structures. The main posterolateral corner structures include the lateral collateral ligament, popliteus tendon complex, iliotibial band, fabellofibular ligament, and the middle third of the lateral capsule and lateral meniscus.^{5,6}

One of the main posterolateral corner structures, the lateral collateral ligament protects the knee against excessive

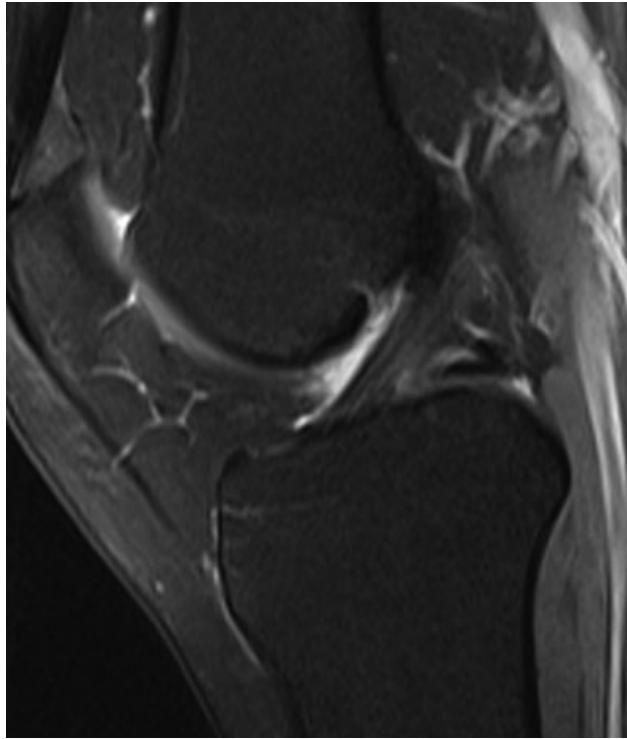

Fig. 4 Sagittal proton density fat-saturated, demonstrating normal anterior cruciate ligament.

varus forces. It extends from the lateral femoral epicondyle attaching to the anterior border of the fibular head.⁶

The popliteus tendon inserts onto the fibular head, anterior and distal to the lateral collateral insertion. It is however a dynamic stabilizer, externally rotating the knee during hyperflexion.

The iliotibial band also contributes to knee stability in varus and extension.⁶ The lateral structures are stretched to their full potential during the stance phase of the gait cycle during which the varus angulation of the limb reaches a maximum during full extension of the knee.

The knee has 4 quadrants - anterolateral, anteromedial, posteromedial and posterolateral. The most commonly injured quadrant is the anterolateral quadrant involving the anterior fibers of the iliotibial band. The mechanism of action is usually a varus force with internal rotation of the tibia. The posterolateral quadrant structures, namely the lateral collateral ligament, biceps femoris, and popliteus tendon are usually involved in varus and external rotation or sudden hyperextension.⁸

The main function of the posterolateral corner structures is to provide lateral stability and protect the knee against excessive varus forces and external tibial rotation (– **Table 1**). The following table illustrates the main components of the posterolateral corner and their contribution to stability.

After a review of the literature and the presentation of our cases, we propose that to produce an isolated tear of the biceps femoris tendon, the mechanism of injury would have to be a lack of varus force and would therefore involve eccentric contraction of the biceps muscle during hyperex-

Table 1 Function of different components of posterolateral corner

Structure	Action	Function
Biceps femoris	External rotation and flexion	Dynamic stabilizer
Lateral collateral ligament	Prevents excessive varus force	Static stabilizer
Popliteus	Externally rotating the knee during hyperflexion	Dynamic stabilizer

ension. What makes the biceps femoris unique when compared with the other posterolateral corner structures is that its long head spans across two major joints, the hip joint and the knee joint. The action of forcible hip flexion and simultaneous knee hyperextension has been shown to place a high strain on the distal biceps femoris rendering it at high risk of injury. A review of the literature by Knapik et al suggests that the distal biceps is more susceptible to eccentric loading than the tendinous insertion in the fibular head.⁹

A review of the literature by Kusma et al¹⁰ shows that the most common mechanism of injury leading to isolated biceps femoris is extension and hyperextension. This motion was present in both our cases as both involved the patient's kicking, therefore flexion followed by sudden extension/hyperextension. However, resisted flexion may also result in increased tension load on the tendon and may be caused by running or kicking backward.⁹ The lack of varus loading in our cases suggests that the absence of this is paramount in protecting the lateral collateral ligament complex in particular.

Conclusion

In summary, we propose that to tear solely the distal biceps femoris tendon, the forces should be lacking a varus component and would therefore involve eccentric contraction of the biceps muscle during hyperextension. Dedicated biomechanical studies would be needed to confirm the proposed mechanism of injury.

Conflict of Interest

None declared.

References

- Valente M, Mancuso F, Alecci V. Isolated rupture of biceps femoris tendon. *Musculoskelet Surg* 2013;97(03):263–266. Doi: 10.1007/s12306-011-0171-2
- Werlich T. Isolated rupture of the biceps tendon of the knee joint [article in German]. *Unfallchirurg* 2001;104(02):187–190
- Takahashi H, Tajima G, Kikuchi S, et al. Morphology of the fibular insertion of the posterolateral corner and biceps femoris tendon. *Knee Surg Sports Traumatol Arthrosc* 2017;25(01):184–191. Doi: 10.1007/s00167-016-4304-x
- Hsu D, Chang KV. Biceps Tendon Rupture of the Lower Limb. [Updated 2019 Jan 9]. In: StatPearls [Internet]. Treasure Island

- (FL): StatPearls Publishing; 2019 Jan-. Available from: <https://www.ncbi.nlm.nih.gov/books/NBK536969/>
- 5 Branch EA, Anz AW. Distal insertions of the biceps femoris: a quantitative analysis. *Orthop J Sports Med* 2015;3(09): 2325967115602255. Doi: 10.1177/2325967115602255
 - 6 Shon O-J, Park J-W, Kim B-J. Current concepts of posterolateral corner injuries of the knee. *Knee Surg Relat Res* 2017;29(04): 256–268. Doi: 10.5792/ksrr.16.029
 - 7 Raines BT, Pomajzl RJ, Ray TE, Bley JA, Sherman SL. Isolated complete rupture of the biceps femoris insertion: a surgical repair technique manuscript. *Arthrosc Tech* 2019;8(04):e407–e411
 - 8 Fortems Y, Victor J, Dauwe D, Fabry G. Isolated complete rupture of biceps femoris tendon. *Injury* 1995;26(04):275–276. Doi: 10.1016/0020-1383(95)90017-R
 - 9 Knapik DM, Metcalf KB, Voos JE. Isolated tearing and avulsion of the distal biceps femoris tendon during sporting activities: a systematic review. *Orthop J Sports Med* 2018;6(07): 2325967118781828. Doi: 10.1177/2325967118781828
 - 10 Kusma M, Seil R, Kohn D. Isolated avulsion of the biceps femoris insertion-injury patterns and treatment options: a case report and literature review. *Arch Orthop Trauma Surg* 2007;127(09): 777–780. Doi: 10.1007/s00402-006-0216-4