



Endoscopic Ultrasonography-Specific Stents

Rahul Haresh Shah¹ Priyanka Udawat¹ Vinay Dhir¹

¹Department of Gastroenterology, Institute of Digestive and Liver Care, S L Raheja Hospital, Mumbai, Maharashtra, India

Address for correspondence Rahul Haresh Shah, MRCP (Medicine, Gastroenterology), Department of Gastroenterology, Institute of Digestive and Liver Care, S L Raheja Hospital, Mumbai 400016, Maharashtra, India (e-mail: rahulshah@hotmail.com).

J Digest Endosc 2021;12:229–234.

Abstract

The evolution of the endoscopic ultrasonography (EUS) technique has necessitated the development of EUS-specific accessories and stents. In the earlier period, EUS-guided interventions mostly relied on borrowed accessories and stents from therapeutic endoscopy in particular ERCP. Traditional stents do not serve the purpose of EUS-guided transluminal stenting in all cases due to the length of the stent, no anchoring mechanism, and chance of migration. From 2011 onward, several EUS-specific stents became available, bringing a paradigm shift in interventional EUS. This article reviews current EUS-specific stents, indications, strengths, and weaknesses.

Keywords

- ▶ BFMS
- ▶ endoscopic ultrasound
- ▶ LAMS

Introduction

Interventional endoscopic ultrasonography (EUS) has evolved rapidly over the past decade. Many techniques have become standardized and have been integrated into routine patient management in advanced endoscopy units worldwide. Parallel with this development, there has been an accumulation of high-quality evidence regarding the safety and efficacy of multiple interventional EUS procedures. There is level 1 evidence for EUS-biliary drainage (EUS-BD) in the distal biliary malignant block, pancreatic fluid collection drainage, and celiac plexus neurolysis.^{1,2} EUS-guided drainage biliary drainage is being used in patients with failed ERCP, ERCP in altered anatomy, or gastric outlet obstruction.³ The evolution of the EUS technique has necessitated the development of EUS-specific accessories and stents.⁴ In the earlier period, EUS-guided interventions mostly relied on borrowed accessories and stents from therapeutic endoscopy in particular ERCP.⁵ Traditional stents do not serve the purpose of EUS-guided transluminal stenting in all cases due to the length of the stent, no anchoring mechanism, and chance of migration.

As the experience with interventional EUS increased, the specific requirements from stents became clear. The most important distinction was the need for a covered stent, full

or partial, as EUS-guided stents need to traverse across organs such as the stomach, liver, jejunum, duodenum, bile duct, and gallbladder. In the absence of a covered stent, the probability of leaks between organs is high. The extent of the covered portion was different in different regions. For example, hepatico-gastrostomy needs long tubular stents with a distal uncovered portion in the intrahepatic ducts to prevent side branch obstruction, and the fully covered portion between the liver capsule and stomach to prevent bile leak.^{4,5}

The second issue was the length of the stent. Stents used in ERCP are usually 4 cm or longer. Such a long stent is not needed for many indications with EUS such as cholecystocholedochostomy, gastro-enterostomy, or pancreatic fluid collection drainage. A short stent length such as 1 to 2 cm is usually sufficient to bring the two walls together.⁶ A longer stent has a propensity to migration, as well as separation of the two anastomosed walls. As described earlier, hepatico-gastrostomy needed long tubular stents to traverse from the left lobe of the liver to the proximal stomach.

The third issue was migration. As these stents do not traverse through any stricture or tumor, they can migrate easily. Thus, anti-migration mechanisms in the form of wide flanges or other anchoring mechanisms were needed.

DOI <https://doi.org/10.1055/s-0041-1741514>.
ISSN 0976-5042.

© 2022. Society of Gastrointestinal Endoscopy of India. All rights reserved.

This is an open access article published by Thieme under the terms of the Creative Commons Attribution-NonDerivative-NonCommercial-License, permitting copying and reproduction so long as the original work is given appropriate credit. Contents may not be used for commercial purposes, or adapted, remixed, transformed or built upon. (<https://creativecommons.org/licenses/by-nc-nd/4.0/>)

Thieme Medical and Scientific Publishers Pvt. Ltd., A-12, 2nd Floor, Sector 2, Noida-201301 UP, India

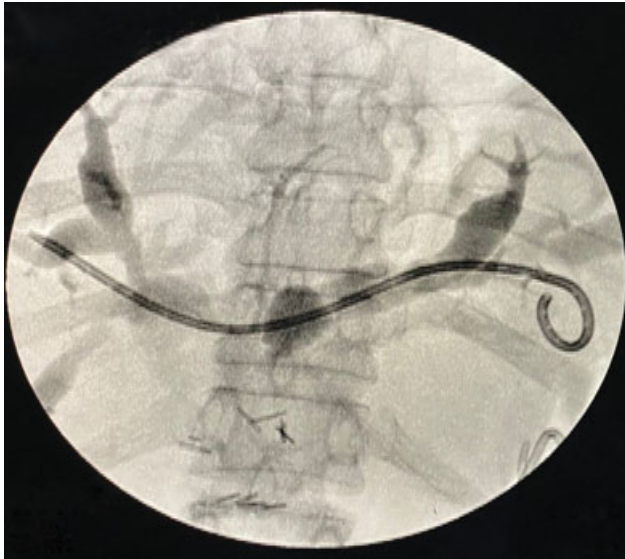


Fig. 1 Cholangiogram showing an IT stent in the left hepatic duct.

Thus around 2011 onward, several EUS-specific stents became available, bringing a paradigm shift in interventional EUS.

Types of Stents

EUS-Specific Plastic Stents

Recently, a EUS-specific plastic single pigtail stent (IT stent) was developed by Itoi et al for use in hepaticogastrostomy (HGS) and PD interventions.⁶ The 7 French stent has a tapered tip, four internal flanges (two in the distal end and two at the proximal end), and a single external pigtail (total length of 20 cm and an effective length of 15 cm [**Fig. 1**]). The new stent has several advantages namely the tapered and straight distal tip can be easily advanced via the needle tract and stricture sites, and the four flange and pigtail anchor the stent and prevent outward and inward migration.

EUS-Specific Metal Stents

There are three types of stent designs available, namely, biflanged fully covered metal stent (BFMS), lumen apposing stents (LAMS), and hybrid tubular stents. We will discuss these stent designs.

Table 1 Comparative data of LAMS stents

Stent type	Flange diameter (mm)	Length (mm)	Catheter diameter (French)	Lumen apposing force (Newton)	Studied applications
AXIOS	6–20	8,10	10.8	2.29	GJ, CDS,PFC, GBD
SPAXUS	8–16	20	10	1.76	PFC, GBD, GJ
NAGI	10–16	10,20,30	9,10	1.08	PFC, GBD
AIXSTENT	10–15	30	10	NA	PFC
PLUMBER	12–16	10,20,30	10.2	NA	PFC

Abbreviations: GJ, gastrojejunostomy; CDS, cholecystoduodenostomy; PFC, pancreatic fluid collection; GBD, gall bladder drainage.




Fig. 2 Axios stent.

Lumen Apposing Stents

The use of LAMS specifically designed for EUS-guided transluminal drainage was first reported by Binmoeller and Shah in 2011.⁷ They are designed with an inbuilt needle and cautery enhanced features leading to one-step deployment. The stents are fully silicone covered with a self-expanding memory metal such as nickel-titanium alloy, which provides flexibility and adequate radial force to anchor the opposing lumens and prevents migration due to wide flanges on either side. Memory metal helps the stent to expand to desired dimensions and flanges prevent migration by anchoring (**Table 1**).

The Hot AXIOS™ delivery system (Boston Scientific Natick, USA) (**Fig. 2**) has an integrated cautery system that consists of two radially distributed diathermic wires converging around the guidewire lumen, which provides a clean, sharp cut with a minimal coagulation effect. This single-step procedure makes it faster, safer with the need for fewer accessories, thus reducing potential complications. The hot AXIOS does not necessarily need a 19-gauge needle or wire.

The Spaxus stent (Taewoong Medical Co., Ltd., Ilsan, Korea) (**Figs. 3 and 4**) on the other hand has flanges that fold back once fully deployed, which aims to enhance the




Fig. 3 Spaxus stent.

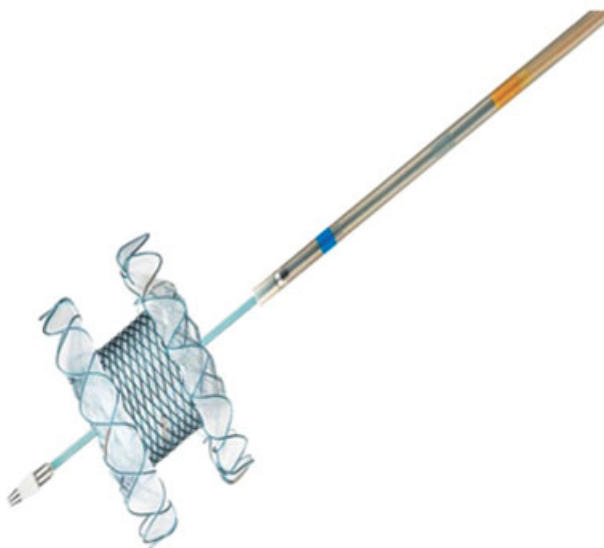

Fig. 4 Hot Spaxus stent.

lumen apposition and prevent migration. Blue marker at the distal flange aids endoscopic accurate placement. It comes in 2 and 3 cm lengths.



Fig. 5 Nagi stent.

Biflanged Metal Stents

NAGI stent (Taewoong Medical Co., Ltd., Ilsan, Korea) (→**Fig. 5**) has radio-opaque markers located at both ends and in the middle that allows fluoroscopy-guided placement. It comes in 2 and 3 cm lengths and a 26 mm diameter flange. It differs from the LAMS described earlier in having less apposition force, and is thus not considered suitable for procedures requiring stringer apposition between the anastomosed walls (→**Table 2**).

Hybrid Stents

Hybrid stents have been designed specifically for patients with failed ERCP in particularly useful for drainage in malignant biliary obstruction (MBO). These hybrid stents were developed with a fully covered distal portion and prevent bile leak and are proximally uncovered to prevent side branch blockage. They have inbuilt anti-migratory flaps.

GIOBOR (Taewoong Medical Co., Ltd.) flexible design and soft material take the stomach curves. It is available in 6, 8, 10 cm in length and 8, 10 mm diameters. It has 70% covered part and 30% uncovered in the intrahepatic portion. It has three markers at both ends and two at the end of the covered portion.

In Hanarostent BPD (MI Tech, Seoul, Korea), the uncovered portion is 30 mm in length, while the distal trans-gastric

Table 2 Comparative data of Hybrid stents

Stent type	Stent diameter (mm)	Stent covered length (mm)	Stent length (cm)	Catheter diameter (French)	Studied applications	Stent type
GIOBOR	8,10	40,50	8,10	8.5	HGS	Giobor
Hanaro	10	30	8,10	8.5	HGS	Hanaro
Deus delivery premounted stent	6	35–85	5,10	7	HGS, CDS	Deus delivery premounted stent

Abbreviations: CDS, cholecochoduodenostomy; HGS, hepaticogastrostomy.



Fig. 6 GIOBOR stent.

silicone-covered portion depends on the length of the stent. The stent comes in 6, 8, 10 cm with a diameter of between 10 and 20 mm with an anti-migration rivet-type flared flap of 20 mm at the gastric extremity. The radio-opaque markers are similar to the GIOBOR stent (► **Fig. 6**). The stent can be fully resheathed during delivery up to 70% deployment.

Indications and Evidence

Since the first report by Giovannini et al in 2001,⁸ EUS-BD has become the procedure of choice replacing PTBD for failed ERCPs. This has been shown to reduce morbidity, stent blockage, re-intervention rates, and length of hospital stay as compared with PTBD.^{9–12} EUS-guided biliary drainage in such cases can be done by choledochoduodenostomy, antegrade stenting, hepatico-gastrostomy, hepatic-duodenostomy.¹³ Emerging evidence suggests that EUS-BD is equivalent to ERCP for distal malignant obstruction. LAMS has been widely preferred over PS in malignant biliary blocks. There is level 1 evidence for use of EUS-BD as an alternative to ERCP in expert centers.¹⁴ Evidence from a recent systemic review suggests that EUS-BD has comparable technical and clinical success to ERCP.¹⁵ The type of stent used differs depending upon the level of obstruction. In general, short stents including LAMS are used for distal obstruction, while tubular stents are used for proximal obstruction.

EUS-guided drainage is the standard of care for symptomatic pancreatic pseudocysts and walled-off necrosis. While traditional surgery and percutaneous drainage have comparable outcomes albeit higher rates of fistula formation and sepsis, EUS-guided drainage has better morbidity, mortality, reduces the length of stay, and is minimally invasive.¹⁶ One randomized controlled trial (RCT) and one meta-analysis have shown equal efficacy of PS versus LAMS/BFMS, while another four meta-analyses have shown better efficacy with LAMS.^{17,18}

EUS-guided transmural gall bladder drainage (GBD) is emerging as an alternative to percutaneous GBD for the management of acute cholecystitis in surgical high-risk patients. Moreover, “salvage” GBD with LAMS seems to be

Table 3 Choice of stents for PFC drainage

Procedure	Type of stent		
	Plastic	BFMS	LAMS
Pseudocyst	✓	✗	✗
WON	✓	✓	✓

Abbreviations: BFMS, biflanged fully covered metal stent; LAMS, lumen apposing stents; PFC, pancreatic fluid collection; WON, walled off necrosis.

an attractive option in malignant obstructing conditions. This has the advantage of lumen apposition with low chances of bile leak, pneumothorax, and hematoma formation compared with percutaneous drainage even in the presence of ascites. Technical difficulties can appear due to the gall bladder being mobile hence only an LAMS stent would be suitable for deployment.^{19,20}

EUS guided gastrojejunostomy with LAMS has been advocated recently for gastric outlet obstruction with comparable if not better outcomes. Duodenal stents come with the inherent problem of stent migration, tumor ingrowth and overgrowth. Clinical outcomes with enteral stenting are often poor while EUS-GJ has shown better clinical outcomes (GOOSS [gastric outlet obstruction scoring system] score), longer stent patency in recent clinical studies.^{21,22}

EUS has also been advocated in pancreatic ductal pathology as an alternative to surgery but these procedures are technically demanding due to their small diameter, shorter length, and stiffer pancreatic parenchyma. Evidence is limited and interventions are done at select tertiary centers.²³

Choosing the Right Stent

No comparative studies of available stents have been published. In the absence of published evidence, current recommendations are based upon evidence of efficacy for a particular indication, stent design, stent properties, and cost considerations²⁴ (► **Tables 3–5**).

Pancreatic Fluid Collections

Current evidence suggests that plastic stents (PS) provide adequate drainage for both pseudocysts and walled off necrosis (WON). Comparative studies of plastic versus metal stents for WON have conflicting conclusions, but the weight of evidence tends to favor metal stents for WON. Lumen apposition is not so necessary for WON, as the wall of WON is a pseudo-wall, and is unlikely to retract away. Hence, both BFMS and LAMS have shown good efficacy for WON. A PS placed through a LAMS or BFMS prevents early blockage by necrotic debris, and probably prevents the stent from touching the opposite WON wall, thereby probably reducing post-procedure bleeding.

EUS-Guided Biliary Drainage

The choice of the stent is influenced by the level of obstruction and the type of procedure being performed.

Trans-papillary procedures (rendezvous and antegrade procedures) can be done when papilla is approachable. Because these procedures are trans-papillary, stents routinely used for ERCP (PS, uncovered metal stents, covered metal

Table 4 Choice of stents for EUS-BD

Procedure	Type of stent				
	Plastic	Uncovered metal	Covered metal	LAMS	Tubular
Rendezvous	✓	✓	✓	✗	✗
Transluminal CDS (CBD < 15 mm)	?	✗	✓	?	✗
Transluminal CDS (CBD > 15 mm)	?	✗	✓	✓	✗
Transluminal HGS	✓	✗	?	✗	✓
Antegrade	✗	✓	✗	✗	✗

Abbreviations: LAMS, lumen apposing stents; CDS, cholechooduodenostomy; CBD, common bile duct; HGS, hepaticogastrostomy.

Table 5 Choice of stents for EUS- GB, GJ

Procedure	Type of stent		
	Plastic	BFMS	LAMS
EUS GJ	✗	✗	✓
GB drainage	✗	✗	✓

Abbreviations: BFMS, biflanged fully covered metal stent; EUS GJ, endoscopic ultrasonography-guided gastrojejunostomy; LAMS, lumen apposing stents.

stents) can be utilized for these procedures. These stents are cheaper compared with EUS-specific stents.

Trans-luminal procedures (Cholecho-duodenostomy, hepatico-gastrostomy) generally need EUS-specific stents although fully covered metal stents used for ERCP have also been utilized. A short fully covered metal stent or a LAMS is suitable. LAMS with a smaller diameter (6 or 8 mm) may be utilized for cholecho-duodenostomy, especially if the common bile duct (CBD) is dilated to 12 mm or more. A long PS developed by Itoi et al is suitable for hepaticogastrostomy (HGS), especially in patients with benign strictures who need repeated procedures. This stent is unfortunately not available in most countries.

Gallbladder Drainage and Gastro-enterostomy

Both gallbladder drainage and gastro-enterostomy need a stent with strong lumen apposing force. A weak apposing force could result in separation of the walls (duodenum and GB, or stomach and jejunum), thus resulting in leak or perforation. Thus, LAMS (Axios or Spaxus) is the only suitable stents currently.

Future Research

While significant progress has taken place in the development of EUS-specific stents in the past decade, further research is needed for further improvements. These stents have large diameters, allowing free movement of solids and liquids from either side. This creates a problem of food material entering the WON cavity or the CBD. A valve-like mechanism is needed for the one-sided passage of fluid or necrotic material. Stents for WON need removal after 3 to 4 weeks. A bio-absorbable stent could be developed that does not need removal. The length of HGS stents and the length of the covered portion need standardization. Access stents need to be refined for patients needing repeated procedures.

Conflict of Interest

None declared.

References

- Dhir V, Isayama H, Itoi T, et al. Endoscopic ultrasonography-guided biliary and pancreatic duct interventions. *Dig Endosc* 2017;29(04):472–485
- Teoh AYB, Dhir V, Kida M, et al. Consensus guidelines on the optimal management in interventional EUS procedures: results from the Asian EUS group RAND/UCLA expert panel. *Gut* 2018;67(07):1209–1228
- Kedia P, Tyberg A, Kumta NA, et al. EUS-directed transgastric ERCP for Roux-en-Y gastric bypass anatomy: a minimally invasive approach. *Gastrointest Endosc* 2015;82(03):560–565
- Weilert F, Binmoeller KF. Specially designed stents for trans-luminal drainage. *Gastrointest Interv* 2015;4:40–45
- Mangiavillano B, Pagano N, Baron TH, et al. Biliary and pancreatic stenting: Devices and insertion techniques in therapeutic endoscopic retrograde cholangiopancreatography and endoscopic ultrasonography. *World J Gastrointest Endosc* 2016;8(03):143–156
- Umeda J, Itoi T, Tsuchiya T, et al. A newly designed plastic stent for EUS-guided hepaticogastrostomy: a prospective preliminary feasibility study (with videos). *Gastrointest Endosc* 2015;82(02):390–396.e2
- Binmoeller KF, Shah J. A novel lumen-apposing stent for trans-luminal drainage of nonadherent extraintestinal fluid collections. *Endoscopy* 2011;43(04):337–342
- Giovannini M, Moutardier V, Pesenti C, Bories E, Lelong B, Delpero JR. Endoscopic ultrasound-guided bilioduodenal anastomosis: a new technique for biliary drainage. *Endoscopy* 2001;33(10):898–900
- Sharaiha RZ, Khan MA, Kamal F, et al. Efficacy and safety of EUS-guided biliary drainage in comparison with percutaneous biliary drainage when ERCP fails: a systematic review and meta-analysis. *Gastrointest Endosc* 2017;85(05):904–914
- Bang JY, Navaneethan U, Hasan M, Hawes R, Varadarajulu S. Stent placement by EUS or ERCP for primary biliary decompression in pancreatic cancer: a randomized trial (with videos). *Gastrointest Endosc* 2018;88(01):9–17
- Dhindsa BS, Mashiana HS, Dhaliwal A, et al. EUS-guided biliary drainage: a systematic review and meta-analysis. *Endosc Ultra-sound* 2020;9(02):101–109
- Tsuchiya T, Teoh AYB, Itoi T, et al. Long-term outcomes of EUS-guided cholechooduodenostomy using a lumen-apposing metal stent for malignant distal biliary obstruction: a prospective multicenter study. *Gastrointest Endosc* 2018;87(04):1138–1146
- Cho DH, Lee SS, Oh D, et al. Long-term outcomes of a newly developed hybrid metal stent for EUS-guided biliary drainage (with videos). *Gastrointest Endosc* 2017;85(05):1067–1075
- Lee TH, Choi JH, Park H, et al. Similar efficacies of endoscopic ultrasound-guided transmural and percutaneous drainage for

- malignant distal biliary obstruction. *Clin Gastroenterol Hepatol* 2016;14(07):1011–1019.e3
- 15 Paik WH, Lee TH, Park DH, et al. EUS-guided biliary drainage versus ERCP for the primary palliation of malignant biliary obstruction: a multicenter randomized clinical trial. *Am J Gastroenterol* 2018;113(07):987–997
 - 16 Hammad T, Khan MA, Alastal Y, et al. Efficacy and safety of lumen-apposing metal stents in management of pancreatic fluid collections: are they better than plastic stents? A systematic review and meta-analysis. *Dig Dis Sci* 2018;63(02):289–301
 - 17 Shah R, Basha J, Rana S, et al. Endoscopic management of pancreatic fluid collections: guidelines of Society of Gastrointestinal Endoscopy of India and Indian EUS Club. *Dig Endosc* 2021;12:3–10
 - 18 Yang J, Chen YI, Friedland S, et al. Lumen-apposing stents versus plastic stents in the management of pancreatic pseudocysts: a large, comparative international, multicenter study. *Endoscopy* 2019;51(11):1035–1043
 - 19 Walter D, Teoh AY, Itoi T, et al. EUS-guided gall bladder drainage with a lumen-apposing metal stent: a prospective long-term evaluation. *Gut* 2016;65(01):6–8[PubMed] [Google Scholar]
 - 20 Teoh AYB, Serna C, Penas I, et al. Endoscopic ultrasound-guided gallbladder drainage reduces adverse events compared with percutaneous cholecystostomy in patients who are unfit for cholecystectomy. *Endoscopy* 2017;49(02):130–138
 - 21 Itoi T, Ishii K, Ikeuchi N, et al. Prospective evaluation of endoscopic ultrasonography-guided double-balloon-occluded gastrojejunostomy bypass (EPASS) for malignant gastric outlet obstruction. *Gut* 2016;65(02):193–195
 - 22 Bukhari M, Kowalski T, Nieto J, et al. An international, multicenter, comparative trial of EUS-guided gastrogastrostomy-assisted ERCP versus enteroscopy-assisted ERCP in patients with Roux-en-Y gastric bypass anatomy. *Gastrointest Endosc* 2018;88(03):486–494
 - 23 Giovannini M. Endoscopic ultrasound-guided pancreatic duct drainage: Ready for the prime time? *Endosc Ultrasound* 2017;6(05):281–284
 - 24 Teoh AY, Ng EK, Chan SM, et al. Ex vivo comparison of the lumen-apposing properties of EUS-specific stents (with video). *Gastrointest Endosc* 2016;84(01):62–68