

# Transanal Endoscopic Platforms: TAMIS versus Rigid Platforms: Pros and Cons

Liam A. Devane, MD<sup>1</sup> Meghan C. Daly, MD<sup>2</sup> Matthew R. Albert, MD<sup>2</sup>

<sup>1</sup>Department of Colorectal Surgery, Beaumont Hospital, Dublin, Ireland  
<sup>2</sup>AdventHealth, Digestive Health and Surgical Institute, Department of Colorectal Surgery, Orlando, FL

Address for correspondence Matthew R. Albert, MD, AdventHealth, Digestive Health and Surgical Institute, Department of Colorectal Surgery, 2501 North Orange Ave, Orlando, FL 32804 (e-mail: Matthew.Albert.MD@AdventHealth.com).

Clin Colon Rectal Surg 2022;35:93–98.

## Abstract

Transanal endoscopic surgery encompasses the minimally invasive surgical techniques used to operate in the rectum under magnification while maintaining pneumorectum via a resectoscope or port. The view, magnification, and surgical precision afforded by these advanced transanal techniques have resulted in excellent specimen quality and low recurrence rates, especially compared with traditional transanal surgery. For rigid platforms, the surgeon operates through a rigid 4-cm diameter steel proctoscope of varying lengths that is clamped to the operating table with an articulating arm. Transanal minimally invasive surgery (TAMIS) is a newer flexible platform using a disposable port which “hooks” into the anorectal ring to remain in place. The cost-effectiveness and versatility of the TAMIS platform have resulted in its popularity and use in more advanced applications such as transanal total mesorectal excision. Ultimately, the choice of operating platform should be based on surgeon preference, patient characteristics, availability, and cost. The pros and cons of each platform will be discussed in this article.

## Keywords

- ▶ transanal endoscopic surgery
- ▶ TAMIS
- ▶ TEM
- ▶ TEO

The earliest technique developed by prof. Gerard Buess in the 1980s was termed as transanal endoscopic microsurgery (TEM)<sup>1</sup> and the equipment is manufactured by Richard Wolf GmbH (Knittlingen, Germany). A similar competing product was subsequently manufactured by Karl Storz (Tuttlingen, Germany) and referred to as transanal endoscopic operation (TEO). Both of these are described as rigid platforms as the equipment is clamped to the operating table via an articulating arm and the telescope is fixed to a rigid 4-cm diameter proctoscope of varying lengths.

Relatively recently, an alternative technique, transanal minimally invasive surgery (TAMIS),<sup>2</sup> was developed, initially using a port adopted from single incision laparoscopic surgery (SILS). This port and other subsequent TAMIS ports are made of flexible material not fixed to the operating table but held in place by “hooking” onto the anorectal ring. Rather than requiring proprietary equipment and instruments used in TEM, TAMIS was conceived to be more flexible and cost-effective by using a standard laparoscopic camera, insufflator, and instruments.

The field of view, magnification, and surgical precision afforded by these advanced transanal techniques have resulted in excellent specimen quality and low recurrence rates, especially compared with traditional transanal surgery.<sup>3,4</sup> This article will compare the technical aspects of these platforms including the advantages and disadvantages of each technique.

## Cost

One of the limitations in widespread adoption of TEM has been the initial capital cost.<sup>2</sup> All of the equipment including the resectoscope, insufflator, stereotactic scope, and angled instruments are proprietary. While this specially designed equipment has some advantages that will be discussed later, it costs approximately US\$80,000.<sup>5</sup> The equipment is reusable, but some disposables are still required such as tubing and sealing caps. Although the capital expense is high, it is cost-effective versus the comparable open procedures.<sup>6</sup> The

Issue Theme Transanal Surgery: From Local Excision to More Complex Procedures; Guest Editor: Gustavo L. Rossi, MD, MASCRS

© 2022. Thieme. All rights reserved. Thieme Medical Publishers, Inc., 333 Seventh Avenue, 18th Floor, New York, NY 10001, USA

DOI <https://doi.org/10.1055/s-0041-1742108>.  
ISSN 1531-0043.

TEO platform costs approximately US\$30,000.<sup>5</sup> The lower cost is achieved by providing a two-dimensional (2D) digital scope and by using standard generic laparoscopic insufflator and instruments, although proprietary angled instruments are available.

In contrast, TAMIS uses a disposable port and cannulas costing US\$500 to US\$800<sup>5</sup> which is comparable to the cost of the disposable tubing set required for TEM.<sup>7</sup> All other required equipment can be attained from a regular laparoscopic surgical set. The most commonly used port is the disposable GelPOINT Path Transanal Access Platform<sup>8</sup> (Applied Medical, Rancho Santa Margarita, CA). Other ports include the disposable SILS Port (Covidien, New Haven, CT) and the reusable KeyPort (Richard Wolf GmbH).

### Operating Resectoscope/Port

TEM (►Fig. 1) and TEO (►Fig. 2) resectoscopes are steel and fixed to the operating table by a mounting arm. The resectoscope is 4 cm in diameter and available in different lengths

(7.5–20 cm) to target proximal and distal rectal lesions. The distal tip is beveled downward to facilitate operating on lesions in the dependent position, although a straight version is also available. Therefore, patients must be positioned in lithotomy for posterior lesions, prone for anterior lesions, or in lateral decubitus for lateral lesions. Depending on the position, operative setup time can be prolonged and less clear for operating room staff. Tubing for insufflation, pressure monitoring, smoke evacuation, and lens cleaning also require attachment. This complex setup typically takes approximately 20 minutes.<sup>9</sup> The mounting arm for the resectoscope and its attachments provide a stable platform, however, may frequently require repositioning to adjust the field of view.

The advantage of the 4-cm rigid opening of the port is that it can be used to stent the anal canal for distal lesions, to pin the rectal valves for lesions behind them, and to stent the bowel wall for more proximal lesions into the distal sigmoid. Although rigid platforms are less commonly used for transanal total mesorectal excision (TaTME), some proponents



**Fig. 1** Transanal endoscopic microsurgery, Richard Wolf GmbH, Germany.



**Fig. 2** Transanal endoscopic operations (TEO), Karl Storz SE & Co. KG, Germany.

prefer this ability to stent the tissue independently of the pneumorectum. However, the long rigid resectoscope reduces the working angles of the instruments (► **Fig. 3**). This is partially overcome by proprietary angulated instruments.

TAMIS ports are flexible and not fixed to the operating table but held in place by “hooking” onto the anorectal ring (► **Fig. 4**). The uncomplicated setup can be complete in 1 to 3 minutes.<sup>2,10</sup> The flexible port can also be angled or slightly retracted if required. The port is flared at either end, but the segment in the anal canal has a smaller diameter (3.4 cm) causing less distortion of the sphincter. Also, the length is much shorter (5.5 cm) which increases the working angle of the instruments (► **Fig. 3**). The ports are not beveled, and the increased working angle allows a 360-degree working space meaning patients can be consistently positioned in lithotomy regardless of location of the lesion. The lithotomy position for anterior rectal lesions enables greater ease of laparoscopic access if the peritoneum is breached. This contrasts with rigid platforms where the patient is positioned prone for anterior lesions making laparoscopy problematic to perform if required.

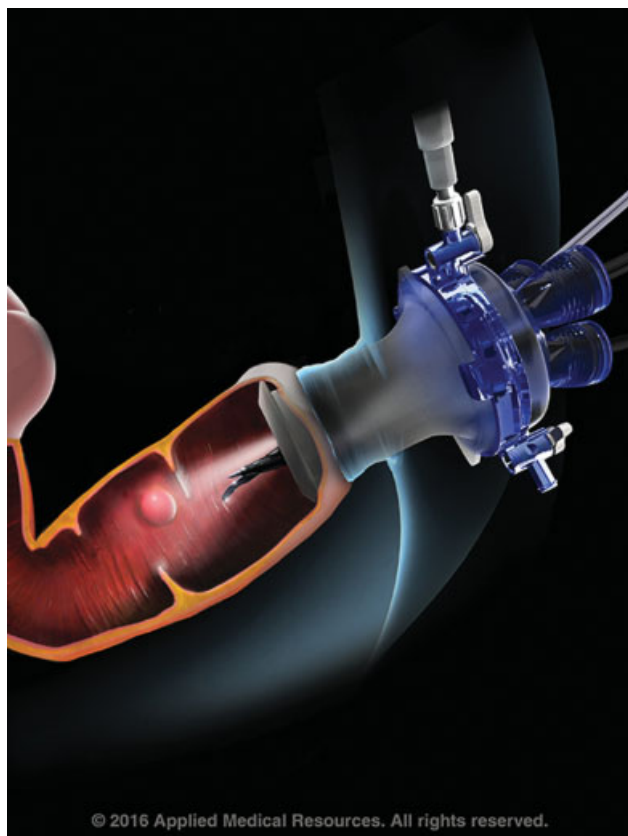
## Telescope

The TEM system has a binocular optical stereoscope which allows greater depth perception and a magnified

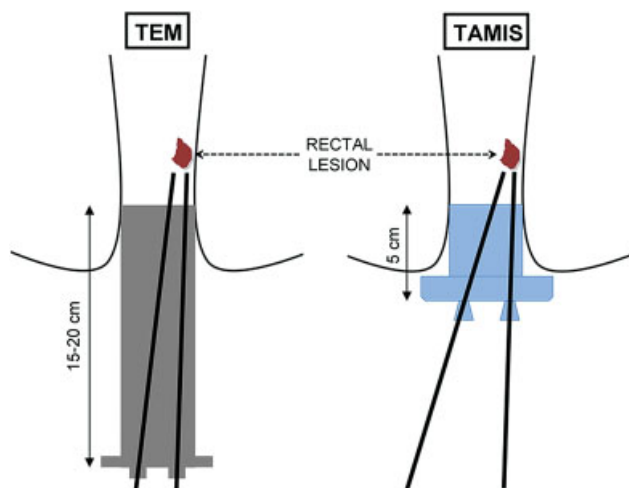
view. There is also a separate connector for a 2D digital display if preferred, or for training purposes. The TEO system has a 2D digital videoscope. TEO allows surgeons to use standard laparoscopic instruments, making the system more favorable for experienced laparoscopic surgeons. In both TEM and TEO, the scope is fixed in position within the resectoscope providing a stable 70-degree field of view.

Proponents of rigid platforms regard the fixed, stable view provided to be advantageous as no assistant is required and many smaller lesions can be excised without having to change the view or angle of the camera. However, others view this as a limitation to the flexibility of rigid platforms as when excising larger lesions, or operating in multiple quadrants such as in TaTME, frequent adjustments of the resectoscope and its supporting arm are required to alter the view from the scope. This platform is cumbersome and can lengthen operative time.

In contrast, a surgeon performing TAMIS requires an assistant to operate the videoscope. The surgeon is reliant on the assistant's technical skill to display the operative field optimally while also avoiding clashes with the operator. However, with an experienced assistant, the flexible platform can provide a dynamic and optimal operative view in which dissection can progress more efficiently. If a 5-mm scope is used, the instrument and camera ports can be interchanged for difficult cases.



**Fig. 3** Schematic representation of dimensions and instrument working angles of transanal endoscopic microsurgery (TEM) endoscope and transanal minimally invasive surgery (TAMIS). (Reprinted with permission from Burke and Albert.<sup>9</sup>)



**Fig. 4** GelPOINT Path TAMIS port, Applied Medical, Rancho Santa Margarita, CA.

## Pneumorectum

When using a standard laparoscopic insufflator, the rectal wall is prone to billowing especially during suctioning. This is due to the small operating volume in the rectum in conjunction with programmed pauses for pressure sensing on most insufflators.<sup>11</sup> The billowing of the rectum makes dissection

difficult and imprecise. Billowing is less of a problem during laparoscopic abdominal operations due to the larger volume of the abdominal cavity and compliance of the abdominal wall which negate the pauses for pressure sensing except during prolonged suctioning.

The TEM apparatus overcomes the problem of billowing due to its proprietary separate connections for gas delivery, smoke evacuation, and pressure sensing. These are all linked and controlled, so the rate of smoke evacuation never exceeds the rate of gas delivery. The result is a very stable pneumorectum while operating without insufflating more proximal bowel, thus avoiding unnecessary bowel distention. In contrast, the TEO system does not include proprietary insufflator and is prone to billowing when using laparoscopic abdominal equipment.

As with the TEO platform, TAMIS relies on generic laparoscopic insufflators. Applied Medical have designed the insufflation stabilization bag (ISB) used with the GelPOINT path port (Applied Medical) to overcome the problem of billowing.<sup>11</sup> The ISB creates a large, compliant dead space between the insufflator and the GelPOINT path. This increases the volume and also the compliance of the system to simulate insufflation of a much larger, abdominal cavity where billowing is minimal.

An alternative insufflator to minimize billowing is the AirSeal system (ConMed, 525 French Road, Utica, NY) which was not developed specifically for TAMIS but has been found to have significant advantages.<sup>12</sup> The AirSeal system continuously circulates turbulent CO<sub>2</sub> into the operating space and back through a filter which extracts smoke from the operating field. The system also constantly measures pressure providing a stable pneumorectum even when suctioning.

## Learning Curve

In general, for minimally invasive trained surgeons, TEM is reportedly more difficult to master than TAMIS as the equipment is proprietary and less familiar. Regardless of platform, the importance of structured training is clear as identified by Kipfmüller et al with the inception of TEM.<sup>13</sup>

In a study of 693 lesions resected by four surgeons using TEM, effects of a long learning curve could be demonstrated statistically even per single additional procedure.<sup>14</sup> This continuum of improvement stresses the importance of maintaining a steady caseload. A single-surgeon series of 73 TEM cases describes a difficult learning curve; however, no significant improvement in operative time was identified in later cases due to the increase in difficulty of cases as experience was gained.<sup>15</sup> Another study of two surgeons performing 95 TEM procedures concluded that after 16 cases, the learning curve started to plateau,<sup>16</sup> whereas a separate study of 23 cases showed a leveling of the rate of excision after the first four cases.<sup>17</sup> For TEO, a series of 46 cases was analyzed using cumulative sum (CUSUM) analysis and the operation time and hospital stay significantly decreased after 17 cases.<sup>18</sup>

In regard to TAMIS, a comparative study of two surgeons in the Netherlands using CUSUM analysis determined 18 to

31 cases were required to become proficient but this could be reduced to 6 to 10 cases with proctoring.<sup>19</sup> Another study of 254 patients operated on by five surgeons in a high-volume center compared surgeons without prior TAMIS experience with those who received formal TAMIS training. This study estimated that 20 to 24 cases were required to achieve proficiency, although this was shortened to 14 cases for surgeons with formal training in TAMIS.<sup>20</sup> The same group also looked at the learning curve for TaTME in surgeons already proficient in laparoscopic TME and TAMIS. Using the same flexible TAMIS platform and CUSUM analysis, they concluded that this complex technique requires approximately 50 cases to achieve acceptable high-quality surgery.<sup>21</sup>

It is interesting that while TaTME was first described using a rigid platform,<sup>22</sup> analysis of the TaTME registry reveals that 85% of recorded cases have been performed with a flexible TAMIS platform, highlighting its increasing popularity.<sup>23</sup>

## Outcomes

Largest comparison of TEM with TAMIS comprised 428 patients (247 TEM and 181 TAMIS) from high-volume centers.<sup>24</sup> While length of stay and operative time were longer with TEM, the specimen quality, complication rate, and recurrence rate were similar between procedures. Melin et al<sup>25</sup> compared 40 TEM and 29 TAMIS cases and reported no statistical differences in resection margin involvement or postoperative complications, although lesions excised by TAMIS were larger. Similarly, Mege et al<sup>26</sup> compared 33 TAMIS and 41 TEM cases and found no differences in resection quality, complications, or recurrence rates. Another institutional series compared 53 TEM and 68 TAMIS cases demonstrated similar outcomes though shorter operative times with TAMIS as all resections were performed in lithotomy position.<sup>27</sup>

Preservation of anorectal function with an organ-sparing approach was the driving force behind the development of transanal endoscopic surgery. For rigid platforms, there was initial concern that the 4-cm diameter rigid proctoscope could affect continence. A prospective study of 201 patients undergoing TEM who were followed up for 4 months showed a reduction in anal sphincter resting and contraction pressures but no change in Wexner score or postoperative incontinence.<sup>28</sup> Ultrasound evaluation of 106 TEM/TEO patients showed 29.2% had a demonstrable sphincter lesion at 1 month but only 6.6% at 4 months with no evidence of incontinence.<sup>29</sup> The malleable 3.4-cm port for TAMIS is thought to be less detrimental. A prospective series of 10 patients measured with anorectal manometry and Cleveland Clinic Incontinence Score pre- and post-TAMIS showed that only mean minimum rectal sensory volume was lower at 3 weeks after surgery.<sup>30</sup> The Cleveland Clinic Incontinence Score was normal in all patients except one which resolved by 6 weeks after surgery. A recent systematic review of functional outcomes and quality of life after transanal surgery concluded that rigid or flexible platforms do not appear to affect continence by themselves except in minor cases.<sup>31</sup>

## Summary

TAMIS and rigid platforms, in experienced hands, are capable of high-quality precise surgery in the rectum and are superior to traditional transanal surgery. They provide precise dissection techniques while limiting patient morbidity. Both platforms mandate appropriate training and neither of these advanced transanal platforms is intended for novice surgeons.

Patient characteristics, surgeon preference, availability, and cost are the driving forces when choosing the operative technique. TAMIS utilization has rapidly spread worldwide because of its versatility, cost-effectiveness, and the increasing number of training courses available for surgeons. Its global adoption has been reflected by the increasing rise in publications and citations since its initial description in 2010.

### Conflict of Interest

None declared.

## References

- Buess G, Hutterer F, Theiss J, Böbel M, Isselhard W, Pichlmaier H. [A system for a transanal endoscopic rectum operation]. *Chirurg* 1984;55(10):677–680
- Atallah S, Albert M, Larach S. Transanal minimally invasive surgery: a giant leap forward. *Surg Endosc* 2010;24(09):2200–2205
- Clancy C, Burke JP, Albert MR, O'Connell PR, Winter DC. Transanal endoscopic microsurgery versus standard transanal excision for the removal of rectal neoplasms: a systematic review and meta-analysis. *Dis Colon Rectum* 2015;58(02):254–261
- Atallah S, Keller D. Why the conventional parks transanal excision for early stage rectal cancer should be abandoned. *Dis Colon Rectum* 2015;58(12):1211–1214
- McLemore EC, Weston LA, Coker AM, et al. Transanal minimally invasive surgery for benign and malignant rectal neoplasia. *Am J Surg* 2014;208(03):372–381
- Maslekar S, Pillinger SH, Sharma A, Taylor A, Monson JR. Cost analysis of transanal endoscopic microsurgery for rectal tumours. *Colorectal Dis* 2007;9(03):229–234
- Barendse RM, Doornebosch PG, Bemelman WA, Fockens P, Dekker E, de Graaf EJR. Transanal employment of single access ports is feasible for rectal surgery. *Ann Surg* 2012;256(06):1030–1033
- Adamina M, Buchs NC, Penna M, Hompes RSt.Gallen Colorectal Consensus Expert Group. St.Gallen consensus on safe implementation of transanal total mesorectal excision. *Surg Endosc* 2018;32(03):1091–1103
- Burke JP, Albert M. Transanal minimally invasive surgery (TAMIS): pros and cons of this evolving procedure. *Semin Colon Rectal Surg* 2015;26(01):36–40. Doi: 10.1053/j.scrcs.2014.10.009
- Albert MR, Atallah SB, deBeche-Adams TC, Izfar S, Larach SW. Transanal minimally invasive surgery (TAMIS) for local excision of benign neoplasms and early-stage rectal cancer: efficacy and outcomes in the first 50 patients. *Dis Colon Rectum* 2013;56(03):301–307
- Waheed A, Miles A, Kelly J, Monson JRT, Motl JS, Albert M. Insufflation stabilization bag (ISB): a cost-effective approach for stable pneumorectum using a modified CO<sub>2</sub> insufflation reservoir for TAMIS and taTME. *Tech Coloproctol* 2017;21(11):897–900
- Bislinghi G, Wolthuis AM, de Buck van Overstraeten A, D'Hoore A. AirSeal system insufflator to maintain a stable pneumorectum during TAMIS. *Tech Coloproctol* 2015;19(01):43–45

- 13 Kipfmüller K, Buess G, Naruhn M, Junginger T. Training program for transanal endoscopic microsurgery. *Surg Endosc* 1988;2(01):24–27
- 14 Barendse RM, Dijkgraaf MG, Rolf UR, et al. Colorectal surgeons' learning curve of transanal endoscopic microsurgery. *Surg Endosc* 2013;27(10):3591–3602
- 15 Saclarides TJ. Transanal endoscopic microsurgery: a single surgeon's experience. *Arch Surg* 1998;133(06):595–598, discussion 598–599
- 16 Helewa RM, Rajae AN, Raiche I, et al. The implementation of a transanal endoscopic microsurgery programme: initial experience with surgical performance. *Colorectal Dis* 2016;18(11):1057–1062
- 17 Maya A, Vorenberg A, Oviedo M, da Silva G, Wexner SD, Sands D. Learning curve for transanal endoscopic microsurgery: a single-center experience. *Surg Endosc* 2014;28(05):1407–1412
- 18 Hur H, Bae SU, Han YD, et al. Transanal endoscopic operation for rectal tumor: short-term outcomes and learning curve analysis. *Surg Laparosc Endosc Percutan Tech* 2016;26(03):236–243
- 19 Clermonts S, van Loon YT, Stijns J, Pottel H, Wasowicz DK, Zimmerman DDE. The effect of proctoring on the learning curve of transanal minimally invasive surgery for local excision of rectal neoplasms. *Tech Coloproctol* 2018;22(12):965–975
- 20 Lee L, Kelly J, Nassif GJ, et al. Establishing the learning curve of transanal minimally invasive surgery for local excision of rectal neoplasms. *Surg Endosc* 2018;32(03):1368–1376
- 21 Lee L, Kelly J, Nassif GJ, deBeche-Adams TC, Albert MR, Monson JRT. Defining the learning curve for transanal total mesorectal excision for rectal adenocarcinoma. *Surg Endosc* 2020;34(04):1534–1542
- 22 Sylla P, Rattner DW, Delgado S, Lacy AM. NOTES transanal rectal cancer resection using transanal endoscopic microsurgery and laparoscopic assistance. *Surg Endosc* 2010;24(05):1205–1210
- 23 Penna M, Hompes R, Arnold S, et al; TaTME Registry Collaborative. Transanal total mesorectal excision: international registry results of the first 720 cases. *Ann Surg* 2017;266(01):111–117
- 24 Lee L, Edwards K, Hunter IA, et al. Quality of local excision for rectal neoplasms using transanal endoscopic microsurgery versus transanal minimally invasive surgery: a multi-institutional matched analysis. *Dis Colon Rectum* 2017;60(09):928–935
- 25 Melin AA, Kalaskar S, Taylor L, Thompson JS, Ternent C, Langenfeld SJ. Transanal endoscopic microsurgery and transanal minimally invasive surgery: is one technique superior? *Am J Surg* 2016;212(06):1063–1067
- 26 Mege D, Bridoux V, Maggiori L, Tuech JJ, Panis Y. What is the best tool for transanal endoscopic microsurgery (TEM)? A case-matched study in 74 patients comparing a standard platform and a disposable material. *Int J Colorectal Dis* 2017;32(07):1041–1045
- 27 Van den Eynde F, Jaekers J, Fieuw S, D'Hoore AM, Wolthuis AM. TAMIS is a valuable alternative to TEM for resection of intraluminal rectal tumors. *Tech Coloproctol* 2019;23(02):161–166
- 28 Mora López L, Serra Aracil X, Hermoso Bosch J, Rebasa P, Navarro Soto S. Study of anorectal function after transanal endoscopic surgery. *Int J Surg* 2015;13:142–147
- 29 Mora López L, Serra-Aracil X, Navarro Soto S. Sphincter lesions observed on ultrasound after transanal endoscopic surgery. *World J Gastroenterol* 2015;21(46):13160–13165
- 30 Karakayali FY, Tezcaner T, Moray G. Anorectal function and outcomes after transanal minimally invasive surgery for rectal tumors. *J Minim Access Surg* 2015;11(04):257–262
- 31 Marinello FG, Curell A, Tapiolas I, Pellino G, Vallribera F, Espin E. Systematic review of functional outcomes and quality of life after transanal endoscopic microsurgery and transanal minimally invasive surgery: a word of caution. *Int J Colorectal Dis* 2020;35(01):51–67