

Classical Case of Primary Cutaneous Diffuse Large B-cell Lymphoma, Leg Type

Fallbericht eines primär kutanen diffusen großzelligen B-Zell-Lymphoms

Authors

V. Lauryne¹, J. Karčiauskienė¹, J. Makstienė², V. Kucinskienė¹, S. Valiukevičienė¹

Institutions

¹ Department of Skin and Venereal Diseases, Lithuanian University of Health Sciences, Medical Academy, Kaunas, Lithuania
² Department of Pathological Anatomy, Lithuanian University of Health Sciences, Medical Academy, Kaunas, Lithuania

Bibliography

DOI <http://dx.doi.org/10.1055/s-0042-108019>
 Published online: 6.6.2016
 Akt Dermatol 2016; 42: 357–359
 © Georg Thieme Verlag KG
 Stuttgart · New York
 ISSN 0340-2541

Corresponding author

Skaidra Valiukevičienė

Professor and Head
 Department of Skin
 and Venereal Diseases
 Medical Academy, Lithuanian
 University of Health Sciences,
 Kaunas
 Eiveniu 2
 50009 Kaunas
 Litauen
skaidra.valiukeviciene@kaunoklinikos.lt

Abstract

Primary cutaneous diffuse large B-cell lymphoma, leg type (PCDLBCL-LT) usually occurs in elderly patients and in most cases affects lower legs. A 76-year old man presented with red-brown coloured patches and plaques with irregular borders and multiple firm nodes on the anterior surface of the right lower leg. The excision biopsy of a

Case Report

A 76-year old man presented with multiple lesions located on his right leg. The skin lesions appeared 5 months ago on the anterior surface of the right lower leg and slowly enlarged (◉ Fig. 1). Previously the patient was treated with topical steroids without any effect. Physical examination showed red-brown coloured patches and plaques with irregular borders and multiple firm nodes on the anterior surface of the right lower leg. There were no palpable regional lymph nodes. The patient's medical history included type II diabetes, hypertension and multiple seborrheic keratoses on the back.

Histological examination of the excised skin node revealed dense infiltrates of large atypical cells within the dermis. Haematoxylin and eosin staining showed lymphoid cells with cellular heteromorphism, cells with irregular nuclei, prominent nucleoli, mitoses, involving the entire dermis (◉ Fig. 2a, b). Immunohistochemical staining showed immunoreactivity with CD3. Tumour cells were positive for CD20 with diffuse BCL-6 staining (◉ Fig. 2c–e). BCL-2 expression varied and CD10 was weakly expressed (◉ Fig. 2f, g), TDT-339 and CYC2 staining were negative. KI-67 staining showed mitotic active tumour cells (◉ Fig. 2h).

Laboratory findings: complete blood count showed normocytic anaemia. The analysis of C-reactive protein, liver enzymes, creatinine, glu-

node and histological examination has confirmed the diagnosis of PCDLBCL-LT. Clinical, laboratory and radiological examination showed no evidence of systemic involvement. The treatment was started with R-CHOP (rituximab-cyclophosphamide, doxorubicin, vincristine and prednisone) regimen. The patient died within 10 months due to cardiac complications since the initial diagnosis.

cose tests, lactate dehydrogenase (LDH 207 U/l), as well as radiological tests (chest X-ray, abdominal ultrasound, peripheral lymph nodes) were without pathological results.

Based on the clinical, histological and immunohistochemistry findings, the diagnosis of primary cutaneous diffuse large B-cell lymphoma, leg type was confirmed.

According to the recommendations of the European Organization for Research and Treatment of Cancer and International Society for Cutaneous Lymphoma consensus [1] for the management of cutaneous B-cell lymphomas, the treatment with polychemotherapy R-CHOP regimen (rituximab-cyclophosphamide, doxorubicin, vincristine, and

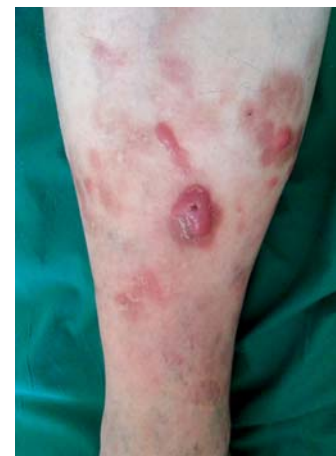

Fig. 1 Red-brown coloured patches and plaques with irregular borders and multiple firm nodes on the anterior surface of the right lower leg.

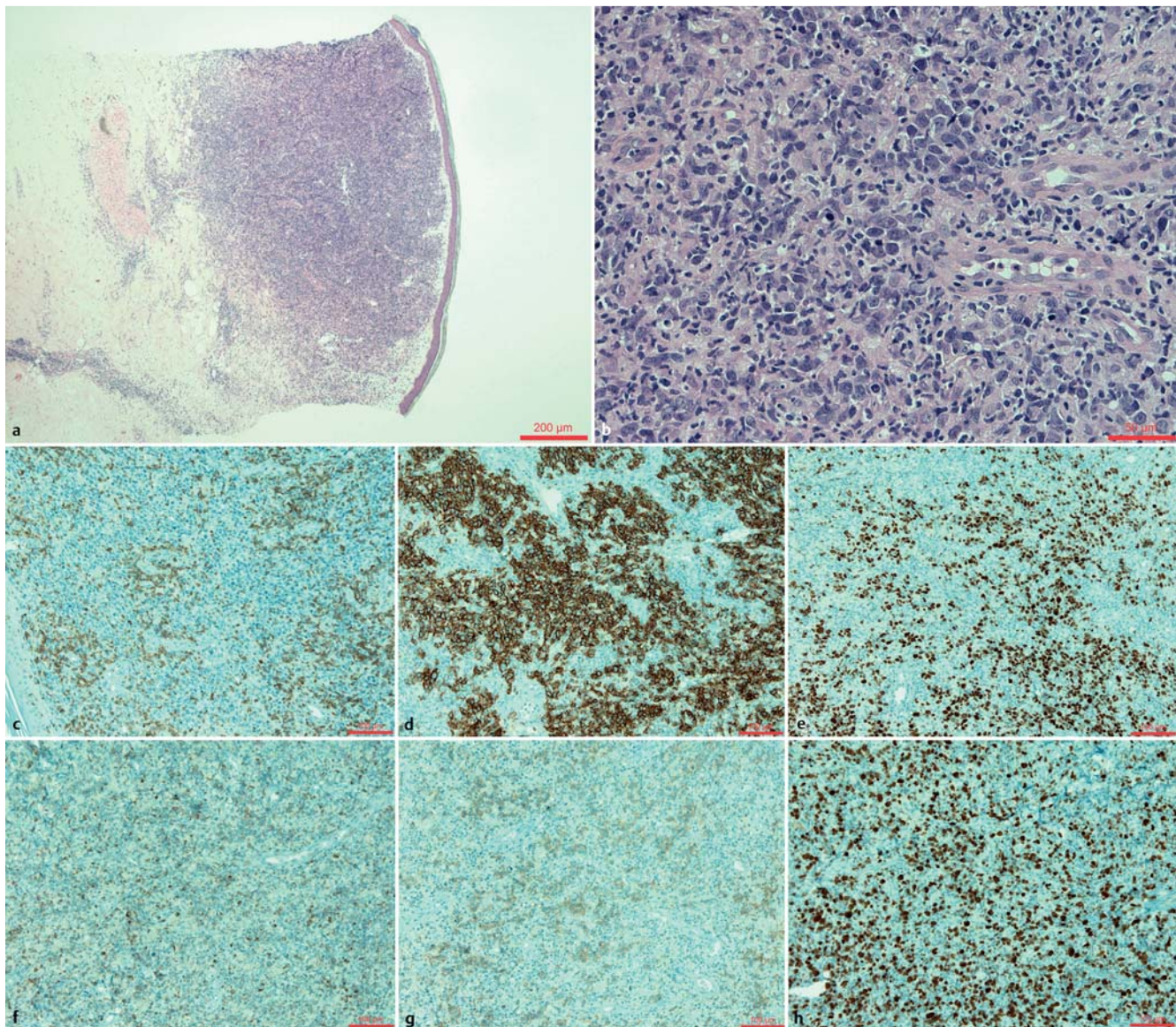


Fig. 2 **a** Dense infiltrate of large atypical lymphoid cells within the dermis (H + E, original magnification $\times 40$). **b** Lymphoid cells with cellular heteromorphism, cells with irregular nuclei, prominent nucleoli, mitoses, involving the entire dermis (H + E, original magnification $\times 400$). **c** CD3, original magnification $\times 200$. **d** CD20, original magnification $\times 200$. **e** BCL-6, original magnification $\times 200$. **f** BCL-2, original magnification $\times 200$. **g** CD10, original magnification $\times 200$. **h** KI-67, original magnification $\times 200$.

prednisone) was started. The patient died within 10 months due to cardiac complications since the initial diagnosis.

Discussion

The 2008 World Health Organization and the European Organization for Research and Treatment of Cancer (WHO-EORTC) classification for cutaneous lymphomas distinguish between three main types of primary cutaneous B-cell lymphomas: primary cutaneous follicular center lymphoma (PCFCL), primary cutaneous marginal zone lymphoma (PCMZL) and primary cutaneous diffuse large B-cell lymphoma, leg type (PCDLBCL-LT) [1]. This group of neoplasms represents a quarter to one-fifth of all primary cutaneous lymphomas [1, 2, 11].

PCDLBCL-LT is a group of B-cell lymphoproliferative disorders with specific histological characteristics (infiltrates contain monotonous population of medium-large cells with round nu-

clei, prominent nucleoli – immunoblasts and centroblasts [8]) and typically affect the lower legs [6, 9, 10]. The majority of the affected patients are elderly with an average age of 70 years and predominantly females [2–4]. Bluish-red to red skin nodes can be solitary or multiple, rapidly growing in size and affect characteristically legs [6, 12]. The minority of PCDLBCL-LT was reported on other body parts with similar morphology and phenotype, including the trunk [6, 7, 11], head [6, 11], and upper and lower arms [11, 13].

PCDLBCL-LT, in contrast to PCMZL and PCFCL with low malignancy, is more aggressive, frequently relapses and more often disseminates to extracutaneous sites during the course [1, 6, 10]. Multiple skin tumors on legs are signs for a bad outcome [7–9, 13] as well as age at onset [7, 8, 11] and disease duration [8, 11]. The 5-year survival rates of the disease range from 20% up to 63% [1, 2, 4, 7, 9, 10].

There are no complete randomized trials to expound the optimal treatment, because PCDLBCL-LT is relatively rare [5]. The first-

line recommendations for PCDLBCL-LT therapy suggest aggressive systemic multivalent chemotherapy in combination with rituximab (R-CHOP) with or without involved-field radiation therapy [1, 14, 15]. Alternative therapy includes local radiotherapy for all skin lesions or rituximab intravenously as a single-agent therapy [1, 10, 14].

Zusammenfassung

Fallbericht eines primär kutanen diffusen großzelligen B-Zell-Lymphoms

Das primäre kutane diffuse großzellige B-Zell-Lymphom, Unterschenkeltyp (PCDLBCL-LT) tritt bei älteren Patienten auf und fast immer an den Unterschenkeln. Ein 76-jähriger älterer Herr stellte sich mit rot-braunen Makeln und Plaques mit unregelmäßiger Begrenzung und mehreren indurierten Knoten am Schienbein des rechten Unterschenkels vor. Die Exzisionsbiopsie eines Knotens und die histologische Untersuchung bestätigten die Diagnose eines PCDLBCL-LT. Klinische, laborchemische und radiologische Untersuchungen zeigten keine Evidenz für eine systemische Beteiligung. Die Behandlung startete mit einem R-CHOP-Schema (Rituximab-Cyclophosphamid, Doxorubicin, Vincristin und Prednisolon). Der Patient verstarb aufgrund von kardialen Komplikationen 10 Monate nach Diagnosestellung.

References

- 1 Senff NJ, Noordijk EM et al. European Organization for Research and Treatment of Cancer and International Society for Cutaneous Lymphoma consensus recommendations for the management of cutaneous B-cell lymphomas. *Blood* 2008; 112: 1600–1609
- 2 Thomas V, Dobson R et al. Primary cutaneous large B-cell lymphoma, leg type. *Proc (Bayl Univ Med Cent)* 2011; 24: 350–353
- 3 Patsatsi A, Kyriakou A et al. Primary cutaneous diffuse large B-cell lymphoma, leg type, with multiple local relapses: case presentation and brief review of literature. *Hippokratia* 2013; 17: 174–176
- 4 Kempf W, Denisjuk N et al. Primary cutaneous B-cell lymphomas. *J Dtsch Dermatol Ges* 2012; 10: 12–22
- 5 Bessell EM, Humber CE et al. Primary cutaneous B cell lymphoma in Nottinghamshire U.K.: prognosis of sub-types defined in the WHO-EORTC classification. *Br J Dermatol* 2012; 167: 1118–1123
- 6 Willemze R, Jaffe ES et al. WHO/EORTC classification for cutaneous lymphomas. *Blood* 2005; 105: 3768–3785
- 7 Mondal SK, Mandal PK et al. Primary cutaneous large B-cell lymphoma, leg type: Report of two cases and review of literature. *Indian Journal of Medical and Paediatric Oncology: Official Journal of Indian Society of Medical & Paediatric Oncology* 2012; 33: 54–57
- 8 Kodoma K, Massone C et al. Primary cutaneous large B-cell lymphomas: Clinicopathologic features, classification and prognostic factors in a large series of patients. *Blood* 2005; 106: 2491–2497
- 9 Slater DN. The new World Health Organization – European Organization for Research and Treatment of Cancer classification for cutaneous lymphomas: a practical marriage of two giants. *British Journal of Dermatology* 2005; 153: 874–880
- 10 Sokol L, Naghashpour M. Primary cutaneous B-cell lymphomas: recent advances in diagnosis and management. *Cancer Control* 2012; 19: 236–244
- 11 Grange F, Beylot-Barry M et al. Primary cutaneous diffuse large B-cell lymphoma, leg type: clinicopathologic features and prognostic analysis in 60 cases. *Arch Dermatol* 2007; 143: 1144–1150
- 12 Antic D, Petrovic N et al. "Invisible" primary cutaneous diffuse large B-cell lymphoma, leg type, as a cause of fever of unknown origin. *J Clin Oncol* 2013; 31: e276–e279
- 13 Wobser M, Kneitz H et al. Primary cutaneous diffuse large B-cell lymphoma, leg-type, treated with a modified R-CHOP immunochemotherapy – diagnostic and therapeutic challenges. *JDDG* 2011; 9: 204–210
- 14 Hayakazu S, Sugaya M et al. Frequent Relapse and Irradiation Strategy in Primary Cutaneous Diffuse Large B-cell Lymphoma, Leg-type. *Acta Dermato-Venereologica* 2013; 97–98
- 15 Stadler R, Assaf C et al. Brief S2k guidelines – Cutaneous lymphomas. *JDDG* 2013; 11: 19–28