

Unilateral Stimulation of the Right Ovary in a 10-Year-Old Girl with Perforated Appendicitis

Introduction

Transabdominal ultrasound is the imaging modality of choice in the evaluation of girls with pathologic ovarian conditions such as ovarian masses, ovarian torsion or hemorrhagic ovarian cysts. The shape of the ovaries and their structure, size and blood flow can be determined by ultrasound. Before puberty, the ovaries have a volume of about 1 ml and contain small, non-stimulated follicles (I.J. Griffin et al. *Acta paediatrica* 1995; 84: 536–543). The presence of unilateral ovarian enlargement in a prepubertal girl may be a sign of torsion or of an ovarian mass and usually warrants further radiological evaluation or laparoscopic exploration (M.F. Brown et al. *J Pediatr Surg* 1993; 28:

930–933). The aim of this case report is to describe the value of abdominal ultrasound in unilateral ovarian stimulation in a prepubertal female patient with perforated appendicitis.

Case Report

A 10 year-old girl was brought by her parents to the emergency room due to pain in the right lower abdomen for 4 days. The girl had suffered from a varicella infection 3 weeks before. The initial ultrasound (Acuson S3000; Siemens, Erlangen, Germany) showed a markedly enlarged right ovary with a volume of 10.5 ml, which far exceeds the 97th percentile. The size and the arterial flow pattern were

consistent with a postpubertal stimulated ovary (F. Ziereisen et al. *Pediatr Radiol* 2001; 31: 712–719). The ovarian parenchyma was homogenous and contained enlarged follicles in the periphery (◉ Fig. 1a). In comparison, the left ovary was significantly smaller with a volume of 1.3 ml (corresponding to the 50th percentile) and showed no positive diastolic flow (◉ Fig. 1b). Moreover, free intraabdominal fluid and a thickened appendix with inflammatory alterations of the adjacent mesentery were present pointing to perforated appendicitis (◉ Fig. 2). No hemorrhagic ovarian cyst or mass was noticed. The pubertal stage of the girl was Tanner 1 (prepubertal) without breast development (B1) and neither pubic (P1) nor axillary hair. After making the diagnosis of perforated appendicitis, the subsequent laparoscopy revealed an inflammatory appendix with thick fibrous tissue lying between the colon and the right ovary. Due to a covered perforation at the tip of the appendix (◉ Fig. 3), antibiotic therapy was started. The right ovary was unre-

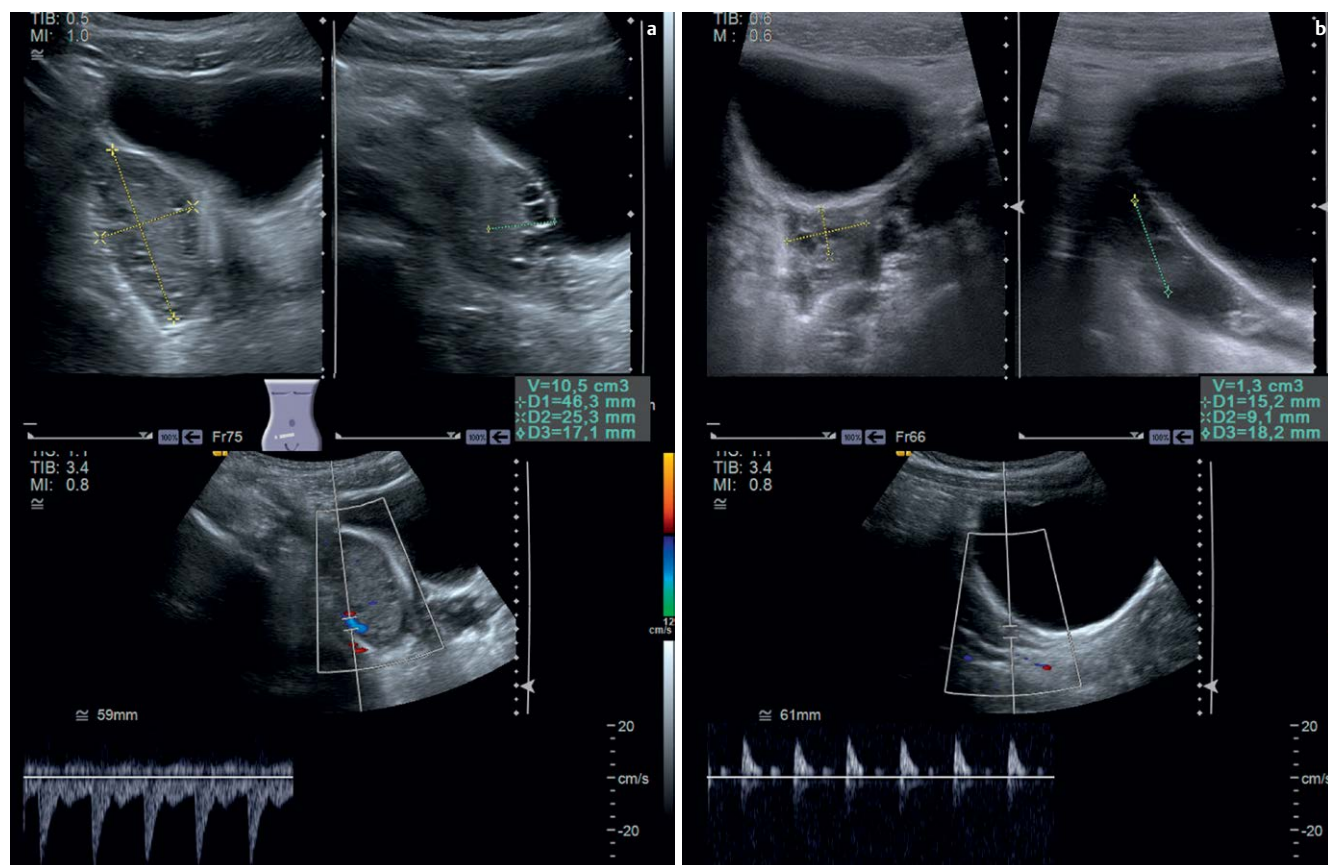


Fig. 1a 10-year-old girl with enlargement of the right ovary (volume of 10.5 ml) and multiple large follicles in the periphery. The Doppler flow pattern on the right side shows a positive diastolic flow consistent with a postpubertal flow pattern. **b** Normal left ovary (volume 1.3 ml). A Doppler pattern with no positive diastolic flow is typical in prepubertal girls.

License terms



markable except for indurated adnexa and nonspecific enlargement. Since there was significant peritonitis, the ovary was not biopsied. The appendix was removed through a 10 mm trocar. Then the peritoneal cavity was rinsed with 2.5 l of Ringer solution until the return of clear fluid. The postoperative course was unremarkable. The girl was discharged home in good general condition, afebrile and with non-irritated surgical wounds, and she had a normal follow-up in our outpatient

care. During surgery, there was no evidence of ovarian torsion or ovarian neoplasm. Therefore, no further laboratory tests were initiated. Due to the unilateral enlargement of the right ovary, follow-up ultrasound was performed after 5 months to rule out persistent stimulation. The follow-up ultrasound showed significant size reduction of the right ovary (from a previous volume of 10.5 ml to 5.5 ml, corresponding to the 75th percentile). In the meantime, the left ovary had grown from

a volume of 1.3 ml to 6.2 ml (corresponding to the 80th percentile). Both ovaries showed comparable size and normal follicles. There was still a difference in the Doppler flow pattern with a postpubertal Doppler flow on the right side (positive diastolic flow) and a prepubertal flow pattern on the left side (no diastolic flow). No clinical signs of puberty were present (Tanner stage 1).

Discussion

During puberty, the ovaries change their size significantly. The changes are related to the increasing concentrations of the gonadotropins LH and FSH. Abdominal ultrasound enables visualization of the size, shape and structure of the ovaries and the uterus. In addition, the Doppler flow pattern of the ovaries may differentiate a prepubertal from a postpubertal state. In females, most pubertal changes are caused by estrogen stimulation as a result of the onset of central puberty, which leads to significant development in

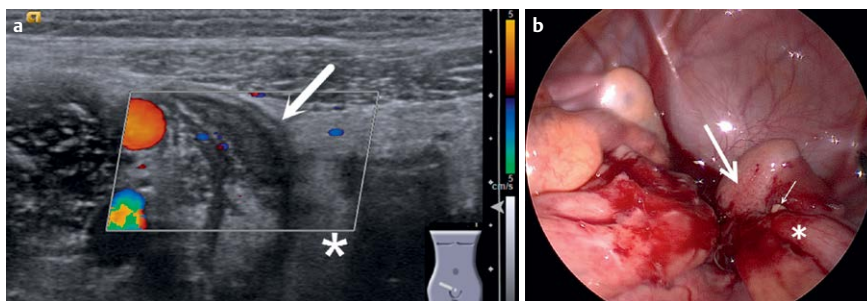


Fig. 2 a With the 18-MHz linear transducer, a thickened appendix (arrow) can be demonstrated with increased echogenicity of the adjacent mesentery (asterisk) in proximity to the right ovary. b During laparoscopy, a thickened and inflamed appendix was revealed (asterisk). There was some pus (small arrow) next to the enlarged ovary (large arrow).

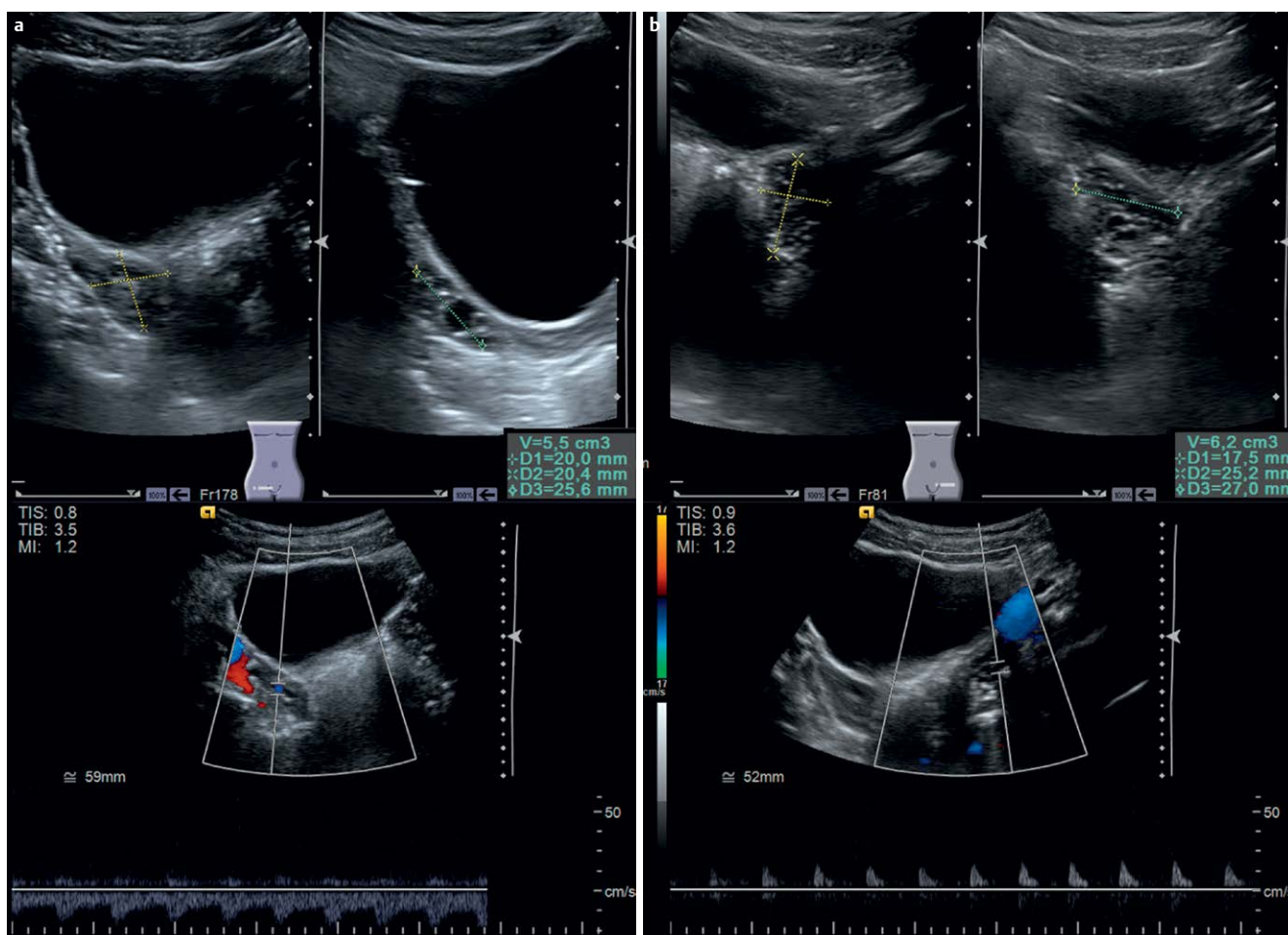


Fig. 3 a 5 months after surgery, the follow-up sonography shows a marked decrease of the ovarian size (5.5 ml) on the right side. b The size of the left ovary is now similar to the right ovary. The Doppler flow pattern of the right ovary is postpubertal, while the flow pattern on the left side is still prepubertal.

the organs of the female reproductive system and to anatomic changes that characterize reproductive maturity (C.W. Colvin et al. *Clin Anat* 2013; 26: 115–129). During puberty, hormonal stimulation of the ovaries usually occurs bilaterally. Ovarian artery pulsatile indices, which seem to reflect the arterial tone or alterations in the resistance to blood flow in the vascular bed, inversely correlate with plasma LH concentrations. Elevated LH plasma levels may be responsible for increased stromal vascularization by different mechanisms that may act individually or in a cumulative way: angiogene-

sis, catecholaminergic stimulation and leukocyte and cytokine activation (M. Brannstrom et al. *Hum Reprod* 1993; 8: 1762–1775). Unilateral enlargement of one ovary may be a sign of ovarian masses, follicle cysts or ovarian torsion. Rare causes in non-sexually active girls are metastatic cancer, ovarian cancer and oophoritis. In this prepubertal girl, it is conceivable that leucocyte activation due to inflammation from perforated appendicitis and peritonitis may have caused enlargement of the right ovary. The follow-up exam showing a marked decrease of the volume virtually excludes other enti-

ties such as neoplasms or persistent hormonal overstimulation of the right ovary. In conclusion, transabdominal ultrasound of the ovaries with Doppler flow is extremely useful in diagnosing ovarian changes during normal development (puberty) as well as in pathophysiological conditions as shown in our patient with concomitant transient ovarian stimulation and alteration of the perfusion pattern due to perforated appendicitis.

E. Stranzinger, C. Scherer, W. Pabst, F. Schuster, C. Flück