

Quality Requirements for Ultrasound Examination in Early Pregnancy (DEGUM Level I) between 4+0 and 13+6 Weeks of Gestation

DEGUM Level III Group Recommendations of the Section Obstetrics and Gynecology, Deutsche Gesellschaft für Ultraschall in der Medizin (DEGUM)

Qualitätsanforderungen an die Ultraschalluntersuchung in der Frühschwangerschaft (DEGUM-Stufe I) zwischen 4+0 und 13+6 Schwangerschaftswochen

Empfehlung der DEGUM-Stufe III der Sektion Gynäkologie und Geburtshilfe der Deutschen Gesellschaft für Ultraschall in der Medizin

Authors

A. Rempen¹, R. Chaoui², M. Häusler³, K.-O. Kagan⁴, P. Kozłowski⁵, C. von Kaisenberg⁶, J. Wisser⁷

Affiliations

Affiliation addresses are listed at the end of the article.

Key words

- first trimester
- gestational age
- normal pregnancy
- abnormal pregnancy

Preliminary remarks

▼
The transvaginal ultrasound scan using high-resolution real-time probes is the method of choice for medically establishing early pregnancy. If there is secondary amenorrhea or a positive pregnancy test, the viability and location of the pregnancy can be assessed. The present DEGUM recommendation replaces the paper from 2001 [1]. In this paper, early pregnancy (1st trimester) is defined as less than 14+0 weeks of gestation from the first day of the last menstrual period. All references to gestational age are made in completed weeks plus additional days from the last menstruation.

The EFSUMB statement gives information on the biological effects of diagnostic ultrasound [2].

Technical recommendations

▼
An early pregnancy ultrasound scan is best performed transvaginally. The probes (mechanical or electronic sector probes) should be high frequency (4.0–12.0 MHz) and have a minimum sector angle of 110°. The urinary bladder should be empty or almost empty. In the last three weeks of early pregnancy, abdominal probes may achieve better visualization of the pregnancy as the uterus has grown and abdominal probes can be rotated and maneuvered more easily. Abdominal probes (electronic curved arrays, electronic sector probes or mechanical sector probes) should have a frequency range of 3.0–7.5 MHz. A zoom function is mandatory for clinical interpretation of the findings and allows the area of interest to be magnified and cover the whole screen. The calipers should be cross-shaped. The focus should be placed near the structure to be examined.

In Germany, periodic examination of ultrasound probes and ultrasound units is compulsory in

order to maintain perfect condition and functioning of the system (Ultraschallvereinbarung 10/31/2008) [3].

Early ultrasound scan tasks

▼
An early pregnancy ultrasound scan should address the following questions:

- ▶ Location of pregnancy
- ▶ Fetal viability
- ▶ Number of embryos including chorionicity, amnionicity
- ▶ Gestational age
- ▶ Abnormalities of embryonal anatomy

Implantation of the embryo into the endometrium can be directly demonstrated using an ultrasound scan from 4 weeks. Fetal viability may be demonstrated as early as 40 days from the first day of the last menstrual period (5+5 weeks of gestation) and after 50 days (7+1 weeks of gestation) embryonal movement can be shown [4, 5].

If multiple gestation is diagnosed in early pregnancy, chorionicity and amnionicity should be recorded and documented on a picture. The suspicion of embryonic abnormalities should prompt clarification by an expert.

Ascertainment of pregnancy

▼
The first ultrasound scan in early gestation should verify intrauterine implantation of the pregnancy. A normal chorionic cavity has an asymmetrical location inside the endometrium, in contrast to intracavitary fluid accumulation. The implantation site should be surrounded by the myometrium on all sides. Thus, the diagnosis of isthmic or cervical pregnancy may be best established in early pregnancy.

received 28.3.2016

accepted 4.8.2016

Bibliography

DOI <http://dx.doi.org/10.1055/s-0042-115581>
Published online: September 14, 2016
Ultraschall in Med 2016; 37: 579–583 © Georg Thieme Verlag KG Stuttgart · New York · ISSN 0172-4614

Correspondence

Prof. Andreas Rempen
Frauenklinik, Diakonie-Klinikum
Diakoniestr.10
74523 Schwäbisch Hall
Germany
Tel.: ++49/791/7534605
Fax: ++49/791/7534923
arempen@diaksha.de

Every scan in early pregnancy should consider uterine anomalies (uterus arcuatus, uterus subseptus, uterus bicornis, uterus duplex) and assess the adnexal region. The evaluation of the uterus and adnexal region includes the documentation of myoma and adnexal cysts.

The viability of the embryo can be easily demonstrated using real-time ultrasound and should be mentioned in the record. A time motion scan (M-mode) is not mandatory for establishing a viable early pregnancy.

Abnormal early pregnancy

To distinguish between a normal and an abnormal intrauterine or ectopic pregnancy, the following criteria may apply [6]:

- ▶ A chorionic cavity should be detectable on a vaginal ultrasound scan from hCG concentrations of 1500 mIU/ml (3rd International Reference Preparation),
- ▶ The yolk sac should be detectable on a vaginal ultrasound scan from a mean chorionic cavity of 10 mm and hCG concentrations of 20 000 mIU/ml,
- ▶ A positive heartbeat should be traceable from a mean chorionic cavity of 20 mm, a crown-rump-length (CRL) of 5 mm and hCG concentrations of 50 000 mIU/ml.

Vaginal/uterine bleeding from the vagina in early pregnancy is an important indication for a vaginal ultrasound scan [6]. A retrochorionic area that is hypoechoic or anechoic may indicate a hematoma and the origin of bleeding. If no hematoma can be demonstrated, bleeding from the trophoblast cannot be excluded as the blood may have flown out. An uterine fibroid behind the placenta or a local uterus contraction can be confused with hematomas.

Ultrasound criteria proving irreversible damage in early pregnancy under normal visualization conditions are [6–8]:

- ▶ A chorionic diameter of ≥ 25 mm without embryonic structures including yolk sac,
- ▶ No growth of the chorionic diameter with a CHD < 25 mm on an ultrasound scan 7 days later,
- ▶ No positive heartbeat in an embryo (CRL) of ≥ 7 mm,
- ▶ Persistent negative heartbeat in an embryo (CRL) < 7 mm on an ultrasound scan 7 days later,
- ▶ Absence of an embryo and a heartbeat ≥ 11 days after demonstrating a chorionic cavity and a yolk sac,
- ▶ Ongoing absence of an embryo with heartbeats ≥ 2 weeks after demonstrating a chorionic cavity without a yolk sac.

Molar pregnancy

A complete molar pregnancy can be sonographically characterized by multiple 3–5 mm cysts infiltrating the trophoblast and an hCG of $> 200\,000$ mIU/ml [9, 10]. There is absence of an embryo. In a partial molar pregnancy, there are abnormally developing embryo-fetal structures and the hCG level is usually $< 100\,000$ mIU/ml.

Ectopic pregnancy

An empty uterus cavity on a vaginal ultrasound scan at more than 6 weeks of gestation or an hCG of > 1500 mIU/ml (3rd International Reference Preparation) without prior bleeding may raise the suspicion of an abnormally located ectopic pregnancy and should prompt the targeted examination of the adnexal regions. In the case of a previous cesarean section, implantation

into the scar should be considered [11, 12]. The ultrasound criteria of ectopic pregnancy are [6, 13]:

- ▶ Empty uterine cavity with/without intrauterine fluid accumulation,
- ▶ +/- free fluid in the Douglas cavity: an- or hypoechoic (fresh blood), inhomogeneous echoes (hematomas, blood clots),
- ▶ +/- tumor of the adnexal region (tubal or ovarian pregnancy): inhomogeneous complex (hematoma, trophoblast) or echogenic circular structure (chorionic cavity) with/without heartbeat (positive heart action is evidence),
- ▶ +/- swollen cervix with a fixed chorionic cavity below the os internum or below the entry of the uterine arteries (cervical pregnancy),
- ▶ +/- chorionic cavity inside the cesarean section scar (anterior isthmus region),
- ▶ +/- chorionic cavity located inside the tube just passing through the very thin external myometrium layer, the distance to the endometrial echo being > 1 cm (interstitial/cornual pregnancy).

As the site of the implantation is unphysiological, the development of the pregnancy is frequently abnormal, making a proper diagnosis more difficult [14]. If the chorionic cavity cannot be identified, the suspected diagnosis can only be made considering the patient's history, the clinical findings and a positive pregnancy test. If the location of the pregnancy remains unclear, repeated ultrasound scans and hCG measurements every other day may be helpful [15].

Pregnancy dating

When performing an early pregnancy scan, the length of the embryo should be measured if an embryo is present and compared with the calculated gestational age. An image of the measurement should be recorded. Internationally there are a number of algorithms to derive gestational age from the measured crown-rump-length [16]. Examples of reference ranges for fetal growth with known gestational age are shown in [Fig. 1](#) [17] and for dating in [Table 1](#) [14]. These ranges have been shown to be useful for Germany.

The determination of gestational age through biometry in early pregnancy yields more reliable results than those based on later measurements [14, 18]. Dating of gestational age should be accurate as gestational age plays a role in the risk assessment of premature contractions, of intrauterine growth restriction in the second half of pregnancy or in post-date pregnancies [19, 20].

The best estimation of gestational age can be achieved by measuring the crown-rump length (CRL) [21]. This can be measured in sagittal and frontal sections ([Fig. 2](#)). In early gestation the yolk sac is excluded and in the late first trimester the fetus should not be bent or overextended. From 8 weeks the biparietal diameter (BPD) may also be used for the estimation of gestational age. The pregnancy should be dated on ultrasound if gestational age deviates more than 7 days from that derived from the first day of the last menstrual period. The gestational age should only be adjusted once.

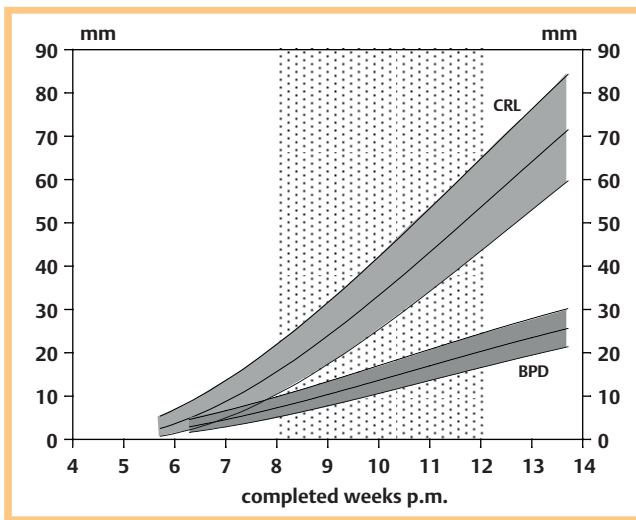


Fig. 1 Vaginosonographic growth curves (50th percentile with 90% confidence limits) of crown-rump length (CRL) and biparietal diameter (BPD) in the 1st trimester (adapted from [17]). The time interval of the first ultrasound screening is depicted.

Multiple gestation

The early pregnancy ultrasound examination can determine the number of fetuses as well as chorionicity and amnionicity [22 – 24]. Dichorionic twins are separated by a thick membrane (chorion). When the two placentae grow towards each other, a fold develops (λ-sign) (● Fig. 3). In monochorionic twins there is a thin membrane (amnion) arising vertically from the placenta (T-sign) (● Fig. 4) and in monoamniotics there is no intertwin membrane. This discrimination is of major prognostic importance [25]. In monochorionic twins, parents should be informed about the possibility of the subsequent development of twin-to-twin-transfusion syndrome (TTTS) [26]. Further potential complications of monochorionic twins are selective intrauterine growth restriction (sIUGR), intrauterine fetal death (IUFD) and the twin-anemia-polycythemia sequence (TAPS) [27].

Multiples have the same growth rates in the first trimester as singletons. Therefore, growth charts for singletons may be used [14]. In the case of discordant growth, the bigger crown-rump length is used for the estimation of the gestational age [28].

Ultrasound screening at 8+0 – 11+6 weeks of gestation

The aim of ultrasound-based prenatal care (Mutterschafts-Richtlinien) is to establish important findings for pregnancy management [29]. Ultrasound screening aims at establishing the location of the pregnancy but this becomes less important as the pregnancy progresses. The viability of an embryo/fetus is established on the basis of a positive heartbeat and movement of the embryo and should be documented. Gestational age is verified by measuring the crown-rump length (CRL) or the biparietal diameter (BPD). Re-dating may be done as described above. An estimated date of delivery should be fixed. In multiple gestation the above applies.

Table 1 Estimated gestational age derived from crown-rump length (CRL) and biparietal diameter (BPD) in the first trimester [16].

mm	completed weeks+days p.m. (CRL)			completed weeks+days p.m. (BPD)		
	5%	50%	95%	5%	50%	95%
1	–	–	–	–	–	–
2	5+2	6+0	6+4	–	–	–
3	5+4	6+1	6+5	6+1	6+6	7+3
4	5+5	6+2	7+0	6+3	7+1	7+6
5	5+6	6+3	7+1	6+5	7+3	8+1
6	6+0	6+4	7+2	7+0	7+5	8+4
7	6+1	6+5	7+3	7+2	8+0	8+6
8	6+2	6+6	7+4	7+4	8+2	9+1
9	6+3	7+0	7+5	7+6	8+4	9+3
10	6+4	7+1	7+6	8+1	8+6	9+5
11	6+4	7+2	8+0	8+2	9+1	10+1
12	6+5	7+3	8+1	8+4	9+3	10+3
13	6+6	7+4	8+2	8+6	9+5	10+5
14	7+0	7+5	8+3	9+1	10+0	11+0
15	7+1	7+6	8+4	9+3	10+2	11+2
16	7+2	8+0	8+5	9+4	10+4	11+5
17	7+3	8+0	8+6	9+6	10+6	12+0
18	7+3	8+1	9+0	10+1	11+1	12+2
19	7+4	8+2	9+0	10+3	11+3	12+4
20	7+5	8+3	9+1	10+5	11+5	13+0
21	7+6	8+4	9+2	11+0	12+1	13+2
22	7+6	8+5	9+3	11+2	12+3	13+5
23	8+0	8+5	9+4	–	–	–
24	8+1	8+6	9+5	–	–	–
25	8+2	9+0	9+6	–	–	–
26	8+3	9+1	9+6	–	–	–
27	8+3	9+2	10+0	–	–	–
28	8+4	9+2	10+1	–	–	–
29	8+5	9+3	10+2	–	–	–
30	8+6	9+4	10+3	–	–	–
31	8+6	9+5	10+3	–	–	–
32	9+0	9+6	10+4	–	–	–
33	9+1	9+6	10+5	–	–	–
34	9+1	10+0	10+6	–	–	–
35	9+2	10+1	11+0	–	–	–
36	9+3	10+2	11+0	–	–	–
37	9+4	10+2	11+1	–	–	–
38	9+4	10+3	11+2	–	–	–
39	9+5	10+4	11+3	–	–	–
40	9+6	10+5	11+4	–	–	–
41	10+0	10+5	11+4	–	–	–
42	10+0	10+6	11+5	–	–	–
43	10+1	11+0	11+6	–	–	–
44	10+2	11+1	12+0	–	–	–
45	10+2	11+1	12+0	–	–	–
46	10+3	11+2	12+1	–	–	–
47	10+4	11+3	12+2	–	–	–
48	10+5	11+4	12+3	–	–	–
49	10+5	11+4	12+3	–	–	–
50	10+6	11+5	12+4	–	–	–
51	11+0	11+6	12+5	–	–	–
52	11+0	11+6	12+6	–	–	–
53	11+1	12+0	12+6	–	–	–
54	11+2	12+1	13+0	–	–	–
55	11+2	12+2	13+1	–	–	–
56	11+3	12+2	13+2	–	–	–
57	11+4	12+3	13+3	–	–	–
58	11+5	12+4	13+3	–	–	–
59	11+5	12+5	13+4	–	–	–
60	11+6	12+5	13+5	–	–	–

This document was downloaded for personal use only. Unauthorized distribution is strictly prohibited.

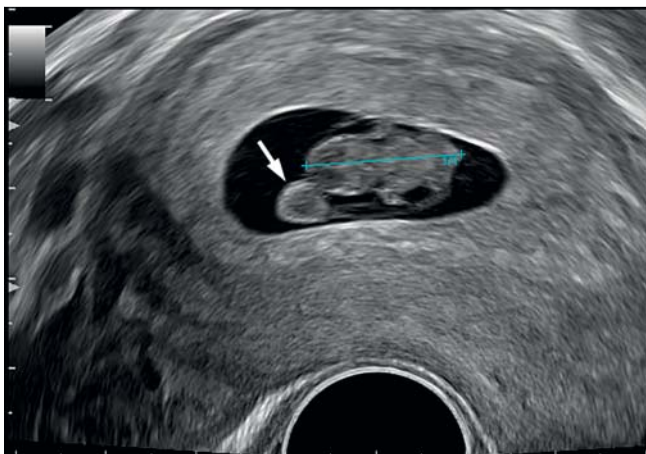


Fig. 2 Vaginosonographically measured crown-rump length (CRL, +--+), 8 weeks. The yolk sac (→) must be considered.

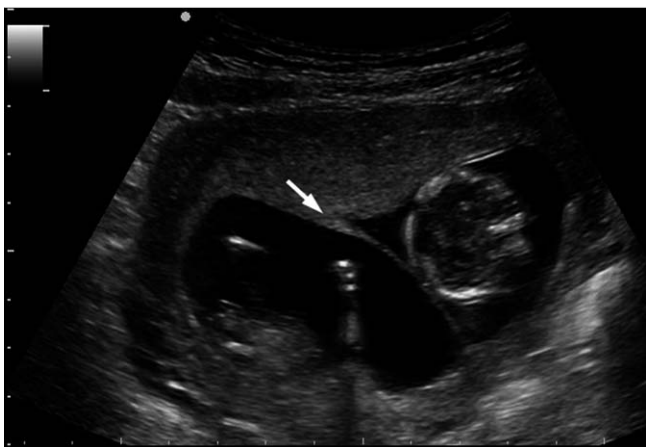

Fig. 3 Dichorionic twin pregnancy with λ-sign (→), 12 weeks.

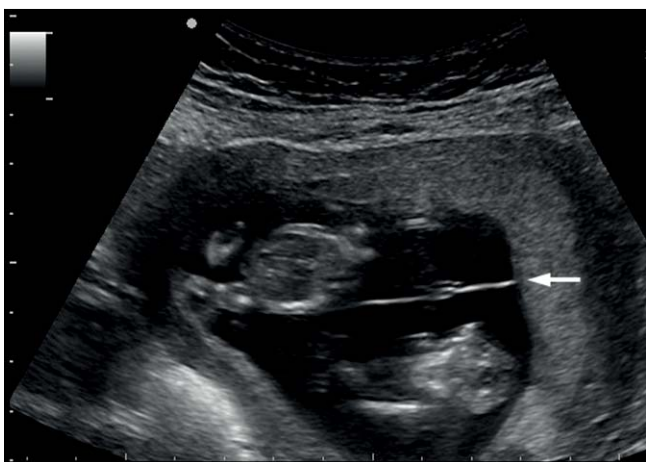

Fig. 4 Monozygotic diamniotic twin pregnancy with T-sign (→), 12 weeks.

Screening should include an assessment of the anatomical integrity of the embryo/fetus. This includes (DEGUM):

- ▶ Demonstration of four extremity buds,
- ▶ Exclusion of generalized skin edema,
- ▶ Demonstration of a smooth contour of the skull,
- ▶ Exclusion of intraabdominal cysts > 10 mm.

Abdominal wall defects can only be excluded at > 12 + 0 weeks of gestation when the physiological umbilical hernia has regressed [17, 30]. If abnormalities of the embryo-fetal anatomy are suspected, an experienced examiner should be involved for a second opinion before clinical consequences follow.

Anomaly scanning in early gestation

The diagnosis of abnormal integrity of the embryo/fetus allows the detection of non-viable major defects such as anencephaly [17, 31] and has the potential for early fetal therapy [32]. An increased nuchal translucency is associated with a large number of developmental disorders [33]. Suspicious ultrasound findings or a respective history should prompt a fetal anomaly scan at 12 + 0 weeks of gestation to confirm normality. There are detailed quality requirements for a detailed anomaly scan at 11 – 13 + 6 weeks of gestation published by the DEGUM [34] and ISUOG [35]. As high-resolution ultrasound machines become more easily available, many details can be visualized [17, 36] (Table 2). A transvaginal route may be additionally used if the transabdominal route does not allow identification of all fetal structures. However, anomalies cannot always be diagnosed or excluded and may manifest later in pregnancy or may be difficult to interpret with respect to their significance in early gestation. Therefore, a follow-up scan between 18 + 0 and 21 + 6 weeks of gestation is recommended [37].

Only when the diagnosis of an anomaly or disease of the embryo or fetus is ascertained can a termination of pregnancy be considered. In many cases the correct diagnosis of an anomaly in the embryo/fetus may not be made post-abortum due to limited availability of appropriately trained pathologists or postmortem MRI (exceptions are numerical and structural chromosomal defects). Recurrent risks for such conditions therefore cannot be given to parents in most cases.

Documentation

Images should be recorded from all measurements and suspicious findings. In multiple gestation, amnionicity and chorionicity should be documented. Written documentation of the viability and the implantation site should be created for each examination and should include a detailed description if suspicious or abnormal findings are identified.

Affiliations

- ¹ Clinic of Gynecology and Obstetrics, Diakonie-Klinikum, Schwaebisch Hall, Germany
- ² Practice of Prenatal Medicine, Berlin, Germany
- ³ Department of Obstetrics, University Clinic, Graz, Austria
- ⁴ University Clinic of Obstetrics and Gynecology, Tübingen, Germany
- ⁵ Prenatal Medicine and Genetics, Duesseldorf, Germany
- ⁶ Department of Obstetrics and Gynecology, Hannover Medical School, Hannover, Germany
- ⁷ Clinic of Obstetrics, University Hospital, Zurich, Switzerland

completed weeks	4	5	6	7	8	9	10	11	12	13
chorionic cavity	••	•••	•••	•••	•••	•••	•••	•••	•••	•••
yolk sac	•	••	•••	•••	•••	•••	••	••	••	•
embryo/heart activity	–	•	••	•••	•••	•••	•••	•••	•••	•••
head	–	–	•	••	•••	•••	•••	•••	•••	•••
umbilical cord	–	–	o	•	•••	•••	•••	•••	•••	•••
physiological umbilical hernia	–	–	–	–	•••	•••	•••	••	–	–
extremities	–	–	–	•	••	••	•••	•••	•••	•••
falx cerebri	–	–	–	–	•	••	•••	•••	•••	•••
stomach	–	–	–	–	o	•	••	•••	•••	•••
bladder	–	–	–	–	–	–	–	••	••	•••
kidneys	–	–	–	–	–	–	–	••	••	•••
heart (4-chamber view)	–	–	–	–	–	–	–	••	•••	•••

Table 2 Sonographic visualization of embryo-fetal structures in early pregnancy: o = < 10 %, • = 10–50 %, •• = 50–90 %, ••• > 90 % [14].

References

- 1 Rempen A, Chaoui R, Kozlowski P et al. Standards zur Ultraschalluntersuchung in der Frühschwangerschaft. Z Geburtshilfe Neonatol 2001; 205: 162–165
- 2 EFSUMB ECMUS Committee. Aktuelle Safety Statements & Guidelines. <http://www.efsumb-portal.org/ep/article.php?id=264>
- 3 Vereinbarung von Qualitätssicherungsmaßnahmen nach § 135 Abs. 2 SGB V zur Ultraschalldiagnostik (Ultraschall-Vereinbarung) vom 31.10.2008 in der Fassung vom 18.12.2012. <http://www.kbv.de/media/sp/Ultraschall.pdf>
- 4 Rempen A. Vaginale Sonografie im ersten Trimenon. I. Qualitative Parameter. Z Geburtshilfe Perinatol 1991; 195: 114–122
- 5 Wisser J, Dirschedl P. Embryonic heart rate in dated human embryos. Early Hum Dev 1994; 37: 107–115
- 6 Feige A, Rempen A, Würfel W et al. Frauenheilkunde. 3. Aufl. München-Wien-Baltimore: Urban & Schwarzenberg; 2006
- 7 Abdallah Y, Daemen A, Kirk E et al. Limitations of current definitions of miscarriage using mean gestational sac diameter and crown-rump length measurements: a multicenter observational study. Ultrasound Obstet Gynecol 2011; 38: 487–502
- 8 Doubilet PM, Benson CB, Bourne T et al. Diagnostic criteria for nonviable pregnancy early in the first trimester. N Engl J Med 2013; 369: 1443–1451
- 9 Benson CB, Genest DR, Bernstein MR et al. Sonographic appearance of first trimester complete hydatiforme moles. Ultrasound Obstet Gynecol 2000; 16: 188–191
- 10 Cole LA. Human chorionic gonadotropin tests. Expert Rev Mol Diagn 2009; 9: 721–747
- 11 Rempen A, Albert P. Diagnose und Therapie einer in der Sectionarbe implantierten Frühschwangerschaft. Z Geburtshilfe Perinatol 1990; 194: 46–48
- 12 Ash A, Smith A, Maxwell D. Cesarean scar pregnancy. BJOG 2007; 114: 253–263
- 13 Kirk E, Bottomley C, Bourne T. Diagnosing ectopic pregnancy and current concepts in the management of pregnancy of unknown location. Hum Reprod update 2014; 20: 250–261
- 14 Rempen A. Ultraschall in der Frühschwangerschaft. In: Schmidt W editor. Jahrbuch der Gynäkologie und Geburtshilfe 1997/98. Zülzich: Biermann-Verlag; 1997: 51–61
- 15 van Calster B, Abdallah Y, Guha S et al. Rationalizing the management of pregnancies of unknown location: temporal and external validation of a risk prediction model on 1962 pregnancies. Hum Reprod 2013; 28: 609–616
- 16 Napolitano R, Dhimi J, Ohuma EO et al. Pregnancy dating by fetal crown-rump length: a systematic review of charts. BJOG 2014; 121: 556–565
- 17 Rempen A. Diagnostik fetaler Anomalien in der Frühschwangerschaft. Gynäkologie 1999; 32: 169–180
- 18 Wisser J, Dirschedl P, Krone S. Estimation of gestational age by transvaginal sonographic measurement of greatest embryonic length in dated human embryos. Ultrasound Obstet Gynecol 1994; 4: 457–462
- 19 Rempen A. Effizienz der Ultraschallbiometrie in der Schwangerschaft. Gynäkologie 1996; 29: 553–561
- 20 Mai R, Rempen A, Kristen P. Vaginalsonografie im I. Trimenon zur Bestimmung des Geburtstermins. Frauenarzt 1995; 36: 681–688
- 21 Pexsters A, Luts J, van Schoubroeck D et al. Clinical implications of intra- and interobserver reproducibility of transvaginal sonographic measurement of gestational sac and crown-rump length at 6–9 weeks' gestation. Ultrasound Obstet Gynecol 2011; 38: 510–515
- 22 Wisser J. Vaginalsonografie im ersten Schwangerschaftsdrittel. Berlin-Heidelberg-New York: Springer; 1995
- 23 Sepulveda W, Sebire NJ, Hughes K et al. The lambda sign at 10–14 weeks of gestation as a predictor of chorionicity in twin pregnancies. Ultrasound Obstet Gynecol 1996; 7: 421–423
- 24 Dias T, Arcangeli T, Bhide A et al. First-trimester ultrasound determination of chorionicity in twin pregnancy. Ultrasound Obstet Gynecol 2011; 38: 530–532
- 25 Sebire NJ, Snijders RJ, Hughes K et al. The hidden mortality of monochorionic twin pregnancies. Br J Obstet Gynaecol 1997; 104: 1203–1207
- 26 Kagan K, Gazzoni A, Sepulveda-Gonzalez G et al. Discordance in nuchal translucency thickness in the prediction of severe twin-to-twin transfusion syndrome. Ultrasound Obstet Gynecol 2007; 29: 527–532
- 27 Lewi L, Gucciardo L, Van Mieghem T et al. Monochorionic diamniotic twin pregnancies: natural history and risk stratification. Fetal Diagn Ther 2010; 27: 121–133
- 28 Khalil A, Rodgers M, Baschat A et al. ISUOG Practice Guidelines: role of ultrasound in twin pregnancy. Ultrasound Obstet Gynecol 2016; 47: 247–263
- 29 Richtlinien des Bundesausschusses der Ärzte und Krankenkassen über die ärztliche Betreuung während der Schwangerschaft und nach der Entbindung („Mutterschafts-Richtlinien“) in der Fassung vom 10. Dezember 1985 (veröffentlicht im Bundesanzeiger Nr. 60a vom 27. März 1986) zuletzt geändert am 21. April 2016, veröffentlicht im Bundesanzeiger AT 19.07.2016 B5, in Kraft getreten am 20. Juli 2016: <https://www.g-ba.de/informationen/richtlinien/19/>
- 30 van Zalen-Sprock RM, Vogt JM, van Geijn HP. First-trimester sonography of physiological midgut herniation and early diagnosis of omphalocele. Prenat Diagn 1997; 17: 511–518
- 31 Johnson SP, Sebire NJ, Snijders RJM et al. Ultrasound screening for anencephaly at 10–14 weeks of gestation. Ultrasound Obstet Gynecol 1997; 9: 14–16
- 32 Wisser J, Kurmanavicius J, Lauper U et al. Successful treatment of fetal megavesica in the first half of pregnancy. Am J Obstet Gynecol 1997; 177: 685–689
- 33 Nicolaides KH, von Kaisenberg CS. Die Ultraschalluntersuchung von 11–13+6 Schwangerschaftswochen. London: Fetal Medicine Foundation; 2004, www.fetalmedicine.com
- 34 von Kaisenberg CS, Chaoui R, Häusler M et al. Qualitätsanforderungen an die weiterführende differenzierte Ultraschalluntersuchung in der pränatalen Diagnostik (DEGUM-Stufen II & III) im Zeitraum 11–13+6 Schwangerschaftswochen. Ultraschall in Med 2016; 37: 297–302
- 35 Salomon LJ, Alfirevic Z, Bilardo CM et al. ISUOG Practice Guidelines: Performance of first-trimester fetal ultrasound scan. Ultrasound Obstet Gynecol 2013; 41: 102–113
- 36 von Kaisenberg CS, Kuhling-von Kaisenberg H, Fritzner E et al. Fetal transabdominal anatomy scanning using standard views at 11 to 14 weeks' gestation. Am J Obstet Gynecol 2005; 192: 535–542
- 37 Merz E, Eichhorn KH, von Kaisenberg C et al. Aktualisierte Qualitätsanforderungen an die weiterführende differenzierte Ultraschalluntersuchung in der pränatalen Diagnostik (=DEGUM-Stufe II) im Zeitraum von 18+0 bis 21+6 Schwangerschaftswochen. Ultraschall in Med 2012; 33: 593–596