




Protocol of a Nerve Neurotmesis Sciatic Repair using Polyvinyl Alcohol Biofilm in Wistar Rats

Protocolo de reparação de uma neurotmesa do nervo ciático utilizando o biofilme de álcool polivinílico em ratos Wistar

Ana Camila Nobre de Lacerda Brito¹  Maria Danielly Lima de Oliveira²
 César Augusto Souza de Andrade² Héli da Cristina Cirilo da Silva³ Paulo César da Silva Queiroz³
 Sara Emanuely Veríssimo Santos³ Wilayne Alves Martins³ Estela Batista Santos³
 Romero Andion de Medeiros Sobrinho³ Kalline Lourenço Ribeiro⁴ Alberto Galdino da Silva Júnior⁴
 Sílvia Regina Arruda de Moraes⁵

¹Postgraduate Program in Neuropsychiatry and Behavioral Sciences, Universidade Federal de Pernambuco, Recife, PE, Brazil

²Department of Biochemistry, Universidade Federal de Pernambuco, Recife, PE, Brazil

³Department of Physiotherapy, Universidade Federal de Pernambuco, Recife, PE, Brazil

⁴Postgraduate Program in Therapeutic Innovation, Universidade Federal de Pernambuco, Recife, PE, Brazil

⁵Department of Anatomy, Universidade Federal de Pernambuco, Recife, PE, Brazil

Address for correspondence Ana Camila Nobre de Lacerda Brito, Laboratório de Plasticidade Neuromuscular, Departamento de Anatomia, Universidade Federal de Pernambuco, Avenida Professor Moraes Rego, 1235, Cidade Universitária, Recife, PE, CEP: 50670-901, Brazil (e-mail: britoanacamil@gmail.com).

Arq Bras Neurocir 2023;42(4):282–287.

Abstract

Background Animal models are commonly used to assess the efficacy of new materials to be employed in the surgical repair of a nerve injury. However, there is no published surgical repair protocol for sciatic nerve neurotmesis in rats.

Objective To produce and evaluate a protocol for the tubing technique using a polyvinyl alcohol biofilm after sciatic nerve neurotmesis.

Methods Eighteen rats were randomized into 3 groups ($n = 6$ per group): control group - CG, neurotmesis group - NG, and neurotmesis biofilm group - NBG. The NG and NBG animals were submitted to neurotmesis of the sciatic nerve at 60 days of life, followed by suture of the nerve stumps; in the NBG, the animals had the suture involved by polyvinyl alcohol biofilm. A descriptive evaluation of the surgical technique was performed after the experimental period. The Shapiro-Wilk normality test was used for body weight, and analysis of variance (ANOVA) with Bonferroni posthoc ($p < 0.05$) was applied.

Results All groups showed good repair of the skin and muscle sutures; however, 33.30% of the CG presented disruption of skin points. Furthermore, 16.70% of the stumps were not structurally aligned and 33.30% had neuromas in the NG, while in the NBG, all stumps were aligned and none of them had neuroma.

Keywords

- ▶ biofilm
- ▶ neurosurgical procedure
- ▶ peripheral nerve injuries
- ▶ rats
- ▶ sciatic nerve

received
 May 27, 2021
 accepted
 October 13, 2021

DOI <https://doi.org/10.1055/s-0042-1742297>.
 ISSN 0103-5355.

© 2023. Sociedade Brasileira de Neurocirurgia. All rights reserved. This is an open access article published by Thieme under the terms of the Creative Commons Attribution-NonDerivative-NonCommercial-License, permitting copying and reproduction so long as the original work is given appropriate credit. Contents may not be used for commercial purposes, or adapted, remixed, transformed or built upon. (<https://creativecommons.org/licenses/by-nc-nd/4.0/>)
 Thieme Revinter Publicações Ltda., Rua do Matoso 170, Rio de Janeiro, RJ, CEP 20270-135, Brazil

Conclusions The present study was able to produce a protocol with high reproducibility in view of the mechanical stability, targeting of the nerve stumps, muscle healing, the low frequency of skin breakage and the low complexity level of the technique, and it can be used in future studies that aim to evaluate other biomaterials for nerve repair in rats.

Resumo

Introdução Modelos animais são comumente utilizados para avaliar a eficácia de novos materiais a ser empregados no reparo cirúrgico de lesões nervosas. No entanto, não há protocolo de reparo cirúrgico publicado para neurotmesa do nervo ciático em ratos.

Objetivo Produzir e avaliar um protocolo para a técnica de tubulização usando um biofilme de álcool polivinílico após uma neurotmesa do nervo ciático.

Métodos Dezoito ratos foram randomizados em três grupos ($n = 6$ por grupo): grupo controle - GC, grupo neurotmesa - GN e grupo neurotmesa biofilme - GNB. Os animais do GN e do GNB foram submetidos à neurotmesa do nervo ciático aos 60 dias de vida, seguida de sutura dos cotos do nervo; no GNB, os animais tiveram a sutura envolvida por biofilme de álcool polivinílico. Após o período experimental, foi realizada avaliação descritiva da técnica cirúrgica. Para o peso corporal, foi utilizado o teste de normalidade Shapiro-Wilk e aplicada a análise de variância (ANOVA) com posthoc de Bonferroni ($p < 0,05$).

Resultados Todos os grupos apresentaram bom reparo de suturas de pele e musculares; porém, 33,30% do GC apresentou rompimento dos pontos da pele. Além disso, 16,70% dos cotos não estavam estruturalmente alinhados e 33,30% apresentavam neuromas no GN, enquanto todos os cotos estavam alinhados e nenhum apresentava neuroma no GNB.

Conclusões O presente estudo foi capaz de produzir um protocolo com alta reprodutibilidade tendo em vista a estabilidade mecânica, direcionamento dos cotos nervosos, cicatrização muscular, a baixa frequência de rompimento da pele e o baixo nível de complexidade da técnica, podendo ser utilizado em estudos futuros que avaliem outros biomateriais para reparo de nervo em ratos.

Palavras-chave

- ▶ biofilme
- ▶ procedimento neurocirúrgico
- ▶ lesões nervosas periféricas
- ▶ ratos
- ▶ nervo ciático

Introduction

The gold standard in repairing neurotmesis has been the autogenous free nerve graft. However, the surgical tubing technique, which consists of suturing the neural stumps inside the guide tube, has been studied since 1980,¹ bringing some benefits such as the prevention of neuromas, adequate guidance for aligning the stumps, inhibition of fibroblast infiltration, and, consequently, reduced scar tissue formation in the injured site.² This ultimately promotes the formation of a new extracellular matrix and, therefore, successful nerve regeneration.³

Several materials are made to serve as guide tubes for the nerve regeneration process, among which those of biological origin (muscles, blood vessels, tendons) and those of natural and synthetic origin stand out.^{4,5} Materials of synthetic origin can have their mechanical, chemical, and structural properties modified to increase the nerve regeneration through incorporating substances in its structure or its production in the form of mesh, sponge, and solid or porous tubes. The nervous conduit must be non-toxic with sufficient strength and flexibility, but without pressing the nerve,

minimally immunogenic and simple to manufacture. In addition, it must guide the direction of the regenerative nerve, isolate the regenerated axon from the scar tissue, and protect the regenerated nerve against surrounding compression.⁶ Synthetic conduits in the literature can be classified into non-biodegradable and biodegradable materials.⁷

Although models for crush injury (neuropraxia) already exist and have been described in the literature,⁸ and there is wide availability of artificial conduits,⁹ which are initially tested on animals (mostly rats) to be later applied in clinic,¹⁰ there are no standardized protocols which evaluate the behavior of these materials in experimental nerve repair models of a neurotmesis using the tubing technique.

Therefore, the present study aims to establish a surgical protocol for nerve repair of a neurotmesis using the sciatic nerve tubing technique in Wistar rats, using a polyvinyl alcohol conduit and a water-soluble, non-biodegradable polymer as a model. This model is well-accepted in the biomedical environment and has already been described in the literature for other therapeutic purposes.^{11,12}

Material and Methods

The study was performed at the neuromuscular plasticity laboratory of the anatomy department and the nanostructured biodevices laboratory (BIONANO) of the biochemistry department at Universidade Federal de Pernambuco (UFPE). The sample consisted of 18 Wistar rats, maintained at a temperature of $23 \pm 1^\circ\text{C}$, subjected to inverted light/dark cycles (12 hours) with commercial diet (Purina, St. Louis, MO, USA) and water ad libitum. The animals were randomized using the Random Allocation version 2.0 software) at 40 days of age into 3 groups: a) the control group (CG, $n=6$), rats that which did not undergo neurotmesis; b) neurotmesis group (NG, $n=6$), rats which underwent a complete lesion in the midpoint of the sciatic nerve with subsequent suture; c) neurotmesis and biofilm group (NBG, $n=6$), rats that underwent injury and had the suture covered with biofilm. The sciatic nerves were then analyzed in the 6th postoperative week.

Manufacturing and Obtaining Polyvinyl Alcohol Biofilm

Polyvinyl alcohol biofilms were produced by Bionano laboratory using 16% PVA and 2% alginate solutions in a 3:1 concentration.

The solutions were placed in syringes and subjected to electrospinning for 8 and 5 hours, respectively. The biofilms were subsequently submitted to the cross-linking process for 24 hours, and then were immersed in a solution of 98.9% methanol, 1% glutaraldehyde and hydrochloric acid. Next, they went through 5 deionized water baths, were placed to dry at 8°C for 3 to 7 days, cut into $10\text{ mm} \times 10\text{ mm}$ squares, and then sterilized under ultraviolet light for 30 minutes.

Surgical Procedure for Sciatic Nerve Injury

All animals were intraperitoneally anesthetized at the age of 60 days with a 0.05 mL and 0.1 mL xylazine hydrochloride (Anasedan) (20 mg Kg^{-1}) and ketamine hydrochloride solution (Dopalen) (100 mg Kg^{-1}) for each 100 g of the animal's body weight, which had been previously measured. Trichotomy was then performed after sedation on the right gluteal region, and then the area was cleaned with chlorhexidine antiseptic. The animal was sent to the sterile location, placed in the anatomical position, and the surgical procedure was started. A longitudinal incision was made in the skin of the posterosuperior region of the right paw, starting one centimeter below the greater trochanter of the femur in a diagonal direction and ending near the popliteal fossa at the level of the hamstring muscles. The sciatic nerve was exposed after disjoining the superficial gluteal and biceps femoris muscles. The sciatic nerve was visualized using a LEICA Zoom 2,000 Stereo Microscope, 10.5–45x (Leica Camera AG, Wetzlar, Germany), and a tentacle was placed under the nerve for its isolation with the adjacent tissues. AU: Please, note that if this is the name of a company, you must provide its complete name and location (city, state, and country) between parentheses.

Neurotmesis was performed in the animals of the injury groups with surgical scissors, 5 mm proximal to the division of the 3 main branches of the sciatic nerve (tibial, common

fibular, and sural), followed by direct coaptation of the nerve extremities with fascicular alignment and monofilament suture 7-0 CATGUT (Ethicon Inc., Raritan, NJ, USA) in about 3 points of the epineurium.¹³ In addition, the suture was covered with polyvinyl alcohol biofilm in the NBG. The animals in the CG only suffered a longitudinal skin incision, disjunction of the muscles described above, and visualization of the sciatic nerve. Then, muscle and skin suture with 4-0 nylon monofilament (Somerville) was performed to promote the same surgical stress as in the other groups (**► Fig. 1**).

Surgical Care

After applying the anesthetics, the analgesic tramadol hydrochloride (5% -100 mg/kg of animal weight, diluted in 0.9% saline - 1:1) was applied subcutaneously, being reapplied every 12 hours for 3 days. Topical antibiotic therapy (rifamycin SV sodium - 10 mg/ml; neomycin sulfate + bacitracin - 5 mg/g + 250 IU/g) was performed at the end of the surgery, enrofloxacin antibiotic (10% - 5 mg/Kg of animal weight) was then administered for 4 days every 24 hours, and the meloxicam antiinflammatory (0.2% - 0.1 mL/Kg of animal weight) was applied subcutaneously for 2 days every 24 hours. All surgical instruments used in the procedure were previously sterilized.

Macroscopic Analysis of the Surgical Technique and Euthanasia of Animals

The animals had their body weight measured in the 6th postoperative week, and then were anesthetized again with a 0.05 mL and 0.1 mL xylazine (Anasedan) (20 mg.Kg^{-1}) and ketamine hydrochloride solution (Dopalen) (100 mg.Kg^{-1}) for each 100 g of animal weight. The right sciatic nerve was visualized to have an evaluation of the performed surgical technique, and a macroscopic analysis was subsequently performed. The evaluation was performed after the experimental period, according to the questionnaire developed (**► Table 1**). The animals received an intracardiac dosage of 1 mL of potassium chloride (KCl) while still under the effect of anesthetics for their euthanasia.

Statistical Analysis

A database was built in Microsoft Excel, 2016 version, (Microsoft Corp., Redmond, WA, USA) using the obtained data, and later analyzed using the IBM SPSS Statistics software, Version 20.0 (IMB Corp., Armonk, NY, USA). The data were expressed in frequency for the qualitative evaluation obtained through the sciatic nerve macroscopy evaluation questionnaire, and then they were expressed as mean and standard deviation, and the Shapiro-Wilk normality test was performed to evaluate body weight. The analysis of variance (ANOVA) was subsequently used followed by the Bonferroni test, as the data were normal. A significance level of 5% was adopted ($p < 0.05$).

Results

► Table 2 represents the sample characterization before the surgical intervention, in which a similarity was observed between the groups at the beginning of the study.

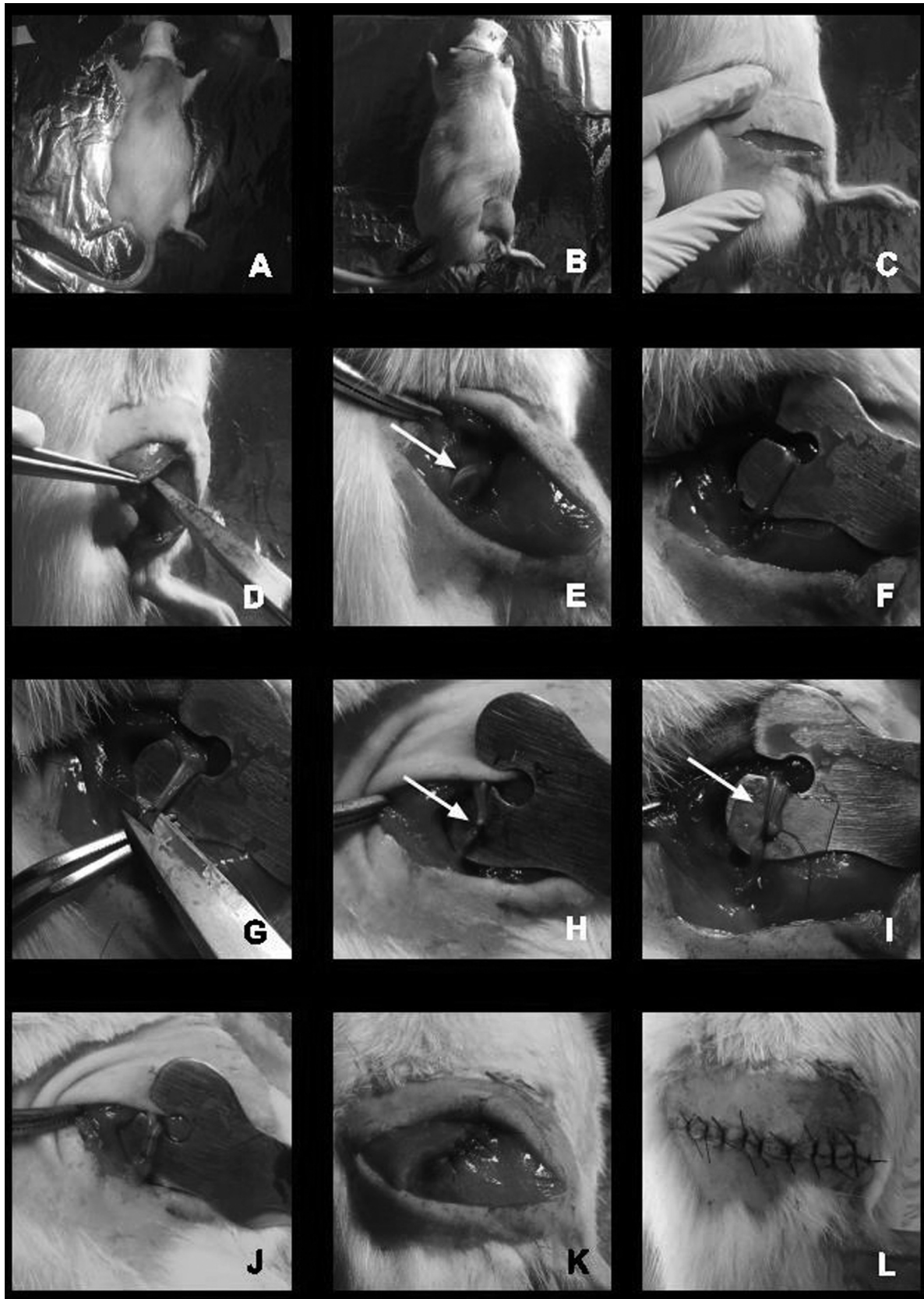


Fig. 1 Surgical procedure: (A) Animal in the anatomical position; (B) trichotomy; (C) skin incision; (D) disjunction of the superficial gluteal muscles and biceps femoris; (E) visualization of the sciatic nerve (arrow); (F) isolation of the nerve; (G) neurotmesis; (H) neurorrhaphy (arrow); (I) biofilm positioned (arrow); (J) biofilm involving the nerve and sutured; (K) muscular suture; (L) skin suture.

Table 1 Questionnaire for macroscopic evaluation of surgical repair

1. Was the skin suture well repaired?	() Yes	() No	() Not applicable
2. Have the skin spots broken?	() Yes	() No	() Not applicable
2.1. If yes, a new suture was performed	() Yes	() No	() Not applicable
3. Was the muscle suture well repaired?	() Yes	() No	() Not applicable
4. Was the suture of the muscle absorbed?	() Yes	() No	() Not applicable
5. Are the stumps aligned structurally?	() Yes	() No	() Not applicable
6. Was the biofilm absorbed?	() Yes	() No	() Not applicable
6.1. If not, was the biofilm in place?	() Yes	() No	() Not applicable
7. Are there neuromas?	() Yes	() No	() Not applicable

Table 2 Characterization of the sample before neurotmesis

	CG (n = 6)	NG (n = 6)	NBG (n = 6)	p
Preoperative weight (g)	267.00 ± 25.13	265.00 ± 12.44	265.00 ± 25.38	0.983

Abbreviations: CG, control group; GN, neurotmesis group; GNB, neurotmesis biofilm group. ANOVA was used, followed by the Bonferroni test. The level of significance was 5%.

Table 3 Frequency of responses to the descriptive evaluation questionnaire 6 weeks after surgical repair of a neurotmesis in Wistar rats

Questions	GC			GN			GNB		
	Y	N	NA	Y	N	NA	Y	N	NA
1. Was the skin suture well repaired?	100%	0%	0%	100%	0%	0%	100%	0%	0%
2. Have the skin spots broken?	33.30%	66.70%	0%	0%	100%	0%	0%	100%	0%
2.1. If yes, a new suture was performed	33.30%	0%	66.70%	0%	0%	100%	0%	0%	100%
3. Was the muscle suture well repaired?	100%	0%	0%	100%	0%	0%	100%	0%	0%
4. Was the suture of the muscle absorbed?	0%	100%	0%	0%	100%	0%	0%	100%	0%
5. Are the stumps aligned structurally?	100%	0%	0%	83.30%	16.70%	0%	100%	0%	0%
6. Was the biofilm absorbed?	0%	0%	100%	0%	0%	100%	0%	100%	0%
6.1. If not, was the biofilm in place?	0%	0%	100%	0%	0%	100%	100%	0%	0%
7. Are these neuromas?	0%	100%	0%	33.30%	66.70%	0%	0%	100%	0%

Abbreviations: CG, control group; GN, neurotmesis group; GNB, neurotmesis biofilm group; N, No; NA, not applicable; Y, yes.

► **Table 3** shows the percentage of responses related to the questionnaire for the descriptive evaluation of surgical repair. The animals of all groups had their skin and muscle sutures well repaired; however, skin stitches were broken in two animals in the CG (33.30%), and a new suture was performed after surgery. There was no absorption of the muscle suture in any of the groups.

Although the biofilm was not absorbed in the NBG, all the stumps were structurally aligned 6 weeks after surgery, and there were no neuromas. However, 16.70% of the animals in the NG had misalignment of the stumps, and 33.30% had neuromas.

Discussion

As neurotmesis is the most severe traumatic injury that can affect the peripheral nervous system and requires surgical

treatment,¹⁴ the present study experimentally evaluated the repair and surgical recovery of a neurotmesis submitted to the application of a PVA biofilm.

The skin suture rupture in two animals in the CG may have been a consequence of the animals moving freely, increasing the tissue reaction induced by the suture itself with softening of the surrounding tissues, delaying the onset of fibroplasia.¹⁵ Despite this, the surgical technique was effective, since perfect asepsis and respect for the force lines of the tissue are necessary in order for the suture to effectively heal with natural approach of the edges and without exaggerated tension; this prevented infection, ischemia, or scarring necrosis,¹⁶ and all animals in the study had good suture repair of both the skin and the muscle.

However, the muscle suture thread was not absorbed in all animals, as nylon monofilament (Somerville) is a non-absorbable synthetic and inorganic thread which loses 30%

of its original tensile strength in 2 years. It was chosen for this for being a non-reactive tissue and for its ability to stretch even with its permanence in the body, reducing the risk of infection and tissue stiffness.¹⁵

Due to the results observed in the structural alignment of the nerve stumps, the biofilms used promoted nerve stability after injury, while there was no alignment in 16.70% of the animals in the NG. This corroborates a recent study which stated that the suture technique by itself does not guarantee mechanical stability, requiring additional strategies for better repair, such as biofilm or those already used in research of suture associated with glue or fibrin conduit.¹⁷

On the other hand, the biofilms were not absorbed after 6 weeks of surgery to repair neurotmesis. This is similar to previous findings with the use of a nervous conduit composed of PVA in the injury of the sciatic nerve, demonstrating the presence of the material 12 weeks after injury, being surrounded by fibrin capsule and connective tissue, the result of its biodegradation.¹⁸

The presence of neuromas in NG is possibly related to a disorganized or incomplete regeneration of a nerve after its injury, due to the deposition of scar tissue by fibroblasts.^{19,20} On the other hand, the absence of this structure in NBG reiterates some of the main benefits of the tubulization technique in nerve repair, which are the proper orientation of the axonal stumps toward the distal stump or target tissues, prevention of neuromas, diffusion of neurotrophic factors released by the damaged nerve, accumulation of extracellular matrix components, and inhibition of fibroblast infiltration, reducing the formation of scar tissue at the injury site.²

Conclusion

The present study was able to establish a surgical protocol for nerve repair of a neurotmesis using the sciatic nerve tubing technique in Wistar rats, using a polyvinyl alcohol conduit and a water-soluble, non-biodegradable polymer as a model. Allied to this, as the structural alignment and the absence of neuroma are parameters considered for faster nerve repair,²¹ it is believed that the tubing technique tested in the present study proved to be effective in the sciatic nerve repair process from a macroscopic point of view.

Therefore, following the guidelines of this protocol, we propose that new studies are carried out to assess the histological and functional repair of the sciatic nerve; these studies should also include a group that has a distance between the stumps in order to evaluate axonal growth within the biofilm.

Ethical Declaration

The procedures used for handling and caring for animals are in accordance with international standards established by the National Institute of Health Guide for Care and Use of Animal, and the project was approved by the Ethics Committee on the Use of Laboratory Animals (CEUA, in the Portuguese acronym) of the Biological

Sciences Center - Universidade Federal de Pernambuco under protocol number 23076.052306/2017-10.

References

- Brunelli GA, Battiston B, Vigasio A, Brunelli G, Marocolo D. Bridging nerve defects with combined skeletal muscle and vein conduits. *Microsurgery* 1993;14(04):247-251
- Adams AM, VanDusen KW, Kostrominova TY, Mertens JP, Larkin LM. Scaffoldless tissue-engineered nerve conduit promotes peripheral nerve regeneration and functional recovery after tibial nerve injury in rats. *Neural Regen Res* 2017;12(09):1529-1537
- Konofaos P, Ver Halen JP. Nerve repair by means of tubulization: past, present, future. *J Reconstr Microsurg* 2013;29(03):149-164
- Moskow J, Ferrigno B, Mistry N, et al. Review: Bioengineering approach for the repair and regeneration of peripheral nerve. *Bioact Mater* 2018;4(01):107-113
- Zhang PX, Han N, Kou YH, et al. Tissue engineering for the repair of peripheral nerve injury. *Neural Regen Res* 2019;14(01):51-58
- Houshyar S, Bhattacharyya A, Shanks R. Peripheral Nerve Conduit: Materials and Structures. *ACS Chem Neurosci* 2019;10(08):3349-3365
- Chen Y, Ed. Chitosan composites nerve conduits. *E3S Web of Conferences*; 2019: EDP Sciences.
- Ronchi G, Nicolino S, Raimondo S, et al. Functional and morphological assessment of a standardized crush injury of the rat median nerve. *J Neurosci Methods* 2009;179(01):51-57
- Braga Silva J, Marchese GM, Cauduro CG, Debiasi M. Nerve conduits for treating peripheral nerve injuries: A systematic literature review. *Hand Surg Rehabil* 2017;36(02):71-85
- Asato F, Butler M, Blomberg H, Gordh T. Variation in rat sciatic nerve anatomy: implications for a rat model of neuropathic pain. *J Peripher Nerv Syst* 2000;5(01):19-21
- Arslantunali D, Dursun T, Yucel D, Hasirci N, Hasirci V. Peripheral nerve conduits: technology update. *Med Devices (Auckl)* 2014;7:405-424
- Weller WJ. Emerging Technologies in Upper Extremity Surgery: Polyvinyl Alcohol Hydrogel Implant for Thumb Carpometacarpal Arthroplasty and Processed Nerve Allograft and Nerve Conduit for Digital Nerve Repairs. *Orthop Clin North Am* 2019;50(01):87-93
- Wu R, Wang L, Chen F, et al. Evaluation of artificial nerve conduit and autografts in peripheral nerve repair in the rat model of sciatic nerve injury. *Neurol Res* 2016;38(05):461-466
- Mohammadi R, Amini K, Charehsaz S. Homeopathic treatment for peripheral nerve regeneration: an experimental study in a rat sciatic nerve transection model. *Homeopathy* 2012;101(03):141-146
- Prado RR, Mendonça EP, Monteiro GP, de Melo RT, Nalevaiko PC, Rossi DAJP. Apostila ilustrada de cirurgia veterinária. 2015:1-110
- Barros M, Gorgal R, Machado AP, Correia A, Montenegro NJAMP. Princípios básicos em cirurgia: fios de sutura. 2011:1051-1056
- Wang W, Degrugillier L, Tremp M, et al. Nerve repair with fibrin nerve conduit and modified suture placement. *Anat Rec (Hoboken)* 2018;301(10):1690-1696
- Marinescu S-A, Zărnescu O, Mihai I-R, Giuglea C, Sinescu RDJRJME. An animal model of peripheral nerve regeneration after the application of a collagen-polyvinyl alcohol scaffold and mesenchymal stem cells. *Rom J Morphol Embryol* 2014;55(03):891-903
- Arnold DMJ, Wilkens SC, Coert JH, Chen NC, Ducic I, Eberlin KR. Diagnostic Criteria for Symptomatic Neuroma. *Ann Plast Surg* 2019;82(04):420-427
- Neumeister MW, Winters JN. Neuroma. *Clin Plast Surg* 2020;47(02):279-283
- de Medinaceli LF. Cell surgery to repair divided nerves: CASIS. 1994