



# Role of Shear-Wave Elastography in Achilles Tendon in Psoriatic Arthritis and Its Correlation with Disease Severity Score, Psoriasis Area and Severity Index

Debajyoti Saha<sup>1</sup> Mahesh Prakash<sup>1</sup> Anindita Sinha<sup>1</sup> Tulika Singh<sup>1</sup> Sunil Dogra<sup>2</sup> Aman Sharma<sup>3</sup>

<sup>1</sup> Department of Radiodiagnosis and Imaging, Postgraduate Institute of Medical Education and Research, Chandigarh, India

<sup>2</sup> Department of Dermatology, Venereology and Leprology, Postgraduate Institute of Medical Education and Research, Chandigarh, India

<sup>3</sup> Division of Clinical Immunology and Rheumatology, Department of Internal Medicine, Postgraduate Institute of Medical Education and Research, Chandigarh, India

Address for correspondence Mahesh Prakash, MD, Department of Radiodiagnosis and Imaging, Postgraduate Institute of Medical Education and Research, Madhya Marg, Sector 12, Chandigarh, India, 160012 (e-mail: image73@gmail.com).

Indian J Radiol Imaging 2022;32:159–165.

## Abstract

**Purpose** The aim of this study was to compare accuracy of shear-wave elastography (SWE) with gray scale (GS) ultrasound and power Doppler (pD) for diagnosing Achilles tendinopathy in psoriatic patients with and without arthritis and correlation with achillodynia and disease severity score, psoriasis area and severity index (PASI).

**Methods** A total of 100 Achilles tendons were evaluated where 56% were cases of psoriatic arthritis with achillodynia; 44% were controls of psoriasis without arthritis in this prospective study. Evaluation was done with GS, pD, SWE at proximal, mid, and distal third of the tendon. Qualitative (color maps) and quantitative data, elastic modulus, kilopascal (kPa), were generated. Pearson's correlation was done to see association between kPa, PASI and clinical symptoms, achillodynia, scored using visual analog scale (VAS).

**Results** Significant negative correlation was seen between duration of arthritis, VAS and PASI with SWE values with  $r = -0.34$ ,  $-0.47$ , and  $-0.41$ , respectively. SWE could identify abnormal tendons in 71/100 (71%) in the overall study, 53/56 (94.6%) in cases, and 18/44 (40.9%) in control. The statistical significance was set at  $p \leq 0.05$ . In comparison, conventional ultrasound, GS, and pD together could identify 13/56 (23.21%) in cases and no abnormal tendon was identified in the control group.

**Conclusion** SWE is a reliable, noninvasive, and valuable tool to detect early tendinopathy and monitor progression of disease.

## Keywords

- ▶ Achilles tendinopathy
- ▶ psoriasis
- ▶ psoriasis area and severity index
- ▶ psoriatic arthritis
- ▶ shear-wave elastography
- ▶ visual analog scale

published online  
July 13, 2022

DOI <https://doi.org/10.1055/s-0042-1743116>.  
ISSN 0971-3026.

© 2022. Indian Radiological Association. All rights reserved.  
This is an open access article published by Thieme under the terms of the Creative Commons Attribution-NonDerivative-NonCommercial-License, permitting copying and reproduction so long as the original work is given appropriate credit. Contents may not be used for commercial purposes, or adapted, remixed, transformed or built upon. (<https://creativecommons.org/licenses/by-nc-nd/4.0/>)  
Thieme Medical and Scientific Publishers Pvt. Ltd., A-12, 2nd Floor, Sector 2, Noida-201301 UP, India

## Introduction

Psoriatic arthritis (PsA) is a form of chronic, inflammatory, seronegative, spondyloarthropathy seen in up to 20% of patients with psoriasis.<sup>1</sup> Peripheral arthritis, spondylitis, enthesitis, and dactylitis are the common manifestations of PsA<sup>2</sup> and achillodynia is frequently associated with it.<sup>3</sup> The psoriasis area and severity index (PASI) is an extensively used scoring system for grading the severity of psoriasis. Patients are stratified based on the score into mild (<7), moderate, (7–15) and severe categories (>15) and the progression of the disease is monitored through it.<sup>4</sup>

Various imaging modalities used for assessment of PsA are plain radiography, gray scale (GS) ultrasound, and magnetic resonance imaging (MRI). Utility of X-ray for early diagnosis of PsA is minimal as soft tissue changes are not identified by it.<sup>5–7</sup> MRI is relatively expensive and time consuming. Conventional ultrasound (GS and power Doppler [pD]) is routinely available, noninvasive, and affordable imaging modality with high patient acceptability. Ultrasound findings suggestive of tendinopathy are thickened tendon, hypoechoic echotexture, and increased signal on pD.<sup>8–10</sup> But studies have shown that the above-mentioned abnormalities are not characteristic for tendinopathy.<sup>11,12</sup> Moreover, the usefulness of conventional ultrasound is limited as they lack sensitivity in diagnosing tendinopathy.<sup>13,18</sup>

Many studies have shown a significant proportion of patients having subclinical enthesitis in patients with psoriasis without arthritis.<sup>3,19–21</sup> Prompt diagnosis is important to prevent progression of the disease to irreversible structural damage and tendon rupture.<sup>22</sup> It is important to identify enthesitis that is a marker for early disease to start timely treatment.<sup>5</sup> Hence, there is importance of early diagnosis as well as objective assessment of measuring the disease progression and treatment response. This has led to a need for tools that allow earlier diagnosis of PsA and for identification of progressive structural damage in tendons.

Shear-wave elastography (SWE) is a new technique that provides information on the elastic properties of tissues. It generates the quantitative data in kilopascals (kPa) by measuring the propagation velocity distribution of shear waves in tissues produced by a focused acoustic push pulse.<sup>23–25</sup> It also provides qualitative data as color-coded images. These images are superimposed on a GS ultrasound image. Harder tissues appear as red or yellow and softer tissues appear blue or green. The efficacy of SWE has already been demonstrated by multiple studies in liver, breast, prostate, and thyroid.<sup>26–32</sup> Tendinopathy is demonstrated by decreased tendon stiffness (kPa) in SWE.<sup>13,33–36</sup> Studies have shown SWE to be a valuable tool for diagnosing and monitoring tendinopathy.<sup>33,37</sup> Hence, the aim of the study was to establish the role of SWE in patients with PsA. It was proposed to compare the accuracy of SWE with conventional ultrasound (GS and pD) for diagnosing Achilles tendinopathy in patients with psoriasis with and without arthritis and correlate the findings with clinical symptoms (achillodynia) and disease severity score (PASI) in patients with psoriasis.

## Materials and Methods

This was a prospective, observational study done in the Department of Radio Diagnosis and Imaging, Postgraduate Institute of Medical Education and Research between August 2014 and November 2015. The ethical committee of the institute approved this study. Written informed consent was taken from all the participants.

### Inclusion Criteria

Patients diagnosed to have PsA according to classification criteria for psoriatic arthritis<sup>38</sup> and presenting with achillodynia, regardless whether symptoms were unilateral or bilateral, were included in the study as cases.

### Exclusion Criteria

Patients with a history of metabolic disease, endocrine disease, and sports-related injury or trauma were excluded from the study.

A standardized questionnaire was used on which demographic data and detailed history of the disease characteristic of the study subjects were recorded. The study population consisted of 50 patients. Among them, 28 were suffering from PsA and 22 were having psoriasis without arthritis. Achilles tendon of both sides was examined regardless of the symptoms. Hence, we examined 56 Achilles tendons in patients with PsA, which were cases, and 44 Achilles tendons with psoriasis without arthritis were controls. An experienced rheumatologist and dermatologist performed the clinical examination and established the diagnosis. Visual analog scale (VAS) was used to score clinical symptoms, achillodynia. The scale ranges from 0 to 10, where 10 implies maximum pain and 0 implies no pain. The severity of the disease was assessed for all the patients using PASI score.

Multimodal ultrasound was done on all the participants bilaterally that included high-resolution GS ultrasound, pD, and SWE. Care was taken to conduct the study in each participant in the same order with the same standardized settings and parameters on a Supersonic Imagine's Aixplorer ultrasound machine, which was equipped with a linear array probe SL14–5 probe (5–14 MHz). Every patient followed a standardized positioning protocol. The tendon was kept in a relaxed state with the patient in prone posture and the foot hanging freely beyond the examination table. A single operator performed all the scans to remove interobserver variability.

Multimodal ultrasound of Achilles tendon was done in the longitudinal plane from the origin at the musculotendinous junction to its point of insertion at the calcaneus. Achilles tendon was evaluated at the level of the medial malleolus for the distal third, at the level of mid-calf for the middle third, and at the musculotendinous junction for the proximal third and three representative images were taken. The criteria for normal tendon thickness were taken according to a study done by Aydin et al.<sup>39</sup> The cutoff values were 3.7 mm for females and 4.8 mm for males. The abnormal GS ultrasound findings included thickened tendon and hypoechoic echotexture. Next pD of the whole tendon was performed. Any

neovascularization was considered abnormal. The results of both GS ultrasound and pD were dichotomized into normal or abnormal.

In the same sitting, SWE was performed on the three representative images at the proximal, middle, and distal thirds of the Achilles tendon. Dual screen was used to generate elastograms showing GS ultrasound image with an overlying elastogram. For recording, the SWE data a standard region of interest (ROI) with a diameter of 1 mm was taken. We had taken proper precaution to place the ROI in the tendon and avoid surrounding soft tissue to avoid minimizing errors in the kPa values. Both qualitative (color maps) and quantitative data (measured in kPa) were recorded. The color maps were coded from blue for components with least strain (i.e., softest) to red for those with greatest strain (i.e., hardest). The criteria for normal SWE values in Achilles tendon were taken by following two previous multicenter studies.<sup>40,41</sup> These studies calculated the mean elasticity of normal Achilles tendon to be >300kPa.

### Statistical Analysis

The statistical analysis was performed using Statistical Package for Social Sciences (SPSS Inc., Chicago, Illinois, United States, version 16.0 for Windows). All the quantitative variables were calculated using mean and measures of dispersion (standard deviation and standard error). For comparing the categorical and continuous variables in the demographic and clinical data of the study groups, chi-squared test and Mann-Whitney U test, respectively, were

used. Covariance analysis was done to look for any confounding effect of age or gender. Pearson's correlation was used to look for any association between duration of arthritis, VAS, PASI with quantitative SWE values. Log regression analysis was done to see for any correlation between VAS and qualitative SWE data (color). The statistical significance was set at  $p \leq 0.05$ .

### Result

The study population consisted of 50 subjects (mean age:  $38.3 \pm 19.1$  years). Among them, 28 (mean age:  $40.6 \pm 9.7$  years) patients were suffering from PsA and 22 (mean age:  $38.2 \pm 12.2$  years) patients were having psoriasis without arthritis. Hence, a total of 100 Achilles tendons were evaluated that fulfilled the inclusion criteria. Of these 56 (56%) were patients with PsA presenting with achillodynia, which were taken as cases, and 44 (44%) patients with psoriasis without arthritis were control. The mean score value of the pain in the leg and heel perceived by patients on a VAS was  $3.5 \pm 1.7$ . The mean score value of PASI in the study population, cases and control, was  $4.5 \pm 3.4$ ,  $5.2 \pm 3.7$  and  $3.7 \pm 2.8$ , respectively.

Demographic details of patients and clinical symptoms are given in ►Table 1. No statistically significant difference was seen in the demographic data in between the groups.

Multimodal ultrasound (GS, pD, SWE) was done in all the patients and results are shown in ►Table 2 and images are shown in ►Fig. 1A–F. The number of abnormal tendons

**Table 1** Demographic data, history, and clinical symptoms

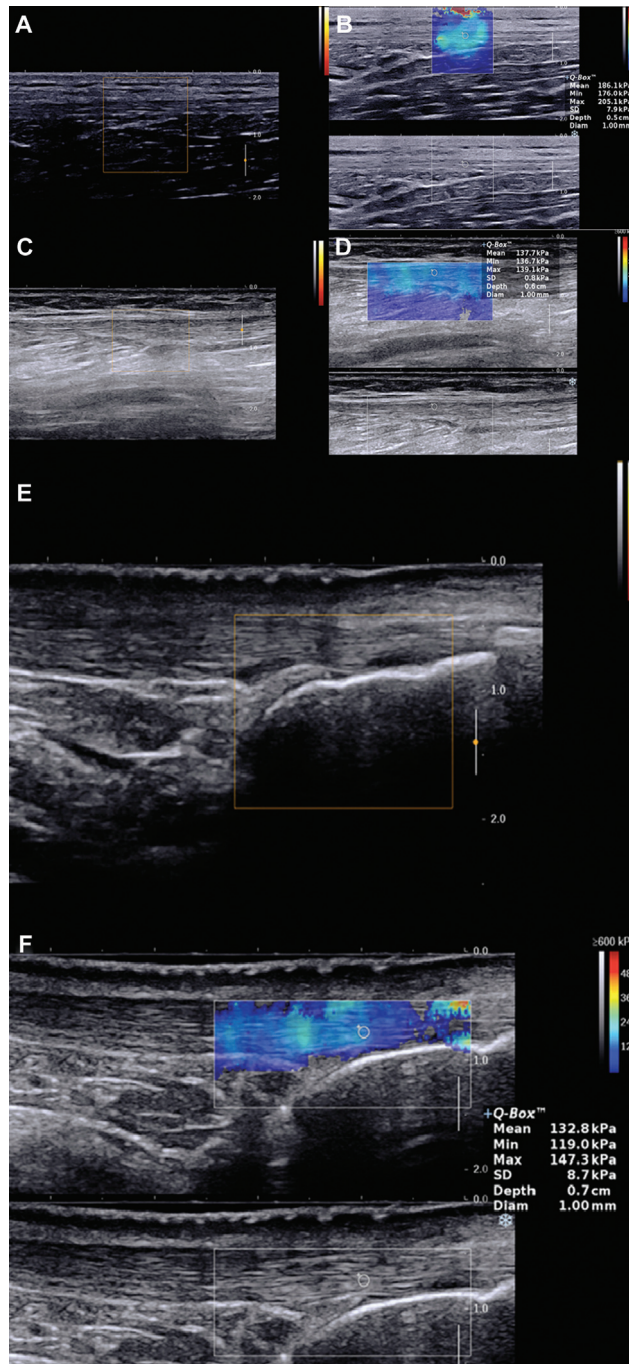
	All (n = 100)	Cases (n = 56)	Control (n = 44)
Mean age (years)	$38.3 \pm 19.1$	$40.6 \pm 9.7$	$38.2 \pm 12.2$
Men	58 (58%)	24 (42.86%)	34 (77.27%)
Women	42 (42%)	32 (57.14%)	10 (22.72%)
Duration of psoriasis (years)	$8.5 \pm 6.6$	$7.3 \pm 4.7$	$9.9 \pm 8.3$
Duration of treatment (years)	$4.5 \pm 5.8$	$4.0 \pm 3.4$	$5.2 \pm 7.9$
Duration of arthritis (years)	–	$2.5 \pm 2.5$	–
Mean of VAS (Achillodynia)	–	$3.5 \pm 1.7$	–
PASI	$4.5 \pm 3.4$	$5.2 \pm 3.7$	$3.7 \pm 2.8$

Abbreviations: PASI, psoriasis area and severity index; VAS, visual analog scale.

**Table 2** Measurement of tendon thickness and SWE values

	Whole tendon		Proximal third		Middle third		Distal third	
	Cases	Control	Cases	Control	Cases	Control	Cases	Control
Mean thickness (mm)	$2.4 \pm 0.6$	$2.5 \pm 0.5$	$1.7 \pm 0.8$	$1.6 \pm 0.4$	$2.3 \pm 0.8$	$2.5 \pm 0.8$	$3.1 \pm 0.8$	$3.4 \pm 0.5$
Mean SWE (kPa)	$265.8 \pm 90.6$	$413.6 \pm 136.2$	$202.2 \pm 87.3$	$367.5 \pm 172$	$285.4 \pm 143.8$	$438.3 \pm 178.8$	$310.0 \pm 175.8$	$434.9 \pm 166.7$
Difference in SWE values between cases and control	150.1kPa		171.2kPa		145.8kPa		133.2kPa	

Abbreviations: kPa, kilopascal; mm, millimeter; SWE, shear-wave elastography.



**Fig. 1** Sagittal gray scale (GS) ultrasound, power Doppler (pD), and shear-wave elastography (SWE) images of the Achilles tendon in patients with psoriatic arthritis (PsA). Dual-screen was used showing GS ultrasound image with an overlying elastogram. Images of the proximal third part of the Achilles tendon; (A) pD image showing no color flow; (B) dual-screen SWE image showing color elastogram with circle representing the region of interest (ROI) where elastic modulus kilopascal (kPa) was measured with mean elastic modulus measuring 186.1kPa. Images of the middle third part of the Achilles tendon; (C) pD image showing no color flow; (D) dual-screen SWE image showing color elastogram with circle ROI where elastic modulus kPa was measured with mean elastic modulus measuring 137.7kPa. Images of the distal third part of the Achilles tendon; (E) pD image showing no color flow; (F) dual-screen SWE image showing color elastogram with circle representing the ROI where elastic modulus kPa was measured with mean elastic modulus measuring 132.8kPa. Color ranges from blue (softer) to red (stiffer).

**Table 3** Results of multimodal ultrasound (abnormal tendons identified)

	All (n = 100)	Cases (n = 56)	Control (n = 44)
GS	12 (12%)	12 (21.43%)	0
pD	2 (2%)	2 (3.57%)	0
GS + pD	13 (13%)	13 (23.21%)	0
SWE value (kPa)	71 (71%)	53 (94.6%)	18 (40.9%)

Abbreviations: GS, gray scale; kPa, kilopascal; pD, power Doppler; SWE, shear-wave elastography.

identified by multimodal ultrasound was shown in **Table 3**. Ultrasound was also performed in few healthy volunteers for reference (**Fig. 2A, B**) but was not included in the data analysis.

#### Association between SWE Values and Duration of Arthritis

There was negative correlation seen between duration of arthritis and SWE values with  $r$ -value for proximal, middle, and distal third part of the Achilles tendon being  $-0.34$  ( $p < 0.001$ ),  $-0.28$  ( $p < 0.001$ ), and  $-0.26$  ( $p < 0.001$ ), respectively.

#### Association between SWE and Clinical Symptom (VAS)

There was negative correlation seen between VAS and SWE values with  $r$ -value for proximal, middle, and distal third part of the Achilles tendon being  $-0.47$  ( $p < 0.001$ ),  $-0.38$  ( $p < 0.001$ ), and  $-0.35$  ( $p < 0.001$ ) (**Fig. 3**), respectively. Log regression analysis between VAS and qualitative SWE data (color) was showing significant correlation with a  $R^2$  value 6.8 ( $p < 0.001$ ).

#### Association between SWE Values and Severity Score (PASI)

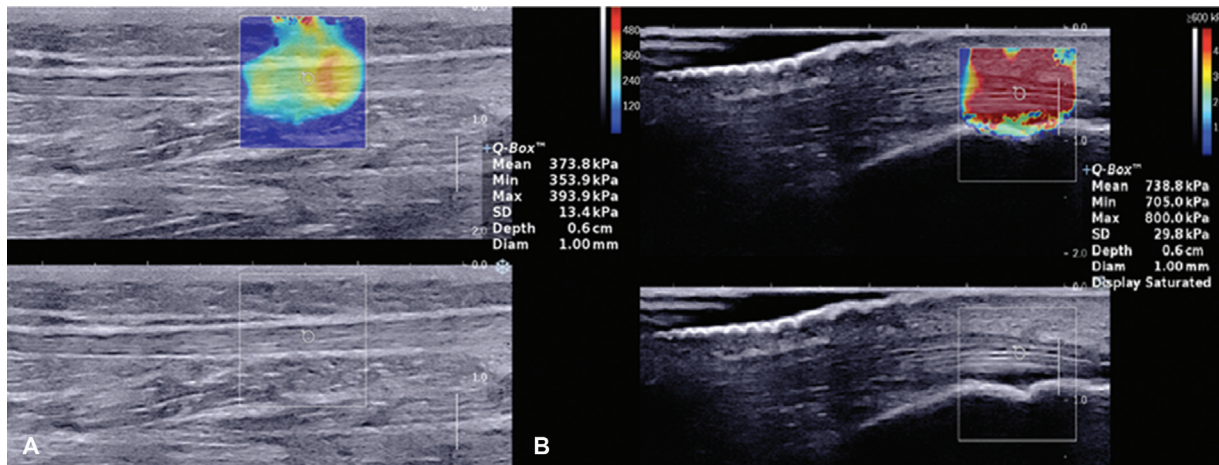
There was a significant negative correlation seen between PASI and mean elastic modulus and elastic modulus of distal third part of the Achilles tendon in cases with  $r$ -values being  $-0.29$  ( $p < 0.05$ ) and  $-0.41$  ( $p < 0.001$ ), respectively (**Fig. 4**). Overall when the entire cohort was taken into consideration, there was a significant negative correlation between PASI and elasticity modulus of the distal third part of the Achilles tendon with  $r=0.27$  ( $p < 0.05$ ), (**Fig. 5**).

## Discussion

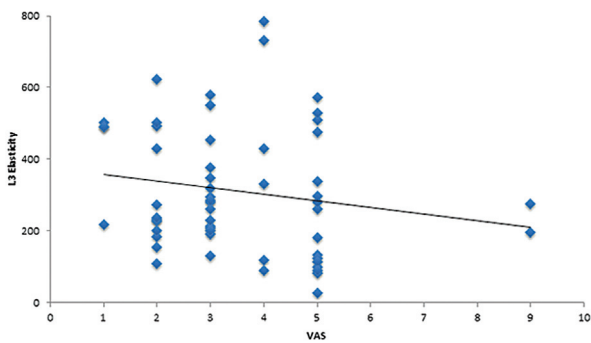
In this study, we evaluated the efficacy of SWE for the assessment of morphologic and elastic alterations in Achilles tendons in patients with psoriasis with and without arthritis. This study provides evidence that SWE can be a dependable tool to detect and quantify the degree of tendinopathies.

This study showed a significant negative correlation between duration of arthritis, VAS and PASI with elastic

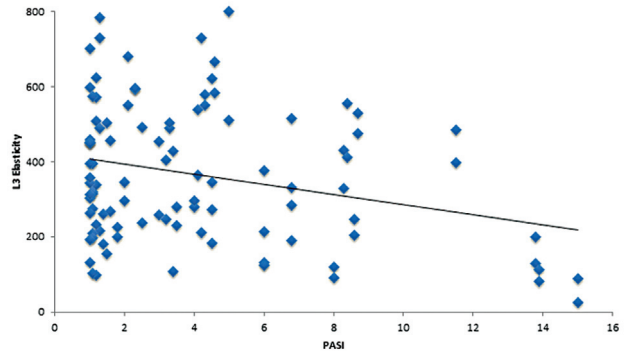




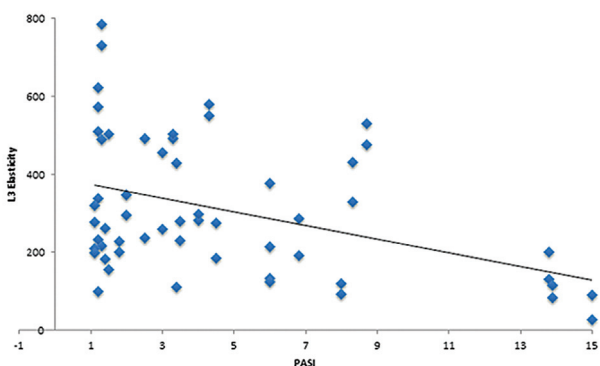
**Fig. 2** Sagittal gray scale (GS) ultrasound and shear-wave elastography (SWE) images of the Achilles tendon in a healthy volunteer. Dual-screen was used showing GS ultrasound image with an overlying elastogram. Images of middle third part of the Achilles tendon, (A) dual-screen SWE image showing color elastogram with circle representing the region of interest (ROI) where elastic modulus kilopascal (kPa) was measured with mean elastic modulus measuring 373.8kPa. Images of distal third part of the Achilles tendon, (B) dual-screen SWE image showing color elastogram with circle representing the ROI where elastic modulus kPa was measured with mean elastic modulus measuring 738.8kPa. Color ranges from blue (softer) to red (stiffer).



**Fig. 3** Relationship between clinical symptom, visual analog scale (VAS) and elastic modulus, kilopascal (kPa) values of distal third part of Achilles tendon (L3) in patients with psoriatic arthritis. Pearson's correlation:  $r = -0.35$ ;  $p < 0.001$ , suggesting a significant negative correlation.



**Fig. 5** Relationship between disease severity score, psoriasis area and severity index (PASI) and elastic modulus, kilopascal (kPa) values of distal third part of Achilles tendon (L3) in the entire cohort. Pearson's correlation:  $r = -0.27$ ;  $p < 0.05$ , suggesting a significant negative correlation.



**Fig. 4** Relationship between disease severity score, psoriasis area and severity index (PASI), and elastic modulus, kilopascal (kPa) values of distal third part of Achilles tendon (L3) in patients with psoriatic arthritis. Pearson's correlation:  $r = -0.41$ ;  $p < 0.001$ , suggesting a significant negative correlation.

modulus. Hence, we can propose that as the severity of the PASI scores increases, there was a decrease in elastic modulus indicating softening of tendons. Similarly, as the duration of arthritis was increasing in patients with PsA, there was a decrease in elastic modulus. With severe clinical symptoms, VAS, there was a decrease in elastic modulus. In the study done by Dirrichs et al,<sup>33</sup> they also found similar findings with SWE improving the diagnostic accuracy and helped monitor treatment. The changes in the elastic modulus in abnormal tendons were due to the microscopic alterations in the tendon due to the disruption of the collagen fibers, fluid accumulation between fibers, and proliferation of noncollagenous matrices.<sup>42,43</sup> To our knowledge, there have been no reported studies in literature, comparing SWE and PASI.

The lesser number of abnormalities identified by GS ultrasound and pD might be due to the fact that most of the patients included in the study were having chronic

disease and were on treatment. Hence, they would have reduced inflammation, which in turn generates lesser pD signal. This effect was also demonstrated by other studies.<sup>44,45</sup> Although tendon abnormalities in patients with PsA can be identified with GS ultrasound, this method alone is not reliable to detect subclinical alterations. Loss of fiber integrity may be depicted well with SWE with greater sensitivity than GS ultrasound. This inability to detect tendinopathy in a significant number of cases can be overcome by the use of SWE. SWE can also rate the degree of tendon impairment by their quantitative values, which was also substantiated in previous study.<sup>33</sup>

Hence, from the above discussion we could say that SWE was successful in identifying more abnormal tendons in patients with PsA as compared with GS ultrasound. In addition, some subclinical elastic alterations in the form of softened Achilles tendon in psoriasis patients without arthritis were also identified in the control. This suggests that subclinical elastic alterations may be far more common than earlier thought. These alterations were unidentifiable by GS ultrasound or pD. The findings were similar to the study done by Dirrichs et al.<sup>33</sup> Hence, we could propose that changes in the elastic properties occur early in the inflammatory process of the tendon, which is unidentifiable by routine GS ultrasound but identified only by SWE. The clinical significance of it is abundant as in equivocal cases if not identified early, degenerative changes in collagen structure, which soften and weaken the tendon, can eventually lead to tear or spontaneous rupture of the tendon. Moreover, by using SWE, tendon structure and integrity can be assessed that are actually clinically significant and help monitor progression or regression of the disease. This can help us in better appreciation of the disease process and aid us in staging the altered elastic properties of the tendon.

The limitation of our study was that no histopathological correlation or MRI was done to confirm the SWE detected lesions. However, histological correlation with elastography was previously evaluated in a study done by Klauser et al.<sup>10</sup> Second, we could not assess the intraobserver variability. However, they have already been evaluated in earlier studies.<sup>46,47</sup> Third, the operator was not blinded to the clinical symptoms of the patient.

In conclusion, SWE can be a novel biomarker in assessing Achilles tendinopathy in patients with psoriasis. Our study has shown that SWE can better diagnose tendinopathy compared with conventional ultrasound. Early identification of the abnormality can prevent the progression of the disease and morbidity to the patient in the form of tendon rupture. Further studies should be done to evaluate the significance of altered elastic modulus in Achilles tendon in patients of psoriasis without arthritis with a prospective study in a large study population. Further evaluation should be done whether treatment should be changed on encountering altered elastic modulus in the Achilles tendon and whether the patients benefited from the changed treatment. We hope that our findings will lead to further research in PsA using SWE.

#### Funding Sources

This research did not receive any specific grant from funding agencies in the public, commercial, or not-for-profit sectors.

#### Conflict of Interest Statement

None of the authors have any conflict of interest to declare.

#### References

- Coates LC, Helliwell PS. Psoriatic arthritis: state of the art review. *Clin Med (Lond)* 2017;17(01):65–70
- Veale DJ, Fearon U. What makes psoriatic and rheumatoid arthritis so different? *RMD Open* 2015;1(01):e000025
- De Simone C, Guerriero C, Giampetruzzi AR, Costantini M, Di Gregorio F, Amerio P. Achilles tendinitis in psoriasis: clinical and sonographic findings. *J Am Acad Dermatol* 2003;49(02):217–222
- Llamas-Velasco M, de la Cueva P, Notario J, Martínez-Pilar L, Martorell A, Moreno-Ramírez D. Moderate psoriasis: a proposed definition. *Actas Dermosifiliogr* 2017;108(10):911–917
- Ran J, Morelli JN, Xie R, et al. Role for imaging in spondyloarthritis. *Q J Nucl Med Mol Imaging* 2017;61(03):271–282
- Kaeley GS, Eder L, Aydin SZ, Gutierrez M, Bakewell C. Enthesitis: a hallmark of psoriatic arthritis. *Semin Arthritis Rheum* 2018;48(01):35–43
- McGonagle D. Imaging the joint and enthesis: insights into pathogenesis of psoriatic arthritis. *Ann Rheum Dis* 2005;64(Suppl 2):ii58–ii60
- Davies SG, Baudouin CJ, King JB, Perry JD. Ultrasound, computed tomography and magnetic resonance imaging in patellar tendinitis. *Clin Radiol* 1991;43(01):52–56
- Weinberg EP, Adams MJ, Hollenberg GM. Color Doppler sonography of patellar tendinosis. *AJR Am J Roentgenol* 1998;171(03):743–744
- de Jonge S, van den Berg C, de Vos RJ, et al. Incidence of midportion Achilles tendinopathy in the general population. *Br J Sports Med* 2011;45(13):1026–1028
- McAuliffe S, McCreesh K, Culloty F, Purtill H, O'Sullivan K. Can ultrasound imaging predict the development of Achilles and patellar tendinopathy? A systematic review and meta-analysis. *Br J Sports Med* 2016;50(24):1516–1523
- Docking SI, Ooi CC, Connell D. Tendinopathy: is imaging telling us the entire story? *J Orthop Sports Phys Ther* 2015;45(11):842–852
- Klauser AS, Miyamoto H, Tamegger M, et al. Achilles tendon assessed with sonoelastography: histologic agreement. *Radiology* 2013;267(03):837–842
- Lehtinen A, Peltokallio P, Taavitsainen M. Sonography of Achilles tendon correlated to operative findings. *Ann Chir Gynaecol* 1994;83(04):322–327
- Khan KM, Forster BB, Robinson J, et al. Are ultrasound and magnetic resonance imaging of value in assessment of Achilles tendon disorders? A two year prospective study. *Br J Sports Med* 2003;37(02):149–153
- Paavola M, Paakkala T, Kannus P, Järvinen M. Ultrasonography in the differential diagnosis of Achilles tendon injuries and related disorders. A comparison between pre-operative ultrasonography and surgical findings. *Acta Radiol* 1998;39(06):612–619
- Kayser R, Mahlfeld K, Heyde CE. Partial rupture of the proximal Achilles tendon: a differential diagnostic problem in ultrasound imaging. *Br J Sports Med* 2005;39(11):838–842, discussion 838–842
- Visnes H, Tegnander A, Bahr R. Ultrasound characteristics of the patellar and quadriceps tendons among young elite athletes. *Scand J Med Sci Sports* 2015;25(02):205–215
- Gisoni P, Tinazzi I, El-Dalati G, et al. Lower limb enthesopathy in patients with psoriasis without clinical signs of arthropathy: a

- hospital-based case-control study. *Ann Rheum Dis* 2008;67(01):26–30
- 20 De Filippis LG, Caliri A, Lo Gullo R, et al. Ultrasonography in the early diagnosis of psoriasis-associated enthesopathy. *Int J Tissue React* 2005;27(04):159–162
  - 21 Ozçakar L, Cetin A, Inanici F, Kaymak B, Gürer CK, Kölemen F. Ultrasonographical evaluation of the Achilles' tendon in psoriasis patients. *Int J Dermatol* 2005;44(11):930–932
  - 22 Haroon M, Gallagher P, FitzGerald O. Diagnostic delay of more than 6 months contributes to poor radiographic and functional outcome in psoriatic arthritis. *Ann Rheum Dis* 2015;74(06):1045–1050
  - 23 Li Y, Snedeker JG. Elastography: modality-specific approaches, clinical applications, and research horizons. *Skeletal Radiol* 2011;40(04):389–397
  - 24 Garra BS. Imaging and estimation of tissue elasticity by ultrasound. *Ultrasound Q* 2007;23(04):255–268
  - 25 Gennisson J-L, Deffieux T, Fink M, Tanter M. Ultrasound elastography: principles and techniques. *Diagn Interv Imaging* 2013;94(05):487–495
  - 26 Ragazzoni F, Deandrea M, Mormile A, et al. High diagnostic accuracy and interobserver reliability of real-time elastography in the evaluation of thyroid nodules. *Ultrasound Med Biol* 2012;38(07):1154–1162
  - 27 Berg WA, Mendelson EB, Cosgrove DO, et al. Quantitative maximum shear-wave stiffness of breast masses as a predictor of histopathologic severity. *AJR Am J Roentgenol* 2015;205(02):448–455
  - 28 Feldmann A, Langlois C, Dewailly M, et al. Shear wave elastography (SWE): an analysis of breast lesion characterization in 83 breast lesions. *Ultrasound Med Biol* 2015;41(10):2594–2604
  - 29 Correas J-M, Tissier A-M, Khairoune A, et al. Prostate cancer: diagnostic performance of real-time shear-wave elastography. *Radiology* 2015;275(01):280–289
  - 30 Athanasiou A, Tardivon A, Tanter M, et al. Breast lesions: quantitative elastography with supersonic shear imaging—preliminary results. *Radiology* 2010;256(01):297–303
  - 31 Tanter M, Bercoff J, Athanasiou A, et al. Quantitative assessment of breast lesion viscoelasticity: initial clinical results using supersonic shear imaging. *Ultrasound Med Biol* 2008;34(09):1373–1386
  - 32 Boehm K, Budäus L, Tennstedt P, et al. Prediction of significant prostate cancer at prostate biopsy and per core detection rate of targeted and systematic biopsies using real-time shear wave elastography. *Urol Int* 2015;95(02):189–196
  - 33 Dirrachs T, Quack V, Gatz M, Tingart M, Kuhl CK, Schradling S. Shear wave elastography (SWE) for the evaluation of patients with tendinopathies. *Acad Radiol* 2016;23(10):1204–1213
  - 34 De Zordo T, Fink C, Feuchtner GM, Smekal V, Reindl M, Klauser AS. Real-time sonoelastography findings in healthy Achilles tendons. *AJR Am J Roentgenol* 2009;193(02):W134–8
  - 35 Aubry S, Nueffer J-P, Tanter M, Becce F, Vidal C, Michel F. Viscoelasticity in Achilles tendinopathy: quantitative assessment by using real-time shear-wave elastography. *Radiology* 2015;274(03):821–829
  - 36 De Zordo T, Chhem R, Smekal V, et al. Real-time sonoelastography: findings in patients with symptomatic Achilles tendons and comparison to healthy volunteers. *Ultraschall Med* 2010;31(04):394–400
  - 37 Gatz M, Schradling S, Dirrachs T, et al. Topical polidocanol application in combination with static stretching in tendinopathies: a prospective pilot study. *Muscles Ligaments Tendons J* 2017;7(01):88–97
  - 38 Congi L, Roussou E. Clinical application of the CASPAR criteria for psoriatic arthritis compared to other existing criteria. *Clin Exp Rheumatol* 2010;28(03):304–310
  - 39 Aydin SZ, Filippucci E, Atagündüz P, Yavuz Ş, Grassi W, Direskeneli H. Sonographic measurement of Achilles tendon thickness in seronegative spondyloarthropathies. *Eur J Rheumatol* 2014;1(01):7–10
  - 40 Chen X-M, Cui L-G, He P, Shen W-W, Qian Y-J, Wang J-R. Shear wave elastographic characterization of normal and torn Achilles tendons: a pilot study. *J Ultrasound Med* 2013;32(03):449–455
  - 41 Cao W, Sun Y, Liu L, et al. A multicenter large-sample shear wave ultrasound elastographic study of the Achilles tendon in Chinese adults. *J Ultrasound Med* 2019;38(05):1191–1200
  - 42 Attia M, Scott A, Carpentier G, et al. Greater glycosaminoglycan content in human patellar tendon biopsies is associated with more pain and a lower VISA score. *Br J Sports Med* 2014;48(06):469–475
  - 43 Yoon JH, Halper J. Tendon proteoglycans: biochemistry and function. *J Musculoskelet Neuronal Interact* 2005;5(01):22–34
  - 44 Tom S, Zhong Y, Cook R, Aydin SZ, Kaeley G, Eder L. Development of a preliminary ultrasonographic enthesitis score in psoriatic arthritis - GRAPPA ultrasound working group. *J Rheumatol* 2019;46(04):384–390
  - 45 Backhaus M, Ohrndorf S, Kellner H, et al. Evaluation of a novel 7-joint ultrasound score in daily rheumatologic practice: a pilot project. *Arthritis Rheum* 2009;61(09):1194–1201
  - 46 Alp NB, Akdağ G, Kaleli T, Macunluoğlu AC, Uzunlulu N. Evaluation of patellar tendon with shear wave elastography after anterior cruciate ligament reconstruction using hamstring tendons. *Jt Dis Relat Surg* 2020;31(01):137–142
  - 47 Peltz CD, Haladik JA, Divine G, Siegal D, van Holsbeeck M, Bey MJ. ShearWave elastography: repeatability for measurement of tendon stiffness. *Skeletal Radiol* 2013;42(08):1151–1156