



# Cholangioscopy: Has It Changed Management?

Sudipta Dhar Chowdhury<sup>1</sup> Rajeeb Jaleel<sup>1</sup>

<sup>1</sup>Department of Gastroenterology, Christian Medical College, Vellore, India

Address for correspondence Sudipta Dhar Chowdhury, MD, DM, Department of Gastroenterology, Christian Medical College, Vellore 632004, India (e-mail: sudiptadharchowdhury@gmail.com).

J Digest Endosc 2022;13:8–13.

## Abstract

The single operator per oral cholangioscope is a catheter-based system that allows for direct visualization of the bile duct and pancreatic duct. The instrument with its improved imaging technique and larger accessory channel allows for high-quality image acquisition and performance of therapeutic and diagnostic procedures within the bile duct and pancreatic duct. There has been an increase in the range of indications for the use of the cholangioscope. The current indications include management of difficult biliary stones, pancreatic calculi, assessment of indeterminate biliary stricture, pancreatic stricture, intra-ductal papillary mucinous neoplasms, and extractions of proximally migrated stents. The use of laser lithotripsy and electro-hydraulic lithotripsy has improved the management of difficult bile duct stones. Direct visualization of biliary and pancreatic duct strictures is helpful in the diagnosis of indeterminate strictures. In this review, we explore how cholangioscopy has changed management.

## Keywords

- ▶ bile duct
- ▶ biliary stricture
- ▶ cholangioscopy
- ▶ choledocholithiasis
- ▶ pancreatoscopy
- ▶ spyglass

## Introduction

Direct visualization of the biliary tree has been an area of active interest over the past century. Almost 100 years ago, J. Bakes, a Czechoslovakian surgeon described the use of a modified ear speculum with a light source and mirror for examination of the bile duct at surgery.<sup>1</sup> However, it was only after McIver developed a rigid right-angled choledochoscope that choledoscopy gained popularity.<sup>2</sup> A flexible choledochoscope with a channel for irrigation and instrumentation was introduced by Shore et al.<sup>3</sup> The improvement in instrumentation allowed for the use of cholangioscope per-cutaneously. However, it was only after the advent of the mother–baby scope in 1976 that cholangioscopy became an important part of an endoscopist's therapeutic armamentarium.<sup>4</sup> The mother–baby system consisted of a duodenoscope (the mother) through which a flexible cholangioscope (the baby) could be inserted. The mother–baby cholangioscope went out of favor as the system was fragile, had limited

steerability, and the procedure required two endoscopists. With the development of the single operator per-oral cholangioscopy system, (SpyGlass, Boston Scientific, Marlborough, MA, USA) cholangioscopy has regained popularity amongst the endoscopists and the areas of its use are gradually increasing.

## Single Operator per Oral Cholangioscope: (SpyGlass, Boston Scientific)

This is a catheter-based system that can be operated by a single operator and allows direct visualization of the biliary system and the pancreatic ducts. The first-generation catheter-based single operator per oral cholangioscope the SpyGlass Direct Visualization system also known as the SpyGlass Legacy system was launched in 2007. The first generation SpyGlass cholangioscope was a very popular device and brought cholangioscopy to the main stream. However, it had a few limitations viz. the image quality was sub-optimal,

DOI <https://doi.org/10.1055/s-0042-1743183>.  
ISSN 0976-5042.

© 2022. Society of Gastrointestinal Endoscopy of India. All rights reserved.

This is an open access article published by Thieme under the terms of the Creative Commons Attribution-NonDerivative-NonCommercial-License, permitting copying and reproduction so long as the original work is given appropriate credit. Contents may not be used for commercial purposes, or adapted, remixed, transformed or built upon. (<https://creativecommons.org/licenses/by-nc-nd/4.0/>)

Thieme Medical and Scientific Publishers Pvt. Ltd., A-12, 2nd Floor, Sector 2, Noida-201301 UP, India

**Table 1** Single operator per oral cholangioscope systems (SpyGlassDirect Visualization System and SpyGlass DS system)

Model	Usage	Catheter diameter (mm)	Accessory Channel diameter (mm)	Tip angulation	Scope length (mm)	Image	Field of view (degree)
Spy GlassDirect Visualization System	Cholangioscope Catheter: single use Optical probe: reusable	3.4	1.2	30°/30°/30°/30°	2,300	Fiber optic	70
Spy Glass DS System	Cholangioscope : single use	3.56	1.2	60°/60°/60°/60°	2,140	Digital	120

the field of view was limited, and it required a complicated setup. In 2015, the SpyGlass DS system was launched. The SpyGlass DS has a simplified “plug and play” setup. It has two parts: a processor (SpyGlass DS digital controller) and a disposable cholangioscope (Spy Scope DS catheter). The processor can be fitted on any standard endoscopy cart and has automatic white balance and focus. The Spy Scope DS catheter includes the handle, a connection cable for attaching the cholangioscope to the processor, and an insertion tube. The instrument is set up by attaching the connection cable to the processor. The catheter handle is then attached to a standard duodenoscope and the insertion tube advanced through the working channel of the duodenoscope. The insertion tube includes one accessory channel (1.2 mm), two irrigation channels, and two optical fibers to transmit light from the processor for illumination. The catheter is fitted with a digital camera at the tip, which provides a four times higher resolution and a 60% wider field of view than the first generation SpyGlass System (► **Table 1**). In 2018, the third-generation Spy ScopeDS II catheter was launched. In this system, the image resolution was improved further by incorporating a new CMOS chip and adjusted lighting, which reduces light flare and provides better down lumen visibility.

Cholangioscopy is performed with the duodenoscope positioned at the papilla, the cholangioscope is advanced across the papilla into the bile duct or pancreatic duct. A sphincterotomy or sphincteroplasty is usually performed before insertion of the cholangioscope to improve the ease of scope insertion.

In this review, we will discuss how cholangioscopy has changed the management of patients with biliopancreatic disorders. For this review “cholangioscope” and “pancreatocopy” refers to the single operator per-oral cholangioscopy (SpyGlass System).

## Indications for Cholangioscopy

The indications for cholangio-pancreatocopy are increasing. Currently, the most frequent use of cholangioscopy is in the management of difficult bile duct stones and the evaluation of indeterminate biliary strictures (► **Table 2**).

### Difficult Bile Duct Stones

Stones within the biliary tree are a commonly encountered problem and 90% of the stones can be extracted

**Table 2** Current indications of cholangio-pancreatocopy

Biliary	Pancreatic
Difficult bile duct stones	Pancreatic stricture
Indeterminate biliary stricture	Intraductal papillary mucinous neoplasms
	Pancreatic stone
Extraction of migrated stents	

**Table 3** Difficult bile duct stones

Difficulty level	
Stone characteristics	a) Large stone $\geq 15$ mm b) Multiple stones $> 10$ mm c) Barrel-shaped stones d) Stone size to bile duct diameter ratio $> 1.0$
Stone location	a) Intrahepatic stones b) Stones above a stricture c) Mirizzi's syndrome
Anatomy	a) Periapillary diverticulum b) Surgically altered anatomy c) Short length of the distal common bile duct (CBD) $\leq 36$ mm d) Acute angle of distal CBD $\leq 135$ degrees

using standard techniques. i.e., using a stone extraction balloon, or a stone extraction basket. However, there can be occasional challenges that make stone extraction using standard techniques difficult. These can be largely grouped into stone characteristics, stone location, and anatomy (► **Table 3**).<sup>5-9</sup> For stones larger than 15 mm endoscopic papillary dilatation in combination with endoscopic sphincterotomy can facilitate the extraction of stones. However, in situations where the stone size is larger than the bile duct (stone to bile duct ratio  $> 1.0$ ), the stone is  $> 20$  mm in diameter, the stone is above a stricture, or there is an acute angle of the distal common bile duct (CBD), it is necessary to fragment the stone within the biliary tree before extraction. Shock wave lithotripsy utilizes shock waves to fragment the stones and this can be applied extracorporeal (extracorporeal shock wave lithotripsy [ESWL]) or within the bile duct.

**Table 4** Randomized controlled trial comparing laser with conventional techniques

Author, year	Study design	Population	Intervention	Comparator	Number (ratio)	Outcome
Li et al, 2021 <sup>10</sup>	RCT; Non inferiority	Large CBD stone ≥2 cm	LL	LCBDE	157 (1:1)	LL not inferior. First session clearance lower in LL
Bang et al, 2020 <sup>11</sup>	RCT	Difficult bile duct stones – failed retrieval with balloon or basket	LL	LBS	66 (1:1)	Laser: 93.9, LBS: 72.7 p = 0.021
Angsuwatcharakon et al, 2019 <sup>12</sup>	RCT	Large bile duct stones that were either not amenable/failed EPLBD	LL	Mechanical lithotripsy	32 (1:1)	Stone clearance 100% vs 63% p < 0.01 (favoring laser lithotripsy)
Buxbaum et al, 2018 <sup>13</sup>	RCT	Patients with bile duct stones > 1 cm in diameter	LL	Conventional (mechanical lithotripsy and EPLBD)	60 (2:1)	Laser: 93, Conventional: 67% p = 0.009

Abbreviations: EPLBD, endoscopic papillary large balloon dilatation; LBS, large balloon sphincteroplasty; LCBDE, laparoscopic common bile duct exploration; LL, laser lithotripsy.

Cholangioscopy allows for endoscopic access to the bile duct for direct visualization and fragmentation of stones. Cholangioscopy, assisted stone extraction is usually performed by utilizing shock waves delivered using laser lithotripsy or electrohydraulic lithotripsy.

#### Laser Lithotripsy

Laser light is monochromatic (i.e., of one wavelength), directional and coherent. These properties of laser light allow for its application in medical procedures. Pulsed solid-state lasers (holmium: YAG) are used for lithotripsy. Pulsed lasers can generate very high power for very short periods and therefore decrease the risk of injury. Laser light creates a plasma (collection of electrons and ions) at the surface of the stone and adjacent fluid. Expansion of the plasma creates a high-energy shock wave that fractures the stone (►Video 1). Laser machines allow for the modulation of pulse energy (Joule) and pulse frequency (Hertz) and thereby the power (Watt) of the laser machine, which is a product of energy (J) and frequency (Hz). The laser fibers are usually 4 m long and vary in diameter (200, 365, 550, or 1000 micrometre). The commonly used fiber diameter is 365 micro M. Laser lithotripsy (LL) has been

compared with conventional therapy (mechanical lithotripsy, EPLBD) and surgery. With LL, successful stone clearance can be achieved in > 90% of patients (►Table 4).

#### Video 1

Cholangioscopy assisted laser lithotripsy. Online content including video sequences viewable at: <https://www.thieme-connect.com/products/ejournals/html/10.1055/s-0042-1743183>.

#### Electrohydraulic Lithotripsy

The electrohydraulic lithotripsy (EHL) probe is a bipolar probe that is connected to a charge generator. With the probe tip positioned 1 to 2 mm from the surface of the stone, the application of charge to the bipolar probe in short pulses creates sparks that induce expansion and contraction of surrounding fluid resulting in an oscillatory shock wave. This shock wave fragments the stone. Continuous saline irrigation is required during EHL for shock wave

**Table 5** Electrohydraulic lithotripsy (EHL) for biliary stones

Author, Year	Study design	Population	Intervention	Number	Outcome
Binmoller et al, 1992 <sup>14</sup>	Prospective observational study	Patients with extrahepatic stones	EHL	108 difficult stones: EHL done in 65	Stone clearance in 64 (98.5%)
Kamiyama et al, 2018 <sup>15</sup>	Retrospective study	Difficult bile duct stone	Cholangioscope assisted: 34 Percutaneous: 8	42	Stone clearance 41 (98%)
Minami et al, 2021 <sup>16</sup>	Observational study	Difficult biliary stone (intrahepatic, CBD and CD)	Cholangioscope assisted	EHL-88 LL-2	Complete stone removal (92.2%)

Abbreviations: CBD, common bile duct; CD, cystic duct.

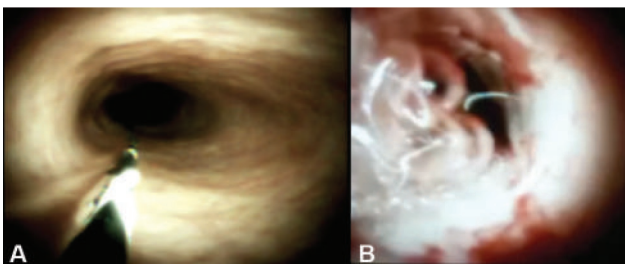
transmission. EHL has been in use for lithotripsy for last couple of decades. More than 90% of the stones can be successfully cleared with EHL (–Table 5). In a meta-analysis of 32 studies in which LL was compared with EHL, LL was found to have a higher rate of stone clearance (95.1% vs. 88.4%). Post-procedural complications appeared to be lower in patients who underwent LL compared with EHL (8.4% vs. 13.8%).<sup>17</sup>

### Pancreatic Calculi

Calculifications are a frequent finding in patients with chronic pancreatitis.<sup>18</sup> Intraductal lithotripsy has been explored as a means of treating calculi within the main pancreatic duct. In a meta-analysis of 15 studies including 370 patients, 237 EHL and 136 LL procedures were performed. The clinical success for EHL was 91.6% and that for LL was 86.6%. Adverse events occurred in 12%.<sup>19</sup> The role of intraductal lithotripsy in management of patients with chronic pancreatitis is unclear. Further studies with a head-to-head comparison between ESWL and intraductal lithotripsy may help better define its role.

### Indeterminate Biliary Stricture

Biliary stricture is considered indeterminate when basic work-up, transabdominal imaging, and ERCP with cytologic brushing are non-diagnostic. Cholangioscopy by its ability to directly visualize the bile duct offers a distinct advantage of visualizing the stricture and obtaining a tissue sample from the stricture under vision (–Fig. 1). Macroscopic features that suggest that the stricture may be neoplastic include, tortuous dilated vessel, papillary projections, vegetative mass, irregular papillary or granular lesions, ulceration, friability, and easy bleeding. Several attempts have been made to classify lesions as neoplastic and non-neoplastic based on macroscopic features. Robles-Medrandá et al made the first attempt at developing a classification for biliary lesions. Lesions with irregular or spider vascularity, irregular ulcerations, infiltrative patterns, or honeycomb patterns were classified as neoplastic.<sup>20</sup> The Monaco classification is a recent attempt at developing a consensus definition for visual interpretation of the biliary stricture. Amongst the visual anomalies observed in a stricture the presence of ulceration and papillary projections were found to be highly associated with a diagnosis of malignancy.<sup>21</sup> El Bacha et al identified three features that were diagnostic of malignant lesion viz. villous pattern, irregular vessels, and reddish aspect.<sup>22</sup> The Mendoza classification is another consensus-based classification system aimed at macroscopic



**Fig. 1** Cholangioscopy: (A) Benign bile duct stricture. (B) Stricture with neovascularization, ulceration, friability, and easy bleeding.

identification of neoplastic lesions. Three criteria viz. friability, tortuous dilated vessels, and raised intra-ductal lesions had the highest intraobserver agreement.<sup>23</sup> In a meta-analysis of six studies, the pooled sensitivity, specificity, and diagnostic odds ratio for visual interpretation of indeterminate biliary stricture at cholangioscopy was 94% (95% confidence interval [CI]: 89–97), 95% (95%CI: 90–98), and 308.83 (95%CI: 106.46–872.82), respectively.<sup>24</sup> In addition to visualization of the lesion, the cholangioscopes also allow for obtaining biopsy specimens from the stricture. In a meta-analysis of 11 studies that included 356 patients, the pooled sensitivity, pooled specificity, and odds ratio for visually directed biopsy in indeterminate biliary stricture was 0.74 (95% CI: 0.67–0.80), 0.98 (95% CI: 0.95–1.00), and 65.18 (95% CI: 26.79–158.61), respectively.<sup>25</sup> The overall sensitivity of cholangioscope assisted biopsy appears to be lower than the visual impression. This could be possibly related to lax criteria used for macroscopic identification of neoplastic lesion and the poor quality of tissue obtained at cholangioscopy with the older generation SpyBite forceps. Recently, the SpyBite Max biopsy forceps has been introduced. In this forceps, the internal spike has been removed and the cups have front and side serrated teeth profile along with two long fenestrated holes to allow grasp of a larger tissue sample. The change in the design of the forceps will probably help improve the sensitivity of cholangioscope-assisted tissue acquisition.

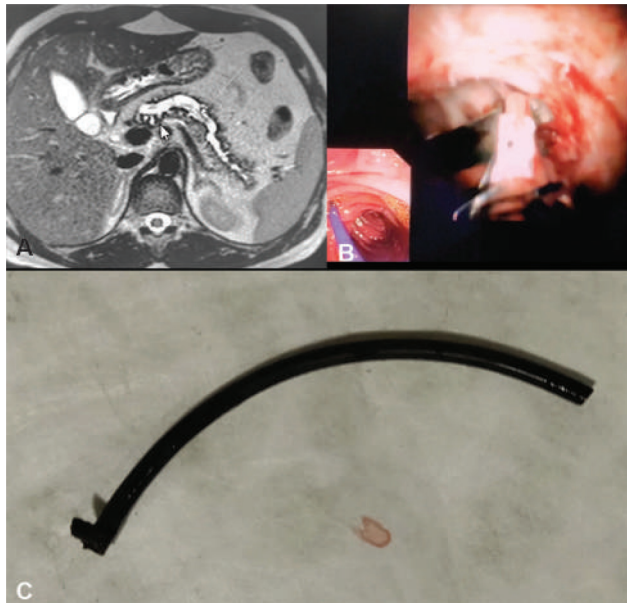
### Lesions in Pancreatic Duct

The utility of the cholangioscope is now being explored for the management of lesions in the pancreatic duct (pancreatocopy). Pancreatic duct strictures and dilatations can occasionally pose diagnostic challenges for clinicians. A 13-year study from the United States explored the role of per oral pancreatoscopy in differentiating malignant and benign lesions of the pancreatic duct. A total of 102 pancreatoscopy procedures were done in 79 patients. The sensitivity of detecting a neoplastic lesion based on visual impression was 87% and this improved to 91% with the addition of biopsy under direct vision. Adverse events that were predominantly in the form of post-procedural abdominal pain were reported in 12% of the patients.<sup>26</sup> Pancreatocopy has also been found to be of help in intra-ductal papillary mucinous neoplasms (IPMN). Using a mother–baby system, Hara et al classified the findings in patients with IPMN into five groups, viz. granular type, fish-egg-like type without vascular images, fish egg-like type with vascular images, villous type, and vegetative type.<sup>27</sup> In a retrospective multicenter study of patients with main duct IPMN, 42% of patients had findings at pancreatoscopy that were not seen on cross-sectional imaging. Pancreatocopy dictated the type of surgery in 77% of patients with diffusely dilated main pancreatic duct (> 10 mm). The authors concluded that pancreatoscopy should be included in the diagnostic algorithm of main duct IPMN in patients with a dilated main pancreatic duct.<sup>28</sup>

### Extraction of Migrated Stents

Plastic stents are commonly deployed in both pancreatic and biliary ducts. Stents at both these locations have a risk of





**Fig. 2** (A) MRCP: Dilated main pancreatic duct with proximally migrated stent within the MPD. (B) Pancreatoscopy: The stent tip is held by SpyBite forceps and extracted from the MPD through the major papilla. (C) Extracted plastic stent.

proximal and distal migration. Distally migrated stents can produce bowel obstruction, perforation, or recurrent cholangitis. Proximal migration of stents can result in biliary pain, cholangitis, formation of stricture or stone around the stent. The risk of proximal stent migration for both biliary and pancreatic stent is ~5%.<sup>29</sup> Several techniques and instruments have been described to extract the proximally migrated stents including rat tooth forceps, snares, stone extraction baskets, Soehendra's stent extraction device. However, at times the above techniques are not successful especially in proximally migrated pancreatic duct stents. In our center, we have successfully used the SpyBite forceps with SpyGlass system for the extraction of proximally migrated pancreatic stents, by holding the stent tip (→ Fig. 2). Recently, SpyGlass Retrieval snare with a snare diameter of 9 mm has been introduced for the extraction of stents.

## Future Directions

In this review, we have attempted to present the current applications of cholangioscope and how it has changed management. In the near future, we foresee a wider range of applications. With better image processing and maneuverability, the need for fluoroscopy will probably diminish. A recent development in the visual interpretation of indeterminate stricture visualized at cholangioscopy is the introduction of artificial intelligence. Mascharenas et al developed a deep learning algorithm that can accurately differentiate malignant from non-malignant biliary stricture.<sup>30</sup> Radiofrequency ablation (RFA) of unresectable cholangiocarcinomas has been shown to improve stent patency and overall survival. There is an emerging role of cholangioscopes in the

pre-procedure and post-procedure evaluation of the tumor after application of RFA.<sup>31</sup> With improvement in the present accessories such as a larger cup of the SpyBite forceps and durable baskets and snares the range of therapeutic applications of cholangioscope is set to widen.

## Conflict of Interest

None declared.

## References

- Bakes J. Die Choledochopapilloskopie, nebst Bemerkungen über Hepaticusdrainage und Dilatation der Papille. *Arch Klin Chir* 1923; 126:473–483
- Mclver MA. An instrument for visualizing the interior of the common duct at operation. *Surgery* 1941;9:112–114
- Shore JM, Berci G. An improved flexible cholangioscope. *Endoscopy* 1976;8(01):41–43
- Kawai K, Nakajima M, Akasaka Y, Shimamoto K, Murakami K. [A new endoscopic method: the peroral choledochopancreatoscopy (author's transl)]. *Leber Magen Darm* 1976;6(02):121–124
- Ersoz G, Tekesin O, Ozutemiz AO, Gunsar F. Biliary sphincterotomy plus dilation with a large balloon for bile duct stones that are difficult to extract. *Gastrointest Endosc* 2003;57(02):156–159
- Kim HJ, Choi HS, Park JH, et al. Factors influencing the technical difficulty of endoscopic clearance of bile duct stones. *Gastrointest Endosc* 2007;66(06):1154–1160
- Uskudar O, Parlak E, Disibeyaz S, et al. Major predictors for difficult common bile duct stone. *Turk J Gastroenterol* 2013;24 (03):260–265
- Lee JW, Kim JH, Kim YS, et al. The effect of periampullary diverticulum on the outcome of bile duct stone treatment with endoscopic papillary large balloon dilation [article on Ko]. *Korean J Gastroenterol* 2011;58(04):201–207
- Lee SH, Park JK, Yoon WJ, et al. How to predict the outcome of endoscopic mechanical lithotripsy in patients with difficult bile duct stones? *Scand J Gastroenterol* 2007;42(08):1006–1010
- Li G, Pang Q, Zhai H, et al. SpyGlass-guided laser lithotripsy versus laparoscopic common bile duct exploration for large common bile duct stones: a non-inferiority trial. *Surg Endosc* 2021;35(07): 3723–3731
- Bang JY, Sutton B, Navaneethan U, Hawes R, Varadarajulu S. Efficacy of Single-Operator Cholangioscopy-Guided Lithotripsy Compared With Large Balloon Sphincteroplasty in Management of Difficult Bile Duct Stones in a Randomized Trial. *Clin Gastroenterol Hepatol* 2020;18(10):2349–2356.e3
- Angsuwatcharakon P, Kulpatcharapong S, Ridditid W, et al. Digital cholangioscopy-guided laser versus mechanical lithotripsy for large bile duct stone removal after failed papillary large-balloon dilation: a randomized study. *Endoscopy* 2019;51(11): 1066–1073
- Buxbaum J, Sahakian A, Ko C, et al. Randomized trial of cholangioscopy-guided laser lithotripsy versus conventional therapy for large bile duct stones (with videos). *Gastrointest Endosc* 2018;87 (04):1050–1060
- Binmoeller KF, Brückner M, Thonke F, Soehendra N. Treatment of difficult bile duct stones using mechanical, electrohydraulic and extracorporeal shock wave lithotripsy. *Endoscopy* 1993;25(03): 201–206
- Kamiyama R, Ogura T, Okuda A, et al. Electrohydraulic lithotripsy for difficult bile duct stones under endoscopic retrograde cholangiopancreatography and peroral transluminal cholangioscopy guidance. *Gut Liver* 2018;12(04):457–462
- Minami H, Mukai S, Sofuni A, et al. Clinical outcomes of digital cholangioscopy-guided procedures for the diagnosis of biliary strictures and treatment of difficult bile duct stones: a

- single-center large cohort study. *J Clin Med* 2021;10(08):1638
- 17 Veld JV, van Huijgevoort NCM, Boermeester MA, et al. A systematic review of advanced endoscopy-assisted lithotripsy for retained biliary tract stones: laser, electrohydraulic or extracorporeal shock wave. *Endoscopy* 2018;50(09):896–909
  - 18 Chowdhury SD, Kurien RT, Ramachandran A, et al. Pancreatic exocrine insufficiency: Comparing fecal elastase 1 with 72-h stool for fecal fat estimation. *Indian J Gastroenterol* 2016;35(06):441–444
  - 19 Guzmán-Calderón E, Martínez-Moreno B, Casellas JA, Aparicio JR. Per-oral pancreatoscopy-guided lithotripsy for the endoscopic management of pancreatolithiasis: a systematic review and meta-analysis. *J Dig Dis* 2021;22(10):572–581
  - 20 Robles-Medranda C, Valero M, Soria-Alcivar M, et al. Reliability and accuracy of a novel classification system using peroral cholangioscopy for the diagnosis of bile duct lesions. *Endoscopy* 2018;50(11):1059–1070
  - 21 Sethi A, Tyberg A, Slivka A, et al. Digital single-operator cholangioscopy (DSOC) improves interobserver agreement (IOA) and accuracy for evaluation of indeterminate biliary strictures: the Monaco classification. *J Clin Gastroenterol* 2020
  - 22 El Bacha H, Harizi R, Laugier R, et al. Cholangioscopic criteria for indeterminate biliary stenosis diagnosis. *Endoscopy* 2019;51(04):S36
  - 23 Kahaleh M, Gaidhane M, Shahid HM, et al. Digital single-operator cholangioscopy interobserver study using a new classification: the Mendoza Classification (with video). *Gastrointest Endosc* 2021;S0016-5107(21)01605-9
  - 24 de Oliveira PVAG, de Moura DTH, Ribeiro IB, et al. Efficacy of digital single-operator cholangioscopy in the visual interpretation of indeterminate biliary strictures: a systematic review and meta-analysis. *Surg Endosc* 2020;34(08):3321–3329
  - 25 Wen LJ, Chen JH, Xu HJ, Yu Q, Liu K. Efficacy and safety of digital single-operator cholangioscopy in the diagnosis of indeterminate biliary strictures by targeted biopsies: a systematic review and meta-analysis. *Diagnostics (Basel)* 2020;10(09):E666
  - 26 El Hajj II, Brauer BC, Wani S, Fukami N, Atwell AR, Shah RJ. Role of per-oral pancreatoscopy in the evaluation of suspected pancreatic duct neoplasia: a 13-year U.S. single-center experience. *Gastrointest Endosc* 2017;85(04):737–745
  - 27 Hara T, Yamaguchi T, Ishihara T, et al. Diagnosis and patient management of intraductal papillary-mucinous tumor of the pancreas by using peroral pancreatoscopy and intraductal ultrasonography. *Gastroenterology* 2002;122(01):34–43
  - 28 Trindade AJ, Benias PC, Kurupathi P, et al. Digital pancreatoscopy in the evaluation of main duct intraductal papillary mucinous neoplasm: a multicenter study. *Endoscopy* 2018;50(11):1095–1098
  - 29 Johanson JF, Schmalz MJ, Geenen JE. Incidence and risk factors for biliary and pancreatic stent migration. *Gastrointest Endosc* 1992;38(03):341–346 <https://pubmed.ncbi.nlm.nih.gov/1607087/> cited 2021 Oct 17 [Internet]
  - 30 Mascarenhas Saraiva M, Ribeiro T, Ferreira JPS, et al. Artificial intelligence for automatic diagnosis of biliary strictures malignancy status in single-operator cholangioscopy: a pilot study. *Gastrointest Endosc* 2022;95(02):339–348
  - 31 Pereira P, Santos AL, Morais R, et al. Endoscopic radiofrequency ablation for palliative treatment of hilar cholangiocarcinoma. *VideoGIE* 2021;6(04):195–198