



Reinke Edema: Factors that Interfere with Vocal Recovery after Surgery

José Luiz Lima Neto¹ Antônio Rodrigues Bueno da Fonseca¹ Elaine Lara Mendes Tavares¹
Andrea Cristina Joia Gramuglia¹ Regina Helena Garcia Martins¹

¹ Department of Ophthalmology, Otorhinolaryngology, and Head and Neck Surgery, Universidade Estadual Paulista Julio de Mesquita Filho, Unesp Botucatu, São Paulo, Brazil

Int Arch Otorhinolaryngol 2023;27(1):e77–e82.

Address for correspondence Regina Helena Garcia Martins, MD, PhD, Departamento de Oftalmologia, Otorrinolaringologia e Cirurgia de Cabeça e Pescoço, Faculdade de Medicina de Botucatu, Universidade Estadual Paulista Julio de Mesquita Filho, Unesp Botucatu, distrito de Rubião Junior, s/n. CEP- 18618-970, São Paulo, Brasil (e-mail: regina.g.martins@unesp.br).

Abstract

Introduction Dysphonia and lower pitch after surgery of Reinke edema are common. They are caused especially due to chronic smoking but, probably, other factors should be associated.

Objectives To evaluate the results of laryngeal microsurgery in patients with Reinke edema, following a standardized postoperative guidance protocol in our service.

Methods Retrospective study. Thirty patients (3 males; 27 females) were included, 70% between 41 and 60 years old. The parameters analyzed in the pre- and postoperative (between 4 and 6 months) of patients undergoing laryngeal microsurgery for Reinke edema were: smoking, vocal symptoms, videolaryngostroboscopy, voice therapy, perceptual and acoustic vocal evaluation, histopathological report.

Results Smoking was reported by 100% of the patients and maintained in the postoperative period by 80%. Complete improvement of symptoms in the postoperative period was reported by 43% of them, partial improvement by 40%, and maintenance by 17%.

There was low adherence to voice therapy in the pre- and postsurgery.

Postoperative videolaryngoscopy indicated congestion (19), atrophy and bowed vocal fold (1), subepithelial edema (2), and normal findings (8). The histological findings were subepithelial edema, enlargement of vessels, inflammation, epithelial hyperplasia, and thickening of the basement membrane. The perceptual and acoustic vocal analyzes indicated improvement of the analyzed parameters.

Conclusions The maintenance of some vocal symptoms and laryngeal alterations in videolaryngoscopy after microsurgery of Reinke edema is frequent, even in patients who follow the recommendations of vocal rest and control of gastroesophageal reflux. Vocal symptoms are attributed to changes in the laryngeal mucosa caused by chronic smoking, aggravated by the maintenance of addiction in the postoperative period.

Keywords

- ▶ reinke edema
- ▶ dysphonia
- ▶ surgery
- ▶ treatment

received
June 21, 2021
accepted after revision
December 1, 2021

DOI <https://doi.org/10.1055/s-0042-1743463>.
ISSN 1809-9777.

© 2023. Fundação Otorrinolaringologia. All rights reserved.
This is an open access article published by Thieme under the terms of the Creative Commons Attribution-NonDerivative-NonCommercial-License, permitting copying and reproduction so long as the original work is given appropriate credit. Contents may not be used for commercial purposes, or adapted, remixed, transformed or built upon. (<https://creativecommons.org/licenses/by-nc-nd/4.0/>)
Thieme Revinter Publicações Ltda., Rua do Matoso 170, Rio de Janeiro, RJ, CEP 20270-135, Brazil

Introduction

Structurally, the vocal folds have a stratified squamous epithelium, a delicate and continuous basement membrane, and a specific lamina that is organized into three layers that differ in terms of the concentration of the components of the fibrous matrix, especially elastic and collagen fibers (types I and III). The superficial layer, called Reinke space, is loose, has few fibers, some fibroblasts and leukocytes, and rare capillaries.^{1,2} The intermediate layer is denser and richer in elastic fibers and, below it, the deep layer is located, corresponding to a true collagen fiber carapace, called the vocal ligament (– Figs. 1 and 2).^{1,2} The reparation of this elaborate ultrastructure, when manipulated during microsurgery, requires restructuring the components of the lamina propria,

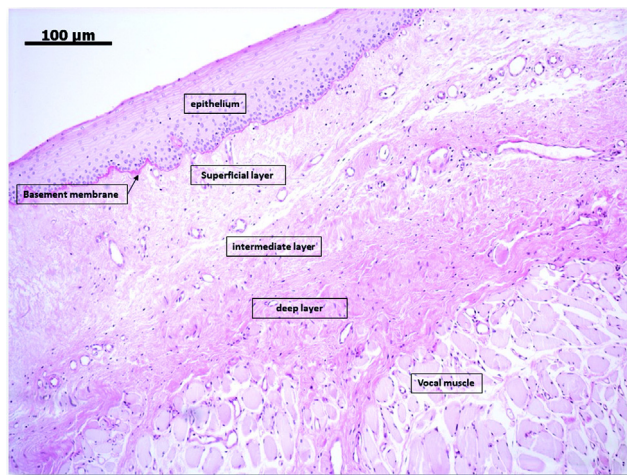


Fig. 1 Human vocal fold. Stratified epithelium, delicate and continuous basement membrane and the three layers of the lamina propria. The superficial layer being looser and the intermediate layer and the deep layer being denser. Light Microscopy, hematoxylin and eosin, 40X

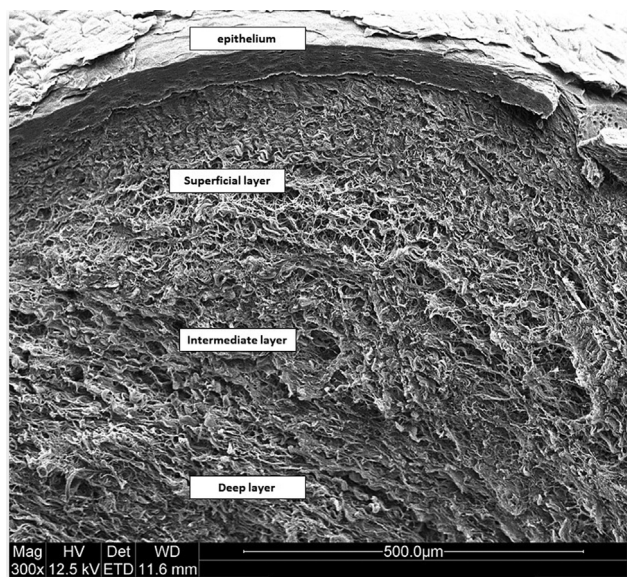


Fig. 2 Human vocal fold. Stratified epithelium, basement membrane, superficial layer, looser in extracellular matrix, intermediate and deep layers, denser. Scanning electron microscopy, 300X

whose process can be slow and not always completed perfectly, which may result in atrophy and fibrosis.

Reinke edema is a benign laryngeal lesion in which a thick and thin mucus accumulates in the superficial layer. The mass effect on the vocal folds makes the voice hoarse and with lower pitch. Symptoms are more important among women, as the voice starts to resemble the male voice, with a fundamental frequency < 130 Hz (normal values for female voices range from 190 to 200 Hz).³

The cause of Reinke edema is chronic smoking, favored by predisposing factors such as gastroesophageal reflux and vocal abuse.³ Cigarette components induce angiogenesis by increasing vascular permeability and resulting in subepithelial edema.³ Histopathological and electron microscopic analyzes show epithelial hyperplasia, thickening of the basement membrane, vesicles in the basement membrane, infiltration of inflammatory cells in the lamina propria, increased vascular permeability, fenestrations in capillaries, loss of intercellular junctions, distortion of the structure of elastic fibers and collagen, and decreased fibronectin.^{3–6}

The treatment of Reinke edema is eminently surgical; however, although most patients report a considerable improvement in voice in the postoperative period, many of them maintain some degree of hoarseness.⁷ The vocal recovery time is variable and depends on several factors, such as the elimination of smoking, control of vocal abuse and reflux, adherence to voice therapy, and the degree of manipulation of the vocal folds during the operation.

The maintenance of dysphonia and of the lower pitch in the postoperative period can be reported even by patients with videolaryngoscopy exams without remaining lesions and are probably due to chronic and irreversible structural changes in the laryngeal mucosa. In a previous study, we compared the voices of patients who underwent microsurgery due to Reinke edema with those of control patients, nonsmokers and without laryngeal lesions. We found that the voices of patients who underwent surgery for Reinke edema remained, after 6 months, with lower values of fundamental frequency.⁸ For some authors, these partially satisfactory results are reported by 81% of patients.³

The aim of the present study was to evaluate the results of laryngeal microsurgery in patients with Reinke edema, following a standardized postoperative guidance protocol in our service.

Material and methods

This is a retrospective study that included adult patients, of both genders, seen at the voice disorders outpatient clinic of the Botucatu Faculty of Medicine of the Júlio de Mesquita Filho State University of São Paulo, who underwent laryngeal microsurgery for Reinke edema between 2018 and 2020, with a diagnosis confirmed by videolaryngostroboscopy. Thirty patients were included in the study, 27 women and three men, 23 of them (76%) aged between 41 and 60 years old.

The parameters evaluated in the pre- and postoperative period (between 4 and 6 months) were age, gender, smoking, videolaryngostroboscopy, histopathological reports,

adherence to speech therapy, and perceptual-auditory and acoustic vocal assessment.

The exclusion criteria were patients undergoing other laryngeal surgical procedures in addition to Reinke edema and patients with suspected laryngeal neoplasia.

Perceptual-auditory vocal assessment was performed using the GRBASI scale, which includes the parameters: GRADE (Grade of dysphonia – G), ROUGHNESS (R), BREATHNESS (B), ASTHENY (A), STRAIN (S), and INSTABILITY (I). The scale uses an intensity rating from 0 to 3 for each of the analyzed parameters. The scores were calculated by three voice specialists, blindly in relation to the pre- or postsurgical moments, with agreement between at least two evaluators. The vocal sample selected was the emission of the sustained vowel /a/ and spontaneous speech.

Acoustic vocal assessments were performed by the same speech therapist, with experience in voice, using the Multi Dimensional VoiceProgram software (MDVP, KayPENTAX, USA), model 5105, version 2.5.2 (Multi Speech 3700). The vocal sample used was the emission of the vowel /a/. The acoustic parameters analyzed were: fundamental frequency (f0), % jitter, pitch disturbance coefficient (PPQ), % shimmer, amplitude disturbance coefficient (APQ), Noise / Harmonic (NHR), Soft phonation index (SPI).

Videolaryngostroboscopy exams were performed using a rigid telescope (Asap, Germany), 70°, 8 mm in diameter, or 3.5 mm flexible nasofibroscope (Olympus, Japan), coupled to a multifunctional system (video system type XE-30, Eco X - TFT / USB - Germany) with image capture registration (Medical capture), video capture card (PinnacleVideoTransfer) and strobe light source (Atmos – model Endo-Stroboscopes Magdeburg, Saxônia-Anhalt, Germany).

Videolaryngoscopy exams and vocal analysis were performed in the pre- and postoperative periods, between 4 and 6 months. Two specialists in laryngology blindly as to the moments of the study performed the reports of the endoscopic exams.

Laryngeal microsurgeries were performed under the supervision of the professor who supervised the present study, using a Zeiss microscope, suspension laryngoscope, and microsurgery material, such as grasping forceps, scissors, and cold scalpel. There was no record of complications during the intra- and postoperative periods or during intubation.

After surgery, all patients received the following postoperative guidelines:

- absolute vocal rest for 3 days and relative vocal rest thereafter for another 15 days, during which the patient was instructed to speak the minimum necessary, maintaining a low voice and in the usual pitch;
- avoid clearing your throat, coughing or whispering;
- drink fluids at room temperature, avoiding extreme temperatures; avoid sweets and spicy foods;
- proton pump inhibitor (Omeprazol 20 mg twice daily) for 2 months and avoid smoking.

The present study received approval by the Human Research Ethics Committee at the Botucatu Faculty of Medi-

cine of the Júlio de Mesquita Filho State University of São Paulo (CAAE - 89892718.7.0000.5411).

For the statistical analysis of the acoustic vocal parameters between the pre- and postoperative moments, the paired t-Student test (paired student *t*-test) was used. For the perceptual-auditory vocal analyzes (GRBASI scale), the nonparametric Wilcoxon paired test (Wilcoxon Signed Rank Test) was performed. All analytical results were discussed considering a 5% level of significance.

Results

Vocal symptoms presurgery: dysphonia and lower pitch predominated, with an average symptom duration of 38 months. In the postoperative period, 13 patients (43%) reported complete voice improvement, 12 (40%) reported partial improvement, and 5 (17%) reported no improvement.

Voice therapy: only 9 patients (30%) underwent irregular voice therapy before surgery, totaling 1 or 2 sessions. In the postoperative period, 12 patients underwent voice therapy (40%), also irregularly.

Smoking: smoking was reported by 100% of the patients before surgery and by 80% of them postsurgery.

Videolaryngoscopy exams: presurgery, the videolaryngoscopies confirmed the diagnosis of Reinke edema in all cases. Unilateral leukoplakia associated with Reinke edema was identified in four cases (→Fig. 3). In the postoperative period, the videolaryngoscopies showed hyperemic and congestion ($n = 19$), atrophy and irregular bowed vocal fold ($n = 1$), mild subepithelial edema ($n = 2$), and normal exam ($n = 8$). Hyperfunction was observed in five patients in the postoperative period.

Videolaryngostroboscopy: before surgery, the videolaryngostroboscopy showed increased amplitude of the glottic wave. In the postoperative period, the glottic wave was present and symmetric ($n = 18$), absent ($n = 1$) or decreased ($n = 11$).

Histopathological findings: mild dysplasia was diagnosed in 2 patients (6.7%), 1 of whom had leukoplakia associated with Reinke edema. In the others, there was a predominance

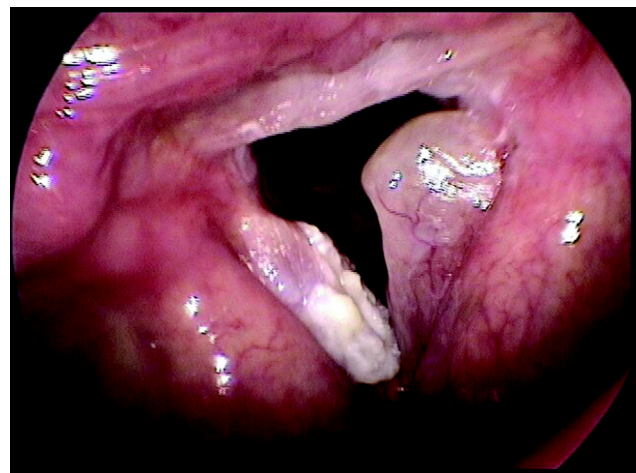


Fig. 3 Reinke edema associated with leukoplakia

Table 1 Median (min and max) of the perceptive vocal analysis

Perceptive parameters	Moment		p-value
	Pre	Post	
G			
Median [Min, Max]	2.00 [1.00, 3.00]	1.00 [0, 3.00]	< 0.001*
R			
Median [Min, Max]	2.00 [1.00, 3.00]	1.00 [0, 2.00]	< 0.001*
B			
Median [Min, Max]	1.00 [0, 2.00]	1.00 [0, 3.00]	0.016*
A			
Median [Min, Max]	0 [0, 1.00]	0 [0, 1.00]	*
S			
Median [Min, Max]	1.00 [0, 3.00]	1.00 [0, 2.00]	0.004*
I			
Median [Min, Max]	1.00 [0, 3.00]	0 [0, 3.00]	0.121

Abbreviations: G; grade; R, roughness; B, breathness; A, asthenia; S, strain.

* $p < 0.05$.

Table 2 Mean and standard deviation of the acoustic vocal parameters

Acoustic vocal parameters	Moments		p-value
	Pre	Post	
f0			
Mean (SD)	145 (39.5)	177 (35.4)	< 0.001*
%JTT			
Mean (SD)	3.45 (3.64)	1.69 (1.15)	0.008*
PPQ			
Mean (SD)	2.27 (2.31)	1.05 (0.689)	0.004*
%SHIM			
Mean (SD)	8.90 (7.90)	4.87 (3.10)	0.002*
APQ			
Mean (SD)	6.21 (5.22)	3.32 (1.61)	0.003*
NHR			
Mean (SD)	0.572 (1.81)	0.196 (0.267)	0.189
SPI			
Mean (SD)	8.00 (5.74)	14.1 (8.10)	< 0.001*

Abbreviations: SD, standard deviation; F0, fundamental frequency; %JTT, jitter percentage; %SHIM, shimmer percentage; PPQ, pitch perturbation quotient; APQ, amplitude perturbation quotient; NHR, noise harmonic ratio; SPI, soft phonation index.

* $p < 0.05$.

of subepithelial edema, enlargement of vessels, inflammatory infiltrate, hyperplasia, and thickening of the basement membrane.

► **Tables 1** and **2** show the results of the perceptual-auditory and acoustic vocal analyzes, respectively. There was an improvement in perceptual-auditory (GRBAS) and acoustic vocal parameters in the postoperative period, except for NHR. There was a considerable increase in the f0 values (145 to 177) in 28 patients.

Discussion

Reinke edema is more frequent in women > 50 years old and is directly related to chronic smoking, reported by 100% of our patients in the preoperative period and maintained by 80% of them in the postoperative moment. Its predilection for women is justified by the considerable decrease in pitch. In a study that included patients with Reinke edema and a control group, without laryngeal lesions, vocal analyzes,

performed blindly, classified the voices of patients with Reinke edema as male, whose fundamental frequency was near 140 Hz.⁹

Probably, the origin of dysphonia in patients with Reinke edema is not limited to submucosal edema, since some degree of vocal symptoms remains after microsurgery in most patients, even in those without remaining lesions. In our study, less than half of the patients (43%) reported complete improvement in vocal symptoms and, for some authors, this percentage can reach 80%.³ Partial improvement was reported by 40% of the patients, and 17% of the others did not report any improvement. However, the comparative pre- and postoperative vocal analyzes (auditory-perceptual and acoustic) revealed an important and statistically significant improvement (–Tables 1 and 2). Even so, these values of the postoperative parameters differ from the norms obtained from control patients, especially the f0 values, maintained at ~ 177 Hz.

The most compromised vocal perceptual parameters in the preoperative period were G, R, and S. These parameters showed significant improvement postoperatively. However, we observed that the median values of these parameters is ~ 1 and not zero, indicating the persistence of some degree of vocal alterations.

In the vocal acoustic analysis, there was a considerable increase in the f0 values (145 to 177) in 28 patients, but still below the normal values for female voices (190 to 200Hz). The jitter and shimmer values also decreased, indicating an improvement in vocal performance. There was also an increase in Soft Phonation Index (SPI) values indicating an increase in breathiness in the postoperative period.

Among other possible causes of dysphonia in the postoperative period of Reinke edema, we highlight the low adherence to voice therapy and, mainly, the chronic structural changes caused by the daily aggression of tobacco components on the laryngeal mucosa that include hyperemia, edema, and congestion, as also observed in our results.^{6,10,11}

The treatment of Reinke edema is surgical, and, in some cases, the procedure requires bilateral manipulation.⁹ In this condition, the covering mucosa takes time to regenerate, resulting in considerable vocal damage in the 1st 15 days. Thus, vocal evaluations should be performed 4 or 5 months after surgery, respecting the time of mucosal regeneration in the three stages of healing: inflammatory, proliferative, and maturation. The inflammatory phase occurs in the first days and is marked by hemostasis and influx of inflammatory cells. The proliferative phase occurs afterwards and remains during the 1st month, being marked by the intense activation of fibroblasts (initiated in the 1st 72 hours) and an important proliferation of extracellular matrix. The maturation phase is a long process, in which the remodeling of the scar tissue occurs, with a variable period to complete, depending on the tissue.¹²

Several factors can compromise and delay the regeneration process of the laryngeal mucosa, such as age, inhaled pollutants, vocal abuse, systemic diseases that compromise healing, and the degree of surgical manipulation.¹³ Imaizumi et al.¹³ performed lesions on the vocal folds of rats at

different depths: subepithelial (epithelium and superficial layers of the lamina propria); transmucous (epithelium and deeper lamina propria); transmuscular (superficial portion of the vocalis muscle). In the subepithelial lesions, there was complete recovery of the mucosa in 14 days, and, in the deeper lesions, the mucosa took 35 days to recover.

Leydon et al.¹⁴ studied the stages of structural and functional regeneration of the vocal fold epithelium of rats after injuries and observed rapid restoration of the cover epithelium, with the recomposition of its multilaminar aspect and intercellular junctions in the first days. However, the epithelial permeability remains atypical, even 5 weeks after the injury, keeping the mucosa fragile to the exposure of pathogens and to mechanical traumas.

For the successful regeneration of the laryngeal mucosa, initial vocal rest is essential; however, there is no consensus regarding the ideal time of rest. Based on the recommendations of some authors,^{15,16} we have guided absolute vocal rest for 3 days, and relative vocal rest for the next 15 days, a period in which low phonatory demand must be maintained. We believe that maintaining absolute vocal rest beyond 3 days is a very difficult mission. Relative rest is very important for the regeneration of the laryngeal mucosa, since we do not use glues or sutures during surgery and vocal rest helps to maintain the positioning of the mucosa. We have no record of adherence or of major complications with this technique. For Kaneko et al.,¹⁵ absolute vocal rest is very important during the inflammatory phase of the postoperative period, corresponding to the 1st 3 days. In the proliferative phase that follows, they recommend a gradual phonation, aiming to stimulate the activity of fibroblasts and, consequently, to speed up the restoration of tissues.

Dhaliwal et al.¹⁶ performed a study in which two groups of patients were recruited in the postoperative period of laryngeal microsurgery: group A – 3 days of vocal rest ($n=16$); and group B – 7 days of vocal rest ($n=15$). The vocal acoustic vocal and auditory perceptual analyzes performed after 1, 3 and 6 months indicated better results in group A, with absolute vocal rest for only 3 days.

In the postoperative period of laryngeal microsurgery, we also recommended the intake of a proton pump inhibitor for 2 months and antireflux measures to prevent acid laryngitis. This practice is used by many professionals; however, we have not found scientific evidence to prove its benefits.^{3,17,18}

Another possible factor unfavorable to the regeneration of the laryngeal mucosa in the postoperative period of Reinke edema would be its association with leukoplakia. We had four patients with this condition, with mild dysplasia being diagnosed in only 1 case (3%). For Tavaluc et al.,¹⁹ moderate and severe dysplasia associated with Reinke edema correspond to < 17% of cases, and for Lim et al.,²⁰ these rates do not exceed 2%, which is indicative of the low degree of malignancy related to Reinke edema.

The present study has some limitations: it is a retrospective study and therefore we had difficulties in obtaining clinical and endoscopic follow-up records for a period longer than six months. It would also be interesting to check if 1 year after the surgery the patients really stopped smoking.

Conclusions

The maintenance of some vocal symptoms and laryngeal alterations in videolaryngoscopy after microsurgery of Reinke edema is frequent, even in patients who obey the recommendations of vocal rest and control of gastroesophageal reflux. Vocal symptoms are attributed to changes in the laryngeal mucosa caused by chronic smoking, aggravated by the maintenance of addiction in the postoperative period.

Financial Support

None.

Conflict of interests

The authors have no conflict of interests to declare.

References

- Hirano M. Morphological structure of the vocal cord as a vibrator and its variations. *Folia Phoniatr (Basel)* 1974;26(02):89–94
- Madruga de Melo EC, Lemos M, Aragão Ximenes Filho J, Sennes LU, Nascimento Saldiva PH, Tsuji DH. Distribution of collagen in the lamina propria of the human vocal fold. *Laryngoscope* 2003;113(12):2187–2191. Doi: 10.1097/00005537-200312000-00027
- Tavaluc R, Tan-Geller M. Reinke's Edema. *Otolaryngol Clin North Am* 2019;52(04):627–635. Doi: 10.1016/j.otc.2019.03.006
- Sato K, Hirano M, Nakashima T. Electron microscopic and immunohistochemical investigation of Reinke's edema. *Ann Otol Rhinol Laryngol* 1999;108(11 Pt 1):1068–1072. Doi: 10.1177/000348949910801108
- Pastuszek P, Krecicki T, Zalesska-Krecicka M, Jeleń M, Rak J, Krajewska B. Histological and electron microscopic investigation of Reinke's edema. *Pol J Pathol* 2003;54(01):61–64
- Grossmann T, Steffan B, Kirsch A, Grill M, Gerstenberger C, Gugatschka M. Exploring the Pathophysiology of Reinke's Edema: The Cellular Impact of Cigarette Smoke and Vibration. *Laryngoscope* 2021;131(02):E547–E554. Doi: 10.1002/lary.28855
- Khodeir MS, Hassan SM, El Shoubary AM, Saad MNA. Surgical and Nonsurgical Lines of Treatment of Reinke's Edema: A Systematic Literature Review. *J Voice*. 2021 May;35(3):502.e1-502.e11. doi: 10.1016/j.jvoice.2019.10.016. Epub 2019 Nov 21. PMID: 31761692
- Martins RHG, Tavares ELM, Pessin ABB. Are vocal alterations caused by smoking in Reinke's edema in women entirely reversible after microsurgery and smoking cessation? *J Voice* 2017;31(03):380.e11–380.e14
- Pereira AM, Dassie-Leite AP, Pereira EC, Cavichiolo JB, Rosa MO, Fugmann EA. Auditory perception of lay judges about gender identification of women with Reinke's edema. *CoDAS* 2018;30(04):e20170046
- Martins RH, Fabro AT, Domingues MA, Chi AP, Gregório EA. Is Reinke's edema a precancerous lesion? Histological and electron microscopic aspects. *J Voice* 2009;23(06):721–725. Doi: 10.1016/j.jvoice.2008.03.001
- Sakae FA, Imamura R, Sennes LU, Tsuji DH, Mauad T, Saldiva PHN. Elastic fibers in Reinke's edema. *Ann Otol Rhinol Laryngol* 2010;119(09):609–614. Doi: 10.1177/000348941011900907
- Chen X, Thibeault SL. Characteristics of age-related changes in cultured human vocal fold fibroblasts. *Laryngoscope* 2008;118(09):1700–1704
- Imaizumi M, Thibeault SL, Leydon C. Classification for animal vocal fold surgery: resection margins impact histological outcomes of vocal fold injury. *Laryngoscope* 2014;124(11):E437–E444
- Leydon C, Imaizumi M, Yang D, Thibeault SL, Fried MP. Structural and functional vocal fold epithelial integrity following injury. *Laryngoscope* 2014;124(12):2764–2769
- Kaneko M, Hirano S. Voice rest after laryngeal surgery: what's the evidence? *Curr Opin Otolaryngol Head Neck Surg* 2017;25(06):459–463. Doi: 10.1097/MOO.0000000000000407
- Dhaliwal SS, Doyle PC, Failla S, Hawkins S, Fung K. Role of voice rest following laser resection of vocal fold lesions: A randomized controlled trial. *Laryngoscope* 2020;130(07):1750–1755. Doi: 10.1002/lary.28287
- Kamargiannis N, Gouveris H, Katsinelos P, et al. Chronic pharyngitis is associated with severe acidic laryngopharyngeal reflux in patients with Reinke's edema. *Ann Otol Rhinol Laryngol* 2011;120(11):722–726. Doi: 10.1177/000348941112001105
- Lechien JR, Saussez S, Nacci A, et al. Association between laryngopharyngeal reflux and benign vocal folds lesions: A systematic review. *Laryngoscope* 2019;129(09):E329–E341. Doi: 10.1002/lary.27932
- Tavaluc R, Herman H, Lin J, Tan M. Does Reinke's Edema Grade Determine Premalignant Potential? *Ann Otol Rhinol Laryngol* 2018;127(11):812–816. Doi: 10.1177/0003489418796529
- Lim S, Sau P, Cooper L, McPhaden A, Mackenzie K. The incidence of premalignant and malignant disease in Reinke's edema. *Otolaryngol Head Neck Surg* 2014;150(03):434–436. Doi: 10.1177/0194599813520123