











# Surgical Treatment of Sublingual Gland Ranulas

Michał Gontarz<sup>1,2</sup>  Jakub Bargiel<sup>1,2</sup>  Krzysztof Gąsiorowski<sup>1,2</sup>  Tomasz Marcik<sup>1,2</sup>   
 Paweł Szczurowski<sup>1,2</sup>  Jan Zapła<sup>1,2</sup>  Krystyna Gałązka<sup>2,3</sup>  Grażyna Wyszńska-Pawełec<sup>1,2</sup> 

<sup>1</sup>Department of Cranio-Maxillofacial Surgery, Jagiellonian University Medical College, Cracow, Poland

<sup>2</sup>University Hospital, Cracow, Poland

<sup>3</sup>Department of Pathology, Jagiellonian University Medical College, Cracow, Poland

Address for correspondence Michał Gontarz, DDS, PhD, Department of Cranio-Maxillofacial Surgery, Jagiellonian University Medical College, University Hospital, Cracow, Poland, 2 Jakubowskiego Street, 30-688 Cracow, Poland (e-mail: [michal.gontarz@uj.edu.pl](mailto:michal.gontarz@uj.edu.pl)).

Int Arch Otorhinolaryngol 2023;27(2):e296–e301.

## Abstract

**Introduction** Ranulas are divided into oral (OR) and plunging (PR) and comprise the most common pathology of the sublingual gland. This study presents a case series of patients operated due to OR and PR within different type of modalities in a 1-year period.

**Objective** The aim of this study is to determine the optimal surgical treatment of ranulas based on our results as well as in the literature review.

**Methods** The medical charts of 7 patients with sublingual gland ranulas treated in 2020 were reviewed.

**Results** The median age of the patients was 19. Three patients with OR were treated by marsupialization, micromarsupialization, and sublingual gland excision. Four patients with PR were operated via cervical approach in three cases and intraoral approach in one case. No recurrence was observed in 14 months of follow-up, on average.

**Conclusion** Micromarsupialization should be consider as the primary treatment for OR. In case of recurrent OR and primary or recurrent PR, the best results might be obtained by radical excision of the sublingual gland, which can be performed without resection of the ranula sac with the intraoral approach.

## Keywords

- ▶ ranula
- ▶ oral ranula
- ▶ plunging ranula
- ▶ salivary gland
- ▶ sublingual gland
- ▶ treatment

## Introduction

The sublingual glands are the smallest of the major salivary glands. The most common pathology of the sublingual gland is ranula. Based on extension, ranulas are divided into oral (simple) and plunging (cervical).<sup>1</sup> The term ranula is derived from the Latin word rana, meaning a small frog. The ranula was first described by Hipocrates, who believed that this is a local chronic inflammatory process.<sup>2,3</sup> In the end of 19<sup>th</sup> century, Suzanne and von Hippel described the sublingual gland origin of ranulas.<sup>4,5</sup> However, in 1920, Thompson

denied the role of the sublingual gland in ranulas formation in favor of an embryologic etiology. He believed that ranulas arise from the remnants of the brachial arches, similar to brachial cysts.<sup>6</sup> In 1956, Bhaskar et al. concluded that ranulas are produced by extravasation of saliva from damaged salivary ducts and are lined by connective tissue without epithelium.<sup>7</sup>

The proper treatment of ranulas is still controversial. Numerous treatment modalities, which can be divided into surgical and nonsurgical, are used. The nonsurgical treatment comprises sclerotherapy with injection of such agents as

received

June 7, 2021

accepted after revision

January 17, 2022

DOI <https://doi.org/>

10.1055/s-0042-1744166.

ISSN 1809-9777.

© 2022. Fundação Otorrinolaringologia. All rights reserved.

This is an open access article published by Thieme under the terms of the Creative Commons Attribution-NonDerivative-NonCommercial-License, permitting copying and reproduction so long as the original work is given appropriate credit. Contents may not be used for commercial purposes, or adapted, remixed, transformed or built upon. (<https://creativecommons.org/licenses/by-nc-nd/4.0/>)

Thieme Revinter Publicações Ltda., Rua do Matoso 170, Rio de Janeiro, RJ, CEP 20270-135, Brazil

dehydrated alcohol or OK-432.<sup>8,9</sup> Sclerotherapy is a minimally invasive technique for the treatment of ranulas with a success rate < 90%.<sup>8,9</sup> Many surgical techniques have been described in the literature. Whitlock and Summersgill, in 1962, were the first to present a treatment option for plunging ranula (PR) by simple sublingual gland excision without pseudocyst.<sup>10</sup> However, oral ranulas (ORs), in most cases, are treated more conservatively by marsupialization.<sup>11</sup> In OR cases, other surgical procedures include intraoral resection and micromarsupialization.<sup>1</sup> In case of extensive PR, transcervical approach with sublingual and submandibular gland resection with pseudocyst can be performed.<sup>1</sup> Such a number of various surgical strategies is confusing, and there is still no gold standard for the treatment of OR and PR. Also, one of the most controversial issues is whether the pseudocyst of the ranula requires excision. Patel et al.'s online survey of 220 members of the American Head and Neck Society showed that the preferred management of OR (32%) requires sublingual gland excision with pseudocyst, followed by marsupialization (30%), and ranula excision alone (25%).<sup>12</sup> The preferred treatments of PR included excision of the sublingual gland (39%), excision of the ranula, sublingual, and submandibular glands (23%), ranula excision alone (14%), and sublingual gland excision with evacuation of the ranula's sac (13%).<sup>12</sup> Such discrepancy in the choice of preferred methods of treatment indicates that surgeons present insufficient awareness of the etiology of this disease and optimal treatment technique.

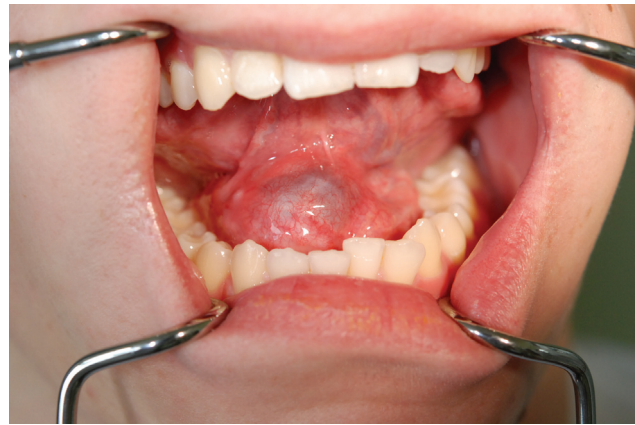This study presents a case series of patients who underwent surgery for OR and PR with different types of modalities in a 1-year period. The aim of the present study is to determine the optimal surgical treatment of ranulas based on our results and those of the literature.

## Method

A retrospective medical chart review was performed based on the K11.6 diagnosis code (mucocele of salivary gland) of the International Classification of Diseases 10<sup>th</sup> revision (ICD-10). The inclusion criteria comprised patients suffering from ranula. The exclusion criteria comprised extravasation cyst of minor salivary gland and parotid and submandibular cysts. Seven patients were treated for sublingual gland ranula (3 with OR, and 4 with PR) in our department between January and December of 2020. The medical charts of the patients were evaluated according to the clinical presentation, methods of treatment, recurrences, follow-up, and outcomes. This study was approved by the Institutional Review Board (No: 122.6120.287.2016). As only medical files were obtained, the review board approved the study without the need for patient consent as long as all personal information was kept confidential.

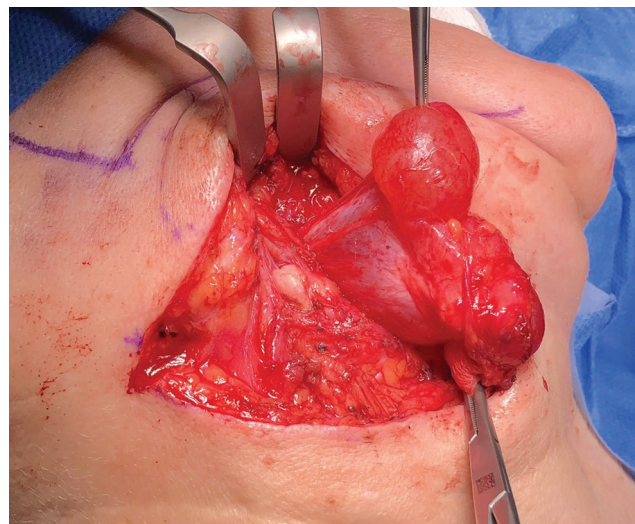
## Result

The group comprised two female and five male patients. The age of the patients ranged from 0.5 to 56 years, with an average of 24.9 years (median 19). All of the patients were of white ethnicity. The diagnosis of OR was based on clinical



**Fig. 1** Clinical manifestation of oral ranula – a typical submucosal bluish, dome-shaped ranula.

examination without imaging. The youngest patient was 6 months old with ankyloglossia complicated by congenital OR. Patients with primary OR were treated under local anesthesia in the outpatient clinic (►Fig. 1). Recurrent OR and PR patients required hospitalization and surgery under general anesthesia (►Fig. 2). Patients with PR were diagnosed on the basis of clinical presentation and magnetic resonance imaging (MRI) examination. Micromarsupialization with sutures was performed according to the technique described by Silva et al.<sup>13</sup> The sutures were maintained up to 30 days after micromarsupialization. The patients' characteristics, treatment, and follow-up are presented in ►Table 1. Patients operated on due to PR by transcervical approach had active drainage for 1 to 2 days following surgery in order to prevent hematoma formation. Transcervical resection of PR was the longest surgical procedure, with an average duration of 110 minutes and ~ 5 days of hospitalization. Intraoral sublingual gland excision was performed according to the technique described by Samant et al.<sup>14</sup> The follow-up protocol comprised visits to the outpatient clinic 1 week and 1 month after the surgery, with ultrasound examination



**Fig. 2** Transcervical excision of plunging ranula with right sublingual gland.

**Table 1** Clinical characteristic of patients with ranulas

Case	Age/ gender	Complaints (months)	Size (mm)	Imaging	Previous surgery (No)	Type	Approach	Treatment	Time of surgery (hospitalization)	Local recurrence	Follow-up (months)
1	19/M	Painful (2)	20 × 15	No	No	OR	Intraoral	Micromarsupialization with sutures	15 min (outpatient)	No	NED (13)
2	0.5/M	Painless (6)	20 × 10	No	No	OR	Intraoral	Frenotomy with marsupialization	10 min (outpatient)	No	NED (11)
6	18/M	Painless (4)	25 × 20	No	Yes (1) marsupialization	OR	Intraoral	Resection of sublingual gland with sac	60 min (3 days)	No	NED (19)
3	35/F	Painless (7)	40 × 25	MRI	Yes (4) Sac resection	PR	Cervical	Resection of sublingual and submandibular gland with sac	110 min (5 days)	No	NED (17)
4	17/M	Painless (9)	50 × 30	MRI/CT	Yes (1) Sac resection	PR	Cervical	Resection of sublingual and submandibular gland with sac	140 min (4 days)	No	NED (12)
5	56/F	Painless (6)	60 × 50	MRI	Yes (2) Sac resection	PR	Cervical	Resection of sublingual gland with sac	80 min (5 days)	No	NED (15)
7	29/M	Painless (3)	40 × 30	MRI	Yes, multiple biopsies	PR	Intraoral	Resection of sublingual gland without sac	75 min (3 days)	No	NED (10)

Abbreviations: CT, computed tomography; F, female; M, male; MRI, magnetic resonance imaging; NED, no evidence of disease; OR, oral ranula; PR, plunging ranula.

being performed 3 and 6 months postsurgery. One year observation without recurrence indicated a favorable outcome.

## Discussion

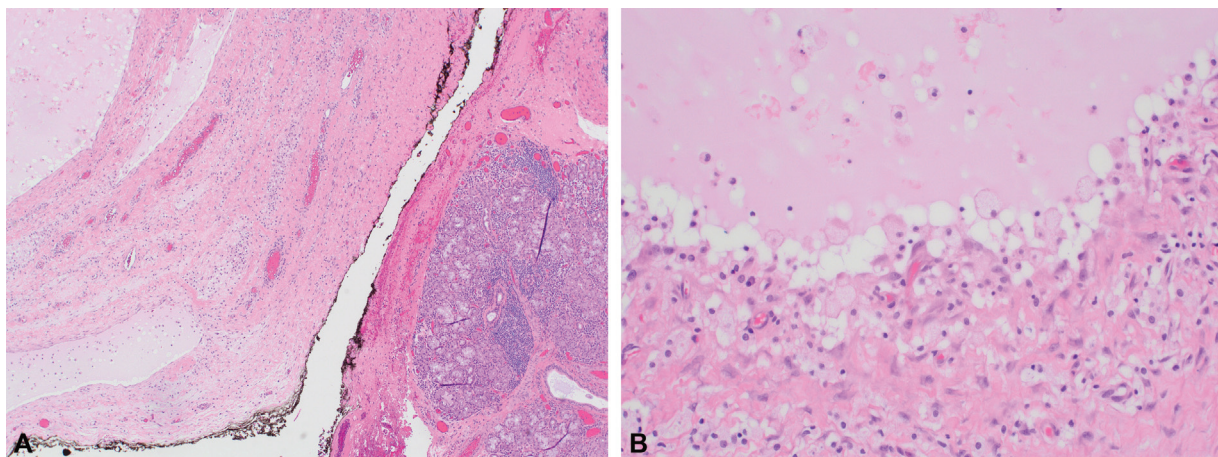
The anatomy of the sublingual gland is quite complex. The sublingual gland lacks capsule or fascial sheath and is divided into two parts.<sup>15</sup> The head consists of numerous minor salivary glands with short Rivinus ducts secreting directly into the oral cavity through the sublingual fold.<sup>15,16</sup> The tail comprises the major part of the sublingual gland with its own Bartholin's duct, which opens into the Wharton's duct or into the oral cavity on the sublingual papilla.<sup>15,16</sup> Understanding the pathomechanism of the ranula's origin plays a crucial role in the proper treatment. Similar to minor salivary glands, the minor part of the sublingual gland is a spontaneous secretor and produces mucus even in the absence of nervous stimulation.<sup>15</sup> For that reason, damage of the Rivinus ducts leads to uncontrolled extravasation of mucus and ranula formation. The mucus initiates an inflammatory reaction of the surrounding tissues and causes the formation of fibrous membrane without epithelium (→Fig. 3).

Most of the ranulas are located in the oral cavity. However, due to the fact that in 36% of cases the mylohyoid muscle can be incomplete, with one or more congenital hiatuses and sublingual gland hernias, the extravasated mucus might spread into the submandibular region, thus causing PR.<sup>17</sup> In the current study, all of the patients were of white ethnicity. However, about 80% of PR cases published in the literature are of Asian ethnic origin.<sup>18</sup> Yin et al. suggested a genetic etiology with predisposition to mylohyoid muscle dehiscence in patients of Pacific Island, Maori, and Asian descent.<sup>14</sup> This group of patients is also characterized by higher risk of bilateral PR occurrence.<sup>19</sup> Harrison, in his literature review, declined the submandibular gland origin of PR, due to the fact that this gland does not present continuous secretion of saliva.<sup>15</sup> Saliva secretion from the submandibular gland occurs only on gustatory stimulation.

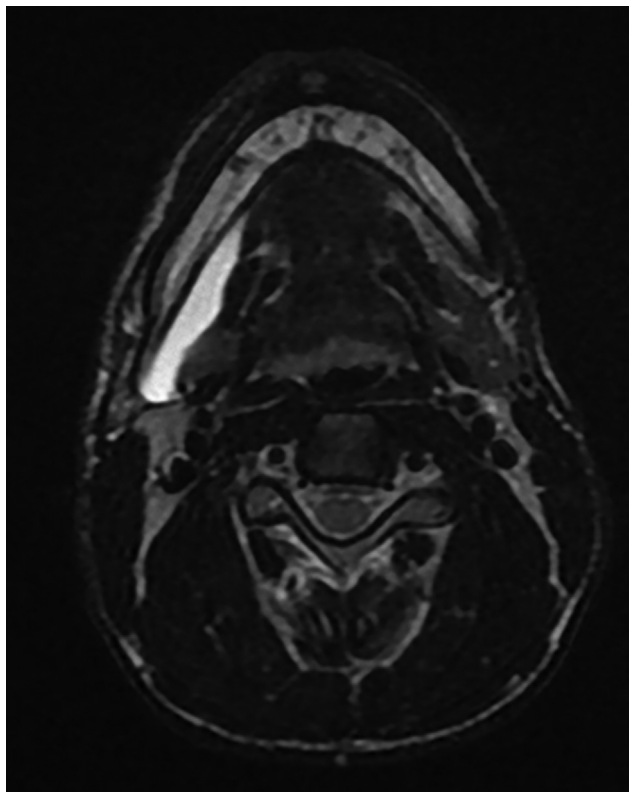
For that reason, extravasation of the saliva is insufficient to overcome the granulation and fibrosis of surrounding tissues that stops leakage.<sup>15</sup>

Oral ranula does not cause problems in the correct preoperative diagnosis, and thorough clinical examination, sometimes without imaging, is sufficient to qualify the patients to the treatment, which can be done under local anesthesia in an outpatient clinic. On the other hand, PR might be misdiagnosed as a lymphatic malformation (lymphangioma, cystic hygroma), dermoid, or brachial cyst.<sup>16</sup> Plunging ranula can be detected in CT, MRI, and ultrasound imaging (→Fig. 4). However, the patients with recurrence of PR after surgical treatment, might be misdiagnosed. For that reason, to confirm PR, O'Connor and McGurk suggest fine needle aspiration cytology (FNAC).<sup>16</sup> The salivary fluid in FNAC is yellow, with mucin and amylase, and does not contain cholesterol crystals, keratin, epithelial, and glandular elements.<sup>16</sup> After FNAC, the pseudocyst can disappear completely, and if PR is not confirmed in cytology, the surgery should be postponed until recurrence of the ranula. Computed tomography or MRI, in primary PR, reveals defects of mylohyoid muscle and propagation of the narrow portion of the cervical pseudocyst into the sublingual space, so called "tail sign".<sup>20,21</sup> In recurrent PR, proper imaging reveals the presence of residual sublingual gland tissue responsible for ranula formation.<sup>2</sup>

Due to the fact that the sublingual gland is responsible for the development of ranulas, radical excision of the sublingual gland is the best treatment modality for both OR and PR.<sup>15</sup> However, there are many surgical procedures with various approaches (intraoral or transcervical) used in the treatment of ranulas. Sublingual gland resection requires general anesthesia and can lead to such complications as lingual nerve or Wharton's duct injury, also extensive bleeding followed by hematoma formation. For that reason, other less invasive surgical procedures, which can be done under local anesthesia in the outpatient clinic, are used in the treatment of OR, such as pseudocyst excision, marsupialization, micromarsupialization with sutures to drain the pseudocyst with



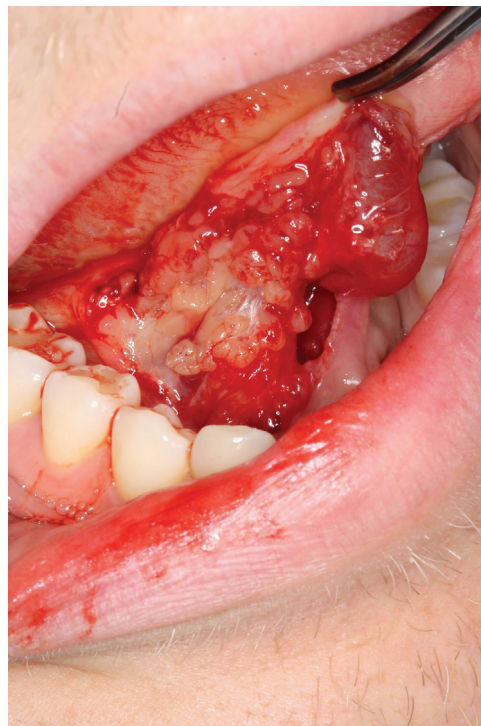
**Fig. 3** (A) A part of an extensive plunging ranula (on the left side) filled with extravasated mucinous saliva in the vicinity of the sublingual salivary gland (right side of the photograph) with focal chronic inflammatory infiltration. Hematoxylin & eosin (H&E) stained. Magnification 106x.; (B) The wall of the ranula lacking epithelium, lined by a thin layer of granulation tissue with visible mucinophages. H&E stained. Magnification 530x.



**Fig. 4** Preoperative magnetic resonance imaging (axial view) of the plunging ranula on the right side. Extravasated saliva extending around the posterior edge of the mylohyoid muscle and reaching the submandibular space.

preservation of the sublingual gland.<sup>1</sup> Nevertheless, these procedures are characterized by a comparatively high risk of ranula recurrence, which is estimated at 21% for marsupialization, 6% for micromarsupialization, and 11% for pseudocyst excision.<sup>1</sup> In case of recurrent ranula, intraoral sublingual gland resection, characterized by the highest cure rate (99%), should be performed.<sup>1</sup> However, Baurmash emphasizes that ranula-like lesions in the floor of the mouth can be observed.<sup>22</sup> Sublingual gland excision seems to be an overtreatment, which is why OR or ranula-like lesions – with the exception of PR – should be treated with caution.<sup>22</sup> According to Zhi et al., the treatment of choice for OR in infant patients includes aspiration of mucus.<sup>23</sup> If the lesion does not resolve after 6 months of observation or recurs repeatedly, surgical treatment is recommended.<sup>23</sup> However, in our study, a 6 month-old patient with OR also suffered from ankyloglossia. In this case, the main goal of the treatment was the improvement of tongue mobility and swallowing. For that reason, frenotomy combined with marsupialization was performed.

Plunging ranula can be treated with the intraoral or transcervical approach. Recurrence after sublingual gland excision is observed in about 1% of cases with the intraoral approach and in 8.5% with the transcervical approach.<sup>1</sup> Recurrence of ranula in such cases is connected with incomplete excision of the sublingual gland and requires revision surgery to remove the residual gland.<sup>2</sup> The cervical approach is technically more difficult, with higher risk of nerve injury,



**Fig. 5** Intraoral resection of sublingual gland with oral component of plunging ranula.

such as the lingual and hypoglossal nerves (n. XII) as well as the marginal mandibular branch of the facial nerve. Complete sublingual gland excision is also more complicated, with higher risk of leaving a residual part of the gland that could cause PR recurrence. Moreover, the operating and hospitalization times are longer. In our material, three patients with PR were operated on primarily with the cervical approach. One patient had four recurrences. All procedures included only sac resection without sublingual gland removal by transcervical approach. In our material, we have not observed nerve disturbance before or after the surgery. In patients with recurrent PR, the cervical approach was used for sublingual gland and pseudocyst resection. This kind of surgical treatment is still recommended by some surgeons.<sup>3,24</sup> In one case of PR, we performed transoral excision without pseudocystic sac, with excellent result (→Fig. 5). According to the literature, this type of surgical treatment of PR has become more popular and should be a gold standard in the treatment of PR.<sup>14,25–28</sup> Intraoral excision helps to avoid the risk of injury of n. XII and the marginal mandibular branch of the facial nerve. Other advantages include the shorter time of surgery and hospitalization, absence of cervical skin scare, and lower risk of PR recurrence. Samant et al., after intraoral sublingual gland excision, observed the following complications: postoperative infection, lingual nerve neuropraxia, and injury of the Wharton's duct requiring submandibular gland excision.<sup>14</sup> For example, Yang and Hong, recommended intraoral sublingual gland excision with pseudocyst's wall and drainage for 2 days in cases of PR.<sup>25</sup> On the other hand, Syebele and Munzhelele proposed intraoral sublingual gland excision without ranula excision and postoperative drainage, which can be done under local

anesthesia.<sup>26</sup> Harrison's meta-analysis of the treatment methods emphasized the lack of understanding of the pathophysiology of PR origin. This implicates sometimes inappropriate therapy of PR.<sup>15</sup> Due to the limited number of patients in a 1-year period, the present study is only an outline of the treatment options for ranulas, taking into account various surgical techniques. Local recurrence is observed usually within 6 months after surgery.<sup>23,27</sup> We did not observe local recurrence in our case series with an average follow-up of 14 months.

## Conclusion

In conclusion, ranula is the most common pathology of the sublingual gland, which is usually observed in adolescents and young adults. Various methods of treatment of OR and PR are used, which can be confusing for surgeons. Micromarsupialization should be considered as the primary treatment for OR. In cases of recurrent OR and primary or recurrent PR, the best results might be obtained by radical excision of the sublingual gland, which can be done without resection of the ranula sac by intraoral approach.

### Conflict of Interests

The authors have no conflict of interests to declare.

## References

- Chung YS, Cho Y, Kim BH. Comparison of outcomes of treatment for ranula: a proportion meta-analysis. *Br J Oral Maxillofac Surg* 2019; 57(07):620–626. Doi: 10.1016/j.bjoms.2019.06.005.
- Chen JX, Zenga J, Emerick K, Deschler D. Sublingual gland excision for the surgical management of plunging ranula. *Am J Otolaryngol* 2018;39(05):497–500. Doi: 10.1016/j.amjoto.2018.05.011
- Kokong D, Iduh A, Chukwu I, Mugu J, Nuhu S, Augustine S. Ranula: Current Concept of Pathophysiologic Basis and Surgical Management Options. *World J Surg* 2017;41(06):1476–1481. Doi: 10.1007/s00268-017-3901-2
- Suzanne G. Recherches anatomiques sur le plancher de la bouche, avec études anatomique et pathogenique sur la grenouillette commune ou sublinguale. *Archives de Physiologie Normale et Pathologique (3rd series)* 1887;10, 141–197.
- von Hippel R Ueber Bau und Wesen der Ranula. *Archiv für klinische. Chirurgie* 1897;55:164–193
- Thompson JE. The relationship between ranula and branchio-genetic cysts. *Ann Surg* 1920;72(02):164–176
- Bhaskar SN, Bolden TE, Weinmann JP. Pathogenesis of mucocoeles. *J Dent Res* 1956;35(06):863–874. Doi: 10.1177/00220345560350060601
- Brannan ZJ, Lubeley LJ, Sutphen SA, Murakami JW. Percutaneous treatment of ranulas: ultrasound-guided drainage with salivary gland chemical ablation. *Pediatr Radiol* 2019;49(06):801–807. Doi: 10.1007/s00247-019-04356-x
- Kono M, Satomi T, Abukawa H, Hasegawa O, Watanabe M, Chikazu D. Evaluation of OK-432 Injection Therapy as Possible Primary Treatment of Intraoral Ranula. *J Oral Maxillofac Surg* 2017;75(02):336–342. Doi: 10.1016/j.joms.2016.08.013
- Whitlock RIH, Summerhill GB. Ranula with cervical extension. Report of a case. *Oral Surg Oral Med Oral Pathol* 1962;15:1163–1171. Doi: 10.1016/0030-4220(62)90151-2
- Baurmash HD. Marsupialization for treatment of oral ranula: a second look at the procedure. *J Oral Maxillofac Surg* 1992;50(12):1274–1279. Doi: 10.1016/0278-2391(92)90226-p
- Patel MR, Deal AM, Shockley WW. Oral and plunging ranulas: What is the most effective treatment? *Laryngoscope* 2009;119(08):1501–1509. Doi: 10.1002/lary.20291
- Silva DFB, Neves GVN, Moura RQ, Carvalho SHG, Pereira JV, Gomes DQC. Modified Micromarsupialization as Treatment of Ranula in a Pediatric Patient. *J Craniofac Surg* 2020;31(03):e230–e232. Doi: 10.1097/SCS.00000000000006114
- Samant S, Morton RP, Ahmad Z. Surgery for plunging ranula: the lesson not yet learned? *Eur Arch Otorhinolaryngol* 2011;268(10):1513–1518. Doi: 10.1007/s00405-011-1509-y
- Harrison JD. Modern management and pathophysiology of ranula: literature review. *Head Neck* 2010;32(10):1310–1320. Doi: 10.1002/hed.21326
- O'Connor R, McGurk M. The plunging ranula: diagnostic difficulties and a less invasive approach to treatment. *Int J Oral Maxillofac Surg* 2013;42(11):1469–1474. Doi: 10.1016/j.ijom.2013.03.019
- Gaughran GRL. Mylohyoid boutonnière and sublingual bouton. *J Anat* 1963;97:565–568
- Morton RP, Ahmad Z, Jain P. Plunging ranula: congenital or acquired? *Otolaryngol Head Neck Surg* 2010;142(01):104–107. Doi: 10.1016/j.otohns.2009.10.014
- Yin T, Jain P, Ahmad Z, Harrison JD, Morton RP. Bilateral Plunging Ranulas in South Auckland: Evidence for a Genetic Basis. *Laryngoscope* 2021;131(01):73–77. Doi: 10.1002/lary.28593
- Coit WE, Harnsberger HR, Osborn AG, Smoker WR, Stevens MH, Lufkin RB. Ranulas and their mimics: CT evaluation. *Radiology* 1987;163(01):211–216. Doi: 10.1148/radiology.163.1.3823437
- Kurabayashi T, Ida M, Yasumoto M, et al. MRI of ranulas. *Neuroradiology* 2000;42(12):917–922. Doi: 10.1007/s002340000341
- Baurmash HD. Treating oral ranula: another case against blanket removal of the sublingual gland. *Br J Oral Maxillofac Surg* 2001;39(03):217–220. Doi: 10.1054/bjom.2000.0606
- Zhi K, Wen Y, Ren W, Zhang Y. Management of infant ranula. *Int J Pediatr Otorhinolaryngol* 2008;72(06):823–826. Doi: 10.1016/j.ijporl.2008.02.012
- Suresh K, Feng AL, Varvares MA. Plunging ranula with lingual nerve tether: Case report and literature review. *Am J Otolaryngol* 2019;40(04):612–614. Doi: 10.1016/j.amjoto.2019.05.017
- Yang Y, Hong K. Surgical results of the intraoral approach for plunging ranula. *Acta Otolaryngol* 2014;134(02):201–205. Doi: 10.3109/00016489.2013.831481
- Syebele K, Munzhelele TI. The anatomical basis and rationale for the transoral approach during the surgical excision of the sublingual salivary gland for the management of plunging ranula. *Am J Otolaryngol* 2020;41(02):102371. Doi: 10.1016/j.amjoto.2019.102371
- Torres Y, Brygo A, Ferri J. A 17-year surgical experience of the intraoral approach for ranulas. *J Stomatol Oral Maxillofac Surg* 2018;119(03):172–176. Doi: 10.1016/j.jormas.2018.02.011
- Huang SF, Liao CT, Chin SC, Chen IH. Transoral approach for plunging ranula—10-year experience. *Laryngoscope* 2010;120(01):53–57. Doi: 10.1002/lary.20674