



Sacro-pelvic Anthropometry in the Portuguese Population and Its Implication for Screw Placement in Spinal Surgery: A Single Centre Retrospective Analysis

Antropometria sacropélvica na população portuguesa e sua importância na colocação de parafusos em cirurgias da coluna vertebral: Análise retrospectiva de um único centro

Catarina da Silva Pereira¹ André Oliveira Mações^{1,2}
 Carolina Luisa Lemos^{2,3} Ricardo Rodrigues-Pinto^{1,2}

¹Spinal Unit, Department of Orthopaedics, Centro Hospitalar do Porto, Porto, Portugal

²Instituto de Ciências Biomédicas Abel Salazar (ICBAS), Porto, Portugal

³Instituto de Investigação e Inovação em Saúde (I3S), Universidade do Porto, Porto, Portugal

Address for correspondence Ricardo Rodrigues-Pinto, MD, PhD, Spinal Unit (UVM), Department of Orthopaedics, Centro Hospitalar do Porto, Largo do Prof. Abel Salazar, 4099-001 Porto, Portugal (e-mail: ric_pinto@hotmail.com).

Rev Bras Ortop 2022;57(6):930–940.

Abstract

Objective The aim of this study was to assess the sacropelvic anthropometry in the Portuguese population, through the study of pelvic computed tomography (CT) scans.

Methods Pelvic CT scans of 40 individuals were analyzed, and the length and angle measurements were performed according to predefined screw trajectories of S1 anterior (S1A), anterolateral (S1AL) and anteromedial (S1AM), S2 anterolateral (S2AL) and anteromedial (S2AM), S2 alar iliac (S2AI), iliac, and sacroiliac (SI) screws. Comparisons between genders were also performed.

Results The S1A screw trajectory mean length was 30.80 mm. The S1AL mean length and lateral angle were 36.48 mm and 33.13°, respectively, and the S1AM's were 46.23 mm and 33.21°. The S2AL mean length was 28.66 mm and lateral angle was 26.52°, and the S2AM length and angle were 29.99 mm and 33.61°, respectively. The S2 alar-iliac screw trajectory mean length, lateral, and caudal angles were 125.84 mm, 36.78°, and 28.66°, respectively. The iliac screw trajectory mean length, lateral, and caudal angles were 136.73 mm, 23,86° and 24.01°, respectively. The sacroiliac screw trajectory length was 75.50 mm. The length

Keywords

- ▶ spinal fusion
- ▶ lumbar vertebrae
- ▶ sacrum
- ▶ anthropometry
- ▶ bone screws

Work developed at the Centro Hospitalar Universitário do Porto, Porto, Portugal. Both authors, Catarina da Silva Pereira and André Oliveira Mações, contributed equally to the manuscript.

received
June 14, 2021
accepted
January 20, 2022
published online
April 25, 2022

DOI <https://doi.org/10.1055/s-0042-1744293>.
ISSN 0102-3616.

© 2022. Sociedade Brasileira de Ortopedia e Traumatologia. All rights reserved.

This is an open access article published by Thieme under the terms of the Creative Commons Attribution-NonDerivative-NonCommercial-License, permitting copying and reproduction so long as the original work is given appropriate credit. Contents may not be used for commercial purposes, or adapted, remixed, transformed or built upon. (<https://creativecommons.org/licenses/by-nc-nd/4.0/>)

Thieme Revinter Publicações Ltda., Rua do Matoso 170, Rio de Janeiro, RJ, CEP 20270-135, Brazil

of the screws was longer in men than in women, except for the S1A and SI screws, for which no difference was found between genders.

Conclusion This study describes sacropelvic anatomical specifications. These defined morphometric details should be taken into consideration during surgical procedures.

Resumo

Objetivo O objetivo deste estudo foi avaliar a antropometria sacropélvica da população portuguesa por meio de exames de tomografia computadorizada (TC).

Métodos Quarenta TCs pélvicas foram analisadas para determinação do comprimento e ângulo das trajetórias definidas dos parafusos, como trajetória anterior (S1A), anterolateral (S1AL) e anteromedial (S1AM) do parafuso no pedículo de S1, trajetória anterolateral (S2AL) e anteromedial (S2AM) do parafuso no pedículo de S2, e trajetória ilíaca alar (S2AI), ilíaca, e sacroilíaca (SI) do parafuso em S2. Comparações entre sexos também foram realizadas.

Resultados O comprimento médio da trajetória S1A foi de 30,80 mm. O comprimento médio e o ângulo lateral de S1AL foram de 36,48 mm e 33,13°, respectivamente, e de S1AM 46,23 mm e 33,21°. O comprimento médio e o ângulo lateral de S2AL foram de 28,66 mm e 26,52° e, de S2AM, 29,99 mm e 33,61°. O comprimento médio da trajetória ilíaca alar e os ângulos lateral e caudal do parafuso em S2 foram de 125,84 mm, 36,78° e 28,66°, respectivamente. O comprimento médio da trajetória ilíaca e os ângulos lateral e caudal foram 136,73 mm, 23,86° e 24,01°, respectivamente. O comprimento da trajetória sacroilíaca foi de 75,50 mm. O comprimento dos parafusos foi maior em homens do que em mulheres, à exceção dos parafusos S1A e SI, que não apresentaram diferenças entre os sexos.

Conclusão Este estudo descreve as especificações anatômicas sacropélvicas. Esses detalhes morfométricos definidos devem ser considerados durante os procedimentos cirúrgicos.

Palavras-chave

- ▶ fusão vertebral
- ▶ vértebras lombares
- ▶ sacro
- ▶ antropometria
- ▶ parafusos ósseos

Introduction

The sacrum is an irregular bone formed by the fusion of five vertebrae with fused transverse processes that make up two large lateral bony masses called the alae. The five vertebrae gradually decrease in diameter toward its caudal end, giving it a unique inverted triangular appearance, with an anterior concavity and posterior convexity. Through the center of the sacral body passes the triangular-shaped sacral canal, which is the continuation of the lumbar vertebral canal. It terminates inferiorly at the sacral hiatus and contains sacral and coccygeal nerve roots, spinal meninges (to the level of S2), and filum terminal. The sacrum, serving as the foundation of the spine, transmits the stress between the spine and the pelvis through the sacroiliac joints.¹

Lumbo-sacro-pelvic instrumentation is frequently performed in posterior pelvic ring injuries, such as sacroiliac joint disruption, unstable sacral fractures, scoliosis, spondylolisthesis, other forms of deformity or instability, and also in long fusion constructs. Each of these indications requires spinopelvic instrumentation to restore optimal spino-pelvic-lower extremity alignment, to provide a secure lumbosacral fixation that can resist cantilever flexion movements, thereby reducing the risk of failure and allow proper weight-bearing.²

In spinal injuries correction, preservation of lower spine mobility may result in implant failure, rod breakage, pseudarthrosis, or neurological deficits. Therefore, extension of spine fusion to the sacrum represents a significant improvement in clinical outcomes and decreases major complications. Lumbopelvic fixation produces an arthrodesis of the lumbosacral junction that immobilizes the joints at the level of the fusion.

In the case of patients that require sagittal spinal realignment and/or neurological decompression, especially in those that undergo pedicle subtraction osteotomy, stabilization through pelvic instrumentation is recommended.³ In cases of high-grade spondylolisthesis, surgical treatment shows high rates of screw pull-out and loss of reduction when instrumentation is used without sacropelvic fixation. When applied, it may improve outcomes and reduce neurologic complications. In patients with neuromuscular deformities, like scoliosis, requiring pelvic obliquity correction, additional pelvic fixation is needed as lumbar or sacral fixation are often insufficient, especially when the deformity reaches the lower levels of the lumbar spine.¹

In patients with multiple injuries from high energy trauma with unstable sacral fractures or sacroiliac joint disruption, a rapid intervention is essential. Because of its close proximity to the sacrum, neurovascular structures may be injured in a sacral fracture, leading to hemodynamic

instability.⁴ While pelvic stabilization with external fixation may be performed in the emergency setting, iliosacral or spinopelvic instrumentation may be required as definitive treatment and to allow for faster weightbearing and avoid complications related to prolonged immobilization (deep vein thrombosis, pneumonia, bed ulcers, among others).³

Instrumentation of the sacrum is challenging. Due to the sacral slope, movements in different planes apply enormous pressure on the sacrum. Furthermore, when approaching the sacrum posteriorly, screw fixation may place anterior anatomic structures at risk if anterior cortical penetration by an implant occurs.

The goal of the present study was to assess the sacropelvic anthropometry in the Portuguese population, through the study of pelvic computed tomography (CT) scans in patient's clinical and imagiological records, and to analyze its implication in screw placement, namely length and orientation, to aid in spinal surgery.

Methods

This is a single-center retrospective medical record review in which the clinical files of 53 patients were analyzed. The SPECTRA IDS7 version 17.3.2086 (Spectra AB, Linköping, Sweden) database was utilized. The selected population included all patients in the database categorized as having performed a pelvic CT scan from November 25, 2019, to February 29, 2020. The study was approved by the local ethics committee (REF: 2019.354(289-DEFI/308-CE).

Out of the 53 patients, 13 were excluded for the following reasons: incomplete/absent CT scans, active fractures, bone neoplasms, osteomyelitis, osteopenic disorders (osteoporosis, osteomalacia), lumbar scoliosis (Cobb angle $> 20^\circ$), spina bifida, in situ spinal or pelvic implants, age < 18 years old, and history of lumbar-sacral-pelvic surgery.

The remaining CT scans from 40 patients were analyzed by running the Digital Imaging and Communications in Medicine (DICOM) files through the Surgimap v2.3.2.1 software (Nemaris Inc., New York, NY, USA).

Measurements of the sacropelvic anthropometry were made based on predefined screw trajectories such as S1 pedicle, in its anterior (S1A), anterolateral (S1AL) and

anteromedial (S1AM) trajectories, S2 pedicle in its anterolateral (S2AL) and anteromedial (S2AM) trajectories, S2 pedicle in its alar iliac (S2AI), iliac, and sacroiliac (SI) trajectories.

The trajectories were measured on the right side of every pelvis, and the measurements were made by two investigators to reduce bias and minimize errors. Each individual measurement was then confirmed and reanalyzed when needed. All measurements were performed without crossing the bone's cortical layer but with the maximum length allowed. In addition to the length, the lateral and caudal angles were also measured, in the axial and sagittal planes, respectively, according to the trajectory being measured. Also, in all screw trajectories it was ensured that the bone corridor was wide enough for the screw to perforate, using a screw with a minimum diameter of 6 mm.

S1 Pedicle Screws

Three trajectories were analyzed. The S1A trajectory was directed into the junction of the sacral ala and vertebral body, with the trajectory making a 90° angle with the horizontal line in the axial plane (\blacktriangleright Fig. 1). The S1AL screw was directed into the sacral ala (\blacktriangleright Fig. 2) and the S1AM into the sacral promontory (\blacktriangleright Fig. 3).

The starting point used was the inferolateral aspect of the S1 facet joint.

S2 Pedicle Screws

The starting point of both S2 pedicle screw trajectories was the fusion between the sacral lamina and the lateral sacral ala with the S2AL being directed laterally (\blacktriangleright Fig. 4) and the S2AM being directed medially (\blacktriangleright Fig. 5).

Measurements in both S1 and S2 trajectories were performed after aligning the screw trajectory parallel to the superior endplate in the sagittal plane since it allows for reduction in screw breakage in axial loading and provides stronger stability.

S2 Alar Iliac Screw

The S2AI screw trajectory starting point used was 1 mm inferior and 1 mm lateral to the S1 dorsal foramen. The direction used was based on the lateral and caudal angles described in existent literature (\blacktriangleright Fig. 6). The mean lateral

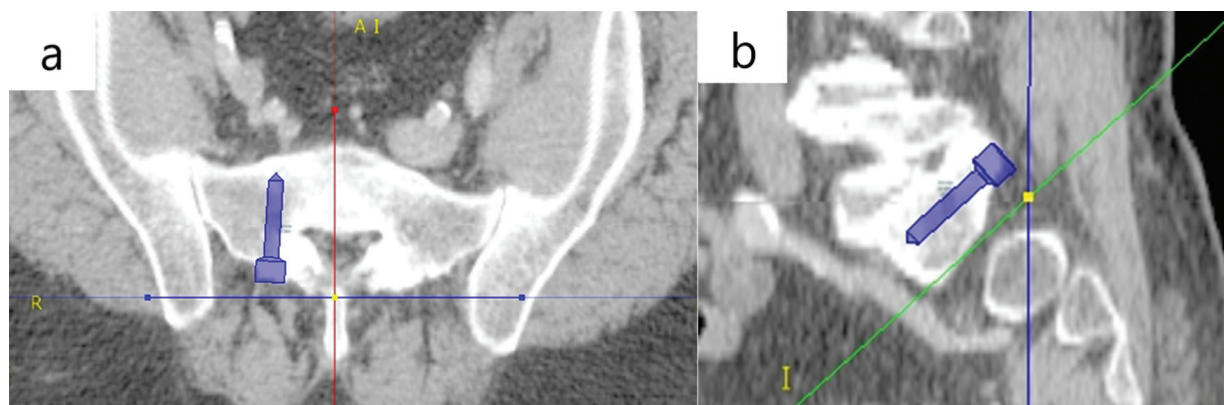


Fig. 1 Illustration of the measurement of the S1A screw trajectory. a) Axial view; b) Sagittal view.

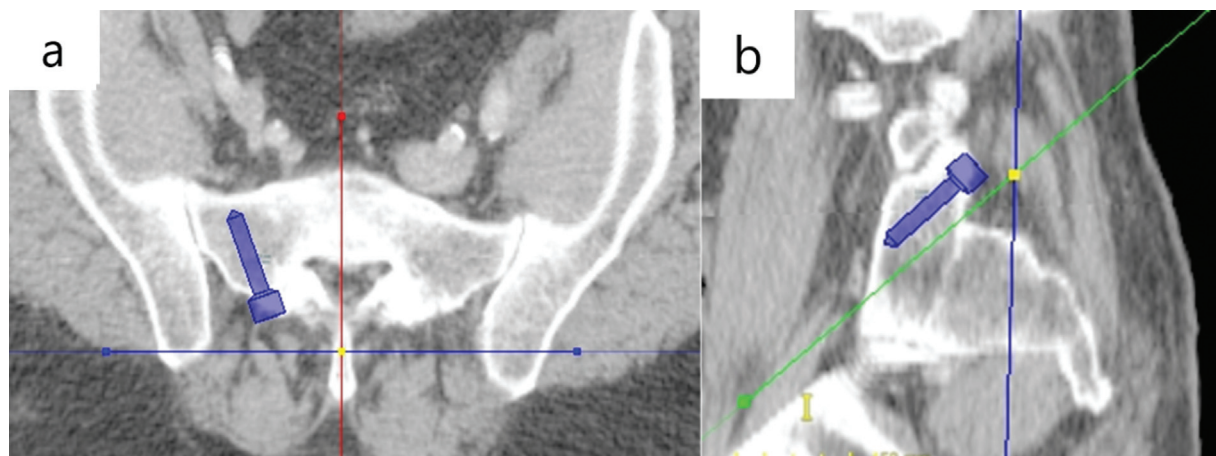


Fig. 2 Illustration of the measurement of the S1AL screw trajectory. a) Axial view; b) Sagittal view.

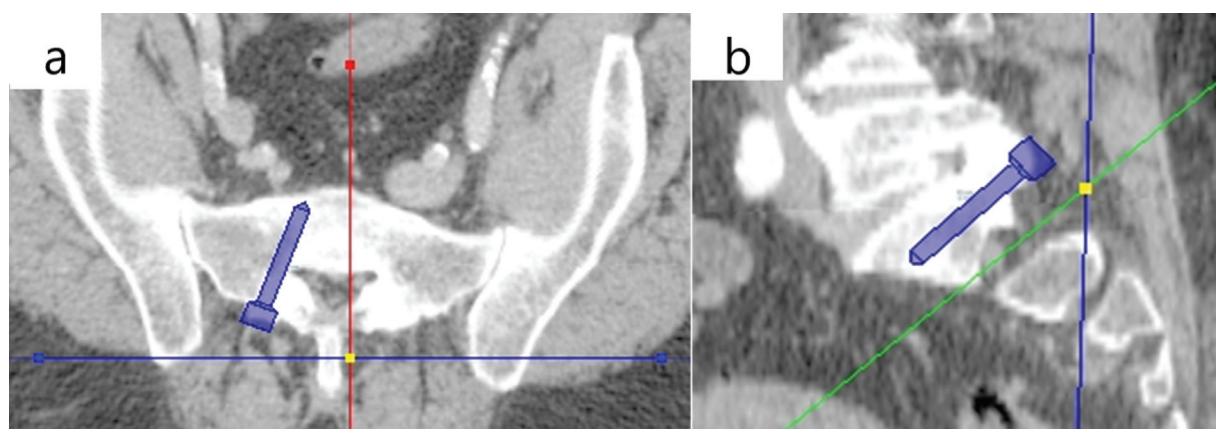


Fig. 3 Illustration of the measurement of the S1AM screw trajectory. a) Axial view; b) Sagittal view

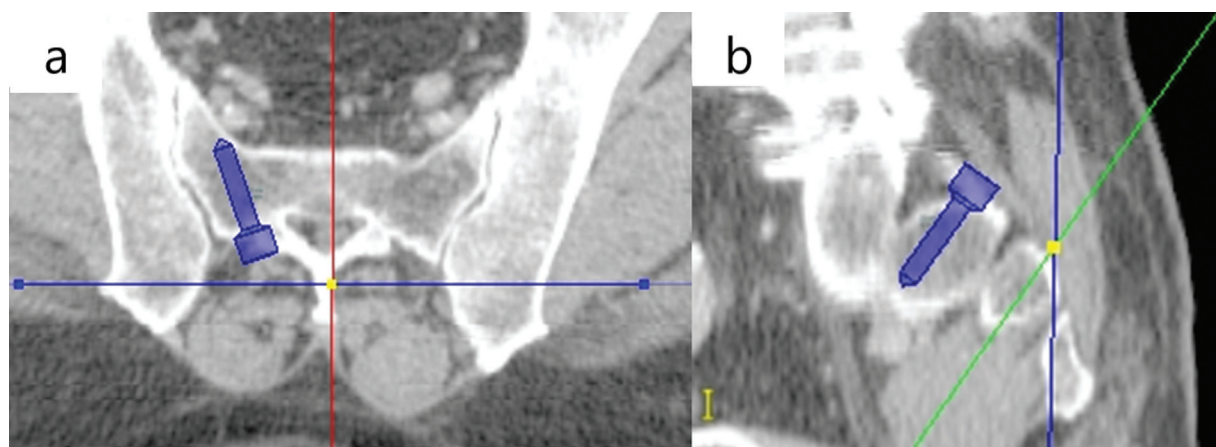


Fig. 4 Illustration of the measurement of the S2AL screw trajectory. a) Axial view; b) Sagittal view.

angles used as reference were 32.40° to 52.20°, and the mean caudal angles were 27.50° to 39°.

Iliac Screw

The iliac screw trajectory starting point was the posterior superior iliac spine (PSIS) into the anterior inferior iliac spine (AIIS) without crossing the cortical layer (► Fig. 7).

Sacroiliac Screw

The SI screw starting point was on the outer table of the ilium, 3 cm anterior to the PSIS and 4 cm cephalad to the greater sciatic notch, through a corridor of bone in the ilium, SI joint, sacral ala, and into the sacral promontory, through the S1 joint. The screw was directed perpendicularly to the outer surface of the table (► Fig. 8).

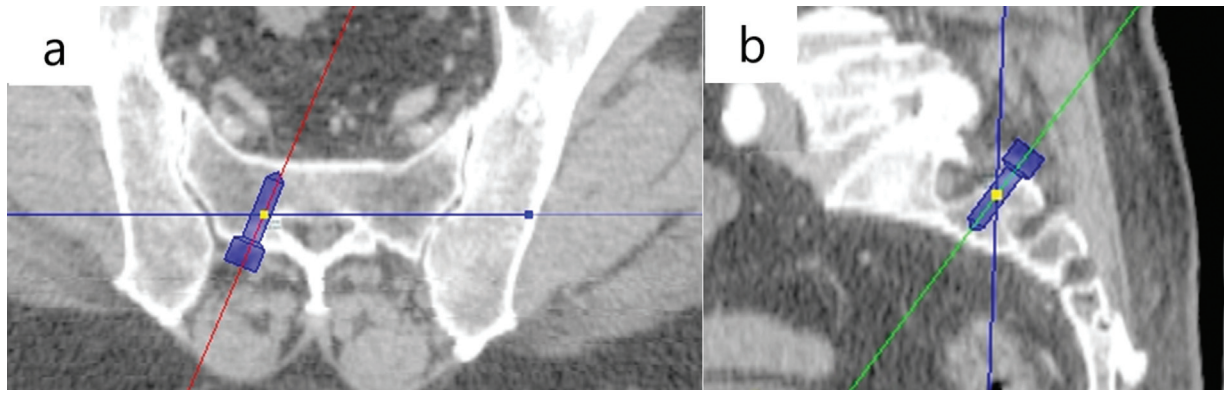


Fig. 5 Illustration of the measurement of the S2AM screw trajectory. a) Axial view; b) Sagittal view.

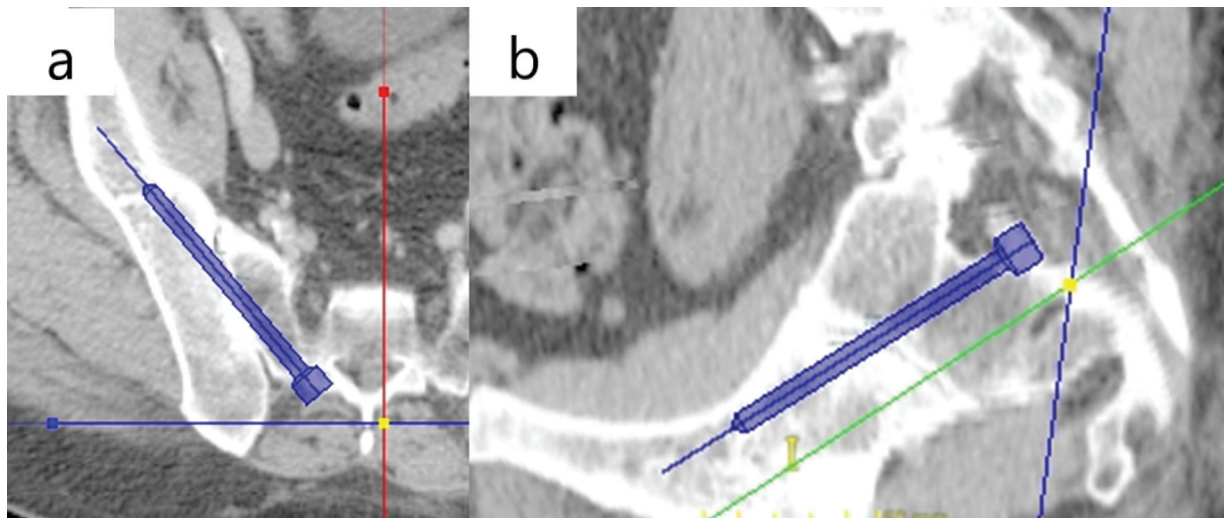


Fig. 6 Illustration of the measurement of the S2AI screw trajectory. a) Axial view; b) Sagittal view.

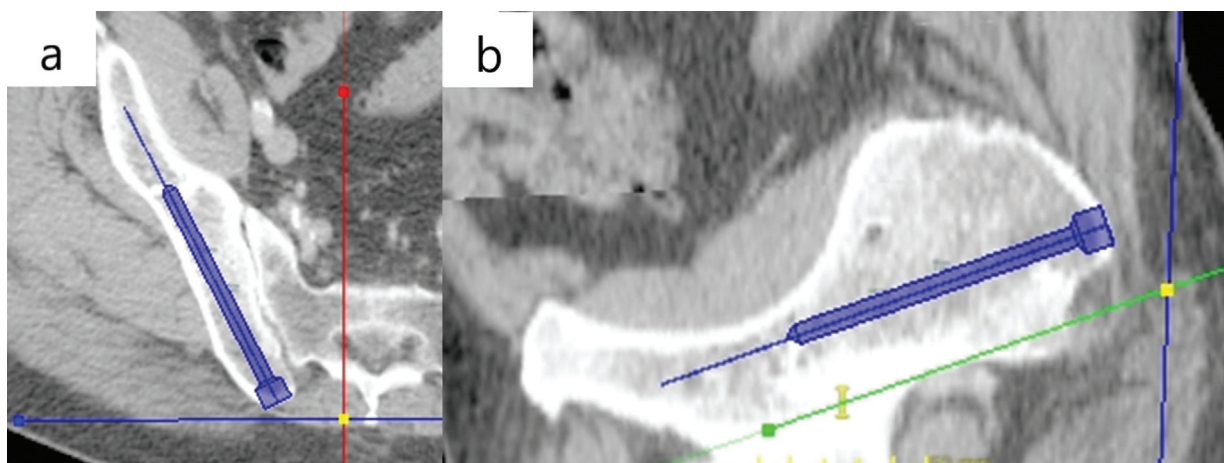


Fig. 7 Illustration of the measurement of the Iliac screw trajectory. a) Axial view; b) Sagittal view.

Statistical Methods

Testing for interobserver correlations was performed with the estimation of the Cronbach α and the intercorrelation matrix.

To get a better understanding of the results obtained, the mean length and angles for each gender were also calculated, and a statistical comparison was made between these parameters, using the *t*-test for independent samples, to

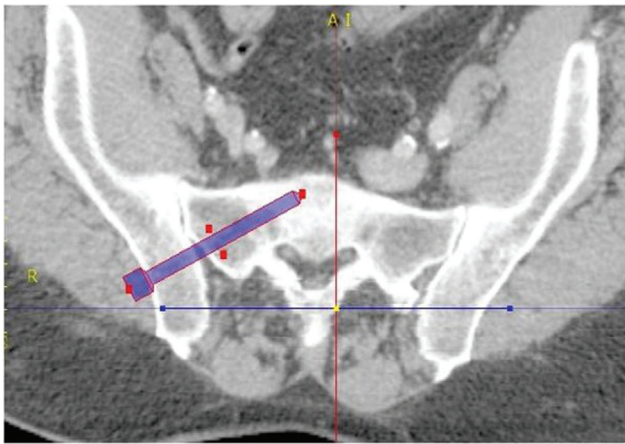


Fig. 8 Illustration of the measurement of the Sacroiliac screw trajectory, axial view.

Table 1 Descriptive analysis of the sample's age by gender

	N	Age (mean ± standard deviation)
Total	40	63.88 ± 15.23
Male	24	65.50 ± 15.18
Female	16	61.44 ± 15.46

identify statistically significant differences. A $p < 0.05$ was considered significant.

Data was collected in Microsoft Excel Version 2013 (Microsoft Corp., Redmond, WA, USA) and transferred to IBM SPSS Statistics for Windows, Version 26.0 (IBM Corp., Armonk, NY, USA) for descriptive and analytical statistics.

Results

The studied population was composed of 24 men and 16 women (60% and 40%, respectively), the mean age at the date of data collection was 63.88 years old (►Table 1).

There was good correlation ($\alpha > 0.5$) between the measurement performed by the two investigators for all meas-

urements and angles, except for the S2AL screw length (►Table 2).

For each individual, the mean length and angulation for each trajectory (►Table 3) and for gender (►Table 4) were calculated.

The correlation between male and female demonstrated that mean screw length in males was higher than in women for the S1AL, S1AM, S2AL, S2AM, S2AI, and iliac screws ($p < 0.05$). There were no significant differences for the S1A and SI screw length or between the angles in each gender (►Table 5).

Discussion

Pedicle screw fixation using S1 and S2 pedicle screws has been relatively successful, especially in lower spine fixation. Nevertheless, there are still instrumentation failures and pseudarthrosis with this procedure.⁵

The low mineral density of the sacral bone and the large loads acting in the lumbar spine and pelvis result in a high risk of pull-out and loosening of the instrumentation, mostly in long fusion constructs in the treatment of spondylolisthesis or scoliosis. Therefore, some modified techniques have been introduced to improve the fixation strength, provide appropriate biomechanical support, and decrease failure rates with screw fixation. Those techniques are the S2AI screw and the iliac screw, which reduce the stress in the S1/S2 screw. Fusion rates in the lumbosacral junction have improved over 90% using these two techniques.¹

In addition, injuries like posterior pelvic ring fractures and SI joint disruptions are difficult to manage because the pelvis has an irregular and complex cortical surface and is also a weight-bearing structure supporting 70% of body weight. Dynamic imbalance of the pelvis caused by poor fracture reduction often results in dysfunctions of weight bearing, which are also serious complications. In view of these, challenges still exist, for orthopedic surgeons, to acquire high-quality reduction of the posterior pelvic ring.⁶

Due to increasingly sophisticated techniques for sacral instrumentation, it is of vital importance to have anatomic

Table 2 Inter-investigator reliability test, for each screw trajectory and angles

Screw trajectory	Interobserver reliability	Trajectory angles	Interobserver reliability
S1A	0.596		
S1AL	0.843	Lateral	0.756
S1AM	0.689	Lateral	0.701
S2AL	0.280	Lateral	0.516
S2AM	0.806	Lateral	0.554
S2AI	0.784	Lateral	0.630
		Caudal	0.753
Iliac	0.772	Lateral	0.435
		Caudal	0.546
Sacroiliac	0.806		

Table 3 Results for each trajectory measured considering length and angulation

	N	Minimum	Maximum	Mean	Standard deviation
S1A length	40	23.50	39.50	30.80	3.31
S1AL length	40	27.50	49.50	36.48	5.39
S1AL angle	40	20.50	46.00	33.13	6.06
S1AM length	40	39.50	53.00	46.23	3.36
S1AM angle	40	25.00	41.00	33.21	3.86
S2AL length	40	23.50	36.50	28.66	2.46
S2AL Angle	40	18.50	33.25	26.52	3.31
S2AM length	40	24.25	42.00	29.99	4.05
S2AM angle	40	25.00	42.75	33.61	3.53
S2alar length	40	106.50	145.00	125.84	8.19
S2alar lateral angle	40	29.75	46.25	36.78	3.27
S2alar caudal angle	40	15.75	39.75	28.66	5.78
Iliac length	40	120.00	156.00	136.73	8.75
Iliac lateral angle	40	17.00	30.25	23.86	3.00
Iliac caudal angle	40	14.25	33.25	24.013	5.34
Sacroiliac length	40	62.0	83.50	75.50	4.75

Table 4 Results for each trajectory measured considering length and angulation by gender

	N	Gender	Mean	Standard deviation	Standard error mean
S1A	24	M	31.35	3.50	0.71
	16	F	29.97	2.91	0.73
S1AL	24	M	38.26	5.58	1.14
	16	F	33.81	3.88	0.97
S1AL angle	24	M	32.73	5.74	1.17
	16	F	33.73	6.66	1.67
S1AM	24	M	47.58	3.15	0.64
	16	F	44.19	2.62	0.65
S1AM angle	24	M	33.84	3.85	0.79
	16	F	32.27	3.80	0.95
S2AL	24	M	29.35	2.56	0.52
	16	F	27.63	1.93	0.48
S2AL angle	24	M	27.11	3.23	0.66
	16	F	25.63	3.32	0.83
S2AM	24	M	31.01	4.41	0.90
	16	F	28.45	2.96	0.74
S2AM angle	24	M	33.10	2.33	0.48
	16	F	34.36	4.80	1.20
S2AI	24	M	128.83	7.61	1.55
	16	F	121.34	7.06	1.76
S2AI lateral angle	24	M	36.79	3.17	0.65
	16	F	36.77	3.51	0.88

Table 4 (Continued)

	N	Gender	Mean	Standard deviation	Standard error mean
S2AI caudal angle	24	M	28.18	6.09	1.24
	16	F	29.39	5.38	1.34
Iliac	24	M	140.69	7.80	1.59
	16	F	130.78	6.57	1.64
Iliac lateral angle	24	M	23.98	2.70	0.55
	16	F	23.69	3.48	0.87
Iliac caudal angle	24	M	24.15	5.09	1.04
	16	F	23.81	5.85	1.46
Sacroiliac	24	M	75.35	4.56	0.93
	16	F	75.72	5.18	1.29

Table 5 Correlational analysis between genders for each screw measurement

	Significance (2-tailed)	Mean difference	Standard error difference
S1A	0.198	1.39	1.06
S1AL	0.009	4.45	1.61
S1AL angle	0.614	-1.01	1.98
S1AM	0.001	3.40	0.95
S1AM Angle	0.209	1.59	1.24
S2AL	0.027	1.73	0.75
S2AL angle	0.166	1.49	1.05
S2AM	0.049	2.56	1.26
S2AM angle	0.276	-1.26	1.14
S2AI	0.003	7.49	2.39
S2AI lateral angle	0.981	0.03	1.07
S2AI caudal angle	0.522	-1.21	1.88
Iliac	0.000	9.91	2.37
Iliac lateral angle	0.767	0.29	0.98
Iliac caudal angle	0.849	0.33	1.74
Sacroiliac	0.816	-0.36	1.55

references, especially related to length and angle for screw insertion to reduce complications, provide augmented load bearing stability to the patient's pelvis and maintain patient safety.

There are several studies that describe the anthropometric traits of some of the sacropelvic screw trajectories. Despite that, none of them has a complete description of all the major screw trajectories in the same population. Furthermore, there are no anatomic references for sacropelvic screw placement in the Portuguese population. Therefore, it is important to provide those references and to integrate this knowledge with that from the available international literature (→ **Table 6**).^{5,7-11}

In addition to screw length, which is important when considering biomechanical stability and risk of neuro-

vascular injury, the usage of appropriate angulation must also be considered. Mirkovic et al.¹² concluded that the length of laterally oriented sacral screws depends mainly on the degree of orientation; using a 30° angle, the mean screw length was 38 mm, and with a 45° angle, the length was 44 mm for the S1AL. However, achieving maximum distance in screw trajectory does not provide the best outcome as it was reported that 45° laterally oriented screws to the sacral wing had a high potential for lumbosacral trunk impingement (55%), and the rate of sacroiliac joint injury was 10%. Hence a well-positioned shorter screw is preferable than a longer but poorly placed one.

Ota et al.⁵ compared two surgical approaches to the S1 pedicle screw entry point and concluded that the technique

Table 6 Comparison between the current study measurements and international literature

Trajectory	Articles										
	Current study		Total	Xu et al. ¹⁶	Asher et al. ⁸	Ota et al. ⁵	Zhu et al. ¹¹	Berry et al. ⁹	Ebraheim et al. ¹⁷		
	Gender										
S1A	M	31.35	30.80	30	-	-	-	-	-	-	
	F	29.97									
S1AL	M	38.26	36.48	-	39	-	-	-	-	-	
	F	33.81									
S1AL angle	M	32.73	36.48	-	25	-	-	-	-	-	
	F	33.73									
S1AM	M	47.58	46.23	-	50	46	-	-	-	-	
	F	44.19									
S1AM angle	M	33.84	33.21	-	35	23	-	-	-	-	
	F	32.27									
S2AL	M	29.35	28.66	34	-	-	-	-	-	-	
	F	27.63									
S2AL angle	M	27.11	26.52	30	-	-	-	-	-	-	
	F	25.63									
S2AM	M	31.01	29.99	32	-	-	-	-	-	-	
	F	28.45									
S2AM angle	M	33.10	33.61	30	-	-	-	-	-	-	
	F	34.36									
S2AI	M	128.83	125.84	-	-	-	121	-	-	-	
	F	121.34									
S2AI lateral angle	M	36.79	36.78	-	-	-	37	-	-	-	
	F	36.77									
S2AI caudal angle	M	28.18	28.66	-	-	-	30	-	-	-	
	F	29.39									
Iliac	M	140.69	136.73	-	-	-	-	147	-	-	
	F	130.78									
Iliac lateral angle	M	23.98	23.86	-	-	-	-	-	-	-	
	F	23.69									
Iliac caudal angle	M	24.15	24.013	-	-	-	-	-	-	-	
	F	23.81									
Sacroiliac	M	75.35	75.50	-	-	-	-	-	-	80	
	F	75.72									

used was influenced by the insertion angle of the screw, which had an effect in trajectory distance. The distance measured for the S1AM was 46 mm, with a 23° angle using the same entry point as in the current study. The S1AM measurements in Asher et al.⁹ were 50 mm in males and 47 mm in females, with a predetermined angulation of 35°. It is generally agreed that the anteromedial trajectory provides greater stability than S1A and S1AL, because the bone density in the central region of the sacrum is greater than in the sacral ala by 30 to 60%.⁵ Here, the length and angle for males and females were 48 mm and 34° and 44 mm and 33°, respectively.

Berry et al.¹⁰ analyzed two trajectories for iliac screw placement: the starting point was the PSIS into either the AIIIS or the superior rim of the acetabulum, measuring 147 mm in males and 141 mm in females, and 128 mm in males and 124 mm in females, respectively. The study concluded that the trajectory into the AIIIS was safer because it was longer and provided more security, while, conversely, the other trajectory had risk of acetabular penetration.¹⁰ Therefore, in the current study, the trajectory used was into the AIIIS, and the distance measured was 141 mm in males and 131 mm in females. The lateral and caudal angles measured were 24° for either angle or gender.

The S2AI and iliac screws are both used for sacropelvic stabilization. The iliac screw has been widely used, but its entry point at the PSIS requires considerable soft tissue dissection to remove the bone block for screw insertion, which has the potential to increase the risk of wound complications, and increase postoperative pain secondary to the extensive soft-tissue manipulation.¹³ Previous studies have shown that 44% of patients treated with iliac screws suffer from complications related to implant failure or prominence over the PSIS.⁷ The S2AI screw has been more recently described to obviate some of these caveats.¹⁴ Its entry point is medial to the iliac screw, requiring less soft-tissue dissection and avoiding instrumentation prominence, among other advantages.¹³

Sacral dysmorphism is defined by variations in the normal sacral anatomy, such as angulated upsloping sacral ala, transverse processes termed “mamillary bodies,” incomplete upper sacral segment disk space, deformed noncircular-appearing upper sacral neural foramina, and tongue-in-groove undulating sacroiliac joint surfaces.¹⁵ In this study, sacral dysmorphism was not an exclusion criteria, because almost half (44%) of the adult population is classified as having a dysmorphic sacrum.¹⁶ The sacroiliac screw trajectory is the most affected by sacral dysmorphism. In dysmorphic sacral bones, the upper sacral segment safe zone is significantly smaller and more obliquely oriented, which can constitute a problem for proper screw placement. However, the bone corridor is still large enough to accommodate an iliosacral screw in nearly all patients. In 97% of males and 94% of females with dysmorphic pelvis, there is a wide enough bone corridor (> 7.5 mm) for oblique sacroiliac screw fixation in the S1 vertebra.¹⁷

Therefore, excluding those cases would not constitute an advantage or allow the sample to be representative of the population.

The present study has some limitations. First, only the right side of the patient's pelvis was measured. Second, whereas the Surgimap software used is reliable and user friendly, all measurements were made manually and are investigator dependent. To overcome this limitation, two independent investigators measured the screw trajectory lengths and angles, and a good concordance was obtained for all but one measurement.

Conclusion

This study describes sacropelvic anatomical specifications. These defined morphometric details should be taken into consideration during surgical procedures.

Financial Disclosure

The authors have no financial disclosures to declare.

Conflict of Interests

The authors have no conflict of interests to declare.

References

- 1 El Dafrawy MH, Raad M, Okafor L, Kebaish KM. Sacropelvic Fixation: A Comprehensive Review. *Spine Deform* 2019;7(04):509–516
- 2 Alvis-Miranda HR, Farid-Escorcia H, Alcalá-Cerra G, Castellar-Leones SM, Moscote-Salazar LR. Sacroiliac screw fixation: A mini review of surgical technique. *J Craniovertebr Junction Spine* 2014;5(03):110–113
- 3 Esmende SM, Shah KN, Daniels AH. Spinopelvic Fixation. *J Am Acad Orthop Surg* 2018;26(11):396–401
- 4 Rodrigues-Pinto R, Kurd MF, Schroeder GD, et al. Sacral Fractures and Associated Injuries. *Global Spine J* 2017;7(07):609–616
- 5 Ota M, Neo M, Fujibayashi S, Takemoto M, Nakamura T. Advantages of the paraspinal muscle splitting approach in comparison with conventional midline approach for s1 pedicle screw placement. *Spine (Phila Pa 1976)* 2010;35(11):E452–E457
- 6 Bi C, Wang Q, Nagelli C, Wu J, Wang Q, Wang J. Treatment of Unstable Posterior Pelvic Ring Fracture with Pedicle Screw-Rod Fixator Versus Locking Compression Plate: A Comparative Study. *Med Sci Monit* 2016;22:3764–3770
- 7 Zhu F, Bao HD, Yuan S, et al. Posterior second sacral alar iliac screw insertion: anatomic study in a Chinese population. *Eur Spine J* 2013;22(07):1683–1689
- 8 Xu R, Ebraheim NA, Mohamed A, el-Gamal H, Yeasting RA. Anatomic considerations for dorsal sacral plate-screw fixation. *J Spinal Disord* 1995;8(05):352–356
- 9 Asher MA, Strippgen WE. Anthropometric studies of the human sacrum relating to dorsal transsacral implant designs. *Clin Orthop Relat Res* 1986;(203):58–62
- 10 Berry JL, Stahurski T, Asher MA. Morphometry of the supra sciatic notch intrailiac implant anchor passage. *Spine (Phila Pa 1976)* 2001;26(07):E143–E148
- 11 Ebraheim NA, Xu R, Biyani A, Nadaud MC. Morphologic considerations of the first sacral pedicle for iliosacral screw placement. *Spine (Phila Pa 1976)* 1997;22(08):841–846
- 12 Mirkovic S, Abitbol JJ, Steinman J, et al. Anatomic consideration for sacral screw placement. *Spine (Phila Pa 1976)* 1991;16(6, Suppl):S289–S294

- 13 Wu AM, Chen D, Chen CH, et al. The technique of S2-alar-iliac screw fixation: a literature review. *AME Med J* 2017;2:1–8
- 14 O'Brien JR, Yu WD, Bhatnagar R, Sponseller P, Kebaish KM. An anatomic study of the S2 iliac technique for lumbopelvic screw placement. *Spine (Phila Pa 1976)* 2009;34(12):E439–E442
- 15 Miller AN, Routt ML Jr. Variations in sacral morphology and implications for iliosacral screw fixation. *J Am Acad Orthop Surg* 2012;20(01):8–16
- 16 Gardner MJ, Morshed S, Nork SE, Ricci WM, Chip Routt ML Jr. Quantification of the upper and second sacral segment safe zones in normal and dysmorphic sacra. *J Orthop Trauma* 2010;24(10):622–629
- 17 Wendt H, Gottschling H, Schröder M, et al. Recommendations for iliosacral screw placement in dysmorphic sacrum based on modified in-out-in corridors. *J Orthop Res* 2019;37(03):689–696