



Can the Processed EEG Be Utilized as a Cerebral Ischemia Monitor during the Temporary Clip Application in Anterior Circulation Aneurysm Surgery?

Ramamani Mariappan¹ Srinivasa B. Krothapalli² Bijesh R. Nair² Benjamin F. Alexander²

¹Department of Neuroanaesthesia, Christian Medical College, Vellore, Tamil Nadu, India

²Department of Neurological Sciences, Christian Medical College, Vellore, Tamil Nadu, India

Address for correspondence Ramamani Mariappan, MD, FNA, FNCC, Department of Neuroanaesthesia, Christian Medical College, Vellore 632004, Tamil Nadu, India (e-mail: ramamani@cmcvellore.ac.in).

J Neuroanaesthesiol Crit Care 2022;9:121–124.

Abstract

Patients undergoing cerebral aneurysm clipping are at risk for cerebral ischemia. Ischemic tolerance varies among individuals. Hence, multimodal intraoperative neuro-monitoring (IONM) is essential. IONM is not available in many centers. This case report highlights the utilization of processed electroencephalography (EEG) as a cerebral ischemia monitor during temporary clip application. Our patient underwent clipping of a ruptured anterior-communicating artery aneurysm. After the temporary clip applications on the right and left, A₁ arterial segments led to a transient drop of somatosensory evoked potentials (SSEPs). At the same time, the frontal four-channel processed EEG showed a burst suppression (BS) pattern. Blood pressure augmentation and the removal of temporary clips helped restore the SSEP back to baseline and the disappearance of the BS pattern in processed EEG. During the steady state of anesthesia, the sudden appearance of the BS pattern in processed EEG can be attributed to clip-induced cerebral ischemia after ruling out other potential causes for BS.

Keywords

- ▶ aneurysm clipping
- ▶ cerebral ischemia
- ▶ intraoperative neuromonitoring
- ▶ four-channel frontal processed EEG
- ▶ somatosensory evoked potential

Introduction

Anesthetic management of a patient undergoing clipping of a ruptured cerebral aneurysm involves maintaining cerebral perfusion pressure, adequate brain relaxation, neuroprotection, and facilitation of intraoperative neuromonitoring (IONM). During aneurysm surgery, a temporary clip is often applied on the parent vessel to gain proximal control while dissecting the neck of the aneurysm. It decreases the trans-

mural pressure, thereby preventing intraoperative aneurysmal rupture. However, temporary clip application is associated with a risk of cerebral ischemia. Ischemic tolerance time varies among individuals. It depends on blood pressure (BP), associated comorbidities, collateral circulation, and the amount of neuroprotection (in the form of burst suppression [BS]) at the time of temporary clip application. Multimodal IONM such as somatosensory evoked potentials (SSEPs), motor evoked potentials (MEPs), and raw electroencephalography (EEG)

published online
May 5, 2022

DOI <https://doi.org/10.1055/s-0042-1744396>.
ISSN 2348-0548.

© 2022. Indian Society of Neuroanaesthesiology and Critical Care. All rights reserved.

This is an open access article published by Thieme under the terms of the Creative Commons Attribution-NonDerivative-NonCommercial-License, permitting copying and reproduction so long as the original work is given appropriate credit. Contents may not be used for commercial purposes, or adapted, remixed, transformed or built upon. (<https://creativecommons.org/licenses/by-nc-nd/4.0/>)

Thieme Medical and Scientific Publishers Pvt. Ltd., A-12, 2nd Floor, Sector 2, Noida-201301 UP, India

help to detect cerebral ischemia.^{1,2} The four-channel frontal processed EEG is routinely used for monitoring the depth of anesthesia (DOA). There are several reports of bispectral index (BIS), a processed EEG monitor detecting cerebral ischemia during carotid surgery,³ aortic aneurysm surgery,⁴ and other general surgery.⁵ But the use of BIS/SedLine sedation monitor as cerebral ischemia monitor during cerebral aneurysm surgery is scarcely reported.

This case report highlights the use of processed four-channel EEG in detecting cerebral ischemia during the temporary clip application and its correlation with the SSEP while maintaining the steady state of anesthesia.

Case Report

A 51-year-old woman with hypertension on a calcium channel blocker presented after an anterior communicating artery (AComMA) aneurysm rupture. Her World Federation of Neurological Surgeons score was grade 1, and the Fisher score was grade 2. Four-vessel cerebral digital subtraction angiogram revealed a $7.8 \times 3.8 \times 6.2$ mm (length, neck, width) AComMA aneurysm, filling from the left side. Before inducing the patient, all ASA standard monitors were attached. Induction was performed with propofol (2 mg/kg), fentanyl (2 mcg/kg), and vecuronium (0.1 mg/kg). The intubation response was obtunded with intravenous lidocaine (1.5 mg/kg), fentanyl (0.5 mcg/kg), and esmolol (0.2 mg/kg). After intubation, arterial and subclavian central venous catheters were secured. Surgeons performed a left fronto-temporal craniotomy.

A propofol infusion (60–100 mcg/kg/min) and intermittent doses of fentanyl were used to maintain anesthesia. A vecuronium infusion was titrated to maintain a train-of-four count of one. SSEP monitoring was performed as a part of routine IONM (Cadwell's Cascade IONM system, Kennewick, Washington, United States). Bilateral tibial nerves and the right median nerve (served as a control) were stimulated to obtain the SSEPs. Recording electrodes, subdermal corkscrew stainless steel needle with 1.2-m lead wires, were placed at CZ' for the lower limb and C4' for the right upper limb, referential with FpZ (10–20 system). Stimulation was delivered at the frequency of 4.1 Hz, duration of 0.3 ms, with the stimulus intensity of

40 mA. The ground electrode was placed at the biceps muscle. The recording time base was set between 50 and 100 ms with a bandwidth of 10 to 500 Hz. The measuring peak latencies for the median nerve were N20, P25 and for tibial nerves were P37, N45. Baseline SSEP recordings were obtained under propofol anesthesia (►Fig. 1A, B). DOA was monitored using a four-channel frontal processed EEG using SedLine brain function monitor (SedLine Sedation Monitor, Masimo, Irvine, California, United States). Since the conventional application of EEG electrode (on the forehead) interfered with the surgical field, we applied them on the nasal side. The CB was placed 2 cm below the standard recommended placement across the nasal bridge. The middle electrodes were placed under the lower eyelid, and the lateral most electrodes were placed on the temporal area. The propofol dose was titrated to maintain the patient state index (PSI) between 25 and 50. As the PSI showed a lower range (19–23) compared with the normal recommended range (25–50), the propofol dose was reduced from 100 to 60 to 70 mcg/kg/min. With this dose, the PSI improved to 25 (►Fig. 2A) and remained at a lower normal range. Since the surgical clipping was performed during the peak vasospasm period, we maintained the BP close to her baseline (130–140/70–80 mm Hg). Her DOA remained stable throughout the procedure. The initial phase of aneurysmal dissection was performed without applying the temporary clip. Prior to dissecting the aneurysmal neck, a temporary clip was applied on the left A-1, followed by another clip on the right A-1 segment after a minute. One minute and 30 seconds after the application of the first temporary clip (left-A1) and 30 seconds after applying the second temporary clip (right-A1), the SSEP signal amplitude dropped more than 80% (►Fig. 1A, B). At the time of the SSEP drop, both the EEG and the spectrogram showed frequent suppression (BS) patterns, which lasted for 19 to 21 minutes, with the drop in PSI (►Fig. 2A, B). Hence, the BP was augmented to 150 to 160/90 to 100 mm Hg using vasopressors and intravenous fluids. The temporary clips were removed within 40 seconds from the beginning of the SSEP drop after placing the permanent clip.

After removal of the temporary clips, the SSEP recovered to 50% of the baseline value in 9 minutes and 40 seconds and improved to 100% of baseline in 16 minutes and 20 seconds (►Fig. 1A, B). The processed EEG, the spectrogram pattern,

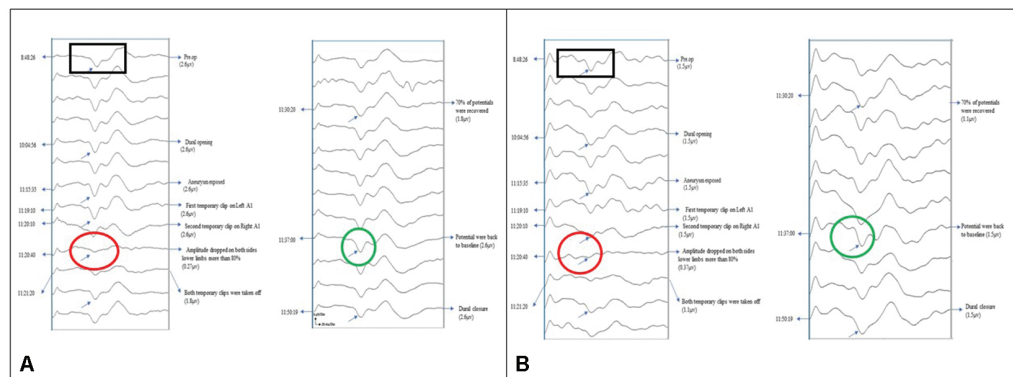


Fig. 1 (A) Somatosensory evoked potential (SSEP) waveforms after the right tibial nerve stimulation. (B) SSEP waveforms after the left tibial nerve stimulation. Baseline SSEP (black box), SSEP drop after the temporary clip application (red circle), and its improvement to baseline (green circle).

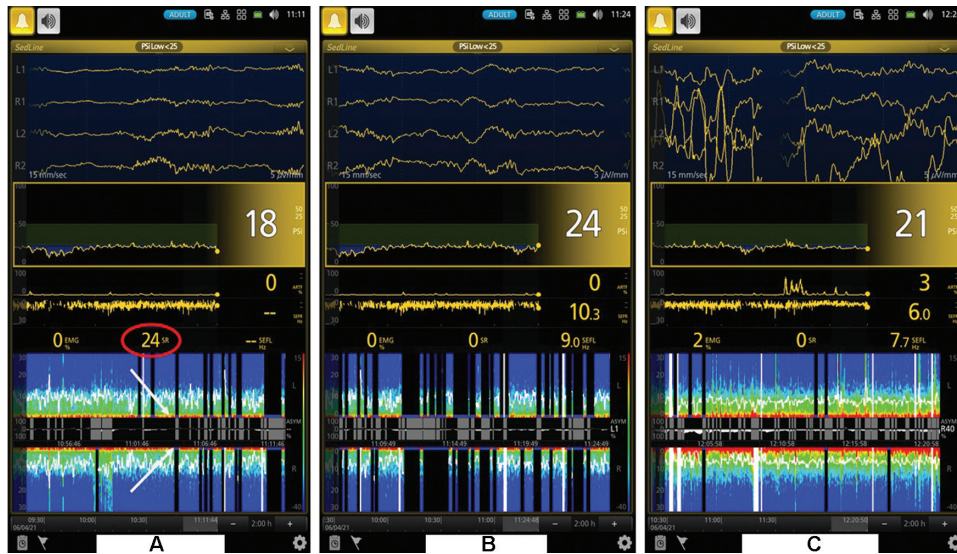


Fig. 2 (A, B) Electroencephalography (EEG), patient state index (PSI), and the spectrogram changes during the temporary clip application. The white arrow in A shows the time of application of the temporary clip. (C) No burst suppression after the temporary clip removal and the blood pressure (BP) augmentation.

and the PSI improved over 21 minutes (→ **Fig. 2C**). The processed EEG took a longer time to reach the baseline potential compared with SSEP (4 minutes and 40 seconds longer). The SSEP and the processed EEG changes were closely correlated. The patient was extubated at the end of the surgery. Her immediate postextubation Glasgow Coma Scale was 14/15 with no neurological deficits. Her postoperative period was uneventful.

Discussion

This case report highlights the correlation between the SSEP and the four-channel frontal processed EEG (placed on the nasal side) in detecting cerebral ischemia during the temporary clip application during the anterior circulation aneurysm surgery during the steady state of anesthesia.

Since the conventional electrode placement on the frontal area interfered with the surgical field, we placed the DOA monitor electrode on the nasal side. Tufegdzcic et al studied the validation of nasal SedLine sensor placement and showed that the measured cerebral activity (EEG) is similar in morphology and frequency to the conventional sensor with interrater agreement or reliability of 88%.⁶ Many studies analyzed the accuracy of alternative positions (nasal, posterior auricular, mandibular, occipital) of BIS sensor and compared it with the conventional placement and showed that the values were comparable within the acceptable range.

We had compared the values of PSI using nasal SedLine sensor placement with the values of conventional BIS sensor placement (> 5 cases); both had a good correlation during the maintenance phase of anesthesia (unpublished data). After which, we routinely place the SedLine sensor on the nasal side for all craniotomy cases involving the frontotemporal area and are satisfied with good clinical correlation.

Empirical neuroprotection in the form of BS (60–70%) is provided in many centers during the temporary clip application to improve the neurological outcome.^{7–9} The BS ratio indicates the total time period during which the EEG is silent in an epoch. The practice of empirical pharmacological neuroprotection makes it challenging to differentiate the ischemia-induced BS (temporary clip application) from propofol-induced BS when the EEG/processed EEG is used to monitor the cerebral ischemia.⁸ In centers where SSEP/MEP is not available, by avoiding routine empirical neuroprotection, the temporary clip-induced ischemic change can be picked up early from the processed EEG monitors and can be treated with BP augmentation or by removing the temporary clip.

Patients presenting late with cerebral vasospasm show a BS pattern on EEG even with the small dose of propofol infusion. In those cases, the EEG/processed EEG cannot be utilized as a cerebral ischemia monitor. The advantage of SSEP monitoring is that even in the presence of a BS pattern, the temporary clip-induced ischemic changes can be picked up (10% increase in latency and 50% drop in amplitude) by the SSEP. Hence, it can be utilized for monitoring cerebral ischemia while simultaneously providing neuroprotection in the form of BS.

Hypoxia, hypothermia (< 22°C), cerebral vasospasm, and anesthetic overdose can cause BS on the processed EEG.⁸ Temperature and oxygenation monitoring can rule out the first two causes. Prolonged administration of propofol can cause BS. In our case, though the PSI remained in the lower normal range, there was no BS noted on EEG/spectrogram until the aneurysmal dissection phase. The gradual increase in propofol concentration in the plasma will cause a gradual drop in PSI or a gradual increase in BS ratio rather than a sudden drop in PSI or a sudden increase in BS ratio. The disappearance of the BS after the temporary clip removal and

BP augmentation and the appropriate waking-up after surgery rules out a propofol overdose.

Studies have shown that multilobar raw EEG is better in predicting ischemia than scalp EEG.¹⁰ Similarly, combined SSEP and MEP monitoring predict ischemia better than SSEP alone. But all of these have some advantages and disadvantages. In this case, the changes in processed EEG using a SedLine sedation monitor (nasal application) showed a good correlation with SSEP changes at the time of temporary clip-induced cerebral ischemia in a patient undergoing anterior circulation aneurysm clipping. Future prospective studies are needed to confirm the utilization of the processed frontal EEG monitor for detecting cerebral ischemia during anterior circulation aneurysm surgery.

Author Contributions

All authors made material contributions to the handling of this case and to the intellectual content of this article.

Conflict of Interest

None declared.

References

- 1 Kang C, Cho AR, Kim KH, et al. Effects of intraoperative low-dose ketamine on persistent postsurgical pain after breast cancer surgery: a prospective, randomized, controlled, double-blind study. *Pain Physician* 2020;23(01):37–47
- 2 Kashkoush AI, Jankowitz BT, Gardner P, et al. Somatosensory evoked potentials during temporary arterial occlusion for intracranial aneurysm surgery: predictive value for perioperative stroke. *World Neurosurg* 2017;104:442–451
- 3 Mérat S, Lévecque JP, Le Gulluche Y, Diraison Y, Brinquin L, Hoffmann JJ. BIS monitoring may allow the detection of severe cerebral ischemia [in French]. *Can J Anaesth* 2001;48(11):1066–1069
- 4 Umegaki N, Hirota K, Kitayama M, Yatsu Y, Ishihara H, Mtasuki A. A marked decrease in bispectral index with elevation of suppression ratio by cervical haematoma reducing cerebral perfusion pressure. *J Clin Neurosci* 2003;10(06):694–696
- 5 Morimoto Y, Monden Y, Ohtake K, Sakabe T, Hagihira S. The detection of cerebral hypoperfusion with bispectral index monitoring during general anesthesia. *Anesth Analg* 2005;100(01):158–161
- 6 Tufegdžic B, Lamperti M, Khozenko A, Achi E, Jayaprakasam S, John TLS. Validation of a nasal SedLine® sensor placement: Going beyond the forehead when the depth of anesthesia is important. *Interdiscip Neurosurg* 2021;26:101310
- 7 Ravussin P, de Tribolet N. Total intravenous anesthesia with propofol for burst suppression in cerebral aneurysm surgery: preliminary report of 42 patients. *Neurosurgery* 1993;32(02):236–240
- 8 Chowdhury T, Petropolis A, Wilkinson M, Schaller B, Sandu N, Cappellani RB. Controversies in the anesthetic management of intraoperative rupture of intracranial aneurysm. *Anesthesiol Res Pract*; 2014; 2014:595837
- 9 Mahajan C, Chouhan RS, Rath GP, et al. Effect of intraoperative brain protection with propofol on postoperative cognition in patients undergoing temporary clipping during intracranial aneurysm surgery. *Neurol India* 2014;62(03):262–268
- 10 Dehdashti AR, Pralong E, Debatisse D, Regli L. Multilobar electrocorticography monitoring during intracranial aneurysm surgery. *Neurocrit Care* 2006;4(03):215–222