



Insulectomy for Refractory Epilepsy: Case Series and Literature Review

Insulectomia para epilepsia refratária: Série de casos e revisão de literatura

Adriano de Medeiros Barbosa Rodrigues¹ Henrique Nicola Santo Antonio Bernardo²
Maria Clara Cardoso Seba² Carlos Alberto de Almeida Castro Junior³ Paulo Roberto Franceschini⁴
Paulo Henrique Pires de Aguiar^{5,6}

¹ Faculdade Israelita de Ciências da Saúde Albert Einstein, São Paulo, SP, Brazil

² Faculdade de Medicina do ABC, Santo André, SP, Brazil

³ Hospital Santa Paula, São Paulo, SP, Brazil

⁴ Universidade de Caxias do Sul, Caxias do Sul, RS, Brazil

⁵ School of Medicine, Pontifícia Universidade Católica de São Paulo, Sorocaba, Brazil

⁶ Medicine School, Faculdade de Medicina do ABC, Santo André, SP, Brazil

Address for correspondence Maria Clara Cardoso Seba, BA, Rua José Abdo Marão, 3418, Votuporanga, São Paulo, 15501-031, Brazil (e-mail: mariaclaracseba@hotmail.com).

Arq Bras Neurocir 2022;41(3):e249–e257.

Abstract

Surgical resection of the insula (insulectomy) is a procedure used for brain lesions and for refractory epilepsy. It has a difficult surgical access and the need of a wide anatomical knowledge and preoperative planning. There are two types of surgical approaches aiming the exposure of the insular cortex: transsylvian and transcortical. The importance of insulectomies is the efficacy in providing a remarkable decrease in seizures. The objective of the present article is to document the results of a series of 10 patients submitted to insulectomies for refractory epilepsies and compare them with the results of other studies reported in the literature, as well as to describe the main nuances of the surgical approaches and their associated risks. In the new case series, all patients corresponded to preoperative Engel classification IV for; after a mean 2-year follow-up period, they corresponded to Engel classification II. A subtotal resection was performed in six patients, and the remaining four underwent a partial resection, most of them leading to temporary complications. The literature review endorsed the good outcomes of the casuistry. A critical analysis of the presented data reiterates the opinion of several authors that insulectomies are beneficial and safe for the patients. A broad anatomical knowledge of the insular region, preoperative planning (limits of resections), and the use of modern microsurgical techniques must be considered as

Keywords

- ▶ island of reil
- ▶ insular cortex
- ▶ refractory epilepsy
- ▶ resective procedures

O presente trabalho foi realizado na Faculdade de Medicina do ABC, Santo André, SP, Brazil.

received
July 16, 2021
accepted
April 6, 2022
published online
August 2, 2022

DOI <https://doi.org/10.1055/s-0042-1749072>.
ISSN 0103-5355.

© 2022. Sociedade Brasileira de Neurocirurgia. All rights reserved. This is an open access article published by Thieme under the terms of the Creative Commons Attribution-NonDerivative-NonCommercial-License, permitting copying and reproduction so long as the original work is given appropriate credit. Contents may not be used for commercial purposes, or adapted, remixed, transformed or built upon. (<https://creativecommons.org/licenses/by-nc-nd/4.0/>)
Thieme Revinter Publicações Ltda., Rua do Matoso 170, Rio de Janeiro, RJ, CEP 20270-135, Brazil

basic principles by neurosurgeons for the prevention of perioperative morbidities. Insulectomies are safe and effective, although they result in temporary postoperative complications, and provide highly satisfactory results in terms of seizure control.

Resumo

A ressecção cirúrgica da ínsula (insulectomia) é um procedimento utilizado para lesões cerebrais e epilepsia refratária. A ínsula possui um acesso cirúrgico difícil com necessidade de um amplo conhecimento anatômico com planejamento pré-operatório. Existem dois tipos de abordagens cirúrgicas que visam a exposição do córtex insular: transsilvianas e transcorticais. A importância das insulectomias é a eficácia em proporcionar uma diminuição das convulsões. O objetivo do presente artigo é documentar os resultados de uma série de 10 pacientes submetidos a insulectomias para epilepsia refratária e compará-los com os resultados de outros estudos relatados na literatura, além de descrever as principais nuances das abordagens cirúrgicas e os seus riscos associados. Na série de casos, todos os pacientes se enquadravam na classificação pré-operatória de Engel IV e, após um período médio de seguimento de 2 anos, eles se enquadravam na classificação de Engel II. Seis pacientes foram submetidos a uma ressecção subtotal e os quatro restantes a uma ressecção parcial, implicando, majoritariamente, em complicações temporárias. A revisão da literatura endossou os bons resultados da casuística. A análise crítica dos dados apresentados reitera a opinião de vários autores de que as insulectomias são benéficas e seguras para os pacientes. O amplo conhecimento anatômico da região insular, o planejamento pré-operatório (limites das ressecções) e a utilização de técnicas microcirúrgicas modernas devem ser considerados princípios básicos para a prevenção de morbidades perioperatórias. As insulectomias são seguras e eficazes conquanto resultem em complicações pós-operatórias temporárias e proporcionem resultados altamente satisfatórios no que diz respeito ao controle das convulsões.

Palavras-chave

- ▶ ilha de reil
- ▶ córtex insular
- ▶ epilepsia refratária
- ▶ procedimentos ressectivos

Introduction

Surgical resection of the insula (insulectomy) is a procedure used for brain lesions and for refractory epilepsy. However, performing this procedure requires a detailed anatomical knowledge of the insula and its surroundings, since its location corresponds to the only cortical region of the brain not visible on the dorsolateral surface of the cerebral hemispheres, which justifies its difficult surgical access and the need of excellent preoperative planning and surgical skills.^{1,2}

There are two types of surgical techniques to approach the insular cortex and perform a total or partial insulectomy: transsylvian and transcortical. Both types of surgical techniques are also associated and combined with other resections of different anatomical locations when needed and, therefore, create different terminologies like operculoinsulectomy (operculum and insula), orbitoinsulectomy (pars orbitalis and insula), or insulectomy plus lobectomy (resection of a brain lobe, for example). In addition, these approaches to the insula are usually associated with good seizure control and acceptable morbidity; nevertheless, it also depends on the histology and location of the lesion.^{3,4} Besides seizure control, a successful surgical procedure aims to provide a positive impact on quality of life.

The knowledge of the insular anatomy, its functions and the clinical presentation of the seizures arising from this location is important for the surgical treatment.

Anatomy of the Insula

The insula, also known as the fifth cerebral lobe, can be described as an external shield of a true brain bloc of anatomically well-defined structures, which is arranged, from lateral to medial, as follows: insular cortex, extreme capsule, claustrum, external capsule, lentiform nucleus, internal capsule, and thalamus.^{5,6}

This lobe, unlike the others, is located in the depth of the lateral sulcus, totally covered by the temporal and frontoparietal opercula, which potentially makes the surgical access more difficult, since, to visualize it, it is necessary to dissect the sylvian fissure and retract the opercula or go transcortical. Only then, the characteristic triangular shape of the insula and the periinsular sulci, which are the anatomical landmarks that separate and distinguish it from the surrounding cortical areas, can be recognized (▶ Fig. 1).^{1,7-9}

On the insular surface, there are three short gyri (anterior, middle, and posterior – divided by the anterior and precentral insular sulci), two long gyri (anterior and posterior – divided by the postcentral insular sulcus) and, very often, two additional gyri situated cranially, called transverse and accessory insular gyrus. The short and long gyri are separated from each other by the central insular sulcus (▶ Fig. 1), which divides the insula into two portions, anterior and posterior, which are connected, to the frontal and temporoparietal lobes, respectively. Finally, the insula is delimited by the anterior, superior, and inferior

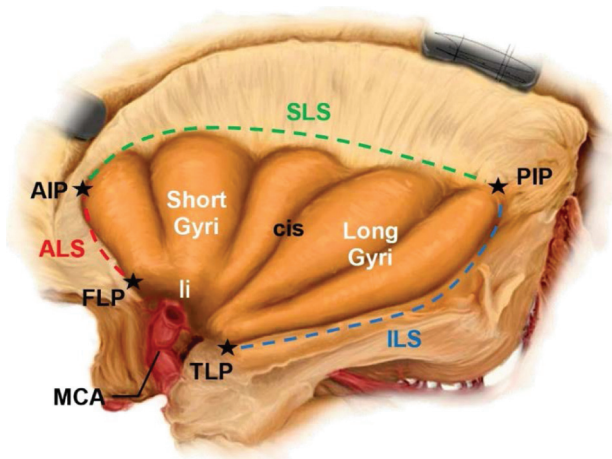


Fig. 1 Representative illustration of the insular cortex and its main anatomical landmarks; the short and long gyri (separated by the central insular sulcus); the anterior, superior, and inferior limiting sulci and, at the anterobasal portion of the insula, the region of the limen (where the sphenoidal segment of the middle cerebral artery bifurcates into M2). Abbreviations: AIP, anterior Insular point; ALS, anterior limiting sulcus; CIS, central Insular sulcus; FLP, frontal limen point; ILS, inferior limen sulcus; LI, limen insulae; MCA, middle cerebral artery; PIP, posterior Insular point; SLS, superior limiting sulcus; TLP, temporal limen point.

limiting sulci, which is also called periinsular sulcus or circular sulcus of the insula.^{8,10,11}

Also considered an important anatomical landmark, located in the most anterobasal portion of the insula, is the limen, corresponding to the level at which the middle cerebral artery (MCA) bifurcates into the M2 branches, laterally to the anterior perforated substance (→Fig. 2).^{8,10,11}

Vascularization of the Insula

The vascular supply to the insula comes from the MCA. The first segment of the MCA is referred to as sphenoidal, or M1, and arises from the ramification of the internal carotid artery (ICA) at the level of the anterior perforated substance, situated superiorly. The lenticulostriate arteries that arise

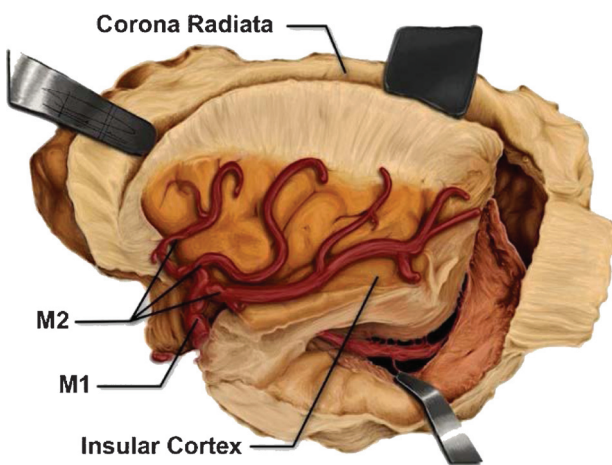


Fig. 2 Illustrative representation of the insular lobe and its adjacent structures, depicting the M1 and M2 branches of the middle cerebral artery (MCA). M1 = M₁ segment of MCA; M2 = M₂ segment of MCA. Source: Ribas et al.¹¹

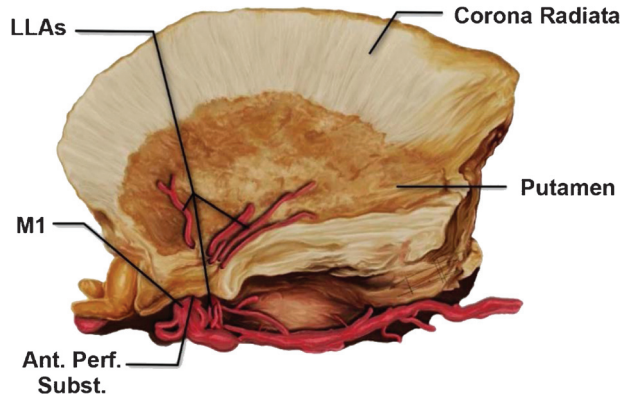


Fig. 3 Illustration representing a lateral view of lateral lenticulostriate arteries (arising from the sphenoidal segment of the middle cerebral artery) crossing the anterior perforated substance and later the lentiform nucleus, after resection, from medial to lateral, of the following structures: Insular cortex, extreme capsule, claustrum, and external capsule. Abbreviations: Ant.Perf.Subst., anterior perforated substance. Source: Ribas et al.¹¹

at the M1 level are extremely important perforators that supply the basal ganglia and the internal capsule. These small arteries should be preserved during surgery at this location to avoid neurological deficits.^{8,10}

At the level of the limen, the M1 (insular segment) branches into M2 segments, one superior and the other inferior, supplying the short and long gyri, respectively. The M2 segment is also important because the long perforating branches projecting superiorly and posteriorly irrigate the corona radiata and, therefore, should be preserved during surgery to prevent ischemic injury resulting in hemiparesis.^{8,10,12-14}

The vascularization of the insula can be seen in more detail in →Figs. 2, 3 and 4.

Functions of the Insula

The function of the insula is not completely understood, probably because there are no isolated insular lesions to

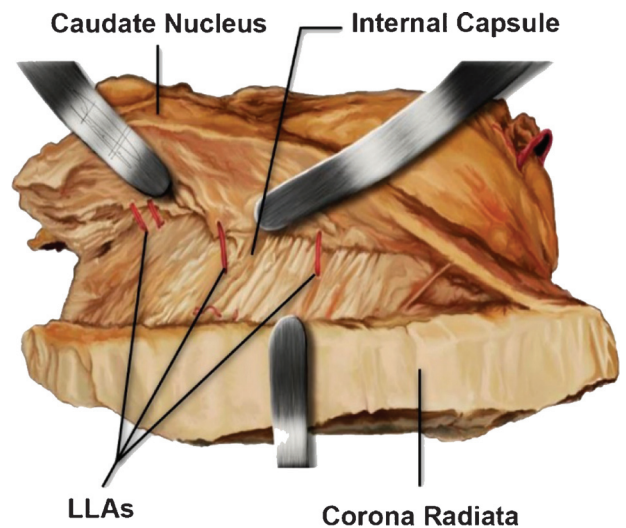


Fig. 4 Illustration representing a superior view of lateral lenticulostriate arteries crossing the internal capsule, with the caudate nucleus medially and, laterally, the internal capsule, after its resection through the sagittal plane. LLAs = lateral lenticulostriate arteries. Source: Ribas et al.¹¹

better understand its neurological deficits.¹⁵ However, there is consistent evidence that this lobe is involved in cognitive functions as well as in sensorimotor and socioemotional processing.

The insular functions related to sensorimotor processing are associated to visceral sensations, autonomic control, interoception, somatic, pain and auditory processing, and vestibular and chemosensory functions. The socioemotional processing functions are related to emotional experience, empathy, and risky decision-making. Finally, the cognitive functions are associated mainly to attention and speech.^{8,9,15,16} In summary, the insula contributes to multiple cognitive and critical functions for human beings and is considered a part of the limbic cortex.

Connectivity

The insula has reciprocal connections with various regions of the brain. The most important insular networks are with the orbitofrontal, anterior cingulate, supplementary motor areas, the parietal and temporal cortex, as well as with subcortical structures, which explains its involvement in many cognitive functions.⁹ These connections can be seen in **Fig. 5**, a reproduction of an image by Shelley et al.¹⁷

Semiology of Insular Epilepsies

Since the insula establishes several reciprocal connections with various cortical and subcortical areas of the brain, the semiology of seizures is characteristically heterogeneous, presenting many differences regarding the manifestation of symptoms and clinical signs. The most important types of seizure manifestation involve viscerosensory, somatosensory, olfactory, gustatory, auditory, and tonic clonic presentation,

as well as changes in heartbeat pattern, vomiting, abnormal self-motor or hypermotor behaviors, and language disorders.^{14,18,19}

By analyzing the presence and evolution of clinical symptoms that occur during the development of an ictal discharge inside the insular lobe, it is noted that seizures can arise from any part of the insula, therefore spreading to adjacent opercula regions.¹⁸

Historically, insular epilepsy has been and still is considered difficult to investigate; therefore, diagnosis, workup, and assessment can take a long time for these patients. Furthermore, insular epilepsy mimics symptoms of frontal and temporal seizures, as well as other types.^{14,18,20,21} Because of this cluster of symptoms and signs, a thorough analysis and assessment is usually performed, especially regarding the history of the seizures and the auras, since insular and operculoinsular seizures with preserved consciousness are characteristically associated with asphyxia, painful sensations, and taste auras.^{14,22}

Finally, when insular epilepsy is drug resistant, the resection of the epileptogenic area usually correlates with good to excellent seizure control over time. Also important is the use of invasive electroencephalography (EEG) monitoring when needed to better understand the size and right topography of the epileptogenic area and the seizure dissipation pattern. Therefore, the surgical resection is tailored for each patient and surgical approach performed.^{14,18,23}

Methods

Study design and patients: Retrospective review of 10 patients submitted to either transsylvian or transcortical

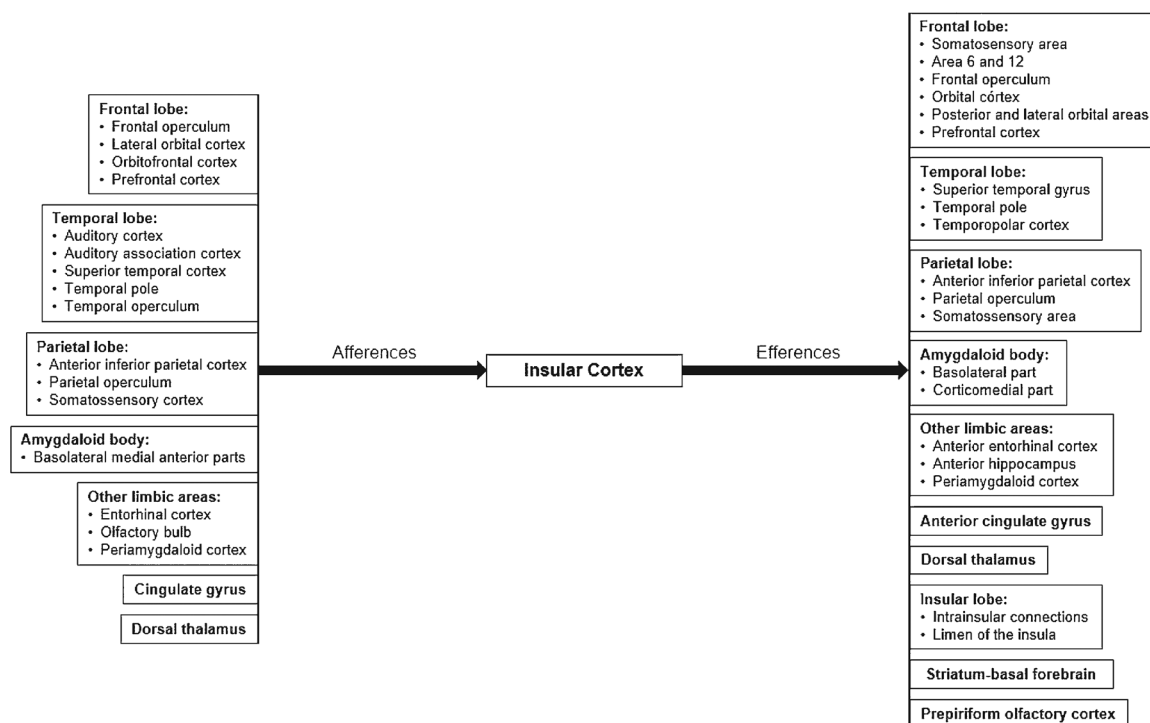


Fig. 5 Insular cortex connections with afferent and efferent projections. This image was reproduced from Shelley et al.¹⁷

insular resection procedures for refractory epilepsy for insular lesions. For all patients, medical history, semiology and frequency of the seizures, neurological status, magnetic resonance imaging (MRI) findings, and electrophysiological studies were recorded during the pre- and postoperative periods.

Preoperative procedure: All patients underwent preoperative epilepsy workup assessment. The anatomy and function of the insula were also described and reviewed in the context of the surgical approach description. These patients were operated on by the senior author of the present article.

Surgery and histopathology: For all procedures, intraoperative ultrasonography, neuronavigation, ultrasonic aspirator, and intraoperative neurophysiological monitoring (IONM) were used. Either a transylvian approach for the left insula or a transcortical approach for the right insula was performed. Despite the approach utilized, tumor resection was performed aiming for gross total resection (GTR). Gross total resection was not feasible due to the high risk for neurological deficits. An extension of the resection was performed to remove the rim of the insular cortex or the epileptogenic surrounding area to achieve seizure control.

Follow-up

All patients were classified preoperatively according to the epilepsy classification by Engel and during the regular follow-ups (FUs). To describe the overall results, the last available outcome was used. Follow-up information regarding seizure reduction and neurological status was obtained from the regular outpatient appointments. The present study began in February 2014 and ended in August 2019. Patients were followed-up, on average, for 27 months.

Results

All 10 patients were right-handed and were left hemisphere-dominant. The mean age was 42.5 years old and there were 6 women and 4 men. The mean FU time was 27.2 months. All patients were Engel IV preoperatively and, after surgery, seven of them became Engel II regardless of the surgical approach, either transylvian or transcortical, during the FU. Three patients during the study became Engel III (patients 1, 6, and 9). The baseline condition or anatomopathological diagnosis did not correlate with worse or better outcomes regarding seizure control. Regarding postoperative complications, there was a case with permanent hemiplegia in a patient with glioblastoma who died at 12 months of FU, a wound dehiscence with cerebrospinal fluid (CSF) fistula in the same patient, and another deceased patient at 13 months of FU also with a glioblastoma (– **Table 1**).

An awake transylvian approach was the choice for six patients whose lesions were on the left hemisphere, whereas the transcortical approach was used for the remaining four patients whose lesions were on the right insula (three awake and one asleep). For 6 patients, a subtotal resection (STR) (between 90 and 95%) was performed, and for the remaining 4, a partial resection (PR) (< 90%) was achieved. Gross total resection (> 95%) was not achievable due to the high risk for

Table 1 Case series of Insulectomy

Case No.	Age (years old), gender	Race	Dominance	Preoperative (Engel class)	Pathology, side	Surgical approach	Resection	Postoperative (Engel class)	Complications	Follow-up and survival
1	55, F	Black	Left	IV	Glioblastoma, L	Transylvian, awake	Partial	II	Permanent hemiplegia	Death after 12 mos
2	43, F	Black	Left	IV	Oligodendroglioma, L	Transylvian, awake	Subtotal	II	–	19 mos
3	34, F	White	Left	IV	Grade II astrocytoma, R	Transcortical, sleep	Subtotal	II	–	22 mos
4	54, M	White	Left	IV	Oligodendroglioma, L	Transylvian, awake	Partial	II	–	46 mos
5	19, F	Yellow	Left	IV	Cortical dysplasia, R	Transcortical, sleep	Subtotal	II	–	34 mos
6	53, M	White	Left	IV	Glioblastoma, L	Transylvian, awake	Partial	II	–	Death after 13 mos
7	44, F	Black	Left	IV	Ganglioglioma, L	Transylvian, awake	Subtotal	II	–	21 mos
8	32, M	White	Left	IV	Oligodendroglioma, L	Transylvian, awake	Partial	II	–	11 mos
9	37, M	Black	Left	IV	Grade II astrocytoma, R	Transcortical, awake	Subtotal	II	CSF fistula	34 mos
10	54, F	White	Left	IV	Ganglioglioma, R	Transcortical, sleep	Subtotal	II	–	60 mos

Abbreviations: CSF, cerebrospinal fluid; F, female; L, left; M, male; mos, months; No, number; R, right.

neurological deficits. Seizure control was better for all patients except for the ones with glioblastomas, possibly due to the more aggressive behavior of the condition (► **Table 1**).

Discussion

From 2009 to 2017, 5 searched articles about insular epilepsies reported the results of 82 patients submitted to lesionectomies plus an insular approach aiming for seizure control (► **Table 2**). The results showed a significant improvement in seizure control after surgery in all studies. Von Lehe et al.²⁴ presented his results according to the ILAE (International League against Epilepsy) classification. They were able to show that 15 out of 24 patients were seizure free (ILAE 1), 4 patients were classified as ILAE 2 and 3; and the remaining 5 patients were class 5 postoperatively. The reported rate of complications was similar to that of our study, including hemiparesis, hemi hypoesthesia, and hemianopia as permanent complications, and hemiparesis and dysphasia as temporary complications. Intraoperative neurophysiological monitoring was used in 50% of the cases and there were no glioblastomas in this study.²⁴ Boucher et al.²⁵ did not classify their patients according to the seizure frequency after insulectomies; however, they described that the 18 patients analyzed presented a general improvement regarding epilepsy control. In this study, arm, tongue, and cheek hypoesthesia, and foot dysesthesia were presented as permanent complications, and transient hemiparesis, transient aphasia, and transient brachyfacial paresis were presented as temporary complications. They have also reported that 11 cases (61.2%) presented postoperative subcortical ischemic infarcts related to injuries to perforating branches (mainly of M2).²⁵ The remaining three other studies classify results according to the Engel classification. In a small study, Park et al.²⁶ reported excellent results showing that 5 cases (83.4%) became Engel I and 1 patient (16.6%) became Engel II after surgery. They did not describe any complications.²⁶ In their study, Malak et al.²⁷ also showed excellent outcomes, with 9 patients (100%) becoming Engel I after insulectomy. They reported hemiparesis and dysphasia as complications.²⁷ Bouthilier et al.³ also reported excellent outcomes in their work, showing that 20 (80%) patients achieved Engel class I, 3 (12%) Engel class II, and 1 (4%) Engel class III. As complications, the study reported permanent decrease in oromotor speed and transient hemiparesis, transient dysphasia, hyperosmia, facial asymmetry, alteration of taste, altered pain and thermal sensation, hyperacusis, and postural tremor as temporary complications.³

Lesions located in the nondominant hemisphere are usually resected under general anesthesia with IONM, whereas lesions located in the dominant side may require an awake procedure to map language areas and minimize deficits. The inferior frontal and superior temporal gyri and the inferior occipitofrontal (IFOF) and arcuate fascicles (AFs), which project along the subcortical region of the insula, are important white matter tracts on the left hemisphere and should be preserved if possible to avoid language deficits. In addition, stimulation of

the dorsal stream, typically performed by the AF, leads to speech apraxias, phonological paraphasias, and repetition disorders, while stimulation of the ventral stream, performed by the IFOF, leads to semantic paraphasia.^{12,28,29}

Prybylowski et al.⁴ compared the surgical morbidity of 52 patients submitted to the transsylvian approach with 48 patients operated on by the transcortical approach for glioma resection. The results suggest that both techniques are associated with equivalent and reasonable morbidity profiles, even though gliomas located within the superior-posterior quadrant of the insula are usually considered for a transcortical approach. To date, however, there are no objective and clear criteria that guide the conduct of neurosurgeons to adopt one technique over the other. In fact, most studies reflect a preference for one technique rather than the other based on subjective criteria, such as the historical preference of the institutions themselves and/or personal tendencies of professionals.⁴

Characteristically, the transopercular approach (► **Fig. 6**) involves the creation of “cortical windows” above or below the sylvian fissure, through nonfunctional cortical areas of the operculum (by subpial dissection) to avoid blood vessel coagulation and ensure better exposure of the insular cortex. The transsylvian technique (► **Fig. 7**), developed by Yaşargil, on the other hand, guarantees an alternative strategy, using a natural corridor provided by the sylvian fissure. One of the major advantages of this technique is the ability to identify and control vascular structures during surgical resection, such as the MCA (and its branches) and the lenticulostriate arteries. However, this approach is frequently associated with surgical manipulation of superficial plus perisylvian vessels and, along with opercular retraction, potentially increases the risks of postoperative deficits and of vascular injury or spasm.^{3,4,28,30–32}

The main postoperative complications were hemiparesis and worsening of previous neurological motor and visual deficits (hemianopsias) (► **Table 1**). Different hypotheses may explain the occurrence of these complications; however, it is important to remember that the insula plays an associative/nonessential role in gustation, olfaction, memory, drive, sympathetic control of cardiovascular tone, somatosensory input and pain processing, motor planning, and language.^{12,13,15,27,30,33} Hence, transient postoperative deficits may reside in the interruption of motor and/or linguistic functions of the insula during surgery or in the shrinkage of the operculum, being subsequently compensated and even fully recovered due to a secondary nature of the insular cortex in performing these functions, while permanent postoperative deficits would be much more associated with the manipulation of the lenticulostriate arteries or with injury causing deep strokes, for example. (► **Figs. 3 and 4**).^{19,27,34}

The lateral lenticulostriate arteries (LLAs) have particular importance because the vertical plane formed by their course corresponds to the medial limit of resection in insulectomies. The LLAs supply blood flow to the lentiform nucleus and the internal capsule. Furthermore, early dissection of the proximal M1 segment allows the neurosurgeon to follow and identify the LLAs, which originate precisely from the M1 segment as it runs inferiorly through the anterior perforated

Table 2 Review of Insulectomy case series reported in the literature since 2009^{3,24-27}

Authors and Year	Patients (n)	Mean age (years old)	Preoperative symptoms	Surgical approach	Postoperative complications	Mean follow-up	Outcome/ seizure outcome	Pathology
von Lehe et al., 2009 ²⁴	24	27 (1-62)	Viscerosensory, emotional and nonspecific sx (including the experience of fear)	n=7: partial insulectomy with or without lobectomies n=17: total insulectomy with or without lobectomies Obs: Transylvian app for strictly insular lesions and temporoin-sular lesions; transcortical app for temporoin-sular and frontotemporal lesions; transylvian and transcortical app in some patients with strictly insular lesions and frontotemporo-insular lesions.	Permanent morbidity: n = 1: increased hemiparesis n = 1: hemi hypoesthesia n = 2: hemianopia Temporary morbidity: n = 1: hemiparesis and dysphasia n = 1: hemiparesis Other complications: n = 1: aseptic inflammatory meningeal response	37.5 months (12-168 months)	Seizure outcomes according to ILAE classification: n = 15: Class I n = 2: Class 2 n = 2: Class 3 n = 5: Class 4	n = 2: cavernoma n = 2: DNT (WHO grade I) n = 3: gliosis n = 5: other gliomas (WHO grades II-III) n = 6: ganglioglioma (WHO grade I) n = 6: cortical dysplasia
Park et al., 2009 ²⁶	6	4.2 (4-7 years)	unspecified	Pt.1: total insulectomy Pt.2: frontal and temporal lobectomy and total insulectomy Pt.3: hemispherectomy and total insulectomy Pt.4: frontal lobectomy and partial insulectomy Pt.5: frontal lobectomy and partial insulectomy Pt.6: temporal lobectomy and partial insulectomy	none	17.8 months (6-33 months)	Seizure outcomes according to the Engel classification: Pt.1,2,3,4,6: Class I Pt.5: Class II	Pt.1: cortical dysplasia Pt.2: could not be diagnosed Pt.3: could not be diagnosed Pt.4: cortical dysplasia Pt.5: hypertrophic astrocyte Pt.6: microdysgenesis
Malak et al., 2009 ²⁷	9	29.4 (16-36)	Somatosensory, viscerosensory, and somatomotor sx; paresthesia; throat constriction; tonic posturing; nausea; dysphasia	Pt.1: temporal lobectomy and partial (ant) insulectomy Pt.2: partial (post) insulectomy Pt.3: frontal lobectomy and total insulectomy Pt.4: frontal, parietal, and temporal operculectomy Pt.5: frontal operculectomy Pt.6: temporal lobectomy and total insulectomy Pt.7: frontal and parietal operculectomy Pt.8: total insulectomy Pt.9: partial insulectomy	Trans increase of dysphasia: n = 1 Trans hemiparesis (or increase): n = 4	54 months (14-122 months)	Engel Class I was achieved in all patients Obs: one patient had an Engel Class III outcome after partial insulectomy but later became seizure-free (Engel Class I) following insular gamma knife surgery	n = 2: tumor associated with seizures n = 7: refractory epilepsy with no tumor
Boucher et al., 2015 ²⁵	18	35 (22-52)	Cognitive impairments; hemiparesis	n = 1: insulectomy and lobectomies n = 2: operculectomy and lobectomies n = 5: insulectomy n = 10: operculectomy Obs: n = 2: partial (inferior) insulectomy n = 3: total insulectomy n = 4: partial (post) insulectomy n = 9: partial (ant) insulectomy	Permanent morbidity: n = 1: arm, tongue, and cheek hypoesthesia and foot dysesthesia Temporary morbidity: n = 3: trans hemiparesis (or increase) n = 3: trans aphasia n = 1: trans brachyfacial paresis and/or: trans depression, hyperosmia, facial asymmetry, altered pain and thermal sensation, etc. Obs: 11/18 postop subcortical ischemic infarcts related to injury of perforating branches (mainly of M2)	21.8 months (5-142 months)	General improvement of seizures in all patients, as well as equivalent pre- and postoperative neurophysiological results	n = 1: tuberous sclerosis n = 1: congenital encephalomalacia n = 2: hippocampal sclerosis n = 4: cortical dysplasia

(Continued)

Table 2 (Continued)

Authors and Year	Patients (n)	Mean age (years old)	Preoperative symptoms	Surgical approach	Postoperative complications	Mean follow-up	Outcome/ seizure outcome	Pathology
Bouthilier et al., 2017 ³	25	35 (9–51 y)	Somatosensory and viscerosensory sx; auditory, gustatory, and olfactory sx; throat constriction	n = 1: operculectomy and frontal lobectomy n = 2: operculectomy and orbitofrontal resection n = 2: insulectomy n = 4: operculectomy and temporal lobectomy n = 16: operculectomy	Permanent morbidity: n = 1: decrease in oromotor speed Temporary morbidity: n = 5: trans hemiparesis (or increase) n = 5: trans dysphasia and/or: trans depression, hyperosmia, facial asymmetry, alteration of taste, postural tremor, altered pain and thermal sensation, hyperacusis etc.	56.4 months (12–192 months)	Seizure outcomes according to Engel classification: n = 20: Class I n = 3: Class II n = 1: Class III n = 1: sudden unexpected death 3 months after insulectomy	Inside operculoinsular area: n = 1: tuberos sclerosis n = 1: encephalomalacia n = 5: cortical dysplasia Outside operculoinsular area: n = 1: tuberos sclerosis n = 3: atrophy/ encephalomalacia n = 5: hippocampal sclerosis

Abbreviations: ant, anterior; app, approach; ILAE, International League against Epilepsy; mo, months; Obs, observation; post, posterior; postop, postoperative; preop, preoperative; pt, patient; sx, symptom; trans, transient; WHO, World Health Organization; yrs., years.

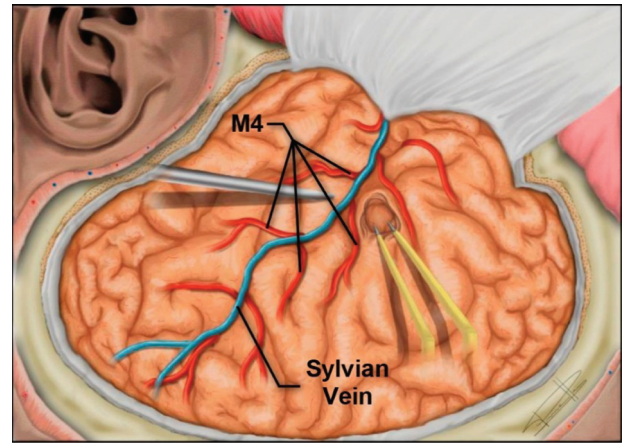


Fig. 6 Illustration of the transcortical approach for resection of the insular cortex – by subpial dissection of the operculum between the M4 branches of the middle cerebral artery. M4 = M₄ segment of the MCA.

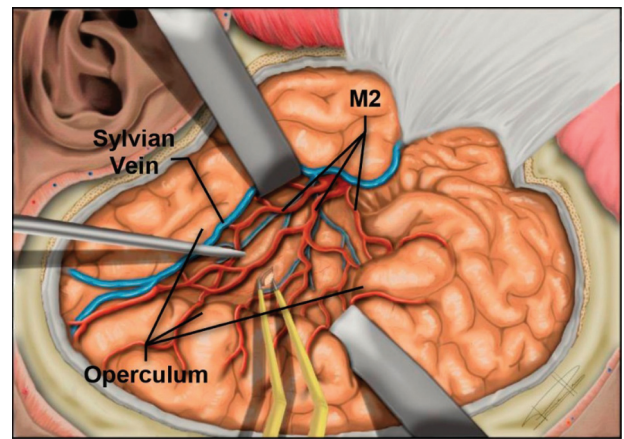


Fig. 7 Illustration of the transsylvian approach for resection of the insular cortex, allowing to observe the divisions of the M2 trunks. M2 = M₂ segment of MCA.

substance and up to the region of the limen insulae. From this point, the M1 bifurcates into M2 segments (– Fig. 1B), whose branches originate the short and long perforating arteries that supply the insular cortex and the corona radiata, respectively. For this reason, is important to preserve the long perforating branches to avoid ischemic lesions and motor deficits.^{12,13,35,36}

Conclusions

Surgical resection of insular lesions can be a challenge regarding the extent of resection and maintaining quality of life with minimal neurological deficits. The present case series presented results comparable with the most recent ones in the literature in terms of seizure control, life expectancy, and quality of life. Despite complications associated with these procedures, in general, the benefits outweigh the risks since, for many patients, the natural history of the baseline condition could be more devastating, thus reinforcing surgical indication. Finally, it is paramount to better understand the insular surgical anatomy when performing

a procedure in this complex region. The utilization of modern microsurgical techniques, ultrasound, neuronavigation, and specially IONM, are important to prevent neurological deficits. Insulectomies can be performed in the context of achieving not only oncological resection but also to accomplish seizure reduction by adding to the lesion resection an extension to include the epileptogenic surrounding cortex.

Conflict of Interests

The authors have no conflict of interests to declare.

References

- Pires de Aguiar PH, Rodrigues L, Estevão I, et al. La Insulectomía podría ser un abordaje ideal para crisis insulares y peri-insulares? *Rev Chil Neurocir* 2019;42(02):107–110. Doi: 10.36593/rev.chil.neurocir.v42i2.107
- Kaneko N, Boling WW, Shonai T, et al. Delineation of the safe zone in surgery of sylvian insular triangle: morphometric analysis and magnetic resonance imaging study. *Neurosurgery* 2012;70(2, Suppl Operative):290–298, discussion 298–299. Doi: 10.1227/NEU.0b013e3182315112
- Bouthillier A, Nguyen DK. Epilepsy surgeries requiring an operculoinsular cortectomy: Operative technique and results. *Neurosurgery* 2017;81(04):602–612. Doi: 10.1093/neuros/nyx080
- Przybyłowski CJ, Baranoski JF, So VM, Wilson J, Sanai N. Surgical morbidity of transsylvian versus transcortical approaches to insular gliomas. *J Neurosurg* 2019;132(06):1731–1738. Doi: 10.3171/2018.12.JNS183075
- Ribas GC, Oliveira Ed. A ínsula e o conceito de bloco cerebral central. *Arq Neuropsiquiatr* 2007;65(01):92–100. Doi: 10.1590/S0004-282x2007000100020
- Penfield W, Faulk ME Jr. The insula; further observations on its function. *Brain* 1955;78(04):445–470. Doi: 10.1093/brain/78.4.445
- Türe U, Yaşargil DCH, Al-Mefty O, Yaşargil MG. Topographic anatomy of the insular region. *J Neurosurg* 1999;90(04):720–733. Doi: 10.3171/jns.1999.90.4.0720
- Aguiar PHP, Mathias RN, Marchi LR, et al. Insulectomy for Insular and Peri-insular Seizures. *Critical Review and Anatomical Landmarks Anatomy of Insula*. 2016;26(03):191–194
- Laoprasert P, Ojemann JG, Handler MH. Insular epilepsy surgery. *Epilepsia* 2017;58(Suppl 1):35–45. Doi: 10.1111/epi.13682
- Guenot M, Isnard J, Sindou M. Surgical anatomy of the insula. *Adv Tech Stand Neurosurg* 2004;29:265–288. Doi: 10.1007/978-3-7091-0558-0_7
- Ribas EC, Yağmurlu K, de Oliveira E, Ribas GC, Rhoton A. Microsurgical anatomy of the central core of the brain. *J Neurosurg* 2018;129(03):752–769. Doi: 10.3171/2017.5.JNS162897
- Rey-Dios R, Cohen-Gadol AA. Technical nuances for surgery of insular gliomas: lessons learned. *Neurosurg Focus* 2013;34(02):E6. Doi: 10.3171/2012.12.FOCUS12342
- Türe U, Yaşargil MG, Al-Mefty O, Yaşargil DC. Arteries of the insula. *J Neurosurg* 2000;92(04):676–687
- Jobst BC, Gonzalez-Martinez J, Isnard J, et al. The Insula and Its Epilepsies. *Epilepsy Curr* 2019;19(01):11–21. Doi: 10.1177/1535759718822847
- Uddin LQ, Nomi JS, Hébert-Seropian B, Ghaziri J, Boucher O. Structure and Function of the Human Insula. *J Clin Neurophysiol* 2017;34(04):300–306. Doi: 10.1097/WNP.0000000000000377
- Augustine JR. Circuitry and functional aspects of the insular lobe in primates including humans. *Brain Res Brain Res Rev* 1996;22(03):229–244. Doi: 10.1016/S0165-0173(96)00011-2
- Shelley BP, Trimble MR. The insular lobe of Reil—its anatomico-functional, behavioural and neuropsychiatric attributes in humans—a review. *World J Biol Psychiatry* 2004;5(04):176–200
- Isnard J, Hagiwara K, Montavont A, et al. Semiology of insular lobe seizures. *Rev Neurol (Paris)* 2019;175(03):144–149. Doi: 10.1016/j.neuro.2018.12.00
- Duffau H, Capelle L, Lopes M, Faillat T, Sichez JP, Fohanno D. The insular lobe: physiopathological and surgical considerations. *Neurosurgery* 2000;47(04):801–810, discussion 810–811. Doi: 10.1097/00006123-200010000-00001
- Nguyen DK, Nguyen DB, Malak R, et al. Revisiting the role of the insula in refractory partial epilepsy. *Epilepsia* 2009;50(03):510–520. Doi: 10.1111/j.1528-1167.2008.01758.x
- Levitt MR, Ojemann JG, Kuratani J. Insular epilepsy masquerading as multifocal cortical epilepsy as proven by depth electrode. *J Neurosurg Pediatr* 2010;5(04):365–367. Doi: 10.3171/2009.11.PEDS09169
- Obadi S, Tucholka A, Ghaziri J, et al. Cortical thickness analysis in operculo-insular epilepsy. *Neuroimage Clin* 2018;19(May):727–733. Doi: 10.1016/j.nicl.2018.05.033
- Isnard J, Guénot M, Sindou M, Manguière F. Clinical manifestations of insular lobe seizures: a stereo-electroencephalographic study. *Epilepsia* 2004;45(09):1079–1090. Doi: 10.1111/j.0013-9580.2004.68903.x
- von Lehe M, Wellmer J, Urbach H, Schramm J, Elger CE, Clusmann H. Epilepsy surgery for insular lesions. *Rev Neurol (Paris)* 2009;165(10):755–761. Doi: 10.1016/j.neuro.2009.07.008
- Boucher O, Rouleau I, Escudier F, et al. Neuropsychological performance before and after partial or complete insulectomy in patients with epilepsy. *Epilepsy Behav* 2015;43:53–60. Doi: 10.1016/j.yebeh.2014.11.016
- Park YS, Lee YH, Shim KW, et al. Insular epilepsy surgery under neuronavigation guidance using depth electrode. *Childs Nerv Syst* 2009;25(05):591–597. Doi: 10.1007/s00381-008-0764-8
- Malak R, Bouthillier A, Carmant L, et al. Microsurgery of epileptic foci in the insular region. *J Neurosurg* 2009;110(06):1153–1163. Doi: 10.3171/2009.1.JNS08807
- Turgut M, Yurttaş C, Shane Tubbs R. Island of Reil (Insula) in the Human Brain: Anatomical, Functional, Clinical and Surgical Aspects. *Springer Cham*; 2018. Doi: 10.1007/978-3-319-75468-0
- Chiosa V, Granziera C, Spinelli L, et al. Successful surgical resection in non-lesional operculo-insular epilepsy without intracranial monitoring. *Epileptic Disord* 2013;15(02):148–157. Doi: 10.1684/epd.2013.0581
- Safae MM, Englot DJ, Han SJ, Lawton MT, Berger MS. The transsylvian approach for resection of insular gliomas: technical nuances of splitting the Sylvian fissure. *J Neurooncol* 2016;130(02):283–287. Doi: 10.1007/s11060-016-2154-5
- Potts MB, Chang EF, Young WL, Lawton MTUCSF Brain AVM Study Project. Transsylvian-transinsular approaches to the insula and basal ganglia: operative techniques and results with vascular lesions. *Neurosurgery* 2012;70(04):824–834, discussion 834. Doi: 10.1227/NEU.0b013e318236760d
- Mascitelli J, Gandhi S, Wright E, Lawton MT. Transsylvian-Transinsular Approach for an Insular Cavernous Malformation Resection: 3-Dimensional Operative Video. *Oper Neurosurg (Hagerstown)* 2019;16(02):50. Doi: 10.1093/ons/opy155
- Hervey-Jumper SL, Berger MS. Insular glioma surgery: an evolution of thought and practice. *J Neurosurg* 2019;130(01):9–16. Doi: 10.3171/2018.10.JNS181519
- Roper SN, Lévesque MF, Sutherling WW, Engel J Jr. Surgical treatment of partial epilepsy arising from the insular cortex. Report of two cases. *J Neurosurg* 1993;79(02):266–269. Doi: 10.3171/jns.1993.79.2.0266
- Moshel YA, Marcus JDS, Parker EC, Kelly PJ. Resection of insular gliomas: the importance of lenticulostriate artery position. *J Neurosurg* 2008;109(05):825–834. Doi: 10.3171/JNS/2008/109/11/0825
- Silfvenius H, Gloor P, Rasmussen T. Evaluation of Insular Ablation in Surgical Treatment of Temporal Lobe Epilepsy. *Epilepsia* 1964;5(04):307–320. Doi: 10.1111/j.1528-1157.1964.tb03338.x