



# Convexity Dura-Based Cerebral Cavernous Malformation Mimicking Meningioma: A Case Report and Literature Review

Raed Hassan Abujarir<sup>1</sup> Ali Ayyad<sup>1</sup> Ahmad Sotouhy<sup>2</sup> Essam Bozom<sup>3</sup> Ahmed Shaaban<sup>1</sup>  
Aisha Al Kubaissi<sup>1</sup>

<sup>1</sup>Neurosurgery Unit, Hamad Medical Corporation, Doha, Qatar

<sup>2</sup>Department of Neuroradiology, Hamad Medical Corporation, Doha, Qatar

<sup>3</sup>Department of Pathology, Hamad Medical Corporation, Doha, Qatar

Address for correspondence Raed Hassan Abu Jarir, MD, FRCS, Ed.SN, ABSSN, Neurosurgery Unit, Hamad Medical Corporation, 7GPR + 3M9, Doha, Qatar (e-mail: raedabujarir70@gmail.com).

AJNS 2022;17:120–126.

## Abstract

Cavernous angioma, cavernoma, cavernous hemangioma, also called cerebral cavernous malformation (when present in the brain), are benign vascular malformations, usually intraparenchymal; however, a few reported cases are in the extra-axial location—as middle cranial fossa, near the cavernous sinuses, and in the cerebello-pontine angle—and are rarely reported as dura-based convexity lesion resembling meningioma. We report a giant dura-based, convexity, a cerebral cavernous malformation. We wish to notify the case as occurring at a rare location and a large-sized cerebral cavernous malformation. A case of young female presented with a long-standing history of headache. Computed tomography scan and magnetic resonance imagings (MRIs) suggested right occipital dura-based large mass lesion of approximately 5 cm in diameter. The lesion was excised and pathology studies confirmed the diagnosis of a cerebral cavernous malformation. A follow-up MRI confirmed total resection of the lesion and the patient had a smooth postoperative recovery.

## Keywords

- ▶ dura-based cavernous malformation
- ▶ extra-axial cavernous malformation
- ▶ cavernoma mimicking meningioma

## Background and Importance

Cavernous angioma is an angiographically occult vascular malformation, related to the fact that it is not usually visible on conventional cerebral angiography. Cavernomas are not neoplastic lesions, but vascular malformation. Cerebral cavernous malformation is present in approximately 0.5% of the

general population, usually intra-axial lesions. But occasional extra-axial locations of cerebral cavernous malformation are reported in the middle cranial fossa or near the cavernous sinus. Cavernous malformation has the classical mulberry appearance with engorged purplish cluster of vessels, caverns, with diameters varying from 2 mm to several centimeters. Histologically, it consists of a dilated thin-walled

DOI <https://doi.org/10.1055/s-0042-1749109>.  
ISSN 2248-9614.

© 2022. Asian Congress of Neurological Surgeons. All rights reserved.

This is an open access article published by Thieme under the terms of the Creative Commons Attribution-NonDerivative-NonCommercial-License, permitting copying and reproduction so long as the original work is given appropriate credit. Contents may not be used for commercial purposes, or adapted, remixed, transformed or built upon. (<https://creativecommons.org/licenses/by-nc-nd/4.0/>)

Thieme Medical and Scientific Publishers Pvt. Ltd., A-12, 2nd Floor, Sector 2, Noida-201301 UP, India

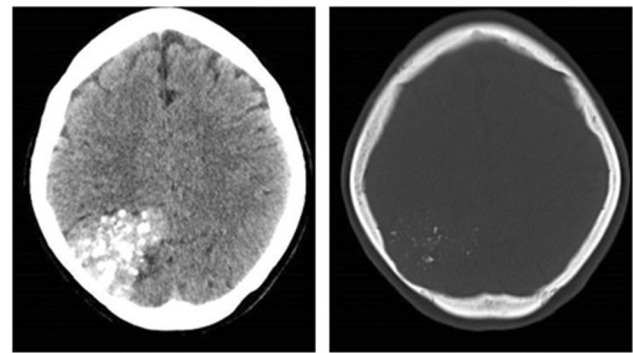
capillary with simple endothelium and thin adventitia, vessels wall lack of smooth muscles, and leakage of blood through the thin walls, lead to surrounding hemosiderin, it may also contain calcification.

Developmental venous anomalies are associated with cavernous malformation in approximately 10 to 20%. Most of cavernous malformation remain asymptomatic, but they may present with headache, seizures, or focal neurological deficit secondary to bleeding. In many occasions, these lesions are discovered incidentally when performing imaging to unrelated symptoms. The best diagnostic imaging is the Susceptibility Weighted Images, and the gradient-echo magnetic resonance imaging (MRI) sequences.

## Case Description

### Clinical Presentation

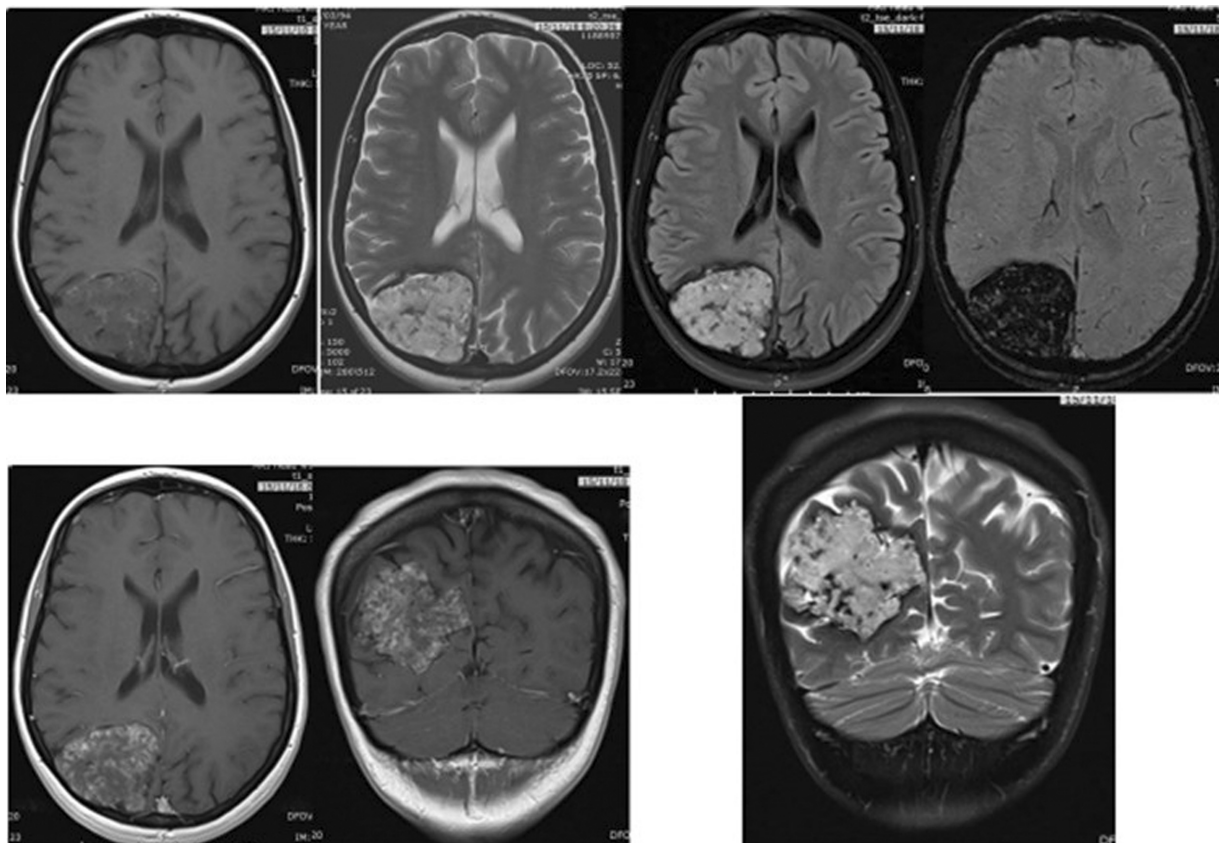
A 24-year-old female presented with frequent episodes of nonspecific headache. There was no history of seizures; she had an unremarkable past medical history. She had no focal neurological deficit.



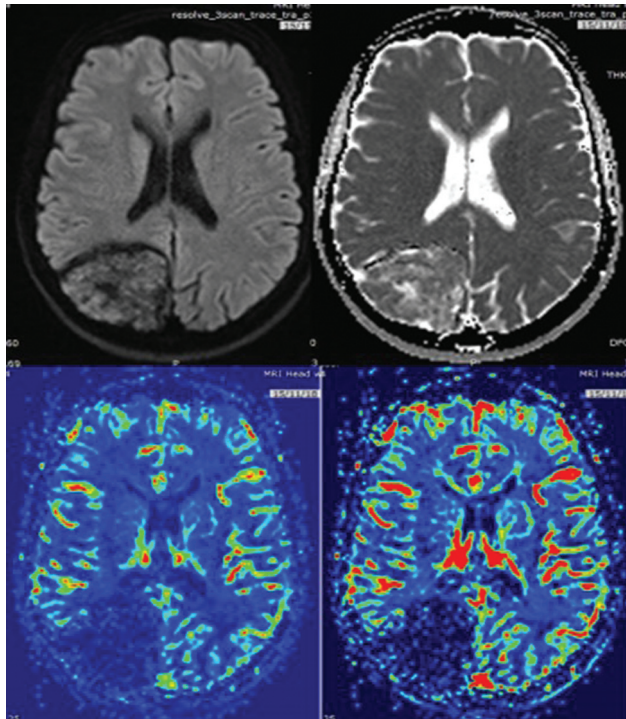
**Fig. 1** CT scan without contrast.

### Images

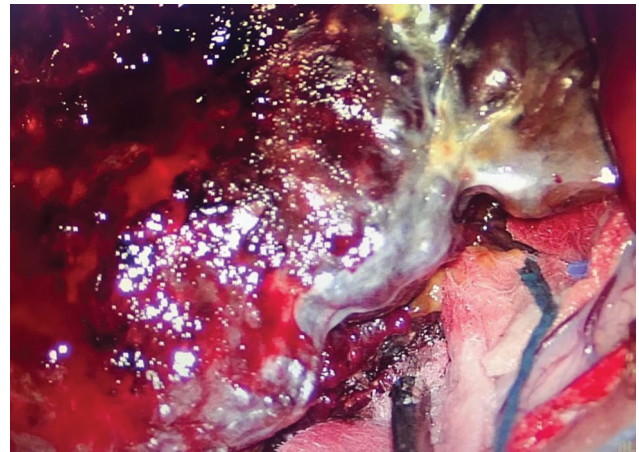
- Computed tomography (CT) scan suggested a dura-based right occipital mass lesion, with calcifications, and evidence of scalloping of the inner table (→ **Figs. 1–4**).



**Fig. 2** Brain magnetic resonance imaging (MRI) showing right occipital dura-based mass lesion. T2 and fluid-attenuated inversion recovery-weighted images displaying intermediate to high signal. Blooming dark low signal intensity on susceptibility weighted images. There is no obvious dura tail, and from the previous computed tomography scan, there is no hyperostosis, suggested differential diagnosis of atypical meningioma, or hemangiopericytoma.



**Fig. 3** The lesion shows evidence of diffusion restriction with heterogeneous enhancement on contrast sequences, while reduced cerebral blood volume and cerebral blood flow in magnetic resonance perfusion study.



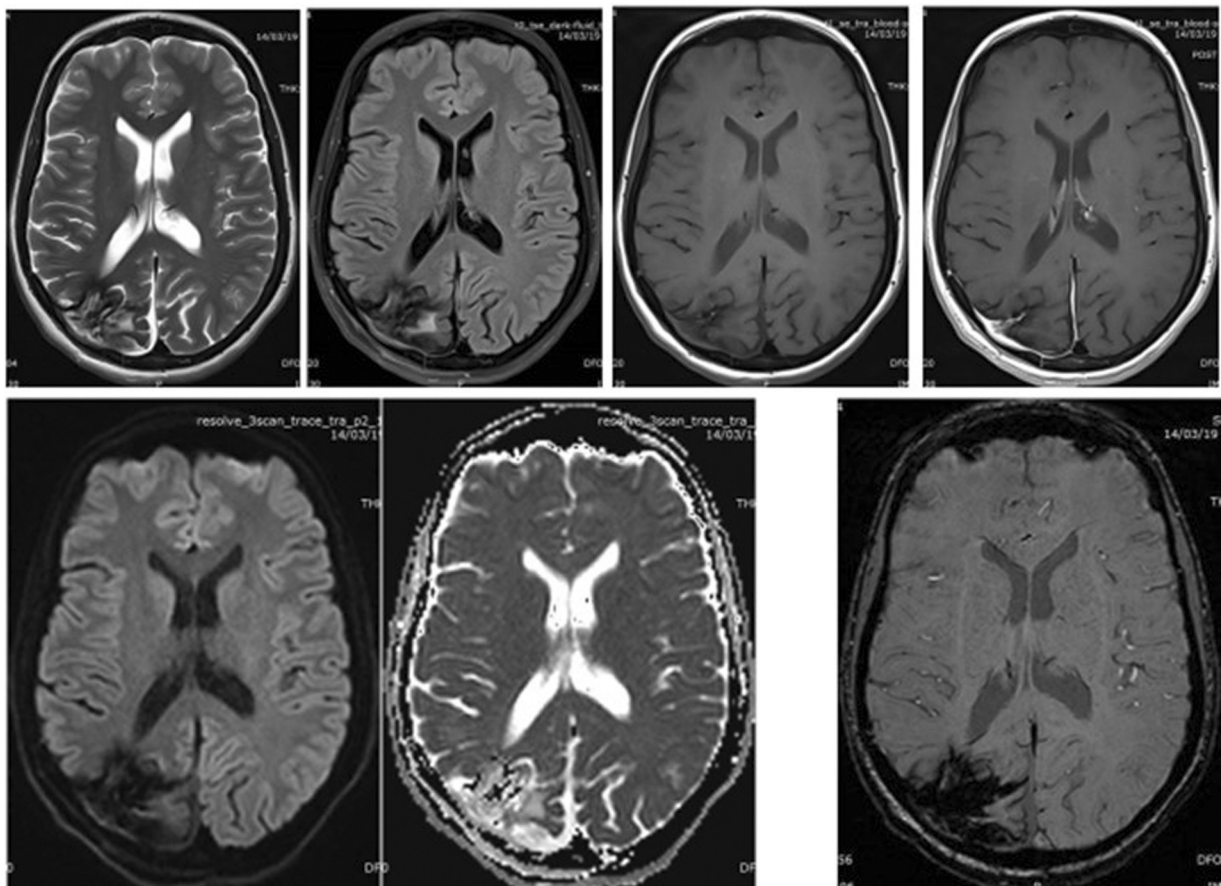
**Fig. 5** Surgical specimen A.

**Surgery**

An elective craniotomy and resection of the mass lesion was done.

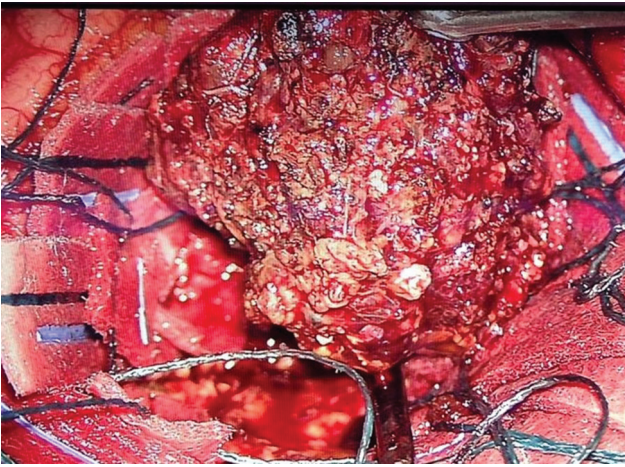
There was no overlying bone hyperostosis; the dura could be separated from the mass lesion, which appeared highly vascular with surrounding small vessels feeders (► **Figs. 5–8**).

Histopathology confirmed the diagnosis of cavernous hemangioma. It was reported as a pack of thin-walled ectatic dilated blood vessels, lined by flat endothelium, which contained fresh and old blood; the lesion showed area of

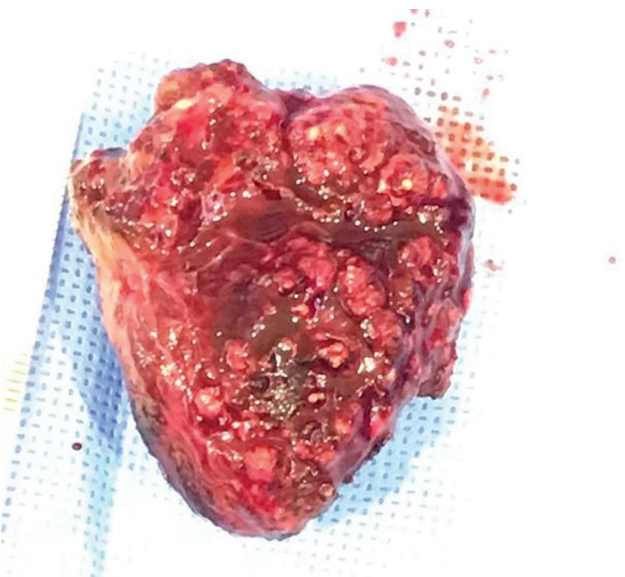

**Fig. 4** Follow-up magnetic resonance imaging scan showed total excision of the mass lesion.





**Fig. 6** Surgical specimen B.



**Fig. 7** Surgical specimen C.

extensive hyalinization with nodule formation, calcification, fibrosis, and organized hemorrhage.

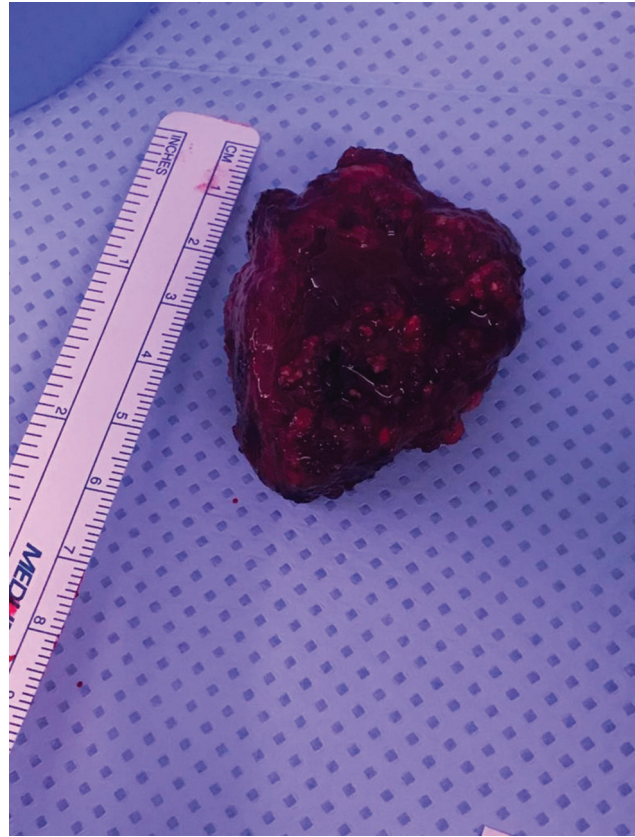
The adjacent brain tissue showed gliosis with organizing inflammation (►Figs. 9, 10A, 10B, 11). The final diagnosis was cavernous hemangioma.

## Discussion and Literature Review

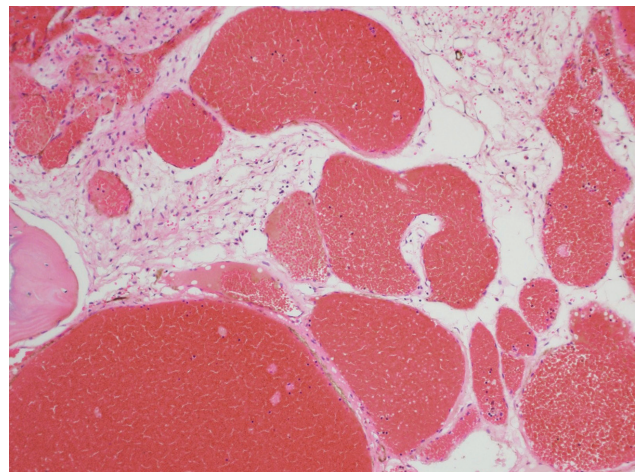
Cavernomas are usually intra-axial lesions; the developing MRI technology allows accurate diagnosis of cavernoma; but, it is a diagnostic challenge when unusual, location, as extra-axial, or even rare presentation as dura-based lesion.

Most of cerebral cavernomas are silent and could be discovered incidental when imaging is done for other reasons, like vague headache, or even after car accident; other presentation is secondary to bleeding.

The clinical presentation is widely variable depending on the location of the lesion, and if any bleed, still headache is the most common presenting symptoms; seizures and neu-



**Fig. 8** Surgical specimen D.



**Fig. 9** Back-to-back thin-walled blood vessels lined by flat endothelium (hematoxylin and eosin  $\times 100$ ).

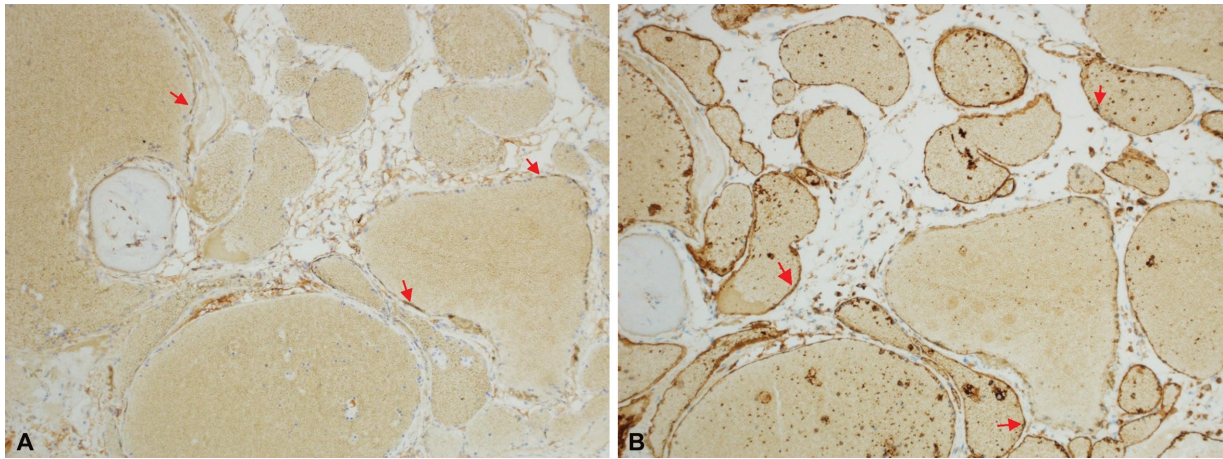
rological deficit are usually after bleeding event, which is usual limited.

There are few reported cases of extra-axial cavernoma, but fewer cases of dura-based, and convexity-dura-based are even rare.

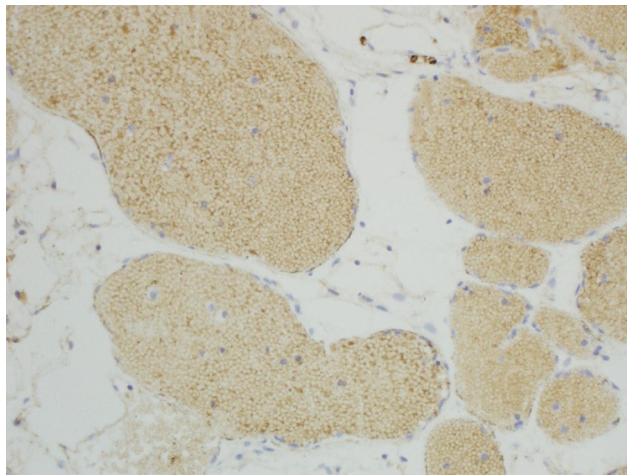
We reviewed 61 papers through PubMed search using related keywords (see ►Table 1).

When reviewing the current data, most of the extra axial located cavernoma are diagnosed around and in the





**Fig. 10** Endothelial cells are highlighted by D2-40 (A, red arrows) and CD31 (B, red arrows) (immunohistochemistry  $\times 100$ ).



**Fig. 11** Endothelial cells are negative by meningotheial marker (immunohistochemistry  $\times 100$ ).

cavernous sinus,<sup>1-11</sup> parasellar, suprasellar,<sup>12-18</sup> in the cerebellopontine angle,<sup>42-49</sup> and lateral to midbrain and medulla.

There is few reported cavernoma presented as convexity dura-based location, mimicking meningioma; among the convexity-located group we found the parietal convexity is the common;<sup>22-25</sup> there are only two reported cases of occipital convexity.<sup>32,33</sup>

In case of dura-based lesions that lack the other radiological feature of meningioma, like dura tail, and adjacent bone hyperostosis, other differential diagnosis should be considered rather than meningioma, like hemangiopericytoma, metastasis to dura, and even cavernoma.

We present a case of large occipital dura-based lesion mimicking meningioma; however, in reviewing the CT scan bone window, there was bone scalloping (not hyperostosis); in MRI scan, we could not see the typical dura tail. These findings raised possible other differential diagnosis as atypical meningioma, hemangiopericytoma, and metastasis to dura, but cavernoma was not in our differential diagnosis.

**Table 1** Literature review of extra-axial cavernoma

Location	Reference	Number of cases
Cavernous sinus	1-3 4 (4 cases) 5 (12 cases) 6 (2 cases) 7-10 11 (6 cases)	31
Suprasellar and parasellar	12-18	7
Anterior clinoid	19	1
Superior sagittal sinus	20,21	2
Parietal	22-25	6
Convexity	26	
Temporal convexity	27,28	2
Frontal convexity	29-31	3
Occipital convexity	32,33	2
Falx cerebri	4,34-37	6
Sphenoid wing	38-40 (2 cases)	4
Anterior cranial fossa	41	1
Cerebellopontine angle	42-49	8
Lateral medullary	50,51	2
Third nerve	52,53	2
Fifth nerve	54	1
Foramen magnum	55,56	2
Falx cerebelli	57,58	2
Posterior cranial fossa	59,60	2
Tentorial cerebelli	61	1

## Conclusion

We report a case of large dura-based, occipital convexity, cavernous malformation; we report the rare location and the large size of the lesion.

Cerebral cavernous malformation may present as a dura-based lesion, but it is rare radiological feature of cavernous

malformation, still could be considered as one of differential diagnosis of dura base lesion, especially when other classical feature of meningioma is missing (dura tail, adjacent bone hyperostosis). Such atypical radiological location and large size of the cerebral cavernous malformation are under-reported. We report this case to be an addition to the literature, and to be available for reviewers.

#### Patient Consent

Patient consent obtained to publish this case report.

#### Conflict of Interest

None

#### References

- Akammar A, Sekkat G, Kolani S, et al. Unusual cause of binocular diplopia: cavernous sinus hemangioma. *Radiol Case Rep* 2021;16(09):2605–2608
- Aversa do Souto A, Marcondes J, Reis da Silva M, Chimelli L. Sclerosing Cavernous hemangioma in the cavernous sinus: case report. *Skull Base* 2003;13(02):93–99
- Bansal S, Suri A, Singh M, et al. Cavernous sinus hemangioma: a fourteen year single institution experience. *J Clin Neurosci* 2014; 21(06):968–974
- Biondi A, Clemenceau S, Dormont D, et al. Intracranial extra-axial cavernous (HEM) angiomas: tumors or vascular malformations? *J Neuroradiol* 2002;29(02):91–104
- Li MH, Zhao JL, Li YY, Zeng CH, Xu GS, Hong T. Extradural transcavernous approach to cavernous sinus cavernous hemangiomas. *Clin Neurol Neurosurg* 2015;136:110–115
- Noblett DA, Chang J, Toussi A, Dublin A, Shahlaie K. Hemangioma of the cavernous sinus: a case series. *J Neurol Surg Rep* 2018;79(02):e26–e30
- Schwyzler L, Tuleasca C, Borruat FX, Radovanovic I, Levivier M. Gamma Knife surgery for a hemangioma of the cavernous sinus in an adult: case report and short review of the literature. *Neurochirurgie* 2017;63(04):320–322
- Shah R, Nadimpalli S. Key imaging characteristics for preoperative identification of cavernous sinus hemangioma. *Radiol Case Rep* 2015;10(01):1013
- Shi J, Wang H, Hang C, Pan Y, Liu C, Zhang Z. Cavernous hemangiomas in the cavernous sinus. *Case reports. Surg Neurol* 1999;52(05):473–478, discussion 478–479
- Bristol R, Santoro A, Fantozzi L, Delfini R. Cavernoma of the cavernous sinus: case report. *Surg Neurol* 1997;48(02):160–163
- Meyer FB, Lombardi D, Scheithauer B, Nichols DA. Extra-axial cavernous hemangiomas involving the dural sinuses. *J Neurosurg* 1990;73(02):187–192
- Abou-Al-Shaar H, Bahatheq A, Takroni R, Al-Thubaiti I. Optic chiasmal cavernous angioma: a rare suprasellar vascular malformation. *Surg Neurol Int* 2016;7(Suppl 18):S523–S526
- Al-Saiari S, Al-Orabi K, Farag A, et al. Intrasellar cavernous hemangiomas: a case report with a comprehensive review of the literature. *Surg Neurol Int* 2021;12:58
- Oommen A, Pratap T, Chandi S, Jalal MJA. A parasellar extra-axial cavernoma mimicking meningioma: a case report. *Neuroimmunol Neuroinflamm* 2017;2017:x
- Chibbaro S, Cebula H, Ganau M, et al. Multidisciplinary management of an intra-sellar cavernous hemangioma: case report and review of the literature. *J Clin Neurosci* 2018;52:135–138
- Escott EJ, Rubinstein D, Cajade-Law AG, Sze CI. Suprasellar cavernous malformation presenting with extensive subarachnoid hemorrhage. *Neuroradiology* 2001;43(04):313–316
- Lombardi D, Giovanelli M, de Tribolet N. Sellar and parasellar extra-axial cavernous hemangiomas. *Acta Neurochir (Wien)* 1994;130(1-4):47–54
- Rheinboldt M, Blase J. Exophytic hypothalamic cavernous malformation mimicking an extra-axial suprasellar mass. *Emerg Radiol* 2011;18(04):363–367
- Mansour TR, Medhkour Y, Entezami P, Mrak R, Schroeder J, Medhkour A. The art of mimicry: anterior clinoid dural-based cavernous hemangioma mistaken for a meningioma. *World Neurosurg* 2017;100:708.e19–708.e22
- Boockvar JA, Stiefel M, Malhotra N, Dolinskas C, Dwyer-Joyce C, LeRoux PD. Dural cavernous angioma of the posterior sagittal sinus: case report. *Surg Neurol* 2005;63(02):178–181, discussion 181
- Li Z, Wang C, Ma L, Wu C, Zhao Y, Jiang Z. Multiple nodular dural cavernous angiomas occluding superior sagittal sinus and destructing calvarium: case report and literature review. *J Clin Neurosci* 2018;58:218–221
- Bteich F, Kassab C, El Hage G, Moussa R, Abadjian GA, Bou-Nassif R. Atypical presentation of a parietal convexity dural-based cavernous hemangioma: a case report and review of the literature. *World Neurosurg* 2019;128:403–407
- Ito J, Konno K, Sato I, Kameyama S, Takeda S. [Convexity cavernous hemangioma, its angiographic and CT findings. Report of a case (author's transl)]. *No To Shinkei* 1978;30(07):737–747 Japanese
- Perry JR, Tucker WS, Chui M, Bilbao JM. Dural cavernous hemangioma: an under-recognized lesion mimicking meningioma. *Can J Neurol Sci* 1993;20(03):230–233
- Shen WC, Chenn CA, Hsue CT, Lin TY. Dural cavernous angioma mimicking a meningioma and causing facial pain. *J Neuroimaging* 2000;10(03):183–185
- Wang X, Liu J-P, You C, Mao Q. Convexity dural cavernous haemangioma mimicking meningioma: a case report. *Br J Neurosurg* 2016;30(03):345–347. Doi: 10.3109/02688697.2015.1096904
- Chakravarthy HK, Mangaleswaran B, Boopesh P, Ambroise MM, Annapurneswari AliS. Dura-based cavernous hemangioma presenting as large intracerebral hematoma in a child: a rare clinicopathological entity. *J Pediatr Neurosci* 2011. Doi: 10.4103/1817-1745.92
- Pelluru PK, Rajesh A, Uppin MS. Dural-based giant cavernous hemangioma mimicking a meningioma: lessons learnt. *Neurol India* 2017;65(05):1173–1176
- Joshi V, Muzumdar D, Dange N, Goel A. Supratentorial convexity dural-based cavernous hemangioma mimicking a meningioma in a child. *Pediatr Neurosurg* 2009;45(02):141–145
- Di Vitantonio H, De Paulis D, Ricci A, Marzi S, Dehcordi SR, Galzio RJ. Cavernous hemangioma of the dura mater mimicking meningioma. *Surg Neurol Int* 2015;6(Suppl 13):S375–S378
- Hwang SW, Pfannl RM, Wu JK. Convexity dural cavernous malformation with intradural and extradural extension mimicking a meningioma: a case report. *Acta Neurochir (Wien)* 2009;151(01):79–83
- Lee AG, Parrish RG, Goodman JC. Homonymous hemianopsia due to a dural cavernous hemangioma. *J Neuroophthalmol* 1998;18(04):250–254
- Li G, Zhai X, Zhang Y, Liang P, Wu X, Hou K. Dural-based cavernous malformation at the cerebral convexity: report of two pediatric patients. *World Neurosurg* 2018;112:81–85 Epub2018Jan10. Doi: 10.1016/j.wneu.2018.01.009
- Dörner L, Buhl R, Hugo HH, Jansen O, Barth H, Mehdorn HM. Unusual locations for cavernous hemangiomas: report of two cases and review of the literature. *Acta Neurochir (Wien)* 2005; 147(10):1091–1096, discussion 1096
- Kim JS, Yang SH, Kim MK, Hong YK. Cavernous angioma in the falx cerebri: a case report. *J Korean Med Sci* 2006;21(05):950–953

- 36 Simonin A, Passaplan C, Sancho S, Rusconi A, Otten P. Giant extra-axial cavernous angioma of the falx: case report. *Neurosurgery* 2019. Doi: 10.1093/neuros/nyy080.PMID:30203083
- 37 Uzunoglu I, Guvenc G, Kizmazoglu C, et al. Cavernous angioma mimicking meningioma. *J Craniofac Surg* 2019;30(03):e218–e220
- 38 Gupta RK, Saran RK, Jagetia A, Narang P. Extra-axial dural cavernous hemangioma with dural tail sign, masquerading as meningioma. *J Neurosci Rural Pract* 2016;7(04):615–616
- 39 Kanaan I, Jallu A, Alwatban J, Patay Z, Hessler R. Extra-axial cavernous hemangioma: two case reports. *Skull Base* 2001;11(04):287–295
- 40 Lan Z, Richard SA, Li J, Xu J, You C. A giant solid cavernous hemangioma mimicking sphenoid wing meningioma in an adolescent: a case report. *Medicine (Baltimore)* 2018;97(44):e13098
- 41 Gutiérrez-González R, Casanova-Peño I, Porta-Etessam J, Martínez A, Boto GR. Dural cavernous haemangioma of the anterior cranial fossa. *J Clin Neurosci* 2010;17(07):936–938
- 42 Abuzayed B, Said A, Jamous O, Al-Ashqar O, Al-Abadi H, Alawneh K. Extra-axial cerebellopontine angle cavernoma: a case report and review of literature. *Surg Neurol Int* 2020;11:386
- 43 Adachi K, Yoshida K, Akiyama T, Kawase T. Cavernous angioma of the vestibular nerve: case report and literature review. *Surg Neurol* 2008;70(01):82–86, discussion 86. Doi: 10.1016/j.surneu.2007.04.008
- 44 Tarabay A, Rocca A, Maeder P, Simonin A, Messerer M, Daniel RT. Extra-axial cavernoma of the cerebellopontine angle: a case study and review of literature. *World Neurosurg* 2019;128:415–421
- 45 Beskonakli E, Kaptanoglu E, Okutan O, Solaroglu I, Taskin Y. Extra-axial cavernomas of the cerebellopontine angle involving the seventh-eighth nerve complex. *Neurosurg Rev* 2002;25(04):222–224
- 46 Brunori A, Chiappetta F. Cystic extra-axial cavernoma of the cerebellopontine angle. *Surg Neurol* 1996;46(05):475–476
- 47 Ghanta RK, Tangella P, Koti K, Dandamudi S. A rare case of an extra-axial cavernous angioma in the cerebellopontine angle. *J Neurosci Rural Pract* 2013;4(02):210–212
- 48 Kim M, Rowed DW, Cheung G, Ang LC. Cavernous malformation presenting as an extra-axial cerebellopontine angle mass: case report. *Neurosurgery* 1997;40(01):187–190
- 49 Wu B, Liu W, Zhao Y. Coexistence of extra-axial cavernous malformation and cerebellar developmental venous anomaly in the cerebellopontine angle. *World Neurosurg* 2012;78(3-4):375.e5–375.e9
- 50 Albanese A, Sturiale CL, D'Alessandris QG, Capone G, Maira G. Calcified extra-axial cavernoma involving lower cranial nerves: technical case report. *Neurosurgery* 2009;64(3, Suppl):E135–E136, discussion E136
- 51 Ke D, Deng X, Li X, Li J, Hui X. Calcified extra-axial cavernous malformation arising from lower cranial nerves: a case report and literature review. *Medicine (Baltimore)* 2021;100(05):e24566
- 52 Itshayek E, Perez-Sanchez X, Cohen JE, Umansky F, Spektor S. Cavernous hemangioma of the third cranial nerve: case report. *Neurosurgery* 2007;61(03):E653, discussion E653
- 53 Patro S, Kesavadas C, Kapilamoorthy TR. Right third nerve palsy caused by extra-axial cavernoma in a patient with multiple intracranial cavernomas. *Neuroradiol J* 2008;21(02):192–195
- 54 Ooi KH, Low SW. Fractionated external-beam radiation therapy for incompletely resected intracranial extra-axial cavernous haemangioma: a case report. *Cureus* 2018;10(03):e2285
- 55 Maenhoudt W, Hallaert G, Kalala JP. Complete resection of an intradural extramedullary foramen magnum cavernous malformation. *World Neurosurg* 2019;129:200–201
- 56 Reynier Y, Alliez B, Sena JC. [Unusual extra-axial infra-tentorial localization of a cavernoma in the cisterna magna]. *Neurochirurgie* 1995;41(02):116–119
- 57 Ito M, Kamiyama H, Nakamura T, Nakajima H, Tokugawa J. Dural cavernous hemangioma of the cerebellar falx. *Neurol Med Chir (Tokyo)* 2009;49(09):410–412
- 58 Melone AG, Delfinis CP, Passacantilli E, Lenzi J, Santoro A. Intracranial extra-axial cavernous angioma of the cerebellar falx. *World Neurosurg* 2010;74(4-5):501–504
- 59 Hsiang JN, Ng HK, Tsang RK, Poon WS. Dural cavernous angiomas in a child. *Pediatr Neurosurg* 1996;25(02):105–108
- 60 Jagannatha AT, Srikantha U, Khanapure K, Joshi KC, Varma RG. Giant posterior fossa dural cavernoma in a child. *Childs Nerv* 2017;33(04):691–694
- 61 Furuta T, Nakada M, Watanabe T, Hayashi Y, Hamada J. Progressive tentorial cavernous malformation. *Surg Neurol Int* 2012;3:18. Doi: 10.4103/2152-7806.92934