




Flexor Tendon Pulley Injuries: A Systematic Review of the Literature and Current Treatment Options

Stefano Artiaco¹  Francesco Bosco¹  Alessandro Lusso¹ Luigi Luca Cioffi² Bruno Battiston¹ 
Alessandro Massè¹

¹ Department of Orthopaedics and Traumatology, University of Torino, CTO Torino, Italy

² Department of Orthopaedics and Traumatology, CTO Napoli, Napoli, Italy

Address for correspondence Francesco Bosco, MD, Department of Orthopaedics and Traumatology, University of Torino, Via Zuretti, 29, 10126 Torino, Italy (e-mail: francescobosco@icloud.com).

J Hand Microsurg 2023;15:247–252.

Abstract

Closed injuries of the finger flexor pulley system are rare among the general population, and most of them occur during rock climbing. During the last few decades, scientific interest on this topic has increased. We conducted a systematic review of the literature according to the Preferred Reporting Items for Systematic reviews and Meta-Analyses (PRISMA) guidelines. The research was limited from January 2000 to March 2022. PubMed and Scopus databases were investigated for full-text articles published in English, French, and Italian using the following MeSH terms: ([pulley rupture] OR [finger pulley lesion]) AND ([injur*] OR [ruptur*] OR [damage] OR [trauma*]). Initial screening results identified 461 studies, among which 172 were included after including additional records identified through other sources and excluding repeated studies. Finally, four clinical studies were included in the analysis. The methodological quality of the articles was evaluated through the methodological index for nonrandomized studies (MINORS) score. Our search identified four studies that enrolled a total of 189 patients, of whom 164 were male and 25 were female. We finally examined 154 patients with a total of 208 pulleys damaged. Except for the thumb, all fingers were involved. Depending on the type of flexor pulley injury, graded with Schöffl classification, 69 patients underwent a surgical procedure, whereas 85 patients were treated conservatively. Closed finger pulleys injury occurred in rock climbers and non-rock climbers. All patients had excellent results on the Buck-Gramcko score regardless of the return to sports activity. Considering the overall outcomes of the reviewed articles, functional results were satisfactory in both conservative and surgical treatment. Moreover, in grade 3 and 4, surgical results were positive regardless of the specific technique used for finger pulley reconstruction. Only minor complications were reported. Closed flexor tendon pulley injuries require a careful clinical and imaging examination to confirm the diagnosis. In most cases, positive clinical results can be achieved with either conservative or surgical therapy.

Keywords

- ▶ bowstringing
- ▶ flexor tendon
- ▶ pulley reconstruction
- ▶ pulley rupture
- ▶ rock climbing

Introduction

The finger flexor pulleys act like a fibrous envelop preventing flexor tendons divergence from their anatomic location. They allow the conversion of pulling action into an angular motion that causes the finger joints to bend.¹ Pulley system injuries are overall rare; however, these lesions can be often observed in rock climbers. The reason for such peculiar finding is due to the position of the hand during the activity, called “crimp grip” with proximal interphalangeal joint (PIPJ) flexed to 90 to 100 degrees and distal interphalangeal joint (DIPJ) hyperextended. In this condition, flexor tendons apply very intense bowstringing forces on the pulleys. The repetitive loading on pulleys during rock climbing activity may lead to acute damages or to overuse syndrome.²

Depending on the characteristics of the lesion, Schöffl et al³ proposed a grading system to guide the therapeutic choice, dividing pulley injuries into four grades. He distinguished grade 1 with pulley strain, grade 2 with a complete rupture of A4 or partial rupture of A2, grade 3 with complete rupture A2 or A3, grade 4 with multiple ruptures (as A2/A3, A2/A3/A4) or single rupture (as A2 or A3) combined with lumbricalis muscle or collateral ligament trauma. Then, the author proposed conservative therapy for grade 1 to 3, and surgical treatment for grade 4 pulley injuries.³

During the last two decades, scientific literature on closed finger flexor pulley injuries increased. Nonetheless, until now, there are few published studies evaluating management strategies and treatment outcomes for this condition. The aim of this systematic review was then to gather current indications and treatment options for flexor tendon pulley injuries, and to evaluate clinical results of conservative and surgical repair reported in the literature.

Materials and Methods

Eligibility Criteria

This systematic review was conducted according to Preferred Reporting Items for Systematic reviews and Meta-Analyses (PRISMA) guidelines.⁴ We evaluated current evidence of closed finger pulley rupture treatments and outcomes. For the systematic review, we used the following inclusion criteria: articles published in English, French and Italian languages, studies published within the past 20 years, full text of the articles should be available, human studies only. We excluded from our research studies less than five participants, editorials, technical notes, preclinical studies, and review articles.

Search Strategy and Information Sources

The research was limited from January 2000 to March 2022. Our literature research of PubMed and Scopus database was performed using the following MeSH keywords: ([pulley rupture] OR [finger pulley lesion]) AND ([injur*] OR [ruptur*] OR [damage] OR [trauma*]). Initial screening results identified 461 studies, among which 172 were included after including additional records identified through other sources and excluding repeated studies.

Study Selection

Following the research, two reviewers (FB and AL) independently reviewed all articles to evaluate their contribution to this study using the aforementioned eligibility criteria. The title and abstract of all articles were reviewed. Furthermore, full text of each selected article was retrieved. After reviewing each study according to the inclusion and exclusion criteria, four clinical studies that analyzed closed finger pulley rupture treatments and outcomes were included in the analysis. The corresponding PRISMA flowchart diagram is shown in ►Fig. 1.

Data Items and Extraction

Extracted data were recorded in a Microsoft Excel spreadsheet (version 2016; Microsoft, Redmond, Washington, United States). A data collection tool was created by the authors extracting the following data: author and publication year, study design, number of groups, groups, sample size patients, follow-up, lost to follow-up, sample size patients treated, trauma mechanism, diagnosis, involved fingers, involved pulleys, lesion grade, treatment, surgical technique, outcomes, complications, sample size sex, sample size mean age (►Tables 1 and 2).

Evaluation of Methodological Quality

The Oxford Center for Evidence-Based Medicine 2011 level of evidence (LoE)⁵ was used by the authors to assess the strength of results in research studies. Articles were graded from levels 1 to 5. The methodological quality of the articles was evaluated independently by two authors (FB and AL) through the methodological index for nonrandomized studies (MINORS) score.⁶ The best methodological quality of a comparative article is set at 24 points, while case series can reach a maximum of 16 points. A third author (SA) resolved any cases of disagreement. All authors participated equally in the study design, manuscript preparation, and final review.

Results

In our systematic review, we identified four studies that enrolled a total of 189 patients, of whom 164 male and 25 females (male/female ratio, 0.87). In one clinical study³ the authors lost 35 patients during follow-up. Then, 154 patients with a total amount of 208 pulleys damaged (A2 $n = 150$, A3 $n = 25$, A4 $n = 33$) were finally examined. Except for the thumb, all fingers were involved (index finger $n = 1$, middle finger $n = 80$, ring finger $n = 106$, little finger $n = 2$). Closed finger pulleys injury occurred in rock climbers ($n = 142$) and in nonrock climbers' patients ($n = 12$). Depending on the type of flexor pulley injury, graded with Schöffl classification,³ 69 patients underwent a surgical procedure, whereas 85 patients were treated conservatively. The main demographic characteristics of patients collected from comprehensive research of literature are listed in ►Table 1.

In 2003, Schöffl et al studied 122 rock climbing patients with pulleys system injuries.³ Only 87 completed the follow-up, of whom 80 were treated conservatively and seven surgically with a “loop and a half” technique of pulley

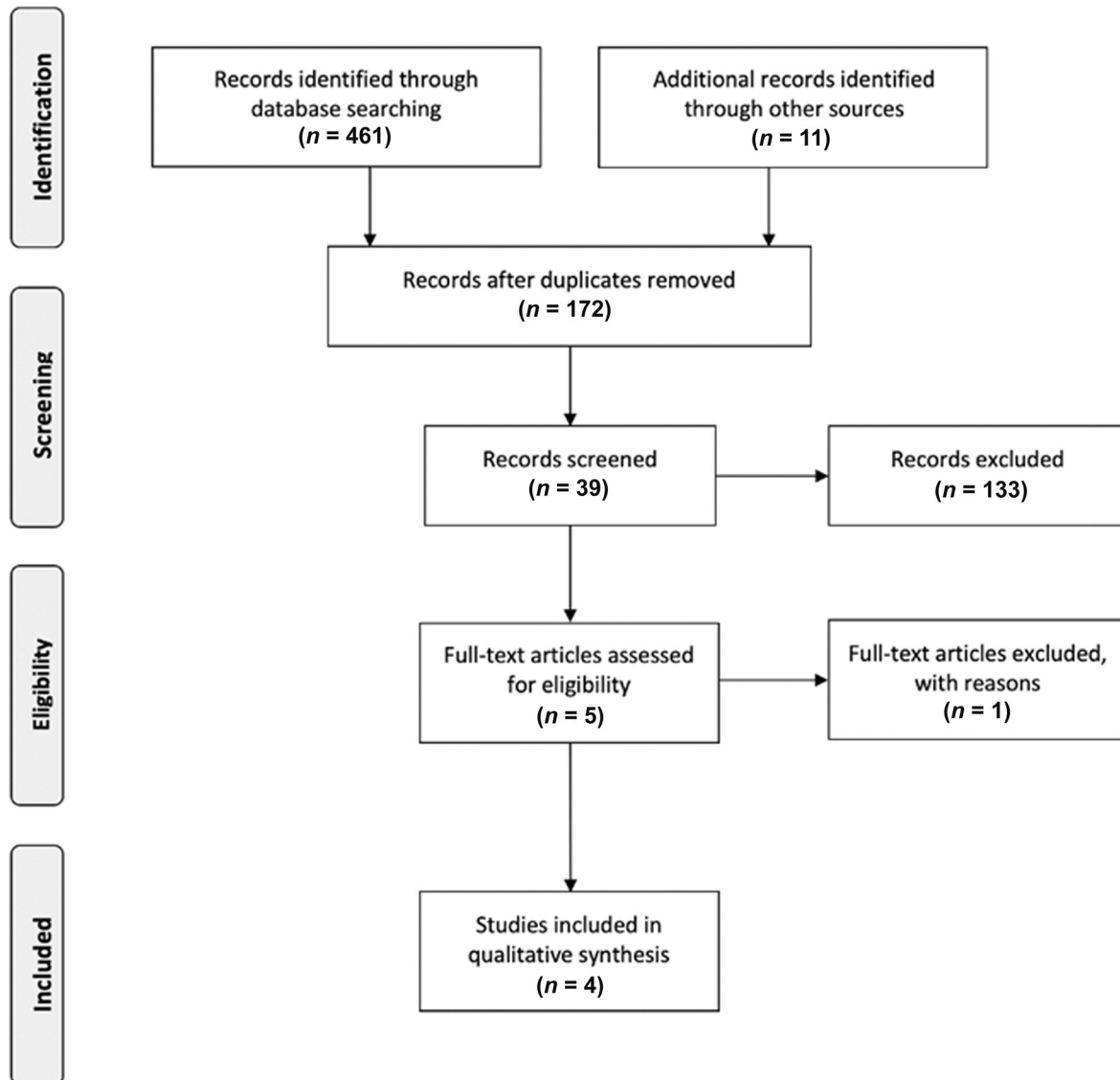


Fig. 1 Preferred Reporting Items for Systematic reviews and Meta-Analyses (PRISMA) flowchart diagram of the systematic review.

Table 1 Main demographic characteristics of patients collected from comprehensive research of literature

Author and publication year	Groups	Sample size patients	Sample size sex		Sample size mean age, yo
			M, n	F, n	
Schöffl et al (2003) ³	A	115	43	5	Not specified
	B	7	67	7	
Schöffl and Jüngert (2006) ⁷	A	5	3	3	44.6
	B	1			
Arora et al (2007) ¹⁰	A	13	11	2	41
	B	10	9	1	
Bouyer et al (2016) ¹¹	A	30	24	6	Not specified
	B	8	7	1	

Abbreviations: F, female; M, male; n, number (of patients); yo, years old.

Table 2 Summary results of the included studies

Author and publication year	Trauma mechanism	Diagnosis	Groups	Sample size patients treated	Involved fingers	Involved pulleys	Lesion grade	Treatment	Surgical technique	Outcomes	Complications	
Schöffl et al (2003) ³	Rock climbing	Clinical, US, MRI	A	80	III (n=47) IV (n=73) V (n=2)	A2 (n=88) A3 (n=13) A4 (n=31)	1, 2, 3 4	Conservative Surgical		Not specified The "pop-and-a-half" technique of Wildstrom	Not specified 1 3 2 1 0	7 0
			B	7								
Schöffl and Jungert (2006) ⁷	Non-rock climbing	Clinical, US, MRI	A	5	III (n=3) IV (n=3)	A2 (n=6)	1, 3	Conservative Surgical		Lister's Extensor Retinaculum Technique	Not specified 5 0 0 0 0 0 0 0	2
			B	1			3					
Arora et al (2007) ¹⁰	Rock climbing and non-rock climbing	Clinical, US, MRI	A	13	III (n=17) IV (n=6)	A2 (n=23) A3 (n=9)	Complete closed flexor tendon pulleys injuries (grade nonspecified)	Surgical		Lister's Extensor Retinaculum Technique	Not specified 10 2 1 0 48/50 8/8	0
			B	10								
Bouyer et al (2016) ¹¹	Rock climbing	Clinical, US, MRI, CT	A	30	II (n=1) III (n=13) IV (n=24)	A2 (n=33) A3 (n=3) A4 (n=2)	Complete closed flexor tendon pulleys injuries (grade nonspecified)	Surgical		Lister's Extensor Retinaculum Technique	Not specified 38 0 0 0 Not specified	15
			B	8								

Abbreviations: %, percentage; kg, kilogram; MRI, magnetic resonance imaging; inj., injury; kg, kilogram; MRI, magnetic resonance imaging; n, number (of patients); not inj., not injury; TAM, total active motion; US, ultrasonography.

reconstruction. No data were reported about mean age, surgical timing, and mean follow-up. According to Schöffl criteria, grade 1 to 3 injuries received conservative therapy, and grade 4 injuries received surgical repair. Outcomes were analyzed with a nonclinical score by assessing the level of return to sports activity according to the Union Internationale des Associations d'Alpinisme (UIAA).³ All patients treated conservatively returned to their previous level of sports activity, except for seven who needed more time to return to full recovery because of persistent pain due to tenovaginitis. Surgically treated patients presented "very good" results in one case, "good" in three cases, "sufficient" in two cases, and "poor" in one according to the return to UIAA sports activity level. All the patients required finger protection as part of the treatment.

Three years after their previous study, Schöffl et al published another study evaluating six nonclimbing patients with flexor pulley injuries.⁷ All patients were treated conservatively except one, who underwent pulley reconstruction using a retinaculum extensor graft. The mean age of patients was 44.6 years, and the mean follow-up time was 6 weeks. Clinical outcomes were "excellent" for all the patients according to Buck-Gramcko score.^{8,9} A 5 degrees PIPJ extension deficit was found in two cases.

In 2007, Arora et al conducted a study on 23 patients with complete closed flexor tendon pulleys injuries who underwent surgical treatment.¹⁰ In 13 cases, pulley reconstruction was performed using a retinaculum extensor graft (group A), and in 10 cases using a free tendon graft of palmaris longus (group B). The average age in group A was 41 years, and 38 years in group B. In group A, the interval between injury and surgical procedure was 9 weeks with a follow-up of 58 months, whereas in group B, the interval time was 7 weeks and the average follow-up was 57 months. The authors used Buck-Gramcko score to evaluate the two surgical procedure outcomes. In group A, ten patients achieved "excellent" results, two "good" results, one "fair" result. In group B, seven patients had "excellent" results, two "good" results, and one "fair" result. Pitch and grip strength were also analyzed noting very good outcomes in both groups. No complications were found in group A and B.

In 2016, Bouyer et al published a work involving 38 patients with complete pulley injuries evaluated on 85 months follow-up.¹¹ The mean age of the patients included in the series was not reported. Patients enrolled in the study were divided into two groups based on the return to previous climbing activity. Those who returned to their prior sport level (n=30) showed less than 2 mm US E-space (defined as the residual bowstringing, corresponding to the distance from phalanx to the deep face of the tendon of the finger flexors) in 70% of cases, permanent pain in 20%, a PIPJ extension deficit greater than 10 degrees in 19%, a grip strength of 102%, a tip pinch strength of 97%, and a total active motion (TAM) score of 97%.

Patients who were unable to return to their previous climbing level (n=8) had significantly worse results showing less than 2 mm US E-space in 25% of cases, persistent pain after the treatment in 50%, a PIPJ extension deficit greater

than 10 degrees in 25%, a grip strength of 94%, a tip pinch strength of 82%, and a TAM of 93%. In this group, the interval time between injury and surgical treatment averaged 6.8 months, being 2.4 months longer than in the group with a complete return to sport level.

All patients had excellent results on the Buck-Gramcko score regardless of the return to sports activity. The following complications were noted: failed procedures ($n = 2$), pulp paraesthesia on involved finger ($n = 2$), asymptomatic flexor nodule ($n = 1$), extensor bowstringing on the harvested wrist ($n = 6/30$, $n = 4/8$).

A comprehensive evaluation of each article reviewed is available in ► **Table 2**.

Discussion

Flexor pulley injuries are a clinical entity of great interest in hand surgery, and most of these injuries occurred during rock climbing. This activity gained popularity over the last years, being recently included in Olympic sport disciplines.^{12,13} Then, at present, a large number of athletes is potentially exposed to these otherwise uncommon injuries.

Flexor tendon pulleys represent 33% of all injuries observed during climbing, and in competitive athletes, there is an estimated 19 to 26% incidence of pulley ruptures.^{12,13} The most commonly injured sites are the middle and the ring fingers,¹⁴ with the A2 pulley being the most frequently damaged pulley followed by A4.^{15,16} Patients describe the moment of the trauma as an acute pain onset, or a “tearing” sensation, occasionally accompanied by a loud “pop” and followed by impairment in flexion movements and decreased finger dexterity.^{1,2}

Bowstringing, which is a very typical injury sign, is not always observed. It may lead to incomplete shortening of the tendon during muscle contraction, resulting in a loss of power in pinching and grasping.² These findings are not specific, therefore imaging with the radiographic exam, ultrasound (US), and magnetic resonance imaging (MRI) is usually needed to confirm diagnostic suspicion.^{16,17}

The data extracted in this systematic review of the literature showed that the indication for conservative versus surgical treatment is still debated.

Schöffl et al^{3,7} according to his classification treated conservatively grade 1 to 3 pulley injuries, reserving surgery for grade 4. The only exception was a patient with a grade 3 injury who was treated surgically suspecting an underlying flexor tendon injury. The surgical technique adopted by Schöffl et al in 2003 was Widstrom's loop-and-a-half technique: a free palmaris longus graft wrapped around the phalanx and passed through a surgically opened operculum in the thickness of the graft, then each end is sutured on both sides. The 2006 surgical procedure was the Lister's Extensor Retinaculum Technique. In this technique, the surgeon harvests an extensor retinaculum graft, which is wrapped around the phalanx and then sutured to itself.^{3,7,14,16}

Arora et al¹⁰ preferred conservative treatment for partial pulley ruptures. In 23 patients surgically treated in his study, 14 showed A2 pulley rupture (Schöffl grade 3), and nine

showed combined A2 and A3 ruptures (Schöffl grade 4). Two types of surgical procedures were used. The first is the Kleinert/Weilby Technique (Shoelace Weave), in which the surgeon harvests an flexor digitorum superficialis (FDS) graft, which is then passed like a shoelace through the holes created in the remaining pulley stumps. The second technique was the Lister's Extensor Retinaculum Technique described above.^{10,14,16}

Finally, Bouyer et al¹¹ reported that in their series including 38 cases, surgical treatment was performed in two patients with grade 2, thirty patients with grade 3, and six patients with grade 4 according to Schöffl classification.³ Bouyer et al also adopted the Lister's Extensor Retinaculum Technique as the surgical procedure they used.^{11,16}

Overall, surgical treatment was never indicated in grade 1 (pulley strain), rarely indicated in grade 2 (partial pulley rupture of A2 or A3, complete rupture of A4), and almost always performed in grade 3 (complete rupture of A2 or A3), and grade 4 (combined ruptures A2-A3 or A2-A3-A4).

The grade 3 flexor pulley injury appeared then as a gray zone area in which both conservative and surgical treatment may give favorable results and return to the sports activity level in rock climbing athletes.

The physical therapy protocol prescribed by Schöffl et al³ is related to the grade of injury. In grade 1, a functional therapy of 2 to 4 weeks is recommended, without any prescribed immobilization, but protection of the pulley by taping is recommended. In grade 2, immobilization for 10 days is recommended, followed by cautious functional therapy for 2 to 4 weeks, and tape to protect the damaged pulley. Immobilization is extended to 14 days in grade 3 and grade 4, which are more frequently surgically treated, with functional therapy for up to 4 weeks and protection of the damaged pulley with a thermoplastic ring. Various scores could evaluate the results after treatment, whether conservative or surgical.

Regarding the assessment of clinical outcomes, the Buck-Gramcko score was the most frequently used in the studies included in this systematic review.^{7,10,11} The total number of patients evaluated with the Buck-Gramcko and treated conservatively was five, and all reported an “excellent” outcome. The total number of patients treated surgically evaluated with the Buck-Gramcko score was 62, of whom 56 reported an “excellent” result, four “good,” two “fair,” and no “poor.”

Schöffl et al did not evaluate clinical outcomes with Buck-Gramcko score in their article published in 2003.³ Nonetheless, they reported largely favorable results for conservative treatment with the UIAA score. Similarly, the outcome of the surgically treated patients evaluated with the same score was “excellent” in one case, “good” in three, “fair” in two, and “poor” in one.

Functional results were satisfactory in both conservative and surgical treatment, considering the overall outcomes of the reviewed articles. Moreover, surgical results were more positive than conservative results in grades 3 and 4 regardless of the specific technique used for finger pulley reconstruction. For this reason, conservative treatment is a reasonable choice for patients with low-grade lesions. At

the same time, surgical treatment should be considered in the first instance, when patients are affected by more severe acute injuries, independently of the technique used, as studies show that in high-grade lesion surgical treatment is more effective than conservative treatment in functional recovery and return to sport.¹⁸⁻²⁰

Our systematic review showed some limitations that must be mentioned. First, it must be said that the number of papers reviewed was small and that the studies included in the analysis were all retrospective case series. The age of the patients, the time of follow-up, and the surgical timing were not reported in all the studies. Furthermore, Arora et al¹⁰ and Bouyer et al¹¹ in their studies mentioned complete closed flexor tendon pulleys injuries not specifying the injury grade. The outcome assessment was heterogeneous because the same score was not used in all the studies. A significant loss of patients during follow-up (35 patients) was observed in the first study published by Schöffl et al, and the outcomes were reported with a nonclinical score difficult to interpret.³ The choice of surgical techniques was also performed according to the author's preference, and no gold standard procedure could be suggested.

Conclusion

Closed flexor tendon pulley injuries require careful examination and a high index of suspicion, particularly in patients who are involved in the sports activity. Radiographic exam, US, and MRI are suggested to confirm the diagnosis and detect the grade of soft tissue injury. On this basis, the most appropriate treatment can be selected, and in most cases, positive clinical results can be achieved with either conservative or surgical therapy.

Ethical Approval

All procedures performed in studies involving human participants were in accordance with the ethical standards of the institutional and/or national research committee and with the 1964 Helsinki Declaration and its later amendments or comparable ethical standards.

Funding

This research received no external funding.

Conflicts of Interest

The authors declare no conflicts of interest.

Acknowledgments

None.

References

- 1 Dy CJ, Daluiski A. Flexor pulley reconstruction. *Hand Clin* 2013;29(02):235-242
- 2 Crowley TP. The flexor tendon pulley system and rock climbing. *J Hand Microsurg* 2012;4(01):25-29
- 3 Schöffl V, Hochholzer T, Winkelmann HP, Strecker W. Pulley injuries in rock climbers. *Wilderness Environ Med* 2003;14(02):94-100
- 4 Liberati A, Altman DG, Tetzlaff J, et al. The PRISMA statement for reporting systematic reviews and meta-analyses of studies that evaluate health care interventions: explanation and elaboration. *PLoS Med* 2009;6(07):e1000100
- 5 Burns PB, Rohrich RJ, Chung KC. The levels of evidence and their role in evidence-based medicine. *Plast Reconstr Surg* 2011;128(01):305-310
- 6 Slim K, Nini E, Forestier D, Kwiatkowski F, Panis Y, Chipponi J. Methodological index for non-randomized studies (minors): development and validation of a new instrument. *ANZ J Surg* 2003;73(09):712-716
- 7 Schöffl VR, Jüngert J. Closed flexor pulley injuries in nonclimbing activities. *J Hand Surg Am* 2006;31(05):806-810
- 8 Buck-Gramcko D, Dietrich FE, Gogge S. Bewertungskriterien bei Nachuntersuchungen von Beugesehenwiederherstellungen. [Evaluation criteria in follow-up studies of flexor tendon therapy] *Handchirurgie* 1976;8(02):65-69
- 9 Nielsen AB, Jensen PO. Methods of evaluation of the functional results of flexor tendon repair of the fingers. *J Hand Surg [Br]* 1985;10(01):60-61
- 10 Arora R, Fritz D, Zimmermann R, et al. Reconstruction of the digital flexor pulley system: a retrospective comparison of two methods of treatment. *J Hand Surg Eur Vol* 2007;32(01):60-66
- 11 Bouyer M, Forli A, Semere A, Chedal Bornu BJ, Corcella D, Moutet F. Recovery of rock climbing performance after surgical reconstruction of finger pulleys. *J Hand Surg Eur Vol* 2016;41(04):406-412
- 12 Cole KP, Uhl RL, Rosenbaum AJ. Comprehensive review of rock climbing injuries. *J Am Acad Orthop Surg* 2020;28(12):e501-e509
- 13 Jones G, Johnson MI. A critical review of the incidence and risk factors for finger injuries in rock climbing. *Curr Sports Med Rep* 2016;15(06):400-409
- 14 King EA, Lien JR. Flexor tendon pulley injuries in rock climbers. *Hand Clin* 2017;33(01):141-148
- 15 Cockenpot E, Lefebvre G, Demondion X, Chantelot C, Cotten A. Imaging of sports-related hand and wrist injuries: sports imaging series. *Radiology* 2016;279(03):674-692
- 16 Freilich AM. Evaluation and treatment of jersey finger and pulley injuries in athletes. *Clin Sports Med* 2015;34(01):151-166
- 17 Bianchi S, Martinoli C, de Gautard R, Gaignot C. Ultrasound of the digital flexor system: normal and pathological findings(). *J Ultrasound* 2007;10(02):85-92
- 18 Desai B, Sumarriva G, Dunbar R. Closed traumatic A2 through A4 pulley rupture and flexor digitorum superficialis avulsion treated with reconstruction. *Ochsner J* 2021;21(01):99-103
- 19 Soulii L, Amirouche F, Solitro G, et al. Evaluation of A2 and A4 hand pulley repair using tendon graft rings. *J Hand Surg Am* 2021;46(07):626.e1-626.e6
- 20 Jakubietz MG, Meffert RH, Schmidt K, Gruenert JG, Jakubietz RG. Acute A4 pulley Reconstruction with a first extensor compartment onlay graft. *Plast Reconstr Surg Glob Open* 2017;5(06):e1361