


Perioperative Clinical Features of Mediastinal Parathyroid Adenoma: A Case Series

Fuqiang Wang^{1,†} Hanlu Zhang^{1,†} Guanghao Qiu¹ Yun Wang¹ 

¹Department of Thoracic Surgery, Sichuan University West China Hospital, Chengdu, Sichuan, China

Thorac Cardiovasc Surg 2022;70:596–600.

Address for correspondence Yun Wang, MD, PhD, Department of Thoracic Surgery, Sichuan University West China Hospital, No. 37, Guoxue Alley, Chengdu, Sichuan 610041, China (e-mail: yunwwang@yeah.net).

Abstract

Rare ectopic mediastinal parathyroid adenoma can result in persistent or recurrent hyperparathyroidism. In this article, we summarized the perioperative outcomes of six patients with mediastinal parathyroid adenoma. All patients underwent minimally invasive surgery (MIS). Abnormal accumulation of sestamibi was observed in four of five patients for preoperative localization of adenoma. Postoperatively, the blood calcium dropped quickly. In addition, we found adenoma function was negatively related to adenoma volume in these patients. In conclusion, although MIS is feasible for parathyroid adenoma, blood calcium should be monitored in a timely manner to avoid hypocalcemia postoperatively. In addition, sestamibi might be a potential pitfall when locating parathyroid adenoma.

Keywords

- ▶ Parathyroid adenoma
- ▶ mediastinum
- ▶ parathyroidectomy

Introduction

Parathyroid adenoma is a benign tumor that can secrete excessive parathyroid hormone (PTH) and thus lead to primary hyperparathyroidism (PHPT).¹ High PTH levels results in osteoporosis, recurrent renal stones and even fragility fractures. Thus, parathyroidectomy is recommended as an effective method to manage PHPT caused by parathyroid adenoma.¹

Generally, parathyroid adenoma is located in the neck and near the thyroid. In rare cases, the adenoma can also be found in the mediastinum, carotid sheath and thymus.² It has been reported that the incidence of ectopic parathyroid glands ranges from 6 to 16%.³ Moreover, ectopic adenoma is the main cause of persistent or recurrent HPT after parathyroidectomy.² Technetium 99m sestamibi (MIBI) scintigraphy is effective and widely applied to help locate the parathyroid adenoma preoperatively.⁴ Due to the rare incidence, the perioperative outcomes of ectopic mediastinal parathyroid adenoma have rarely been discussed. In this case series, we presented six PHPT patients with mediastinal

parathyroid adenoma and summarized the perioperative outcomes and changes in the biochemical values of these patients.

Materials and Methods

We consecutively reviewed six patients diagnosed with mediastinal parathyroid adenoma between March 2013 and October 2020 in our department. All patients met the indication in the guidelines for Definitive Management of Primary Hyperparathyroidism from the American Association of Endocrine Surgeons.⁵ The inclusion criteria included (1) hypercalcemia (serum calcium > 2.5 mmol/L), (2) hyperparathyroidism (intact PTH [iPTH] > 6.9 pmol/L) and (3) ectopic mediastinal parathyroid adenoma confirmed by final pathology. Patients with secondary or tertiary hyperparathyroidism, parathyroid hyperplasia, multiglandular adenomas, multiple endocrine neoplasia, and familial PHPT were excluded. The clinical data were collected in the hospital information system of our medical center. The study was approved by the Ethics Committee of West China Hospital of Sichuan University (2021–578). Written informed consent was obtained from all patients.

[†] These authors contributed equally to this work.

received
January 14, 2022
accepted after revision
April 4, 2022
published online
July 28, 2022

© 2022, Thieme. All rights reserved.
Georg Thieme Verlag KG,
Rüdigerstraße 14,
70469 Stuttgart, Germany

DOI <https://doi.org/10.1055/s-0042-1750026>
ISSN 0171-6425.

Before surgery, computed tomography/cervical ultrasonography and MIBI scintigraphy were applied to locate the hyperfunctioning adenoma. Serum iPTH, calcium and phosphorus were assayed pre- and postoperatively. We defined the changes in serum calcium and phosphorus as the difference between serum calcium and phosphorus before and 3 days after the surgery. The secretory function of adenoma was defined as the ratio of iPTH released per volume of excised adenoma.⁶ The ectopic adenomas of all patients were resected with a minimally invasive method. The three-dimensional mode of ectopic adenoma was constructed with Materialise's interactive medical image control system (MIMICS, Version 21.0, Materialise, Switzerland) to estimate the volume of adenoma.

Categorical data are expressed as counts (percentages). Bivariate correlations were calculated by Spearman's correlation test. p -Values < 0.05 and $|r| \geq 0.3$ were considered indicative of factors that were significantly correlated with each other.

Results

As shown in ►Table 1, the median age of these patients was 56.5 years. The median body mass index was 24.49 kg/m². The most common symptom was body pain, and the most common morbidities were hypercalcemia, osteoporosis, and renal stones. Of them, four patients underwent video-assisted thoracoscopic surgery, and two patients underwent robot-assisted thoracic surgery. The median adenoma volume was 9.69 cm³.

As shown in ►Fig. 1, the blood calcium and iPTH dropped quickly after parathyroidectomy. The median reductions in blood iPTH and calcium were 38.88 and 0.685 mmol/L, respectively. However, blood phosphorus did not change significantly before and after parathyroidectomy. Moreover, hypocalcemia occurred in five patients (83.3%) and was threatened by oral calcium supplements and calcitriol.

MIBI scintigraphy was performed in five patients, and abnormal accumulation was observed in four patients (►Fig. 2). In patient 2, a large mass (72.92 cm³) was found in the posterior mediastinum, and MIBI scintigraphy was negative. Ultrasonography showed that this mass was a solid-cystic neoplasm. Simultaneously, a 1.3 cm ground glass node (GGN) with pleural retraction was found in the right upper lobe posterior segment. Thus, we performed video-assisted thoracoscopic surgery mediastinal tumor resection and right upper lobe posterior segmentectomy with lymph node dissection (GGN was diagnosed as adenocarcinoma via frozen section). On final pathology, this mediastinal tumor was found to be the parathyroid adenoma.

According to previous studies, we also estimated adenoma function by calculating the ratio of iPTH released per volume of excised adenoma (►Fig. 3). We found that adenoma function was strongly negatively related to adenoma volume ($p = 0.005$, $r = -0.94$).

Discussion

In this case series, we detailed the clinical characteristics of these patients. In accordance with the typical clinical manifestations of PHPT, the most common symptom of patients

in this research was body pain. The most common manifestations of these patients were hypercalcemia, osteoporosis, and renal stones. A MIBI scintigraphy-negative adenoma was found. Moreover, serum calcium can decrease rapidly due to the removal of hyperactive adenoma. Five patients experienced hypocalcemia after the operation. Furthermore, we estimated the volume of adenoma with MIMICS software and found that the secretory function of adenoma might be negatively correlated with volume.

In this case series, the clinical manifestations of these patients were typical for PHPT. Moreover, after the removal of adenoma, the blood calcium dropped rapidly. It has been reported that hypocalcemia is more likely to occur after the resection of large adenomas.⁷ In this case series, the median adenoma volume was 9.69 cm³, and five patients experienced postoperative hypocalcemia. Thus, it is important to monitor blood calcium in a timely manner and use calcium supplements once hypocalcemia is detected after parathyroidectomy.

MIBI scintigraphy was recommended to locate the parathyroid adenoma.⁴ However, a slightly high false-negative rate might impair the diagnostic efficiency of MIBI scintigraphy.⁴ In this research, false-negative MIBI scintigraphy was confirmed in one patient. It has been reported that MIBI can also be accumulated by thymoma and is significantly correlated with its clinical stage.⁸ This false-positive MIBI scintigraphy may also misguide surgery. Thus, despite the importance of MIBI for locating parathyroid adenoma, surgeons should be aware of this "potential pitfall."⁹ Recently, ¹⁸F-fluorocholine positron emission tomography/computed tomography (PET/CT) was recommended as an alternative first-line method to locate the adenoma.⁴ The sensitivity of this imaging method in PHPT is more than 90%.⁴ In addition, ¹⁸F-fluorocholine PET/CT was still effective in locating MIBI-negative hyperfunctioning tissue in patients with PHPT.⁴ However, this novel method was not applied in this article.

Moreover, the secretion efficiency of large parathyroid adenoma might negatively correlate with volume. Previous studies have shown that the level of preoperative serum PTH was positively correlated with the volume and weight of adenoma.¹⁰ However, further studies have shown that the secretion efficiency of parathyroid adenoma (the ratio of iPTH released per weight or volume of adenoma) might negatively correlate with its volume.⁶ The results of our research are in accordance with this view. The reason for this negative correlation can be explained by two hypotheses.⁶ First, the larger the adenoma volume is, the more inactive cells there are. The larger adenoma might be filled with more endocrine inactive portions, such as fibrous tissue, cystic components, and cholesterol clefts. Second, endocrine regulation may play an important role. Excessive PTH might activate stronger negative regulation. Thus, the growth of adenoma may not increase the level of PTH to the same magnitude in PHPT patients. However, further study with more samples is needed to confirm this negative correlation in parathyroid adenoma.

In summary, despite the importance of MIBI for locating parathyroid adenoma preoperatively, surgeons should be aware of this "potential pitfall." After the operation, blood

Table 1 Patients' information

	Patient 1	Patient 2	Patient 3	Patient 4	Patient 5	Patient 6
Age	47	55	86	58	70	53
Sex	Female	Male	Female	Male	Female	Male
BMI (kg/m ²)	24.24	26.53	22.21	26.04	24.73	19.72
Chief complaint	Right leg pain	Postmediastinal tumor found during periodic health examination	Hypercalcemia	Repeated osphalgia	Right leg pain, dry mouth, polyphagia and polyuria for 2 months	Repeated osphalgia and dry mouth
Manifestation	Hypercalcemia; osteoporosis	Hypercalcemia; reduced glucose tolerance; hypertension; hypercholesteremia; renal stone	Hypercalcemia; osteoporosis	Osteoporosis; hypertriglyceridemia; vitamin D deficiency	Osteoporosis; vitamin D deficiency; hyperuricemia; gallstones; renal stone; osteoarthritis	Hypercalcemia
Location	Between the trachea and superior vena cava	Posterior mediastinum	Retroesophageal space	Anterior mediastinum	Retroesophageal space	Anterior mediastinum
Operation method	VATS	VATS	VATS	RATS	RATS	VATS
MIBI scintigraphy	+	-	n.d.	+	+	+
Postoperative hypocalcemia Date of occurrence	Yes/POD1	Yes/POD1	Yes/POD2	Yes/POD1	Yes/POD3	No
Estimated volume (cm ³)	17.57	72.92	0.91	1.81	18.64	0.93
Pre-Ca (mmol/L)	2.97	2.78	2.88	2.27	2.58	2.86
Pre-P (mmol/L)	0.53	0.66	0.70	0.49	0.58	0.64
Pre-PTH (pmol/L)	136.55	54.81	30.04	42.45	200.55	46.35
ΔCa ^a (mmol/L)	1.10	0.95	0.85	0.42	0.52	0.36
ΔP ^a (mmol/L)	-0.06	-0.24	0.15	0.06	-0.06	-0.17
ΔPTH ^b (pmol/L)	130.73	38.87	22.36	34.75	196.62	38.89
Postoperative hospital stays (days)	6	10	11	6	9	2

Abbreviations: BMI, body mass index; COPD, chronic obstructive pulmonary disease; LUAD, lung adenocarcinoma; MIBI, technetium-99m methoxyisobutylisotrile; n.d., not done; POD, postoperative day; PTH, parathyroid hormone; RATS, robot-assisted thoracic surgery; VATS, video-assisted thoroscopic surgery.

^aΔCa and ΔP were calculated by (the mean value within 72h after surgery) minus (preoperative mean value).

^bΔPTH was calculated by (postoperative mean PTH) minus (postoperative mean PTH).

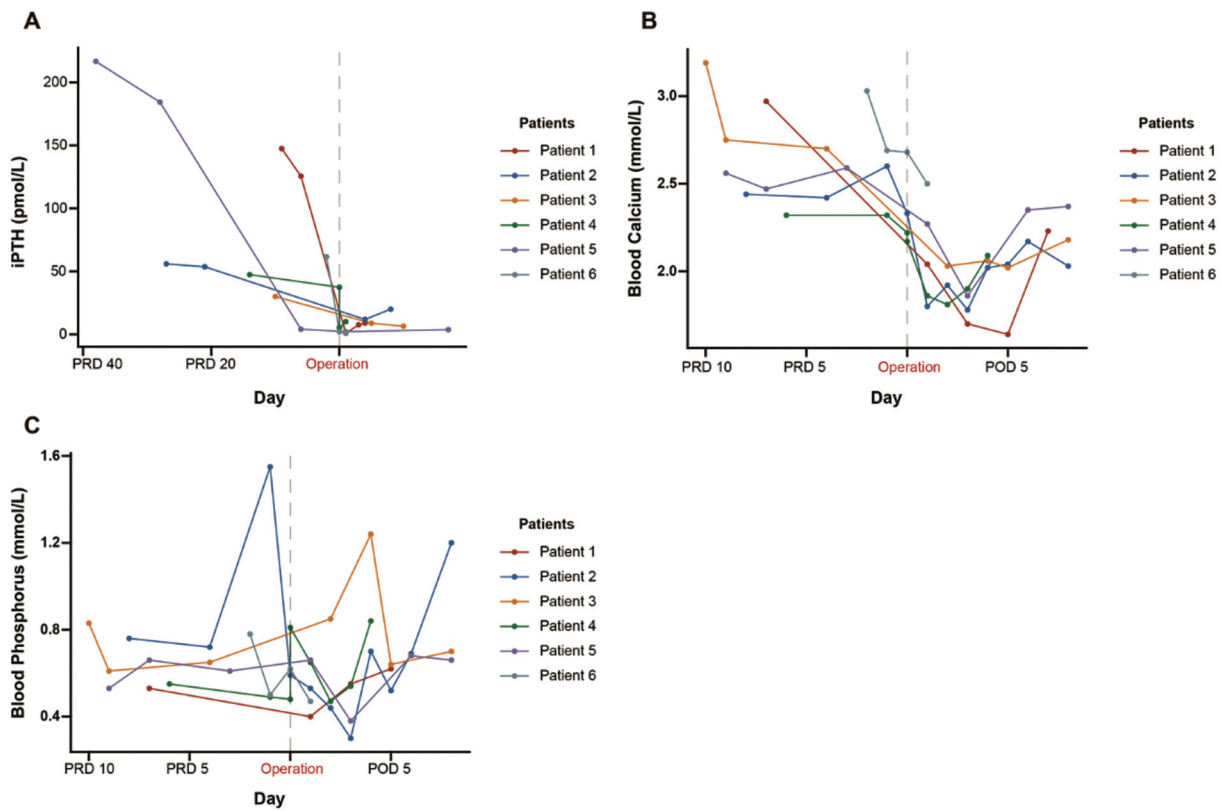


Fig. 1 Changes in biochemical values before and after surgery. Changes in iPTH (A), blood calcium (B), and blood phosphorus (C). POD, postoperative day; PRD, preoperative day; iPTH, intact parathyroid hormone.

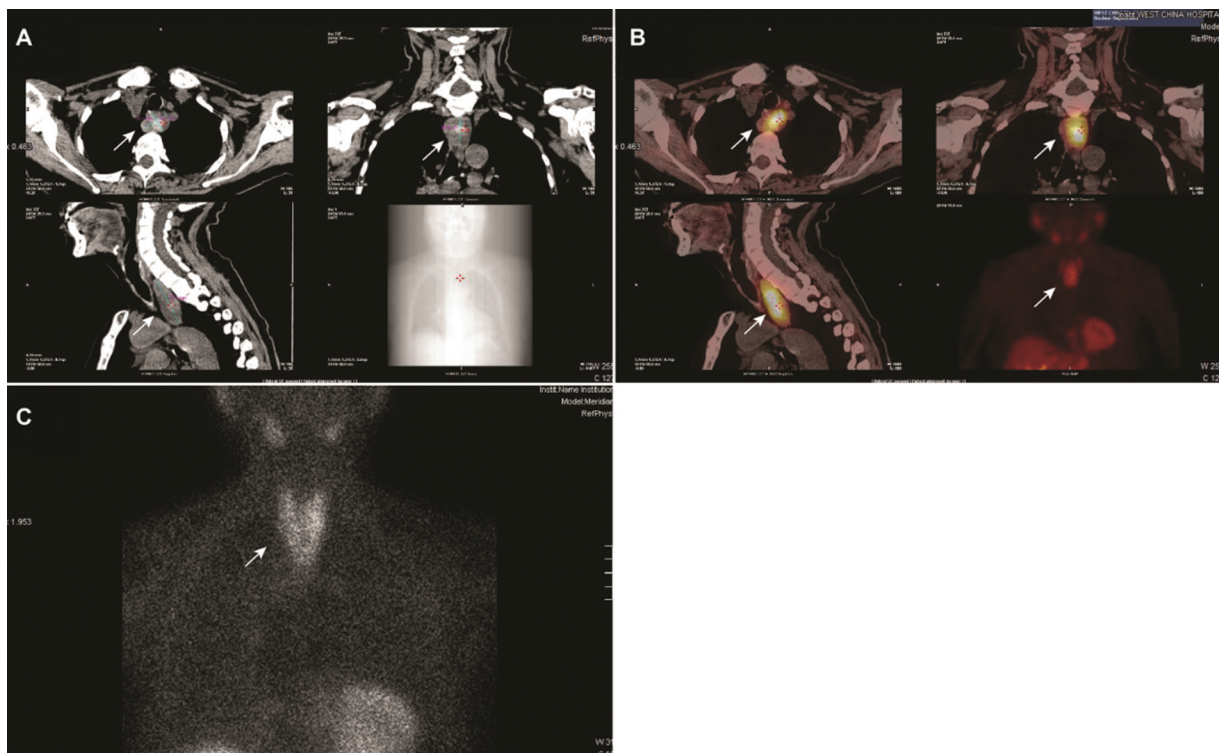


Fig. 2 Ectopic mediastinal parathyroid adenoma in preoperative imaging. (A) Adenoma on computed tomography (CT) scan (white arrow). (B) and (C) Technetium 99m sestamibi images of adenoma (white arrow) and the merged images with CT scan.

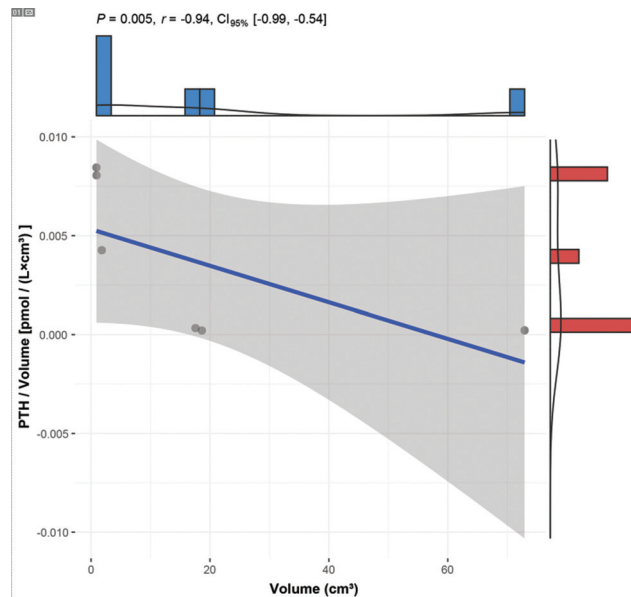


Fig. 3 The negative correlation between adenoma's secretory function and adenoma volume. PTH, parathyroid hormone.

calcium should be monitored in a timely manner to avoid hypocalcemia and even seizures.

Funding

This study was supported by the 1-3-5 project for disciplines of Excellence-Clinical Research Incubation Project, West China Hospital, Sichuan University (No. 2021HXFH056), the grants from the Key Research Project of Sichuan Province (No. 2020YFS0249), and grants from National Key Research Project of China (No. 2017YFC0113502).

Conflict of Interest

None declared.

Acknowledgments

Additionally, we would like to thank the Library & Information Center of West China Hospital, Sichuan University for kind help in language polishing. This article was edited for language by American Journal Experts (AJE).

Fuqiang Wang and Hanlu Zhang designed the study, performed data interpretation and participated in study coordination. They therefore share equal authorship.

References

- 1 Bilezikian JP, Bandeira L, Khan A, Cusano NE. Hyperparathyroidism. *Lancet* 2018;391(10116):168–178
- 2 Roy M, Mazeh H, Chen H, Sippel RS. Incidence and localization of ectopic parathyroid adenomas in previously unexplored patients. *World J Surg* 2013;37(01):102–106
- 3 Phitayakorn R, McHenry CR. Incidence and location of ectopic abnormal parathyroid glands. *Am J Surg* 2006;191(03):418–423
- 4 Petranović Oščariček P, Giovanella L, Carrió Gasset I, et al. The EANM practice guidelines for parathyroid imaging. *Eur J Nucl Med Mol Imaging* 2021;48(09):2801–2822
- 5 Wilhelm SM, Wang TS, Ruan DT, et al. The American Association of Endocrine Surgeons Guidelines for Definitive Management of Primary Hyperparathyroidism. *JAMA Surg* 2016;151(10):959–968
- 6 Hamidi S, Aslani A, Nakhjavani M, Pajouhi M, Hedayat A, Kamalian N. Are biochemical values predictive of adenoma's weight in primary hyperparathyroidism? *ANZ J Surg* 2006;76(10):882–885
- 7 Spanheimer PM, Stoltze AJ, Howe JR, Sugg SL, Lal G, Weigel RJ. Do giant parathyroid adenomas represent a distinct clinical entity? *Surgery* 2013;154(04):714–718, discussion 718–719
- 8 Fiorelli A, Vicidomini G, Laperuta P, et al. The role of Tc-99m-2-methoxy-isobutyl-isonitrile single photon emission computed tomography in visualizing anterior mediastinal tumor and differentiating histologic type of thymoma. *Eur J Cardiothorac Surg* 2011;40(01):136–142
- 9 Isaacs KE, Belete S, Miller BJ, et al. Video-assisted thoracoscopic surgery for ectopic mediastinal parathyroid adenoma. *BJS Open* 2019;3(06):743–749
- 10 Filser B, Uslar V, Weyhe D, Tabriz N. Predictors of adenoma size and location in primary hyperparathyroidism. *Langenbecks Arch Surg* 2021;406(05):1607–1614